

Original Article

Risk factors for C5 palsy after anterior cervical decompression

Yipeng Yang, Yu Wang, Junming Cao, Hehuan Xia, Zhihong Wang, Yong Shen

Department of Spine Surgery, The Third Hospital of Hebei Medical University, Shijiazhuang City 050051, Hebei Province, P.R. China

Received April 13, 2018; Accepted May 3, 2018; Epub July 15, 2018; Published July 30, 2018

Abstract: Objective: To investigate risk factors for C5 palsy following anterior cervical decompression (ACD). Methods: A retrospective analysis was made on clinical data from 100 patients with cervical spondylotic myelopathy (CSM) admitted to the Department of Spine Surgery of The Third Hospital of Hebei Medical University from January 2015 to June 2017. All the patients underwent ACD. In terms of the criteria for diagnosing postoperative C5 palsy, the patients were divided into the palsy group and the non-palsy group. The patients in the two groups were compared in the basic data, the Japanese Orthopaedic Association (JOA) scores, changes in the values of cervical lordosis, the sagittal diameters of C4/C5 intervertebral foramina, and the incidence of preoperative hyper-intense signal changes within the spinal cord at C4-C5. Multivariate logistic regression analysis was employed for exploring the risk factors for C5 palsy. Results: The patients in the two groups differed insignificantly in basic data (age, sex, operative time, intraoperative blood loss, and course of disease). The postoperative JOA scores in the palsy group were significantly lower than those in the non-palsy group ($P < 0.001$). The changes in the values of cervical lordosis before and after surgery in the paralyzed group were greater than those in the non-palsy group, but sagittal diameters of C4/C5 intervertebral foramina were remarkably larger in the non-palsy group than in the palsy group (all $P < 0.001$). The incidence of preoperative hyper-intense signal changes within the spinal cord at C4-C5 varied insignificantly between the two groups. Multivariate logistic regression analysis demonstrated that changes in the values (greater than 6.5°) of cervical lordosis before and after surgery, and sagittal diameter (less than 2.2 mm) of C4/C5 intervertebral foramina were risk factors for the presence of postoperative C5 palsy. Conclusion: For patients with CSM who had undergone ACD, changes in the values of cervical lordosis before and after surgery, changes in the values of cervical lordosis, and the sagittal diameter of C4/C5 intervertebral foramina are risk factors for presence of postoperative C5 palsy.

Keywords: Cervical spondylotic myelopathy, anterior cervical decompression, C5 palsy, risk factor

Introduction

Clinically, cervical spondylosis (CS) is a common degenerative disease which severely affects patients' physical and mental health, and quality of life [1, 2]. Surgery is necessary when the spinal cord is compressed severely. Currently, clinically surgical techniques for CS are primarily anterior and posterior cervical approaches. Postoperative cervical C5 palsy is a frequently-seen complication, and is difficult to treat clinically [3, 4]. C5 palsy is considered to be the clinical manifestation of decreases in muscle strength of deltoid muscle or *musculus biceps brachii* associated with or without shoulder numbness, pain, and other functional

impairments following cervical decompression surgery, without any aggravation of impaired spinal cord functions [5, 6]. In recent years, with the extensive application of cervical decompression surgery, postoperative C5 palsy is increasingly prevalent, which captures increasing attention from relevant scholars.

However, the exact mechanisms for C5 palsy remain unknown. The presence of C5 palsy may be related to surgery-induced injury, spinal cord ischemia-reperfusion injury, spinal cord drift after decompression, or segmental lesions of the spinal cord [7, 8]. Multiple studies have focused on the pathogenesis of C5 palsy after posterior cervical decompression, but few have

Risk factors for C5 palsy after anterior cervical decompression

Table 1. Basic patient data

Variables	Case	Age (year)	Sex	CD (mon)	OT (min)	IOBL (mL)
Palsy group	11	48.6±5.1	7/4	28.7±7.5	127.8±12.4	63.5±6.7
Non-palsy group	89	50.6±5.5	41/48	24.8±6.7	130.1±13.2	62.4±5.8
t/X ²		1.319	0.199	0.420	0.357	0.201
P		0.192	0.656	0.679	0.722	0.849

Note: CD, course of disease; OT, operative time; IOBL, intraoperative blood loss.

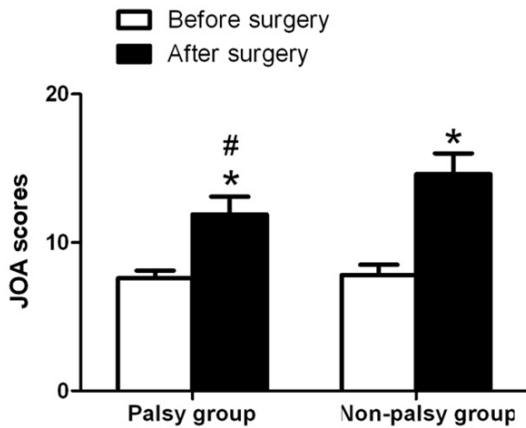


Figure 1. Comparison of JOA scores of patients before and after surgery between the non-palsy group and the palsy group. *P < 0.001, compared within the same group before surgery; #P < 0.001, compared to the non-palsy group. JOA denotes the Japanese Orthopedic Association.

reported on C5 palsy after anterior cervical decompression [9-12]. To further explore the risk factors for C5 palsy after anterior cervical decompression, the current study was designed. From January 2015 to June 2017, we retrospectively reviewed the clinical records of 100 patients with CS who had undergone anterior cervical decompression (ACD) in The Third Hospital of Hebei Medical University to elucidate the risk factors related to the onset of C5 palsy, with an expectation to provide more experimental evidence for better prevention and treatment of C5 palsy.

Materials and methods

Study patients

From January 2015 to June 2017, 100 patients with confirmed CS admitted to The Third Hospital of Hebei Medical University who had undergone ACD were recruited in this study. C5 palsy was defined as when the patient's muscle strength of the musculus biceps brachii or del-

toid muscle had declined by at least one level without any aggravation of spinal cord symptoms. Enrolled patients with ACD were randomly divided into the palsy group and the non-palsy group. Patients older than 18 years of age were eligible for enrollment

if they presented with the indications for anterior cervical decompression (ACD) and could actively comply with this study. Patients were excluded if they had a history of CS, cervical ossification of the posterior longitudinal ligaments, severe hepatorenal disorder, osteoporosis, tumors, or co-infection. This study was approved by the Medical Ethics Committee of The Third Hospital of Hebei Medical University, and all patients submitted written informed consent.

Surgical procedures

As far as the surgical technique for treating CSM was concerned, ACD was selected for the patients. The procedures were as follows: under general anesthesia, each patient was placed in supine position, with the neck slightly out-stretched. A right transverse incision was made in the anterior neck. The tissues were separated layer by layer. The cervical vascular sheath and the visceral sheath were separated, and advancing into the prevertebral space allows the exposure of the anterior surface of the spine. A positioning needle was inserted into the intervertebral space and confirmed using a C-arm x-ray apparatus during the operation. After disc nucleus spreaders were installed in the positions above and below the site for discectomy, a transverse incision was made to cut the anterior longitudinal ligaments in the disc center. The intervertebral disc tissue and endplate cartilage were removed with a curette and nucleus pulposus forceps. After rinsing the lesions with normal saline, the remaining nucleus pulposus tissue was removed from different angles with nerve dissectors. Thorough decompression was performed until the dura mater returned to normal. A bone graft fusion cage in suitable size was selected, filled with autologous bone and then implanted into the corresponding intervertebral space. After it had been confirmed in good condition by the C-arm

Risk factors for C5 palsy after anterior cervical decompression

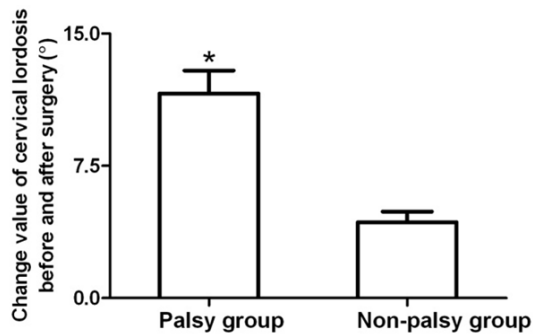


Figure 2. Changes in the values of cervical lordosis of patients in the two groups. *P < 0.001, compared with the non-palsy group.

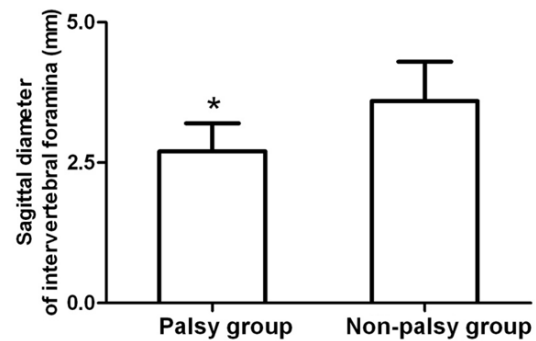


Figure 3. Sagittal diameters of C4/C5 intervertebral foramina of patients in the two groups. *P < 0.001, compared with the non-palsy group.

x-ray apparatus, the anterior edge of the vertebral body was fixed by plates. The surgical region was washed and the wound was tightly closed to stop bleeding. A drainage tube was placed and the incision was sutured layer by layer. After surgery, the patients received routine symptomatic treatment which included administration of antibiotics for anti-infection, trophic nerve, and rehydration. They were also instructed to wear cervical collars. The drainage tubes were removed within 24-48 h after surgery. Three days after surgery, patients were asked to ambulate and do exercise, and the cervical collars were taken off at around 3 months.

Outcome measures

The primary outcomes in this study are independent risk factors for postoperative C5 palsy, which were evaluated by univariate and multivariate logistic regression analyses.

Secondary outcomes comprised the Japanese Orthopaedic Association (JOA) scores, changes in the value of cervical lordosis, the difference in sagittal diameter of C4/C5 intervertebral foramina, and the incidence of preoperative hyper-intense signal changes within the spinal cord at C4-C5. The JOA scores covered motor, sensory, and bladder functions. On a scale of 17 points, lower scores indicated more severe spinal cord dysfunction. On the lateral cervical spine radiograph, the angle formed by drawing two lines in parallel to the endplates inferior to C2 and C7 vertebra was the Cobb angle. The changes in the values of cervical lordosis were assessed by the differences in the values of the Cobb angle before and after surgery. The sagittal diameter of C4/C5 intervertebral

foramina was defined as the sagittal diameter of the intervertebral foramina from the junction between the posterior lower border of the uncinate process of the upper vertebrae and the posterior upper border of the uncinate process of the lower vertebrae to the midpoint at the junction between the superior and inferior articular processes.

Statistical analysis

All the data were processed using SPSS software, version 19.0. Quantitative data are described as mean \pm sd, with the independent samples t-tests used for between-group comparisons. Count data were analyzed by the Chi-square tests. The risk factors for C5 palsy following surgery were evaluated by multivariate logistic regression analyses. The included variables were the indicators which were remarkably different between the two groups in univariate analysis, including the JOA scores, the changes in the values of cervical lordosis, the sagittal diameter of C4/C5 intervertebral foramina, and preoperative hyper-intense signal changes within the spinal cord at C4-C5 of patients. The variables were evaluated by the step-wise method. P < 0.05 was set as significant difference.

Results

Basic data of patients

The basic data (sex, age, course of disease, operative time, and intraoperative blood loss) were well-matched between the palsy group and the non-palsy group, as illustrated in **Table 1**.

Risk factors for C5 palsy after anterior cervical decompression

Table 2. Assigned values for the variables

Variables	Assigned values
Postoperative JOA score	1: JOA score > 8.5 2: JOA score < 8.5
Changes in the cervical lordosis values	1: Cervical lordosis value < 6.5° 2: Cervical lordosis value > 6.5°
Sagittal diameter of intervertebral foramina	1: C4/C5 sagittal diameter > 2.2 mm 2: C4/C5 sagittal diameter < 2.2 mm
Preoperative hyper-intense signal changes within spinal cord	1: No 2: Yes

Note: JOA, the Japanese Orthopedic Association.

JOA scores of patients

No significant difference was noted in preoperative JOA scores between the non-palsy group and the palsy group (7.6 ± 0.5 vs 7.8 ± 0.7 , $P=0.967$). The postoperative JOA scores were remarkably higher in both groups than those before surgery ($P < 0.001$), with considerably lower JOA scores in the palsy group than in the non-palsy group (11.9 ± 1.2 vs 14.6 ± 1.4 , $P < 0.001$; **Figure 1**).

Changes in the values of cervical lordosis of patients

The value of cervical lordosis of patients was increased by 11.6 ± 1.3 in the palsy group, and 4.3 ± 0.6 in the non-palsy group, with substantive difference between the two groups ($P < 0.001$; **Figure 2**).

Sagittal diameter of C4/C5 intervertebral foramina of patients

The sagittal diameter (2.7 ± 0.5 mm) of the C4/C5 intervertebral foramen in the palsy group was markedly lower than that (3.6 ± 0.7 mm) in the non-palsy group ($P < 0.001$; **Figure 3**).

Preoperative hyper-intense signal changes within the spinal cord at C4-C5

The preoperative hyper-intense signal changes within spinal cord at C4-C5 were noted in 3 of 11 patients in the palsy group, and in 13 of 89 patients in the non-palsy group. There was no substantive difference in the proportions of patients with preoperative hyper-intense signal changes within the spinal cord at C4-C5 between the two groups ($X^2=0.416$, $P=0.519$).

Multivariate logistic regression analysis

Multivariate logistic regression analysis was conducted with the presence of palsy symptom after ACD was utilized as a dependent variable, and the postoperative JOA scores, the changes in the values of cervical lordosis, the sagittal diameter of C4/C5 intervertebral foramina, and the preoperative hyper-intense signal changes within spinal cord at C4-C5 as independent variables. The assigned values for the variables are listed in **Table 2**. The analysis demonstrated that the changes in the values of cervical lordosis, and the sagittal diameter of C4/C5 intervertebral foramina were high risk factors for C5 palsy following ACD (**Table 3**).

Discussion

C5 palsy, one of the common complications after cervical decompression surgery, was first introduced by Scoville in 1961 [13]. A retrospective analysis on the clinical data of 750 patients with cervical surgery revealed that the rate of overall postoperative C5 palsy was approximately 6.7%, of which the rate of postoperative C5 palsy after ACD was 5.1% [14]. Hashimoto et al. reported 8.5% of C5 palsy after ACD in patients [15]. In the current study, postoperative C5 palsy occurred in approximately 11% of the 100 enrolled patients who had undergone ACD. In this study, C5 palsy was diagnosed when the muscle strength of musculus biceps brachii or deltoid muscle had been reduced by at least one level or more. The different incidences of C5 palsy reported might be attributed to the diverse criteria for identifying declining muscle strength in previous studies. The results of the current study indicated no remarkable difference was noted in the preop-

Risk factors for C5 palsy after anterior cervical decompression

Table 3. Multivariate logistic regression analysis for C5 palsy

Factors	β	SE	Wald	Adjusted OR	OR (95% CI)	P
Changes in the cervical lordosis values	0.747	0.388	6.069	1.845	1.065-1.354	0.003
Sagittal diameter of intervertebral foramina	0.842	0.415	5.374	0.338	0.087-0.814	0.021

Note: OR, odd ratio; CI, confidence interval.

erative JOA scores between the patients with C5 palsy and those without C5 palsy, but postoperative JOA scores were considerably improved in all the patients, with lower JOA scores in patients with C5 palsy than those without C5 palsy. Previous studies reported better overall prognosis of postoperative C5 palsy, and 67% of patients had recovered neurologic functions within 2 years after surgery, with a mean recovery duration of approximately 4.1 mon [16]. In our current study, the differences in JOA scores of patients between the two groups might affect patient's satisfaction with the improvements in surgical outcomes.

Segmental pathological changes in the spinal cord are one of the key mechanisms for presence of C5 palsy following ACD. A study stated hyper-intense opacities at the C4/C5 segment of the cervical spine on T2WI images, implying that long-term compression gave rise to pathological changes (degeneration of the spinal cord or edema), and caused segmental spinal cord dysfunctions, resulting in the presence of symptoms of C5 palsy. Therefore, it is considered that the hyper-intense signals on T2WI correlate with C5 palsy [17]. Nevertheless, other studies show that the changes in hyper-intense signals on T2WI are merely unspecific changes in inflammation and edema of the spinal cord after compression, and local hyper-intensity is predominantly found in the gray matter surrounding the central canal of the spinal cord [18, 19]. The multivariate logistic regression analysis in the current study demonstrated that there was no correlation between C5 palsy following ACD and segment C4/C5 hyper-intense signals on T2WI. This indicates that not all patients with hyper-intense regions on T2WI will develop C5 palsy.

In the current study, values for cervical lordosis greater than 6.5° was one of the risk factors for postoperative C5 palsy. Likewise, another study reported greater changes in the values of cervical lordosis in patients with C5 palsy than in those without C5 palsy, suggesting a greater change in the value of cervical lordosis indicate

a higher incidence of postoperative C5 palsy [20]. This might be due to the fact that C5 nerve root is shorter than other nerve roots in length, and C5 is at the apex of cervical lordosis. An excessive correction of the cervical curvature may cause damage to C5 nerve root, and subsequent insufficient blood supply of the nerve root arteries, ultimately resulting in nerve root edema and neurologic impairment. This is basically in line with the results reported by Baba et al. [21].

Cervical nerve root is prone to be compressed as it runs along the cervical nerve root groove. The intervertebral foramen is the initial part of the cervical nerve root groove, and intervertebral foramen narrowing inevitably lead to nerve root compression, which in turn results in edema and neurologic disorder. Postoperative C5 palsy has been showed to be associated with narrowing of the sagittal diameter of C4/C5 intervertebral foramina [22]. Another study reported that for patients with laminoplasty, C5 nerve root decompression helps reduce the incidence of postoperative C5 palsy [23]. The result of the current study demonstrated that the sagittal diameter of intervertebral foramina was more remarkably reduced in the palsy group than in the non-palsy group ($P < 0.001$). Multivariate logistic regression analysis showed that sagittal diameter narrowing of C4/C5 intervertebral foramina is an important risk factor for C5 palsy after ACD, which is largely consistent with the results reported by Katsumi et al. [24].

However, there are still some limitations in the current study, which include the small sample size of enrolled patients with postoperative C5 palsy, a single-center study in nature, no long-term follow-ups of patients, and the defects of the retrospective study, as well as the failure to fully elucidate the pathogenesis of C5 palsy. In the future, additional multi-center prospective randomized controlled trials with larger sample sizes and diversified imaging indicators are required for further validation.

Risk factors for C5 palsy after anterior cervical decompression

In conclusion, in the current study, we made a retrospective analysis regarding the clinical data of 100 patients who had undergone ACD. Postoperative C5 palsy occurred in 11 patients. However, causes for the presence of C5 palsy were complicated, and there were numerous compounding factors. The results of the current study demonstrated that the changes in the values of cervical lordosis and the sagittal diameter of C4/C5 intervertebral foramina were risk factors for postoperative C5 palsy. This, to a certain degree, has a positive effect on prevention and treatment of postoperative C5 palsy and provides more experimental evidence for clinical prevention of postoperative C5 palsy.

Disclosure of conflict of interest

None.

Address correspondence to: Yong Shen, Department of Spine Surgery, The Third Hospital of Hebei Medical University, No. 139 Ziqiang Road, Shijiazhuang City 050051, Hebei Province, P.R. China. Tel: +86-0311-88603000; Fax: +86-0311-88603000; E-mail: Yongshen63@163.com

References

- [1] Zheng B, Hao D, Guo H and He B. ACDF vs TDR for patients with cervical spondylosis-an 8 year follow up study. *BMC Surg* 2017; 17: 113.
- [2] Wu D, Liu CZ, Yang H, Li H and Chen N. Surgical interventions for cervical spondylosis due to ossification of posterior longitudinal ligament: a meta-analysis. *Medicine (Baltimore)* 2017; 96: e7590.
- [3] Basaran R and Kaner T. C5 nerve root palsy following decompression of cervical spine with anterior versus posterior types of procedures in patients with cervical myelopathy. *Eur Spine J* 2016; 25: 2050-2059.
- [4] Liu T, Kong J, Zou W, Sun Z, Yan W and Xiao J. The correlation study of C5 nerve root palsy and common body position in Posterior Total Laminectomy Decompression and Instrumentation. *Turk Neurosurg* 2016; 26: 280-285.
- [5] Kurakawa T, Miyamoto H, Kaneyama S, Sumi M and Uno K. C5 nerve palsy after posterior reconstruction surgery: predictive risk factors of the incidence and critical range of correction for kyphosis. *Eur Spine J* 2016; 25: 2060-2067.
- [6] Kim S, Lee SH, Kim ES and Eoh W. Clinical and radiographic analysis of c5 palsy after anterior cervical decompression and fusion for cervical degenerative disease. *J Spinal Disord Tech* 2014; 27: 436-441.
- [7] Sakaura H, Hosono N, Mukai Y, Ishii T and Yoshikawa H. C5 palsy after decompression surgery for cervical myelopathy: review of the literature. *Spine (Phila Pa 1976)* 2003; 28: 2447-2451.
- [8] Wang T, Tian XM, Liu SK, Wang H, Zhang YZ and Ding WY. Prevalence of complications after surgery in treatment for cervical compressive myelopathy: a meta-analysis for last decade. *Medicine (Baltimore)* 2017; 96: e6421.
- [9] Pan FM, Wang SJ, Ma B and Wu DS. C5 nerve root palsy after posterior cervical spine surgery. *J Orthop Surg (Hong Kong)* 2017; 25: 2309499016684502.
- [10] Gu Y, Cao P, Gao R, Tian Y, Liang L, Wang C, Yang L and Yuan W. Incidence and risk factors of C5 palsy following posterior cervical decompression: a systematic review. *PLoS One* 2014; 9: e101933.
- [11] Wang H, Zhang X, Lv B, Ding W, Shen Y, Yang D and Bai Z. Analysis of correlative risk factors for C5 palsy after anterior cervical decompression and fusion. *Int J Clin Exp Med* 2015; 8: 3983-3991.
- [12] Anelman SM, McAnany SJ, Qureshi SA and Hecht AC. Bilateral C5 motor palsy after anterior cervical decompression and fusion: a case report and review of the literature. *Int J Spine Surg* 2017; 11: 14.
- [13] Scoville WB. Cervical spondylosis treated by bilateral facetectomy and laminectomy. *J Neurosurg* 1961; 18: 423-428.
- [14] Nassr A, Eck JC, Ponnappan RK, Zanon RR, Donaldson WF 3rd and Kang JD. The incidence of C5 palsy after multilevel cervical decompression procedures: a review of 750 consecutive cases. *Spine (Phila Pa 1976)* 2012; 37: 174-178.
- [15] Hashimoto M, Mochizuki M, Aiba A, Okawa A, Hayashi K, Sakuma T, Takahashi H, Koda M, Takahashi K and Yamazaki M. C5 palsy following anterior decompression and spinal fusion for cervical degenerative diseases. *Eur Spine J* 2010; 19: 1702-1710.
- [16] Imagama S, Matsuyama Y, Yukawa Y, Kawakami N, Kamiya M, Kanemura T and Ishiguro N. C5 palsy after cervical laminoplasty: a multicentre study. *J Bone Joint Surg Br* 2010; 92: 393-400.
- [17] Wang T, Wang H, Liu S and Ding WY. Incidence of C5 nerve root palsy after cervical surgery: a meta-analysis for last decade. *Medicine (Baltimore)* 2017; 96: e8560.
- [18] Kang KC, Suk KS, Kim HS, Moon SH, Lee HM, Seo JH, Kim SM, Jin SY and Mella P. Preoperative risk factors of C5 nerve root palsy after laminectomy and fusion in patients with cervical

Risk factors for C5 palsy after anterior cervical decompression

- cal myelopathy: analysis of 70 consecutive patients. *Clin Spine Surg* 2017; 30: 419-424.
- [19] Katsumi K, Yamazaki A, Watanabe K, Ohashi M and Shoji H. Analysis of C5 palsy after cervical open-door laminoplasty: relationship between C5 palsy and foraminal stenosis. *J Spinal Disord Tech* 2013; 26: 177-182.
- [20] Shou F, Li Z, Wang H, Yan C, Liu Q and Xiao C. Prevalence of C5 nerve root palsy after cervical decompressive surgery: a meta-analysis. *Eur Spine J* 2015; 24: 2724-2734.
- [21] Baba S, Ikuta K, Ikeuchi H, Shiraki M, Komiya N, Kitamura T, Senba H and Shidahara S. Risk factor analysis for C5 palsy after double-door laminoplasty for cervical spondylotic myelopathy. *Asian Spine J* 2016; 10: 298-308.
- [22] Blizzard DJ, Gallizzi MA, Sheets C, Klement MR, Kleeman LT, Caputo AM, Eure M and Brown CR. The role of iatrogenic foraminal stenosis from lordotic correction in the development of C5 palsy after posterior laminectomy and fusion. *J Orthop Surg Res* 2015; 10: 160.
- [23] Komagata M, Nishiyama M, Endo K, Ikegami H, Tanaka S and Imakiire A. Prophylaxis of C5 palsy after cervical expansive laminoplasty by bilateral partial foraminotomy. *Spine J* 2004; 4: 650-655.
- [24] Katsumi K, Yamazaki A, Watanabe K, Ohashi M and Shoji H. Can prophylactic bilateral C4/C5 foraminotomy prevent postoperative C5 palsy after open-door laminoplasty?: a prospective study. *Spine (Phila Pa 1976)* 2012; 37: 748-754.