

Case Report

A case report of clonorchiasis misdiagnosed as liver metastasis of breast cancer

Lingjun Meng^{1*}, Di Zhou^{1*}, Zhenzi Bai², Ronghua Hao³, Lintao Bi¹, Zhenxia Lu¹

Departments of ¹Hematology and Oncology, ²Infectious Disease, China-Japan Union Hospital Affiliated to Jilin University, Changchun, Jilin, P.R. China; ³Department of Pathogeny Biology, Norman Bethune Medical College of Jilin University, Changchun, Jilin, P.R. China. *Equal contributors.

Received September 28, 2017; Accepted May 6, 2018; Epub August 15, 2018; Published August 30, 2018

Abstract: The liver is a common metastatic site of breast cancer, but not all liver masses in cases of breast cancer are metastases. Therefore, a diagnosis of liver metastasis should be carefully considered before the liver mass is biopsied again. In the present case, a 38-year-old Chinese female presented with abdominal discomfort after breast cancer, and a liver mass was detected on abdominal ultrasonography and MRI scans, which led to the suspicion of liver metastasis of breast cancer. However, after core needle aspiration of the liver mass, a metastasis was excluded. Finally, the diagnosis of clonorchiasis was confirmed, and the liver mass disappeared two months after treatment with praziquantel.

Keywords: Breast cancer, liver metastasis, clonorchiasis

Introduction

The liver is a common metastatic site, and the incidence rate of liver metastasis is approximately 7.9%-23.3% according to different breast cancer subtypes [1]. However, not all liver mass lesions that form after breast cancer are metastases, and a re-biopsy of the liver mass should be performed to exclude other diseases before subsequent therapy is given. In this report, we describe a case of clonorchiasis misdiagnosed as liver metastasis of breast cancer before re-biopsy.

Case report

A 38-year-old Chinese female with left invasive breast cancer underwent a modified radical mastectomy with dissection of the axillary lymph nodes in August 2015. The pathological stage of the cancer was T1 (m) NOMO, the histological grade was 2, and lymphovascular invasion was present. Immunohistochemical staining showed ER positivity (80% 3+), PR positivity (80% 3+), moderate HER2 expression (2+), and Ki-67 positivity (20%). The HER2 test result according to dual-probe in situ hybridiza-

tion (ISH) was negative. According to the 2015 St Gallen Consensus, this patient had the luminal B-like (HER-2 negative) subtype of breast cancer. Four cycles of chemotherapy consisting of docetaxel-cyclophosphamide were given, which was followed by the start of endocrine therapy (tamoxifen 20 mg orally QD) in November 2015. In September 2016, the patient presented with abdominal discomfort of the right upper quadrant, and subsequent abdominal ultrasonography revealed a liver mass. The MRI scan showed an irregular anomaly in an unequal signal area in the right lower lobe of the liver that also had an unclear boundary. The lesion was demonstrated to be mildly hypointense to isointense on T1-weighted images (T1WI) and hyperintense on T2-weighted images (T2WI), with a slightly higher signal on diffusion weighted imaging (DWI) images (Upper panel of **Figure 1**). In addition, splenomegaly eight rib units in size were also observed. Based on these results, a liver metastasis was initially diagnosed. Eosinophilia was found on complete blood count (CBC), with 1360 eosinophilic leukocytes per microliter (μ L). The tumor markers, peripheral blood biochemical tests, brain and chest CT, and bone scan were all normal. The

Clonorchiasis misdiagnosed as liver metastasis of breast cancer

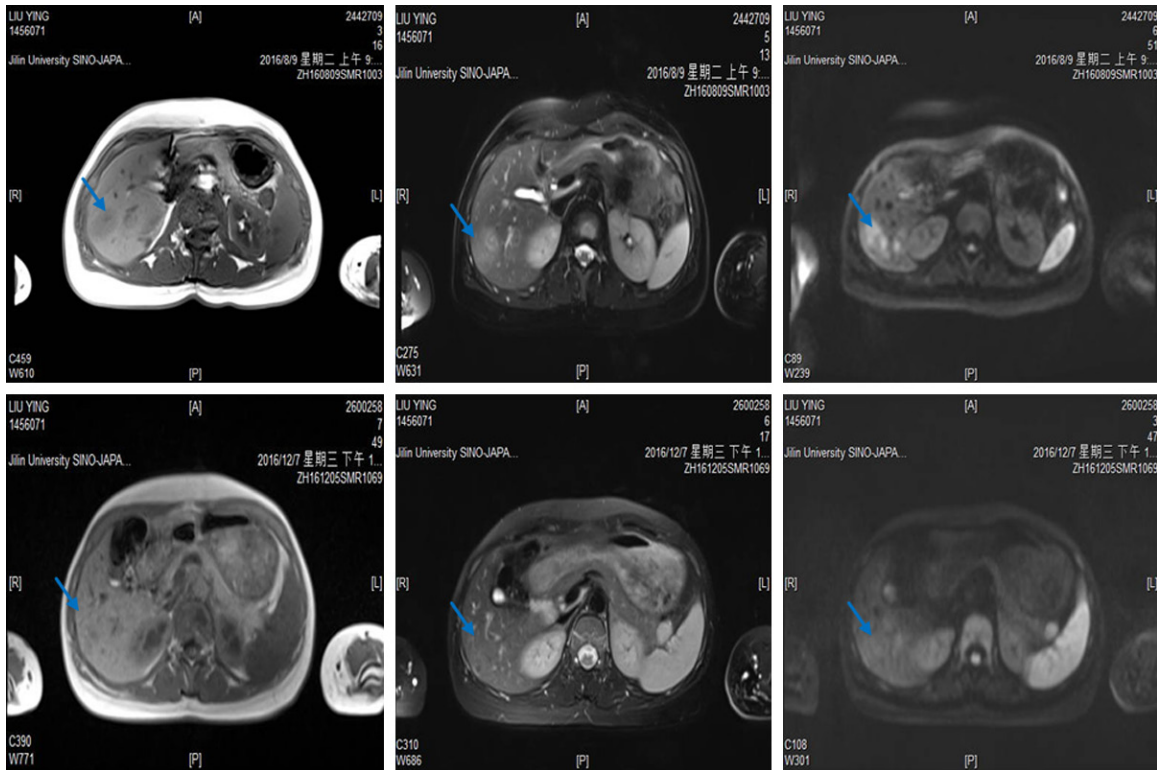


Figure 1. The mass (blue arrow) in the right lower lobe of liver on MRI. (Left: T1WI; Middle: T2WI; Right: DWI) (Upper: before treatment; Lower: after treatment).



Figure 2. The eggs of *C. sinensis* (blue arrow) detected in stool using Kato-Katz method; magnification $\times 100$.

patient reported no history of hepatitis or alcohol abuse. To confirm the diagnosis and to assess the ER, PR, and HER2 status of the suspected metastatic lesion, an ultrasonography-guided core needle aspiration of the liver mass was performed. Unexpectedly, no cancer cells were seen in the aspirated specimen, but diffuse eosinophil infiltration was observed. Based on the eosinophil infiltration in the liver

mass specimen, eosinophilia in the peripheral blood, splenomegaly and a habit of consuming undercooked or raw freshwater fish, the diagnosis of parasite infection was established. The patient's stool specimen was sent to the Parasitology Department of Jilin University School of Basic Medical Sciences for further tests. The presence of eggs, which is the gold standard for the diagnosis of *C. sinensis* infection, was detected in the stool using the Kato-Katz method (**Figure 2**). Finally, the diagnosis of clonorchiasis was confirmed, and praziquantel (25 mg/kg, three times daily for 2 days) was given as treatment for clonorchiasis. Two months after treatment, the liver mass had disappeared, as evidenced in a repeat MRI scan (Lower panel of **Figure 1**).

Discussion

Breast cancer (BC) is the most common cancer diagnosed and is the leading cause of cancer death among women worldwide [2]. With the advent of surgery, radiotherapy, chemotherapy, endocrine therapy and targeted therapy, the survival of individuals with breast cancer has

improved enormously, but relapse is still inevitable. For ER-positive/HER2-negative tumors, the risk of relapse is approximately 2-3% yearly [3]. The liver is the most common site of metastasis of breast cancer, and for luminal B cancers, the fifteen-year cumulative incidence rate of liver metastasis is approximately 13.8% [1]. However, a diagnosis of metastasis solely based on a space-occupying lesion of the liver on radiology must be considered carefully, as a rebiopsy is essential.

First, it has been reported that women are at a higher risk for the development of a second non-breast primary cancer after the diagnosis of breast cancer; the incidence is approximately 1.5, and the common sites of a second primary are the lungs, the digestive system and the genitourinary system [4-8]. Second, a discordance in the ER and PR status is observed between the primary breast cancer and recurrent disease in as many as 40% of women, while discordance in HER2 status is observed in approximately 5% [9, 10]. In one study, for liver metastases, changes in ER, PR, and HER2 status were observed in 14.5%, 48.6% and 13.9% of patients, respectively, and the discordance in receptor status between liver metastases and the primary tumor led to a change in therapy for 12.1% patients [11]. Hence, before any therapy is begun, a core needle biopsy of the suspected metastasis is necessary, as it provides histological information and the ER, PR and HER-2 status, which are essential to guide treatment decisions [12]. Therefore, we performed an ultrasonography-guided core rebiopsy of the liver mass and did not observe any cancer cells but rather detected a large quantity of eosinophils, which were also increased in the peripheral blood of this patient.

Eosinophilia can be idiopathic (primary), or more commonly, secondary to another disease (reactive). Reactive eosinophilia is typically found in patients with parasitic infections, toxic or allergic drug reactions and atopic disorders [13]. Clonorchiasis, one of the most common zoonoses and an important food-borne parasitic disease, is caused by *C. sinensis*. The life cycle of *C. sinensis* occurs in three hosts: the first intermediate hosts (freshwater snails), the second intermediate hosts (freshwater fish and occasionally shrimps), and the definitive hosts (human or carnivorous mammals). Chronic *C.*

sinensis infection causes diverse complications in the liver and biliary systems, and patients present with various symptoms that are dependent on worm burden, including nausea, diarrhea, indigestion, asthenia, dizziness, headache, vertigo, abdominal discomfort or pain, especially in the right upper quadrant. Typical physical signs of *C. sinensis* infection are jaundice, hepatosplenomegaly, and liver tenderness [14, 15]. Clonorchiasis is prevalent in Asian countries, and in China, an estimated 13 million people are infected with *C. sinensis*. In China, the Northeast-Heilongjiang and Jilin provinces and the Southeast-Guangdong and Guangxi provinces, are major endemic regions [16]. The detection of eggs in stool using the Kato-Katz method is the gold standard for diagnosis of *C. sinensis* infection. Imaging methods including ultrasound, magnetic resonance imaging (MRI), and computed tomography (CT) are of importance for accessory diagnosis. However, these methods are nonspecific and exhibit relatively poor sensitivity. Currently, the only recommended drug for the treatment of clonorchiasis is praziquantel, which has been approved for use in China [14, 15].

This patient resides in Jilin province, which is an endemic area of clonorchiasis. The patient also had splenomegaly, a physical sign of clonorchiasis. In addition, this patient frequently consumed undercooked or raw freshwater fish (the second intermediate hosts of *C. sinensis*). All of these combined with the final evidence of the detection of *C. sinensis* eggs in the patient's stool led to a diagnosis of clonorchiasis. Effective treatment with praziquantel further confirmed the diagnosis in this patient.

In conclusion, a core biopsy of a suspected breast cancer metastasis to confirm histology and to re-evaluate biomarkers (proliferation/grade, ER, PR, and HER-2 status) should be the first step before any therapy is begun.

Disclosure of conflict of interest

None.

Address correspondence to: Dr. Lintao Bi, Department of Hematology and Oncology, China-Japan Union Hospital Affiliated to Jilin University, 5th Building, 126 Xiantai Street, Changchun 130033, Jilin, P.R. China. Tel: +86 13614305610; Fax: 0431-84995733; E-mail: mlj501@163.com

References

- [1] Kennecke H, Yerushalmi R, Woods R, Cheang MC, Voduc D, Speers CH, Nielsen TO, Gelmon K. Metastatic behavior of breast cancer subtypes. *J Clin Oncol* 2010; 28: 3271-3277.
- [2] Torre LA, Bray F, Siegel RL, Ferlay J, Lortet-Tieulent J, Jemal A. Global cancer statistics, 2012. *CA Cancer J Clin* 2015; 65: 87-108.
- [3] Cossetti RJ, Tyldesley SK, Speers CH, Zheng Y, Gelmon KA. Comparison of breast cancer recurrence and outcome patterns between patients treated from 1986 to 1992 and from 2004 to 2008. *J Clin Oncol* 2015; 33: 65-73.
- [4] Donin N, Filson C, Drakaki A, Tan HJ, Castillo A, Kwan L, Litwin M, Chamie K. Risk of second primary malignancies among cancer survivors in the United States, 1992 through 2008. *Cancer* 2016; 122: 3075-3086.
- [5] Hung MH, Liu CJ, Teng CJ, Hu YW, Yeh CM, Chen SC, Chien SH, Hung YP, Shen CC, Chen TJ, Tzeng CH, Liu CY. Risk of second non-breast primary cancer in male and female breast cancer patients: a population-based cohort study. *PLoS One* 2016; 11: e0148597.
- [6] Marcheselli R, Marcheselli L, Cortesi L, Bari A, Cirilli C, Pozzi S, Ferri P, Napolitano M, Federico M, Sacchi S. Risk of second primary malignancy in breast cancer survivors: a nested population-based case-control study. *J Breast Cancer* 2015; 18: 378-385.
- [7] Mellemkjaer L, Friis S, Olsen JH, Scelo G, Hemminki K, Tracey E, Andersen A, Brewster DH, Pukkala E, McBride ML, Kliewer EV, Tonita JM, Kee-Seng C, Pompe-Kirn V, Martos C, Jonasson JG, Boffetta P, Brennan P. Risk of second cancer among women with breast cancer. *Int J Cancer* 2006; 118: 2285-2292.
- [8] Molina-Montes E, Pollan M, Payer T, Molina E, Davila-Arias C, Sanchez MJ. Risk of second primary cancer among women with breast cancer: a population-based study in Granada (Spain). *Gynecol Oncol* 2013; 130: 340-345.
- [9] Amir E, Clemons M, Purdie CA, Miller N, Quinlan P, Geddie W, Coleman RE, Freedman OC, Jordan LB, Thompson AM. Tissue confirmation of disease recurrence in breast cancer patients: pooled analysis of multi-centre, multidisciplinary prospective studies. *Cancer Treat Rev* 2012; 38: 708-714.
- [10] Macfarlane R, Seal M, Speers C, Woods R, Masoudi H, Aparicio S, Chia SK. Molecular alterations between the primary breast cancer and the subsequent locoregional/metastatic tumor. *Oncologist* 2012; 17: 172-178.
- [11] Curigliano G, Bagnardi V, Viale G, Fumagalli L, Rotmensz N, Aurilio G, Locatelli M, Pruneri G, Giudici S, Bellomi M, Della Vigna P, Monfardini L, Orsi F, Nole F, Munzone E, Goldhirsch A. Should liver metastases of breast cancer be biopsied to improve treatment choice. *Ann Oncol* 2011; 22: 2227-2233.
- [12] Cardoso F, Costa A, Senkus E, Aapro M, Andre F, Barrios CH, Bergh J, Bhattacharyya G, Biganzoli L, Cardoso MJ, Carey L, Corneliussen-James D, Curigliano G, Dieras V, El Saghir N, Eniu A, Fallowfield L, Fenech D, Francis P, Gelmon K, Gennari A, Harbeck N, Hudis C, Kaufman B, Krop I, Mayer M, Meijer H, Mertz S, Ohno S, Pagani O, Papadopoulos E, Peccatori F, Pernault-Llorca F, Piccart MJ, Pierga JY, Rugo H, Shockney L, Sledge G, Swain S, Thomssen C, Tutt A, Vorobiof D, Xu B, Norton L, Winer E. 3rd ESO-ESMO international consensus guidelines for advanced breast cancer (ABC 3). *Breast* 2017; 31: 244-259.
- [13] Butt NM, Lambert J, Ali S, Beer PA, Cross NC, Duncombe A, Ewing J, Harrison CN, Knapper S, McLornan D, Mead AJ, Radia D, Bain BJ; British Committee for Standards in Haematology. Guideline for the investigation and management of eosinophilia. *Br J Haematol* 2017; 176: 553-572.
- [14] Qian MB, Utzinger J, Keiser J, Zhou XN. Clonorchiasis. *Lancet* 2016; 387: 800-810.
- [15] Tang ZL, Huang Y, Yu XB. Current status and perspectives of clonorchis sinensis and clonorchiasis: epidemiology, pathogenesis, omics, prevention and control. *Infect Dis Poverty* 2016; 5: 71.
- [16] Fang YY, Chen YD, Li XM, Wu J, Zhang QM, Ruan CW. Current prevalence of clonorchis sinensis infection in endemic areas of China. *Zhongguo Ji Sheng Chong Xue Yu Ji Sheng Chong Bing Za Zhi* 2008; 26: 99-103, 109.