

Original Article

Experiences in the management of acute abdominal aortic occlusion

Feng-Rui Lei^{1*}, Wen-Dong Li^{2*}, Xiao-Qiang Li^{1,2}, Hong-Fei Sang¹, Ai-Min Qian¹, Xiao-Bin Yu¹, Li-Wei Zhu¹, Kun Jiang¹

¹Department of Vascular Surgery, The Second Affiliated Hospital of Soochow University, Suzhou, China; ²Department of Vascular Surgery, The Affiliated Drum Tower Hospital, Nanjing University Medical School, Jiangsu, China.
*Equal contributors.

Received October 21, 2017; Accepted June 8, 2018; Epub September 15, 2018; Published September 30, 2018

Abstract: Background: Acute abdominal aortic occlusion is an infrequent but catastrophic event with limited management methods. This study aims to report our experiences of management of this rare illness. Methods: Twelve patients with acute abdominal aortic occlusion were involved in this retrospective study. The procedure, complications and clinical outcome of these patients were retrospectively reviewed. Results: Of the 12 patients, nine were treated by embolectomy using double femoral artery Fogarty catheter. Endovascular aortic aneurysms repair was performed after embolectomy in one patient. Endovascular aortic repair was performed in three patients caused by aortic dissection. All patients, except one patient died during the procedure, got a good prognosis. Ankle-brachial index was restored to normal within 24 h after the surgery. Eleven patients were followed up for 1 to 4 years. No serious blood circulatory disorder of the limb was observed. Conclusions: Fogarty embolectomy catheter and/or combined with endovascular aortic repair can significantly reduce the mortality and morbidity of acute occlusion of abdominal aorta.

Keywords: Acute abdominal aortic occlusion, thromboembolectomy, endovascular aortic aneurysms repair

Introduction

Acute abdominal aortic occlusion, with variable symptoms depending on the completeness of obstruction, is an infrequent but catastrophic event [1]. The most common symptoms include pain, pulselessness, pallor, paralysis and paresthesia in the lower extremities. It is most frequently caused by saddle embolism. And the most common embolic source is atrial fibrillation [2]. But other etiologies, such as acute thrombosis with or without preexisting aortoiliac atherosclerotic disease, thrombosis of an abdominal aortic aneurysm (AAA), aortic dissection (AD) and posttraumatic abdominal aortic occlusion can also result in this occlusion [3-7].

Acute abdominal aortic occlusion, if without a timely and proper management, may lead to disastrous consequence, for example compartment syndrome, limb loss, myoneuropathic metabolic syndrome, renal failure, visceral isch-

emia and even death [7-9]. Proper management, consisting of prompt recognition, provision of anticoagulation, immediate surgical consultation, and initiation of a limited diagnostic workup, can decrease or avoid the permanent disability [1]. Ultimately, the treatment of acute aortic occlusion is surgery. But overall, the mortality rate of the disease is extremely high.

Surgical approaches, with a time dependent outcome, vary depending on the etiologies. For patients with acute occlusion from embolism or thrombosis in aortoiliac artery, a decrease in mortality and morbidity has been seen with the use of high-dose anticoagulation and embolectomy with Fogarty arterial catheters via bilateral common femoral arteriotomies [1, 10]. Thromboembolectomy by Fogarty is the gold standard for urgent treatment of such acute arterial occlusion [2]. But nowadays, endovascular therapy has opened the door for the percutaneous treatment with tremendous advancement

Treatment of acute abdominal aortic occlusion

[3, 5, 11-13], especially to be preferential for patients with AD, thrombosed AAA, posttraumatic abdominal aortic occlusion and chronic distal aortic occlusion. This study retrospectively reviewed a set of patients with acute abdominal aortic occlusion who were treated in our center to share our experience in the management of this disease.

Methods

Ethics

This was a retrospective case series. The study protocol was approved by the ethics committee of the Second Affiliated Hospital of Nantong University, Suzhou, China. All patients provided written informed consent for the procedure and follow-up.

Patients

All patients with acute abdominal aortic occlusion from January 2011 to January 2015 were enrolled in this study. The diagnosis of acute abdominal aortic occlusion was established based on symptoms and signs, and further confirmed by computed tomography angiography (CTA). Lesion site, length, etiology and inflow and distal outflow vessels were also evaluated by CTA. Echocardiogram was also performed to help to identify the etiology. Data included demographic data, clinical manifestations, surgical records, laboratory test results were reviewed. Status of patency of the abdominal artery, bilateral iliac arteries and femoral arteries assessed via CTA and/or ultrasonography during the follow-up period were also included.

Managements

Once diagnosis was made, an intravenous bolus of low molecular weight heparin (LMWH) (4000 U) was immediately injected to prevent thrombosis in the distal lower extremity arteries. Preoperative assessment was performed as promptly as possible. Surgery was performed under general anesthesia. Surgical methods should be made according to etiology. For the acute occlusion caused by embolism in abdominal or aortoiliac artery, thromboembolectomy by Fogarty arterial catheters via bilateral common femoral arteriotomies was performed. Briefly, bilateral longitudinal inguinal incisions were made in the patients under

anesthesia to expose to the bilateral femoral, deep femoral, superficial femoral artery, and femoral vein. A 5F or 6F Fogarty embolectomy catheter was used at the proximal end and a 4F or 3F was used at the distal superficial femoral and deep femoral artery until no emboli was removed. Then about 200 ml blood was bled respectively from bilateral femoral veins as soon as blood flow was restored. Generally, thromboembolectomy could be completed easily but for embolism caused by atrial myxoma. This embolism, which actually was a large plasticine-shaped tumor tissue, was not able to be removed by a Fogarty catheter. Instead, cutting with guide wire was performed to divide the embolus into small pieces. Briefly, a 0.018 metal guidewire was inserted from one side of femoral artery and pushed out through the contralateral femoral artery. Then cutting was performed by pulling the two terminals of the metal guidewire. Finally, thromboembolectomy by Fogarty arterial catheters was performed as the former methods. A dose of 200,000 U urokinase was injected into the arterial cavity immediately after the embolectomy. For acute occlusion caused by AAD, emergency endovascular repair should be performed to seal the rupture and restore the true lumen. If patients complicated with thrombosis in the true lumen, thromboembolectomy with Fogarty arterial catheters was performed after the stent implantation. For acute occlusion caused by mural thrombus in AAA, thromboembolectomy was performed firstly. Then covered stent was placed to repair the AAA and to compress the mural thrombi on the vessel wall.

Postoperative management

Continuous renal replacement therapy (CRRT) was prepared for the patients with a long duration of ischemia in the lower extremities. Once the diagnosis of acute renal dysfunction or renal failure was made based on a serum creatinine level of 1.5 mg/dL (132.6 μ mol/L) or higher, CRRT was implemented promptly.

All the patients were given LMWH (4000 U) twice daily for a week. Patients complicated with atrial fibrillation were given oral warfarin for anticoagulation. Patients with aortic dissection and aortic aneurysm and performed with stent implantation were treated with aspirin for at least six months.

Treatment of acute abdominal aortic occlusion

Table 1. Characteristics of patients and lesions

No.	Age (Years)	Gender	Clinical symptoms	Duration (hours)	Etiology	Managements	Outcome	Complication
1	50	Male	Sensorimotor loss and cold in BLE	40	Nephrotic syndrome	Embolectomy through double FAs	Death	Hyperkalemia
2	53	Male	Pain and cold in BLE	21	Atrial myxoma	Cutting with guide wire to divide embolus into small pieces. Then embolectomy via double FAs	Well	Renal failure
3	63	Male	Pain in the lower back, cold and paralysis in BLE	6	Aortic artery dissection	Endovascular aortic repair	Well	None
4	57	Male	Abdominal pain, pain and cold in BLE	12	Atrial fibrillation, rheumatic heart disease	Embolectomy through double FAs	Well	Cerebral infarction
5	74	Male	Cold and paralysis in BLE	10	Mural thrombosis in AAA	Embolectomy through double FAs + Endovascular aortic aneurysm repair	Well	None
6	48	Male	Pain in the lower back, cold and paralysis in BLE	8	Aortic artery dissection	Endovascular aortic repair	Well	None
7	52	Male	Pain and cold in BLE	18	Atrial fibrillation	Embolectomy through double FAs + incision decompression in legs	Well	Compartment syndrome
8	69	Male	Cold and paralysis in BLE	9	Mural thrombosis in AAA	Embolectomy through double FAs + Endovascular aortic aneurysm repair	Well	Intermittent claudication in hip
9	73	Male	Pain and cold in BLE	7	Atrial fibrillation	Embolectomy through double FAs	Well	None
10	55	Male	Pain in the chest and back, cold and paralysis in BLE	12	Aortic artery dissection	Endovascular aortic repair	Well	None
11	65	Female	Pain, cold and paralysis in BLE	10	Atrial fibrillation	Embolectomy through double FAs	Well	None
12	46	Female	Pain and cold in BLE	8	Atrial fibrillation	Embolectomy through double FAs	Well	None

AAA: AAA; FAs: femoral arteries; BLE: both lower extremities.

Treatment of acute abdominal aortic occlusion

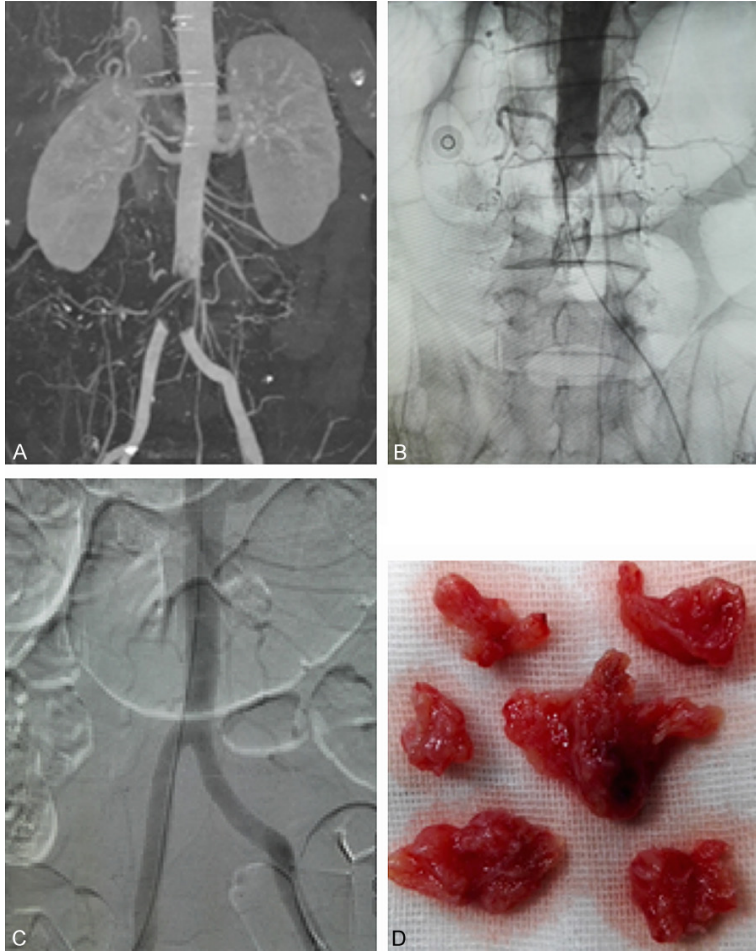


Figure 1. Management of acute abdominal aortic occlusion caused by atrial myxoma. Diagnosis was made via compute tomography angiography (A) and arteriography (B). This embolism, which actually was a large plasticine-shaped tumor tissue, was not able to be removed by a Fogarty catheter. Instead, cutting with guide wire was performed to divide the embolus into small pieces. Then thromboembolotomy by Fogarty arterial catheters was performed. The blood flow of obstructive artery was restored (C). The emboli were identified as neoplasm tissue from atrial myxoma (D).

atrial fibrillation. Two patients complicated with atrial myxoma. Six patients accompanied with hypertension, three patients caused by aortic dissection, two patients caused by mural thrombosis from an abdominal aortic aneurysm (**Table 1**).

Nine patients underwent embolotomy through double femoral arteries. Of which, emboli from one patients was large plasticine-shaped tissue which was verified as abdominal aortic atrial myxoma embolization by pathologic examination. It was not able to remove by Fogarty catheter. Cutting with guidewire was performed first to divide the embolus into small pieces. And then the cataclastic emboli were removed by catheter embolotomy (**Figure 1**). There were three patients with AAD (DeBakey type III) who were performed emergency endovascular aortic repair. The blood supply of the lower limbs was restored immediately after the true lumen was restored (**Figure 2**). Two patients caused by AAA mural thrombus. Thromboembolotomy was performed firstly. Then covered stent was placed to repair the AAA.

Results

Characteristics of patients

Twelve consecutive patients with acute abdominal aortic occlusion were involved in the present study, including 10 males and two females, aged 46-74 years (median age: 58.8 years). All the patients suffered an abrupt onset and severe lower limb ischemia with symptoms including severe pain in the lower limbs, no pulse, pale, cold, piebald, and cyanosis. Neurologic dysfunction, which revealed a loss of motor function and a sensory deficit to pin prick, occurred in eight patients. Preoperative duration of symptoms was in the interval from six to 40 hours. Five cases complicated with

Complications

Limb compartment syndrome and necrosis: One patient suffered with limb compartment syndrome in the left limb. Decompression via leg incision was performed to prevent myonecrosis. Finally, this patient underwent a slight foot drop. No one suffered ulcer and necrosis. No amputations occurred. Skin temperature in the lower limbs of all patients returned to normal after the surgery. Artery pulse of the dorsalis pedis or posterior tibial arterial recovered. ABI of all patients were normal at 24 hours after the intervention.

Visceral bleeding: There were two patients who suffered gastrointestinal bleeding and intesti-

Treatment of acute abdominal aortic occlusion

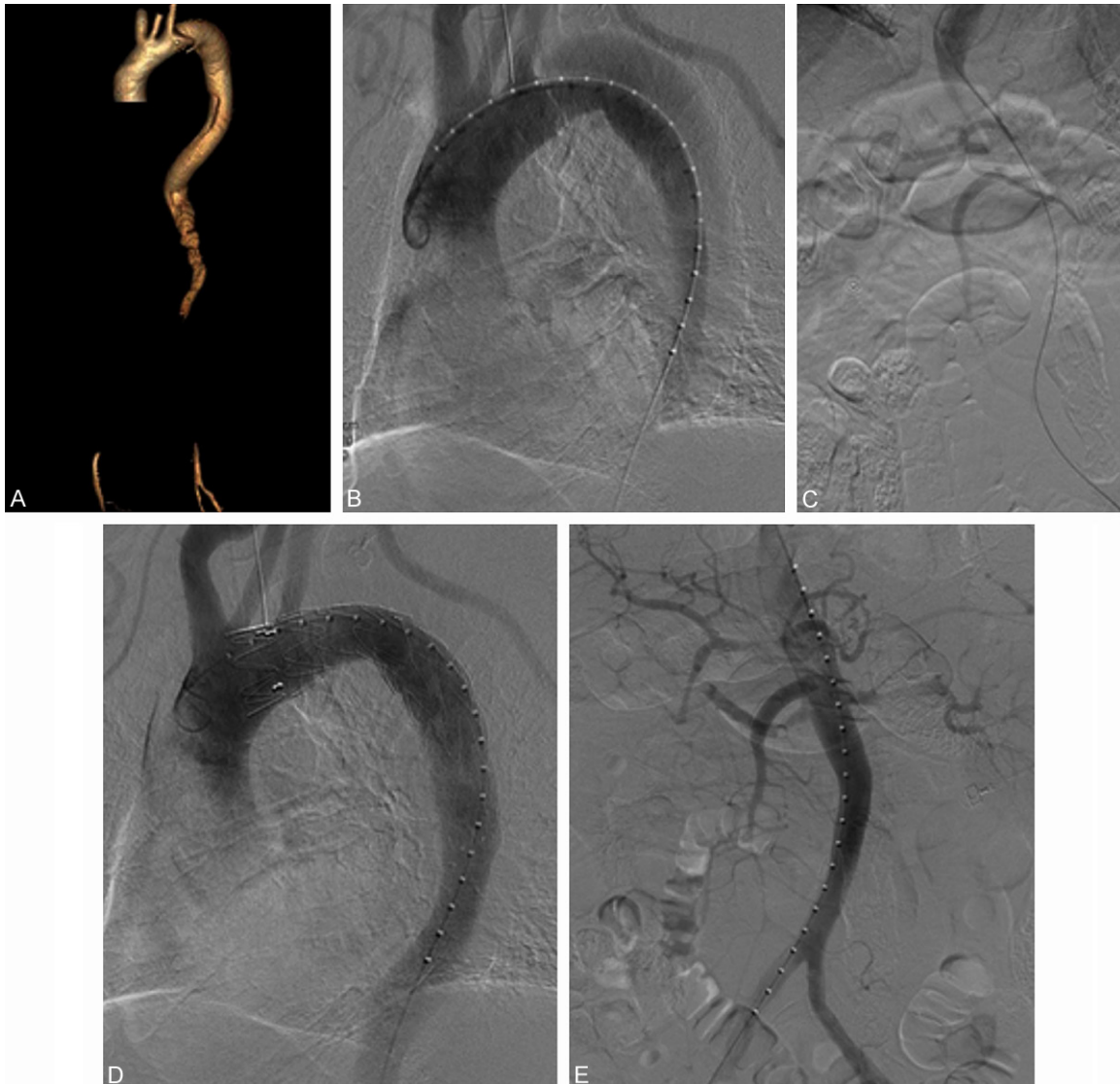

Figure 2. Management of acute abdominal aortic occlusion caused by aortic artery dissection (Debakey III). Diagnosis was made via compute tomography angiography (A) and confirmed by arteriography (B, C). Emergent endovascular aortic repair was performed (D), and then the blood flow of obstructive artery was restored (E).

nal perforation respectively. Both of them were treated with fasting, nutritional support, omeprazole and hemostatics. And both of them recovered.

Renal dysfunction: Eight patients suffered acute renal dysfunction. Laboratory results found that creatinine, urea nitrogen and plasma potassium were higher. All of them except one were subjected to CRRT and got a well recovery. After CCRT, creatinine and plasma potassium returned to normal. There was one patient who died soon after the embolectomy because of hyperkalemia cardiac arrest.

Follow up

A total of 11 patients were followed up for 1 to 4 years. ABI of all patients were normal. All the patients were performed CTA and/or ultrasonography at six months and once a year later. All the patients had no restenosis or reobstruction in abdominal artery, bilateral iliac arteries and femoral arteries.

Discussion

It is difficult to get a correct and prompt diagnosis of acute abdominal aortic occlusion owing

Treatment of acute abdominal aortic occlusion

to variable symptoms and rare clinical picture. In some patients, neurologic symptoms other than ischemic symptoms are the predominant symptoms. The progressing neurological symptoms, caused by acute loss of blood perfusion, may confuse the diagnosis with brain or spinal cord infarction [14, 15]. Delayed diagnosis could result in a longer ischemic time and further a higher mortality. In the present study, there was one patient with a delayed diagnosis because of the predominant neurologic symptoms. He was misdiagnosed as Guillain-Barre syndrome at first, which led the ischemic duration to endure about 40 hours. He died as soon as embolectomy was performed because of the hyperkalemia and renal failure. Thus this alerted us that paraplegia symptoms such as sudden paralysis of lower limbs but accompanied with the absence of double-femoral pulse strongly indicated the diagnosis of this disease. CTA should be performed in all the suspected patients timely. Once the diagnosis was made, emergent surgery should be implemented.

The management of acute abdominal aortic occlusion varies depending on its etiology. For acute occlusion caused by embolism or thrombosis, emergent embolectomy via bilateral common femoral arteries using Fogarty arterial balloon catheter may be the optimal choice. But for some special emboli, for instance emboli from atrial myxoma, it may be unworkable for embolectomy simply using a Fogarty catheter. Actually, atrial myxoma is a benign tumor, which rarely caused abdominal aortic occlusion [16, 17]. But this type of emboli, just like a large plasticine-shaped tissue, could be cut into small pieces by metal guide wire. Then the emboli were able to be removed using a Fogarty catheter. In the present study, embolism in one patient came from atrial myxoma. It was unable to remove the emboli through Fogarty catheter at first. Cutting using metal guide wire was performed. And then, the emboli were removed completely via Fogarty catheter.

Concerning the pathophysiological mechanisms and risk of late rupture when complicated with AAA, thromboembolectomy and extra-anatomical bypass were not selected as the first choice of treatment [6]. It has been demonstrated that stenting of the aorta and iliac arteries has a good primary and secondary

patency rates which is comparable to surgical bypass [18, 19]. Covered stent, placed to repair the AAA, also plays an important role in preventing mural thrombi detaching new embolism.

AAD can result in aortic occlusion when the unruptured false lumen expanded enough to compress the true lumen completely [4, 20-22]. It has been reported that ischemia of the lower limbs was observed in 9.7% preoperative AAD patients [23]. It is worth mentioning that, in these patients, lower limb ischemia is less likely to present with chest and back pain, which makes it difficult to be diagnosed. Kristofer M et al [24] proposed that lower limb ischemia could be used as a surrogate marker for more extensive and severe dissection because the mortality was as three times as higher than those without it. Peripheral revascularization should be carried out prior to the proximal aortic repair, because it would cause an acute renal failure or myocardial infarction if there is not a timely and effective intervention. Branch artery stenting and extra-anatomic bypass may be reliable techniques for achieving this goal. Arteriotomy of femoral artery plus embolectomy was performed promptly.

Acquired kidney injury (AKI) is a common but potentially mortal complication of the surgical procedure. It is also known as myonephropathic metabolic syndrome (MNMS) [25], which is closely related to postoperative mortality and morbidity [26, 27]. It has been known that CRRT, initiated emergently for patients with life-threatening changes in fluid, electrolyte and acid-base balance, can significantly reduce the mortality rate [28]. Besides, early RRT, compared with delayed initiation of RRT, reduced the mortality over the first 90 days [29]. Thus timely CRRT could protect renal function and reduce the postoperative mortality. In this study, seven patients with a long duration of ischemia underwent CRRT. Renal failure was reversed in all of them. But there was one patient who suffered cardiac arrest because of hyperkalemia immediately after the artery restoration. Thus, this reminded us that intraoperative CRRT may be necessary for patients with a long duration of ischemia.

Long ischemic duration can cause striated muscle dissolution, myoglobin, acidic metabo-

lites and potassium releasing into blood. This may cause ischemia and reperfusion. Thus, according to our experience, it is beneficial that 200 ml of blood was bled from bilateral femoral veins as soon as the artery restoration. This will contribute to reduce the toxin, especially prevent hyperkalemia as soon as restore the blood flow. Besides, intravenous infusion of high glucose, insulin, and sodium bicarbonate should be given through intravenous way to promote the transfer of potassium ions into cells.

In conclusion, acute abdominal aortic occlusion is a critical disease with various symptoms and etiologies. The mortality and morbidity can be markedly reduced by timely diagnosis and proper management. Besides, CRRT can protect renal function and reduce the postoperative mortality.

Acknowledgements

This work was supported by grants from the Jiangsu Provincial Science and Technology office (No. BL2014043). Youth project of Suzhou Medicine Exploration (KJXW2017016).

Disclosure of conflict of interest

None.

Address correspondence to: Xiao-Qiang Li, Department of Vascular Surgery, The Second Affiliated Hospital of Soochow University, No. 1055 Sanxiang Road, Suzhou 215000, Jiangsu, China. Tel: +86-512-67784869; E-mail: vasculars@126.com; fly-tsg@126.com

References

- [1] Frost S, Jordan RC. Acute abdominal aortic occlusion. *J Emerg Med* 1992; 10: 139-145.
- [2] Toriumi S, Ikemoto T, Waki H, Nagai M, Eguchi K, Shimpo M, Katsuki T, Kurumisawa S, Aizawa K, Misawa Y, Kario K. Life- and limb-saving endovascular therapy in a patient with acute abdominal aortic occlusion. *Cardiovasc Interv Ther* 2017; 32: 190-195.
- [3] Terai Y, Mitsuoka H, Nakai M, Goto S, Miyano Y, Tsuchiya H, Yamazaki F. Endovascular aneurysm repair of acute occlusion of abdominal aortic aneurysm with intra-aneurysmal dissection. *Ann Vasc Surg* 2015; 29: 1658. e1611-1654.
- [4] Garrett HE Jr, Wolf BA. Management of acute infrarenal aortic occlusion secondary to type a dissection. *Ann Thorac Surg* 2006; 81: 1500-1502.
- [5] Idoguchi K, Yamaguchi M, Okada T, Nomura Y, Sugimura K, Okita Y, Sugimoto K. Endovascular treatment of blunt traumatic abdominal aortic occlusion with kissing stent placement. *Cardiovasc Intervent Radiol* 2012; 35: 1216-1220.
- [6] Hirose H, Takagi M, Hashiyada H, Miyagawa N, Yamada T, Tada S, Kugimiya T. Acute occlusion of an abdominal aortic aneurysm—case report and review of the literature. *Angiology* 2000; 51: 515-523.
- [7] Nakajima M, Tsuchiya K, Akashi O, Morimoto H, Kato K. Thoracoabdominal aortic aneurysm associated with abdominal aortic and visceral arterial occlusion in a hemodialysis patient. *Ann Thorac Surg* 2007; 83: 2216-2219.
- [8] Drager SB, Riles TS, Imparato AM. Management of acute aortic occlusion. *Am J Surg* 1979; 138: 293-295.
- [9] Eugster T, Obeid T, Gurke L, Wolff T, Stierli P. Acute supramesenteric thrombosis of an abdominal aortic aneurysm with deleterious embolism: a case report. *Ann Vasc Surg* 2005; 19: 411-413.
- [10] Busuttill RW, Keehn G, Milliken J, Paredero VM, Baker JD, Machleder HI, Moore WS, Barker WF. Aortic saddle embolus. A twenty-year experience. *Ann Surg* 1983; 197: 698-706.
- [11] Nadahama T, Kawarada O, Shibata K, Harada K, Noguchi T, Minatoya K, Ogawa H, Yasuda S. Stenting for juxtarenal abdominal aortic occlusion. *JACC Cardiovasc Interv* 2016; 9: 856-858.
- [12] Alkhouli M, Shafi I, Patil P, Bashir R. Percutaneous treatment of chronic distal aortic occlusion: a viable option. *JACC Cardiovasc Interv* 2014; 7: e185-186.
- [13] Mujtaba M, Chhabra L, Abdalbaki AM, Sadiq I. Balloon angioplasty with secondary stenting for chronically occluded abdominal aorta in a high-risk patient. *BMJ Case Rep* 2014; 2014.
- [14] Wong SS, Roche-Nagle G, Oreopoulos G. Acute thrombosis of an abdominal aortic aneurysm presenting as cauda equina syndrome. *J Vasc Surg* 2013; 57: 218-220.
- [15] Zingler VC, Strupp M, Bruning R, Lauterjung L, Waggershausen T, Bruckmann H, Brandt T. Recurrent exertion-induced spinal cord ischemia due to infrarenal aortic occlusion. *J Neurol* 2003; 250: 998-1000.
- [16] Kao CL, Chang JP. Abdominal aortic occlusion: a rare complication of cardiac myxoma. *Tex Heart Inst J* 2001; 28: 324-325.
- [17] Horn KD, Becich MJ, Rhee RY, Pham SM. Left atrial myxoma with embolization presenting as an acute infrarenal aortic occlusion. *J Vasc Surg* 1997; 26: 341-345.

Treatment of acute abdominal aortic occlusion

- [18] Stirling MJ, Miller MJ, Smith TP, McCann RL. Subintimal stent graft reconstruction of an infrarenal aortic occlusion. *Semin Intervent Radiol* 2007; 24: 10-14.
- [19] Murphy TP, Ariaratnam NS, Carney WI Jr, Marcaccio EJ, Slaiby JM, Soares GM, Kim HM. Aortoiliac insufficiency: long-term experience with stent placement for treatment. *Radiology* 2004; 231: 243-249.
- [20] Yamamoto H, Yamamoto F, Izumoto H, Shiroto K, Tanaka F, Yamaura G, Motokawa M, Ishibashi K. Acute aortic occlusion due to false-lumen expansion after repair of abdominal aortic rupture in type B acute aortic dissection. *Ann Vasc Surg* 2010; 24: 951. e951-956.
- [21] Chung JW, Elkins C, Sakai T, Kato N, Vestring T, Semba CP, Slonim SM, Dake MD. True-lumen collapse in aortic dissection: part I. Evaluation of causative factors in phantoms with pulsatile flow. *Radiology* 2000; 214: 87-98.
- [22] Tsai TT, Evangelista A, Nienaber CA, Myrmel T, Meinhardt G, Cooper JV, Smith DE, Suzuki T, Fattori R, Llovet A, Froehlich J, Hutchison S, Distant A, Sundt T, Beckman J, Januzzi JL Jr, Isselbacher EM, Eagle KA; International Registry of Acute Aortic Dissection. Partial thrombosis of the false lumen in patients with acute type B aortic dissection. *N Engl J Med* 2007; 357: 349-359.
- [23] Trimarchi S, Nienaber CA, Rampoldi V, Myrmel T, Suzuki T, Mehta RH, Bossone E, Cooper JV, Smith DE, Menicanti L, Frigiola A, Oh JK, Deeb MG, Isselbacher EM, Eagle KA; International Registry of Acute Aortic Dissection Investigators. Contemporary results of surgery in acute type a aortic dissection: the international registry of acute aortic dissection experience. *J Thorac Cardiovasc Surg* 2005; 129: 112-122.
- [24] Henke PK, Williams DM, Upchurch GR Jr, Proctor M, Cooper JV, Fang J, Nienaber CA, Isselbacher EM, Fattori R, Dasika N, Gemmete J, Stanley JC, Wakefield TW, Eagle KA. Acute limb ischemia associated with type B aortic dissection: clinical relevance and therapy. *Surgery* 2006; 140: 532-539, discussion 539-540.
- [25] Haimovici H. Muscular, renal, and metabolic complications of acute arterial occlusions: myoneuropathic-metabolic syndrome. *Surgery* 1979; 85: 461-468.
- [26] Tallgren M, Niemi T, Poyhia R, Raininko E, Railo M, Salmenpera M, Lepantalo M, Hynninen M. Acute renal injury and dysfunction following elective abdominal aortic surgery. *Eur J Vasc Endovasc Surg* 2007; 33: 550-555.
- [27] Adali F, Gonul Y, Aldemir M, Hazman O, Ahsen A, Bozkurt MF, Sen OG, Keles I, Keles H. Investigation of the effect of crocin pretreatment on renal injury induced by infrarenal aortic occlusion. *J Surg Res* 2016; 203: 145-153.
- [28] Khwaja A. KDIGO clinical practice guidelines for acute kidney injury. *Nephron Clin Pract* 2012; 120: c179-c184.
- [29] Zarbock A, Kellum JA, Schmidt C, Van Aken H, Wempe C, Pavenstadt H, Boanta A, Gerss J, Meersch M. Effect of early vs delayed initiation of renal replacement therapy on mortality in critically ill patients with acute kidney injury: the elain randomized clinical trial. *JAMA* 2016; 315: 2190-2199.