

Case Report

Apatinib for treatment of HGF in advanced lung adenocarcinoma harboring EGFR activating mutation: a case report and review of literature

Jie Zhang^{1*}, Ting-Ting Gu^{1*}, Xiao-Xiao Li¹, Cai-Hua Wang², Da-Xiong Zeng¹, Chang-Guo Wang¹, Jian-An Huang¹, Jun-Hong Jiang¹

¹Department of Respiratory Medicine, The First Affiliated Hospital of Soochow University, Suzhou, China;

²Department of Critical Care Medicine, The Affiliated Jiangning Hospital of Nanjing Medical University, Nanjing, China. *Equal contributors.

Received May 27, 2018; Accepted August 4, 2018; Epub January 15, 2019; Published January 30, 2019

Abstract: Hepatocyte growth factor (HGF) is a complex, multi-domain protein related to the blood proteinase precursor plasminogen, known to be detected in 29% of tumors with intrinsic resistance in EGFR mutant lung cancer. However, the proportion of HGF in primary resistance of lung adenocarcinoma is not clear. We describe the case of a 54-year-old non-smoking man who was diagnosed lung adenocarcinoma via pathology test. The lymph nodes of his right neck, submandibular, left axillary, and mediastinal were metastasized. Next generation sequencing of the patient showed L858R in 21 exon and overexpression of HGF. Apatinib is a salvage treatment for patients after failure in response to chemotherapy and icotinib. Therefore, apatinib might be an optional choice for advanced lung adenocarcinoma patients with HGF overexpression as a post second-line treatment.

Keywords: Apatinib, HGF, primary resistance, lung adenocarcinoma, L858R

Introduction

Lung cancer is one of the leading causes of cancer-related death in the worldwide [1]. About 30% of patients with EGFR-activating mutations show intrinsic resistance to EGFR-TKIs [2]. Several mechanisms of primary resistance to EGFR-TKIs have been described, such as exon 20 insertion, KRAS mutations, Anaplastic Lymphoma Kinase (ALK) rearrangements, threonine-methionine substitution at position 790 (T790M), mesenchymal-epithelial transition factor (Met) amplification, overexpression of hepatocyte growth factor (HGF), HER2 gene mutations, ROS1 rearrangements, etc. [3-7].

Angiogenesis plays an important role in tumor growth, development and metastasis [8]. Vascular endothelial growth factor (VEGF) signaling promotes angiogenesis via activation of VEGF receptor (VEGFR). Apatinib is an oral small molecule inhibitor of VEGFR-2 tyrosine kinase, which has been applied to metastatic breast or gastric cancer. Apatinib has gradually become the focus of targeted therapy for advanced lung

adenocarcinoma in recent years. Here, we report a case of apatinib treat intrinsic EGFR-TKI resistance induced by overexpression of HGF.

Case report

In December 10, 2016, a 54-year-old non-smoking male patient was admitted to the First Affiliated Hospital of Soochow University, due to "a chest radiograph indicated that there was a space occupying lesion at the low lobe of left lung for more than a year". Positron emission tomography-computed tomography (PET-CT) showed the mass sized 27×20 mm. He was diagnosed lung adenocarcinoma via pathology, with lymph nodes of right neck, submandibular, left axillary, and mediastinal showing metastasis (**Figure 2**). Gene detection of biopsy tissue showed L858R in 21 exon. The treatment process of the patient is shown in **Figure 1**.

Discussion

The patient was initially diagnosed with left lung adenocarcinoma via pathology examina-

Apatinib, hepatocyte growth factor, lung adenocarcinoma, primary resistance

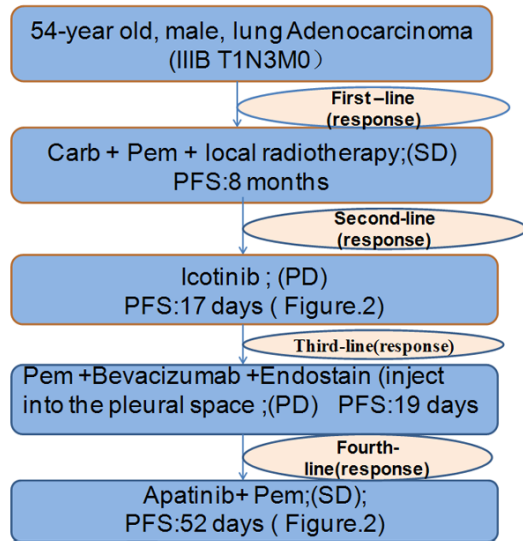


Figure 1. The treatment process of the patient.

tion. Platinum-based doublets chemotherapy was recommended as the first-line therapy. Systemic chemotherapy and local radiotherapy were given, but disease progression (PD) was observed after 8 months. According to the result of gene detection, icotinib was chosen as the second-line therapy. Evaluation after application of icotinib for 17 days was PD (**Figure 2A, 2B** before Icotinib treatment, **Figure 2C, 2D** after icotinib treatment). Next-generation sequencing from the pleural effusion showed HGF over-expression and L858R in 21 exon (**Figure 3A-C**). As far as we know, this is the first case of over-expression of HGF that describes the original resistance mechanism for icotinib.

EGFR-TKIs have become the first-line treatment of patients with EGFR mutations. However, about 30% of patients with EGFR-activating mutations show intrinsic resistance to EGFR-TKIs. The mechanism of primary drug resistance is not yet clear. At present, exon 20 insertion, KRAS mutations, ALK rearrangements, threonine-methionine substitution at position 790 (T790M), mesenchymal-epithelial transition factor (Met) amplification, overexpression of hepatocyte growth factor (HGF), HER2 gene mutations, and ROS1 rearrangements are known. Yano S concluded that high-level HGF was detected in 29% of 45 lung cancer with intrinsic resistance [7]. HGF, a ligand of MET [9], induces EGFR-TKI resistance by activating MET, which restores phosphorylation of downstream MAPK-ERK1/2 and PI3K-Akt pathways,

using Gab1 as an adaptor [10-13]. In view of the primary drug resistance caused by HGF amplification, the current clinical experiments mainly target the transduction of HGF/c-MET signaling pathway. Anti-HGF antibody, c-MET receptor kinase inhibitors, anti-c-MET antibody, the natural HGF inhibitor NK4 are included [14-17]. Wu reported that Norcantharidin combined with EGFR-TKIs overcomes HGF-induced resistance to EGFR-TKIs in EGFR mutant lung cancer cells via inhibition of Met/PI3K/Akt pathway [17]. Nevertheless, the results were not optimistic. There is an urgent need for an effective treatment to reverse the primary EGFR-TKIs resistance.

Angiogenesis plays an important role in tumor growth, development and metastasis. Vascular endothelial growth factor (VEGF) signaling promotes angiogenesis via activation of VEGF receptor (VEGFR). In recent years, anti-angiogenic therapy has gradually become a hotspot in the field of lung cancer treatment, including targeted therapy for VEGF or VEGFR. Bevacizumab, the antibody against VEGF, combined with chemotherapy can significantly improve prognosis of lung adenocarcinoma. It has been recommended as the first-line therapy for lung adenocarcinoma until disease progression in NCCN Guidelines [18]. Pemetrexed (500 mg/m², day 1) combined with bevacizumab (300 mg, day 1) as third-line treatment. At the same time, endostatin was injected into the pleural cavity. It is strange that performance status (ps) of the patient was increased to 4 after 1 cycle. Chest CT indicated that pulmonary nodules were smaller than before, and bilateral pleural effusion was less than before, but pericardial effusion was more than before. The left axillary lymph nodes were enlarged. Evaluation of efficacy was PD. There was little evidence for antiangiogenic gene modulation, therefore drug monotherapy is used as post second-line therapy in advanced lung adenocarcinoma, especially for complex mutations of L858R in 21 exon and HGF overexpression. Currently, we know that the anti-tumor mechanism of apatinib involves selective targets such as VEGFR-2, which binds all VEGF-A isoforms, as well as VEGF-C, and VEGF-D. The binding of VEGF-A to VEGFR-2 can induce a cascade of signaling pathways, eventually causing cell migration and proliferation, thus blocking new blood vessel formation in tumor tissue [19-21].

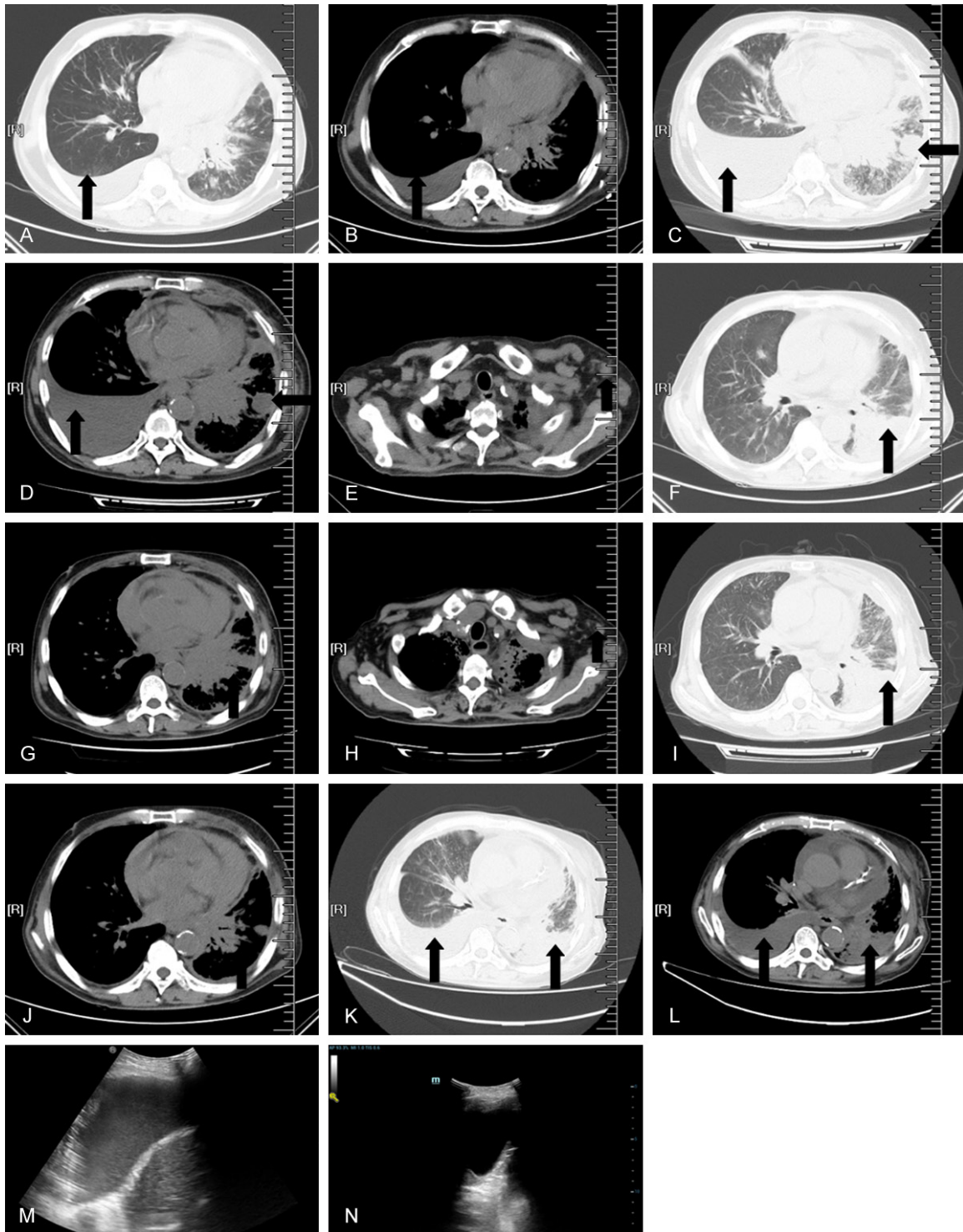

Figure 2. Chest computed tomography (CT). A, B. The chest CT scan reveals pleural effusion of the right mediastinal window before icotinib treatment on August 24, 2016; C, D. CT showed that bilateral pleural effusions was significantly progressed more than before and pulmonary nodules were similar to previous readings after icotinib treatment for 17 days on September 10, 2016; E-L. Shows the left axillary lymph nodes, pericardial effusion, pleural effusion and pulmonary nodules. E-G. Chest CT indicated that pulmonary nodules, bilateral pleural effusion, the left axillary lymph node and pleural effusion before apatinib treatment on September 27, 2016; H-J. CT shows that the left axillary lymph node was smaller than before, pericardial effusion was less than before, but pleural effusion and pulmonary nodules were stable after apatinib treatment for 4 days on October 7, 2016; K, L. Apatinib treatment for 52 days (November 25, 2016), the pleural effusion of the right appeared again and the pleural effusion of the left increased more than before (October 7, 2016). The patient PFS has increased to 52 days after taking apatinib. M.

Apatinib, hepatocyte growth factor, lung adenocarcinoma, primary resistance

Before apatinib treatment on September 10, 2016; N. After apatinib treatment for 44 days (November 17, 2016) the patient's chest ultrasound showed a significant reduction of pleural effusion.

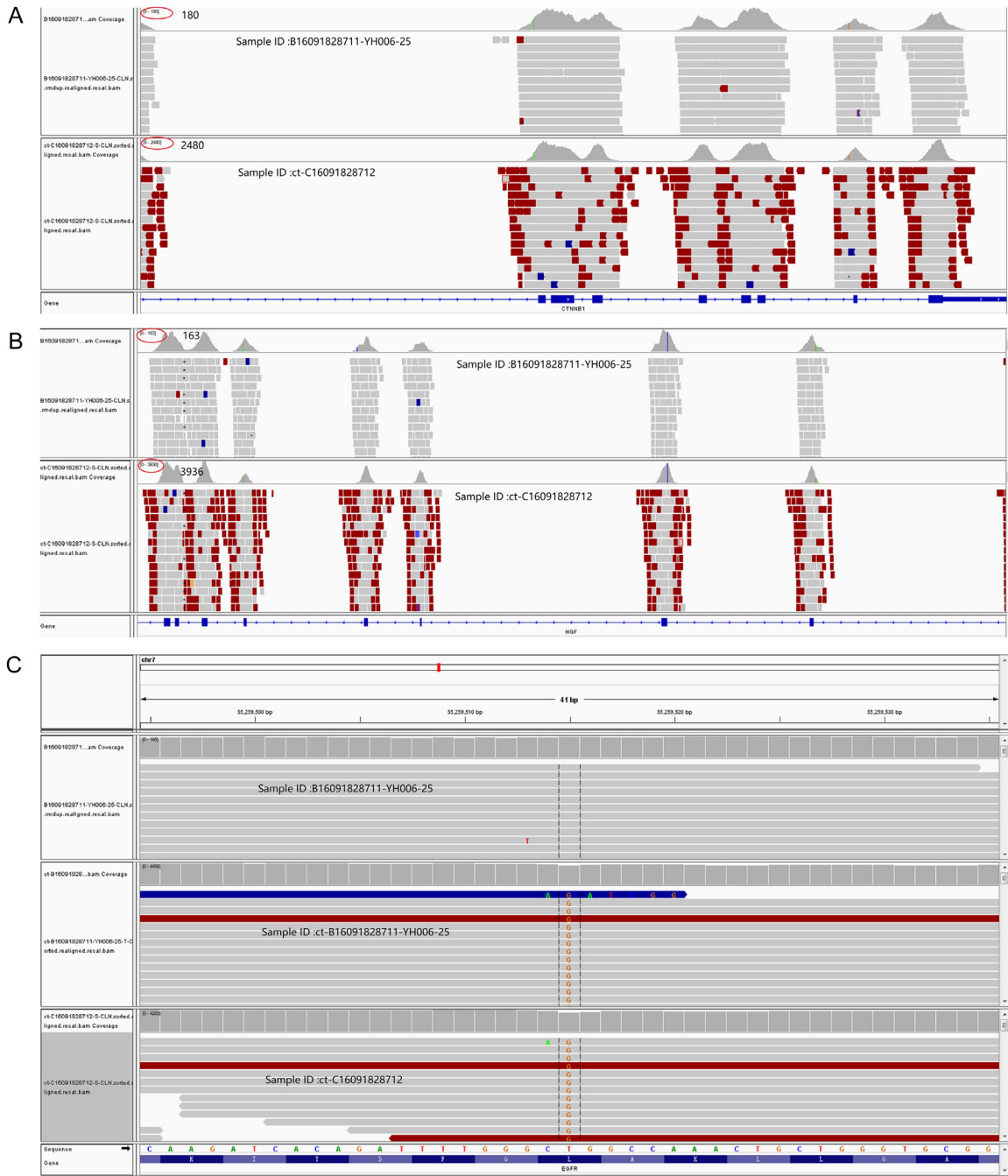


Figure 3. Next-generation sequencing of the patient. A. The screenshot of IGV about CTNNB1 (reference gene). B. The screenshot of IGV about HGF (HGF overexpression about 1.9 times in pleural effusion). C. The result of EGFR mutation. B16091828711-YH006-25 (peripheral blood); ct-B16091828711-YH006-25 (plasma); ct-C16091828712 (pleural effusion).

Endostatin and bevacizumab also can inhibit tumor angiogenesis, but they cannot control the patient's pleural effusion. However, in

Figure 2M, 2N, the patient's chest ultrasound shows a significant reduction of pleural effusion in comparison to an earlier reading.

Therefore, apatinib might have other mechanisms of anti-tumor growth, such as reducing pleural effusion by dropping the permeability of pulmonary capillary. Unfortunately, there is a lack of more detailed experimental evidence.

Additionally, there are several different points in our report. First, as far as we know, this is the first case of the over-expression of HGF that describes the original resistance mechanism for icotinib. Second, it is the first case that we report of apatinib in the treatment of primary resistance to EGFR-TKIs. This is significantly different from previous studies which apatinib is used in adenocarcinoma with acquired resistance or without EGFR mutation and ALK-negative [20, 22, 23]. Our report might provide some information for a potential choice in primary EGFR-TKIs resistance with activating mutations, which is caused by overexpression of HGF. Third, the dosage of apatinib in our report is 250 mg/d. The recommended dose of apatinib in different tumors is not uniform. In phase II trial, the dosing regimen of 850 mg once daily is recommended for the treatment of gastric cancer [24]. In a phase II trial, the dosing regimen of 500 mg once daily was recommended for treatment of metastatic breast cancer [25]. The side effects are also obvious, with the main side effects being hypertension, proteinuria, and hand-foot syndrome. The dosage of apatinib in lung cancer is not clear. How to choose the suitable dose of apatinib in lung cancer to reduce the side effects is still in the exploratory stage. Doses of 850 or 500 mg once daily of apatinib has been reported. However, hand-foot skin reaction and hypertension appeared [22, 26]. In our case, 250 mg once daily of apatinib was combined with chemotherapy as a salvage treatment. Zeng reported that the recommended dose of apatinib was 250 mg daily, adverse affects were significantly decreased but the PFS was similar to that of the high-dose regimen in previous studies. The median PFS was 4.5 months, 5.5 months, 1.5 months (one of the patient was PD) [27]. Therefore, 250 mg once daily was used for the patient in this study. After for 4 days treatment with apatinib, the left axillary lymph nodes were smaller than before and pericardial effusion was much less than before. Pleural effusion changes from bloody to clear and PS of the case improve from 4 to 1 (**Figure 2E-J**). Thereafter, the patient's chest ultra-

sound showed a significant reduction of pleural effusion in comparison to earlier reading (**Figure 2M, 2N**). However, endostatin and bevacizumab could not control the patient's pleural effusion and hydropericardium, thus apatinib may reduce pleural effusion by dropping the permeability of pulmonary capillary, which may indicate that apatinib may target different pathways in its anti-tumor activity. Regrettably, increasing the dose of apatinib (1000 mg/qd) led a grade 1 hypertensive but the blood pressure returned to normal after reduction of apatinib. In the case, the patient's PFS had increased to 52 days after taking apatinib. These might given an optional choice for salvage therapy in primary resistance patients. However, there remain a lack of large-scale random controlled clinical trials on apatinib in adenocarcinoma, especially in HGF overexpression lung adenocarcinoma.

Conclusion

This case provides some inspiration that apatinib can be used for treatment of primary resistance to EGFR-TKIs. However, more experiments and clinical cases are needed to explain the mechanism of apatinib in treatment in advanced lung adenocarcinoma, as well as the efficiency in other primary resistance and the most suitable dosage.

Acknowledgements

This study was supported by the Jiangsu Province Special Program of Medical Science (number BE2016672).

The authors thank the Geneseeq Technology Inc for their gene sequencing.

Disclosure of conflict of interest

None.

Address correspondence to: Jun-Hong Jiang, Department of Respiratory Medicine, The First Affiliated Hospital of Soochow University, Suzhou, China. E-mail: jiang20001969@163.com

References

- [1] Chen W, Zheng R, Baade PD, Zhang S, Zeng H, Bray F, Jemal A, Yu XQ, He J. Cancer statistics in China, 2015. *CA Cancer J Clin* 2016; 66: 115-32.

Apatinib, hepatocyte growth factor, lung adenocarcinoma, primary resistance

- [2] Mitsudomi T, Yatabe Y. Mutations of the epidermal growth factor receptor gene and related genes as determinants of epidermal growth factor receptor tyrosine kinase inhibitors sensitivity in lung cancer. *Cancer Sci* 2007; 98: 1817-24.
- [3] Bell DW, Gore I, Okimoto RA, Godin-Heymann N, Sordella R, Mulloy R, Sharma SV, Brannigan BW, Mohapatra G, Settleman J, Haber DA. Inherited susceptibility to lung cancer may be associated with the T790M drug resistance mutation in EGFR. *Nat Genet* 2005; 37: 1315-6.
- [4] Jänne PA, Meyerson M. Meyerson, ROS1 rearrangements in lung cancer: a new genomic subset of lung adenocarcinoma. *J Clin Oncol* 2012; 30: 878-9.
- [5] Liu H, Wang M, Hu K, Xu Y, Ma M, Zhong W, Zhao J, Li L, Wang H. [Research progress of the resistance mechanism of non-small cell lung cancer to EGFR-TKIs]. *Zhongguo Fei Ai Za Zhi* 2013; 16: 535-40.
- [6] Wang SE, Narasanna A, Perez-Torres M, Xiang B, Wu FY, Yang S, Carpenter G, Gazdar AF, Muthuswamy SK, Arteaga CL. HER2 kinase domain mutation results in constitutive phosphorylation and activation of HER2 and EGFR and resistance to EGFR tyrosine kinase inhibitors. *Cancer Cell* 2006; 10: 25-38.
- [7] Yano S, Yamada T, Takeuchi S, Tachibana K, Minami Y, Yatabe Y, Mitsudomi T, Tanaka H, Kimura T, Kudoh S, Nokihara H, Ohe Y, Yokota J, Uramoto H, Yasumoto K, Kiura K, Higashiyama M, Oda M, Saito H, Yoshida J, Kondoh K, Noguchi M. Hepatocyte growth factor expression in EGFR mutant lung cancer with intrinsic and acquired resistance to tyrosine kinase inhibitors in a Japanese cohort. *J Thorac Oncol* 2011; 6: 2011-7.
- [8] Hicklin DJ and Ellis LM. Role of the vascular endothelial growth factor pathway in tumor growth and angiogenesis. *J Clin Oncol* 2005; 23: 1011-27.
- [9] Naldini L, Vigna E, Narsimhan RP, Gaudino G, Zarnegar R, Michalopoulos GK, Comoglio PM. Hepatocyte growth factor (HGF) stimulates the tyrosine kinase activity of the receptor encoded by the proto-oncogene c-MET. *Oncogene* 1991; 6: 501-4.
- [10] Kanaji N, Yokohira M, Nakano-Narusawa Y, Watanabe N, Imaida K, Kadowaki N, Bando S. Hepatocyte growth factor produced in lung fibroblasts enhances non-small cell lung cancer cell survival and tumor progression. *Respir Res* 2017; 18: 118.
- [11] Turke AB, Zejnullahu K, Wu YL, Song Y, Dias-Santagata D, Lifshits E, Toschi L, Rogers A, Mok T, Sequist L, Lindeman NI, Murphy C, Akhavanfard S, Yeap BY, Xiao Y, Capelletti M, Iafrate AJ, Lee C, Christensen JG, Engelman JA, Jänne PA. Preexistence and clonal selection of MET amplification in EGFR mutant NSCLC. *Cancer Cell* 2010; 17: 77-88.
- [12] Yamada T, Takeuchi S, Kita K, Bando H, Nakamura T, Matsumoto K, Yano S. Hepatocyte growth factor induces resistance to anti-epidermal growth factor receptor antibody in lung cancer. *J Thorac Oncol* 2012; 7: 272-80.
- [13] Yano S, Wang W, Li Q, Matsumoto K, Sakurama H, Nakamura T, Ogino H, Kakiuchi S, Hanibuchi M, Nishioka Y, Uehara H, Mitsudomi T, Yatabe Y, Nakamura T, Sone S. Hepatocyte growth factor induces gefitinib resistance of lung adenocarcinoma with epidermal growth factor receptor-activating mutations. *Cancer Res* 2008; 68: 9479-87.
- [14] Jiang T, Zhou C. [Research progress of hgf/c-met inhibitor in the treatment of non-small cell lung cancer]. *Zhongguo Fei Ai Za Zhi* 2015; 18: 240-4.
- [15] Okamoto W, Okamoto I, Tanaka K, Hatashita E, Yamada Y, Kuwata K, Yamaguchi H, Arai T, Nishio K, Fukuoka M, Jänne PA, Nakagawa K. TAK-701, a humanized monoclonal antibody to hepatocyte growth factor, reverses gefitinib resistance induced by tumor-derived HGF in non-small cell lung cancer with an EGFR mutation. *Mol Cancer Ther* 2010; 9: 2785-92.
- [16] Wang W, Li Q, Yamada T, Matsumoto K, Matsumoto I, Oda M, Watanabe G, Kayano Y, Nishioka Y, Sone S, Yano S. Crosstalk of stromal fibroblasts induces resistance of lung cancer to epidermal growth factor receptor tyrosine kinase inhibitors. *Clin Cancer Res* 2009; 15: 6630-8.
- [17] Wu H, Fan F, Liu Z, Shen C, Wang A, Lu Y. Norecantharidin combined with EGFR-TKIs overcomes HGF-induced resistance to EGFR-TKIs in EGFR mutant lung cancer cells via inhibition of Met/PI3k/Akt pathway. *Cancer Chemother Pharmacol* 2015; 76: 307-15.
- [18] Ettinger DS, Wood DE, Akerley W, Bazhenova LA, Borghaei H, Camidge DR, Cheney RT, Chirieac LR, D'Amico TA, Dilling TJ, Dobelbower MC, Govindan R, Hennon M, Horn L, Jahan TM, Komaki R, Lackner RP, Lanuti M, Lilienbaum R, Lin J, Loo BW Jr, Martins R, Otterson GA, Patel JD, Pisters KM, Reckamp K, Riely GJ, Schild SE, Shapiro TA, Sharma N, Stevenson J, Swanson SJ, Tauer K, Yang SC, Gregory K, Hughes M. NCCN guidelines insights: non-small cell lung cancer, version 4.2016. *J Natl Compr Canc Netw* 2016; 14: 255-64.
- [19] Ding J, Chen X, Gao Z, Dai X, Li L, Xie C, Jiang H, Zhang L, Zhong D. Metabolism and pharmacokinetics of novel selective vascular endothelial growth factor receptor-2 inhibitor apatinib in humans. *Drug Metab Dispos* 2013; 41: 1195-210.
- [20] Song Z, Yu X, Lou G, Shi X, Zhang Y. Salvage treatment with apatinib for advanced non-

Apatinib, hepatocyte growth factor, lung adenocarcinoma, primary resistance

- small-cell lung cancer. *Onco Targets Ther* 2017; 10: 1821-1825.
- [21] Tian S, Quan H, Xie C, Guo H, Lü F, Xu Y, Li J, Lou L. YN968D1 is a novel and selective inhibitor of vascular endothelial growth factor receptor-2 tyrosine kinase with potent activity in vitro and in vivo. *Cancer Sci* 2011; 102: 1374-80.
- [22] Ding L, Li QJ, You KY, Jiang ZM, Yao HR. The use of apatinib in treating nonsmall-cell lung cancer: case report and review of literature. *Medicine (Baltimore)* 2016; 95: e3598.
- [23] Li F, Zhu T, Cao B, Wang J, Liang L. Apatinib enhances antitumour activity of EGFR-TKIs in non-small cell lung cancer with EGFR-TKI resistance. *Eur J Cancer* 2017; 84: 184-192.
- [24] Li J, Qin S, Xu J, Guo W, Xiong J, Bai Y, Sun G, Yang Y, Wang L, Xu N, Cheng Y, Wang Z, Zheng L, Tao M, Zhu X, Ji D, Liu X, Yu H. Apatinib for chemotherapy-refractory advanced metastatic gastric cancer: results from a randomized, placebo-controlled, parallel-arm, phase II trial. *J Clin Oncol* 2013; 31: 3219-25.
- [25] Hu X, Zhang J, Xu B, Jiang Z, Ragaz J, Tong Z, Zhang Q, Wang X, Feng J, Pang D, Fan M, Li J, Wang B, Wang Z, Zhang Q, Sun S, Liao C. Multicenter phase II study of apatinib, a novel VEGFR inhibitor in heavily pretreated patients with metastatic triple-negative breast cancer. *Int J Cancer* 2014; 135: 1961-9.
- [26] Fang SC, Zhang HT, Zhang YM, Xie WP. Apatinib as post second-line therapy in EGFR wild-type and ALK-negative advanced lung adenocarcinoma. *Onco Targets Ther* 2017; 10: 447-452.
- [27] Zeng DX, Wang CG, Huang JA, Jiang JH. Apatinib in the treatment of advanced lung adenocarcinoma with KRAS mutation. *Onco Targets Ther* 2017; 10: 4269-4272.