

Case Report

Cryptococcal rib osteomyelitis mimicking a metastatic tumor: a case report and literature review

Nian Dong*, Shanshan Su*, Yupeng Xie

Department of Respiratory and Critical Care Medicine, The First Affiliated Hospital of Wenzhou Medical University, Wenzhou, Zhejiang, P.R. China. *Equal contributors.

Received May 30, 2019; Accepted August 11, 2019; Epub October 15, 2019; Published October 30, 2019

Abstract: Cryptococcal osteomyelitis is clinically rare, and only a few cases of cryptococcal rib osteomyelitis have been reported to date. The atypical manifestation of cryptococcal osteomyelitis might lead to clinical misdiagnosis. A rare case from a 61-year-old woman with recurrent cough and chest pain is presented here. The chest CT revealed a lytic lesion in the left posterior ninth rib with surrounding soft tissue masses mimicking a metastatic tumor. The CT-guided biopsy confirmed the definite diagnosis of cryptococcal rib osteomyelitis, and lumbar puncture as well as ¹⁸F-FDG PET/CT excluded the involvement of the central nervous system or respiratory system. Treatment with fluconazole improved the osteolytic rib. In the context of review of the relevant literature, cryptococcal osteomyelitis should be considered in the differential diagnosis of osteolytic lesions, and the cryptococcal polysaccharide antigen assay, histopathology, and tissue culture should be adopted when necessary.

Keywords: Biopsy, cryptococcal osteomyelitis, *Cryptococcus neoformans*, fluconazole, immunosuppression, ribs

Introduction

Cryptococcosis is an invasive opportunistic infection with the encapsulated spherical fungus *Cryptococcus neoformans*. Cryptococcosis primarily involves the respiratory and central nervous system, while involvement of the skeletal system is relatively unusual and only reported in 5-10% cases of multi-organ disseminated cryptococcosis [1]. Our review of the English literature on skeletal cryptococcosis has revealed that the vertebral column is the most common bone site for disease, whereas the rib is much more infrequent. Here we present a rare case of isolated cryptococcal rib osteomyelitis in a kidney transplant recipient that manifested as chest pain mimicking metastatic cancer. A systematic review of the relevant literature was conducted to highlight the clinicopathological characteristics.

Case presentation

A 61-year-old woman was an out-patient of The First Affiliated Hospital of Wenzhou Medical University, with a three-month history of recur-

rent cough and a one-month history of ingravescient left-side chest pain. Three months beforehand, a chest computed tomography (CT) in the local hospital illustrated scattered pulmonary nodules in the left lower lobe and right middle lobe (**Figure 1A, 1B**). However, later the chest computed tomography (CT) of the patient illustrated a 12 mm*16 mm pulmonary nodule in the left lower lobe and osteolytic destruction of the left posterior ninth rib with surrounding soft tissue masses (**Figure 1C, 1D**). The patient was thus hospitalized under the suspicion of pulmonary malignancy with bone metastasis. The medical history revealed kidney transplantation due to uraemia eight years prior, for which the patient was on an immunosuppressive regimen including mycophenolate, methylprednisolone, and tacrolimus. The patient denied possible exposure to birds, especially pigeons.

Upon admission, the patient was afebrile with vital signs within the normal range. Physical examination of the left posterior chest revealed a 4×4 cm soft tissue mass with intact overlying skin. Laboratory investigations revealed a white blood cell count of 12.15×10^9 with 68% neutro-

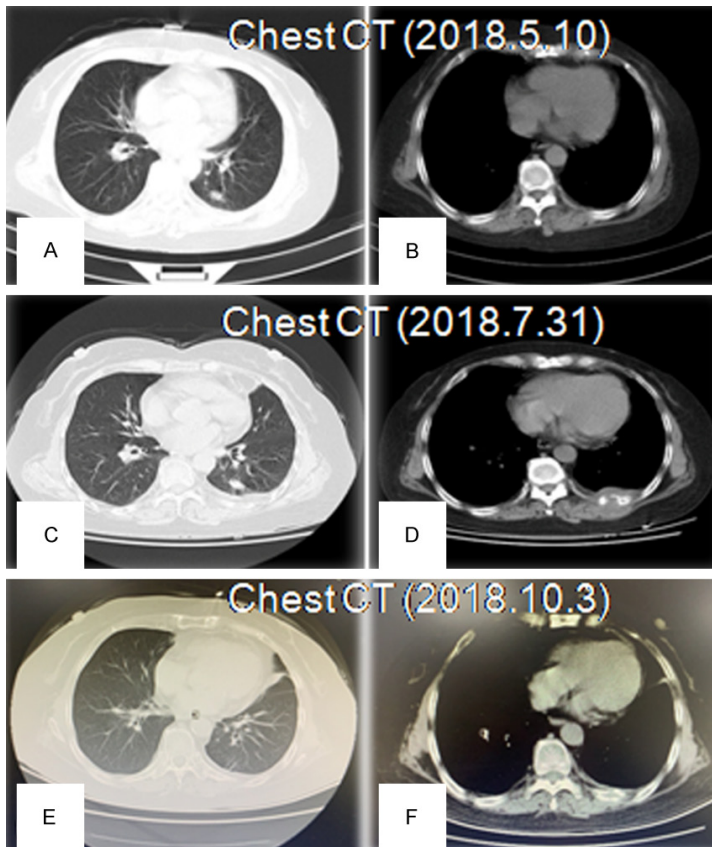


Figure 1. Chest CT illustrated scattered pulmonary nodules in the left lower lobe and right middle lobe (A, B). Chest CT illustrated a 12 mm*16 mm pulmonary nodule in the left lower lobe and osteolytic destruction of the left posterior 9th rib with surrounding soft tissue masses (C, D). Chest CT illustrated a partial decrease of the pulmonary nodule in the left lower lobe and restricted erosion of the left posterior ninth rib (E, F).

phils and 20% lymphocytes and a cell-mediated immunity (including NK, CD4, CD8, and CD4/CD8) within normal ranges. The C-reactive protein was 34.3 mg/L and procalcitonin 0.031 ng/ml. The qualitative assay of serum cryptococcal polysaccharide antigen (CrAg) was positive, while the galactomannan, 1,3, β -D-glucan antigen, and T cell enzyme-linked immune-spot assay were negative. A chest CT with contrast, revealed a pulmonary nodule in the left lower lung lobe and osteolytic destruction of the left posterior ninth rib (Figure 2A, 2B), as suggestive of pulmonary malignancy with bone metastasis. No bronchial abnormality was observed with bronchoscopy (Figure 2C-E). Furthermore, single-photon emission-computed tomography (SPECT) illustrated excessive uptake of Tc99m in the posterior aspect of the left ninth rib (Figure 2L). Clinically, malignancy as well as infection was considered in the differential diagno-

sis. The patient was started on intravenous cefoperazone and sulbactam (2 g every 8 h).

Based on the medical history (immunosuppression status), physical examination (soft tissue mass), laboratory investigation (serum cryptococcus capsular antigen), and imaging examination (osteolysis of the left ninth rib), CT-guided biopsy of the soft tissue mass (Figure 2F, 2G) was conducted and the lesion was confirmed as cryptococcosis by periodic acid-Schiff and Gomori's methenamine-silver staining (Figure 2H-J). Moreover, the culture of biopsied specimen yielded *Cryptococcus neoformans*. Further lumbar puncture demonstrated that the cerebrospinal fluid was negative for cryptococcal antigen. Given the status of kidney transplantation and side effects of amphotericin B and flucytosine on renal function, fluconazole was adopted instead. In fact, intravenous fluconazole (0.4 g every day) was started along with cefoperazone and sulbactam when the outcome of the serum cryptococcal antigen assay was positive. To evaluate the therapeutic effect and exclu-

de the localizations of the infection, ^{18}F -Fluorodeoxyglucose positron emission tomography/CT (^{18}F -FDG PET/CT) was employed two weeks after the anti-infective therapy. ^{18}F -FDG PET/CT illustrated partial improvement of the pulmonary nodule in the left lower lobe, restricted erosion of the left posterior ninth rib, and soft tissue mass with an SUVmax of 10.8, suggestive of improvement (Figure 2K). A diagnosis of cryptococcal osteomyelitis of the left posterior ninth rib was made and therapeutic regimen was changed to oral fluconazole (0.4 g every day) at discharge.

On follow-up visits, the chest pain was gradually resolved while the serum CrAg still remains positive. A chest CT two months after discharge was implicative of continuous regression of the bone lesion (Figure 1E, 1F). Currently, the patient is undergoing antifungal therapy and is under follow-up treatment.

Cryptococcal osteomyelitis

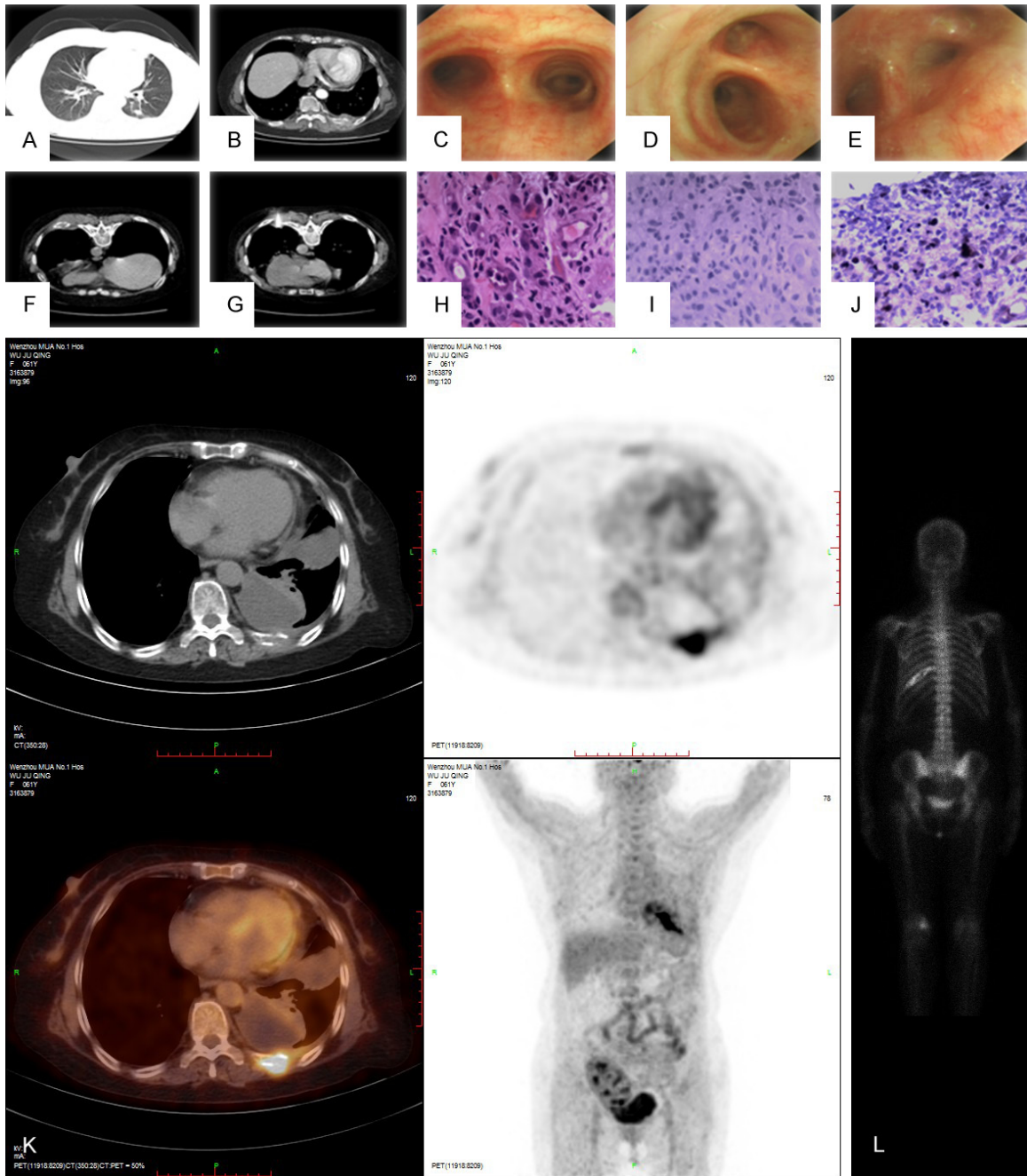


Figure 2. Chest CT with contrast illustrated a 12 mm*16 mm pulmonary nodule in the left lower lobe and osteolytic destruction of the left posterior ninth rib with surrounding soft tissue masses (A, B). Bronchoscopic examination illustrated no obvious abnormality of the bronchial lumen (C-E). The CT-guided biopsy of the soft tissue mass around the left ninth posterior rib (F, G). H&E staining illustrated chronic inflammation and fibrotic hyperplasia with scattered neutrophil infiltration (H). Periodic acid-Schiff stain and Gomori's methenamine-silver staining indicated *Cryptococcus neoformans* as an evident dark brown spherical structure (I, J). Single photon emission-computed tomography illustrated elevated uptake of ^{99m}Tc in the left posterior ninth rib (L). ¹⁸F-Fluorodeoxyglucose positron emission tomography/CT examination illustrated up-regulated ¹⁸F-FDG concentration in the left ninth posterior rib with osteolytic lesion (K).

Discussion

Cryptococcosis is an opportunistic mycosis with significant morbidity and mortality in im-

munocompromised hosts and brings about enormous social economic burden. With the increasing number of immunocompromised hosts worldwide due to transplantation, malig-

Cryptococcal osteomyelitis

Table 1. Review of cryptococcal rib osteomyelitis

Manifestation	Immunity	Involved sites	Therapy	Ref
Chest pain	Cryptogenic cirrhosis	Left 5th rib	Liposomal amphotericin B/Fluconazole	[9]
Swelling and pain over manubrium and chest wall	Immunocompetent	Mandible, manubrium, and left 3rd rib	Fluconazole	[10]
Mass related to the left 10th rib	Idiopathic CD4 lymphopenia	Left 10th rib, vertebral spondylitis, and pleural empyema	Voriconazole/Fluconazole	[11]
Fever, swelling and pain in the left scapula	Immunocompetent	Scapula and rib	Amphotericin B deoxycholate/Flucytosine/Fluconazole	[12]
Atraumatic right side rib pain	Non-Hodgkin's lymphoma	Right 8th rib, L3 vertebral body, and meningitis	Liposomal amphotericin B/Fluconazole	[13]
Pain in right hip	Immunocompetent	Right femur and right 7th rib	Surgical resection and hemiarthroplasty/Fluconazole	[14]
Chest pain	Immunocompetent	Left 6th rib	Surgical excision/fluconazole	[15]
Pain and swelling on the chest	Immunocompetent	Left 1st rib	Antifungal therapy	[16]
Chest pain	Immunocompetent	Right 11th rib	Itraconazole/Fluconazole	[17]
Dyspnoea, fever, and left pleuritic pain	Immunocompetent	Thoracic empyema and left 9th rib	Surgical resection/Fluconazole	[18]

nancies, and steroid therapy, it is urgent to alert clinicians of the high incidence of cryptococcosis in immunocompromised hosts [2]. The clinical manifestation of cryptococcosis depends on the involved system and varies to a certain extent. Pulmonary inhalation is the initial route through which *Cryptococcus neoformans* enters the body and localizes to the respiratory system, and the subsequent hematogenous spread leads to the disseminated cryptococcal disease [3]. In comparison with the involvement of the respiratory and central nervous system, cryptococcal osteomyelitis is a quite rare manifestation of disseminated cryptococcal disease [4]. Given the rarity of cryptococcal osteomyelitis in clinic, its diagnosis is inevitably delayed. Here, a rare case of cryptococcal rib osteomyelitis is presented to strengthen the understanding of potential extra-pulmonary manifestations of the disease.

The characteristics of the present case are summarized as follows. First, as a kidney transplant recipient, the patient was on an immunosuppressive regimen with a high risk of cryptococcosis. It is reported that *Cryptococcus neoformans* ranks as the third causative pathogen of fungal infection in solid organ transplant recipients [5]. Second, physical examination and imaging upon admission were suggestive of the diagnosis of pulmonary malignancy with bone metastasis. The positive result of serum CrAg implied the possibility of cryptococcosis; however, only the subsequent periodic acid-Schiff stain and Gomori's methenamine-silver staining and tissue culture lead to the definite diagnosis. Although serum CrAg is a highly specific and sensitive indicator for cryptococcosis, it must be noted that serum cryptococcal antigen is negative for up to 35% of immunocompetent hosts with cryptococcosis [6]. Thus histopathologic examination as well as cell culture of biopsy is important, as we have demonstrated previously [7]. Third, considering the neurotropic nature of *Cryptococcus neoformans*, lumbar puncture was conducted to exclude the involvement of the central nervous system. Furthermore, ^{18}F -FDG PET/CT was performed to confirm the isolated cryptococcal osteomyelitis of the left posterior ninth rib with an SUVmax of 10.8. Consistent with the case report of pulmonary cryptococcosis and cryptococcal osteomyelitis mimicking primary and metastatic lung cancer with an SUVmax of

16.4, using ^{18}F -FDG PET/CT [8] the manifestation of cryptococcosis is considered to highly resemble malignancy. Nevertheless, the pathophysiological mechanisms underlying cryptococcal rib osteomyelitis are unclear and thus the optimal duration of antifungal therapy has also not yet been established.

To better understand the diverse clinical manifestations of cryptococcal rib osteomyelitis, a systematic review of the relevant case reports published in PUBMED was performed with the key words "cryptococcus", "cryptococcal", "cryptococcosis", "osteomyelitis", and "rib". The relevant case reports with full texts available since 2000 have been described (Table 1).

With this systematic review of the relevant literature, it is clear that cryptococcal osteomyelitis should be considered during the differential diagnosis of osteolytic lesions. Isolated cryptococcal rib osteomyelitis augments the diverse manifestation of cryptococcosis. Additionally, the CrAg assay is a sensitive method for screening potential candidates, whereas histopathology and tissue culture enable definite diagnosis.

Acknowledgements

We acknowledge CSC from the Department of Respiratory and Critical Care Medicine, The First Affiliated Hospital of Wenzhou Medical University, for the revision of the manuscript.

Disclosure of conflict of interest

None.

Address correspondence to: Dr. Yupeng Xie, Department of Respiratory and Critical Care Medicine, The First Affiliated Hospital of Wenzhou Medical University, 2 Fuxue Road, Wenzhou 325000, Zhejiang, P.R. China. E-mail: xieyp2002@126.com

References

- [1] Qadir I, Ali F, Malik UZ and Umer M. Isolated cryptococcal osteomyelitis in an immunocompetent patient. *J Infect Dev Ctries* 2011; 5: 669-673.
- [2] Perfect JR, Dismukes WE, Dromer F, Goldman DL, Graybill JR, Hamill RJ, Harrison TS, Larsen RA, Lortholary O, Nguyen MH, Pappas PG, Powderly WG, Singh N, Sobel JD and Sorrell TC. Clinical practice guidelines for the manage-

Cryptococcal osteomyelitis

- ment of cryptococcal disease: 2010 update by the infectious diseases society of america. *Clin Infect Dis* 2010; 50: 291-322.
- [3] Chang CC, Sorrell TC and Chen SC. Pulmonary Cryptococcosis. *Semin Respir Crit Care Med* 2015; 36: 681-691.
- [4] Zhou HX, Lu L, Chu T, Wang T, Cao D, Li F, Ning G and Feng S. Skeletal cryptococcosis from 1977 to 2013. *Front Microbiol* 2014; 5: 740.
- [5] Henao-Martinez AF and Beckham JD. Cryptococcosis in solid organ transplant recipients. *Curr Opin Infect Dis* 2015; 28: 300-307.
- [6] Kiertiburanakul S, Wirojtananugoon S, Prachartam R and Sungkanuparph S. Cryptococcosis in human immunodeficiency virus-negative patients. *Int J Infect Dis* 2006; 10: 72-78.
- [7] Zhou Y, Lin PC, Ye JR, Su SS, Dong L, Wu Q, Xu HY, Xie YP and Li YP. The performance of serum cryptococcal capsular polysaccharide antigen test, histopathology and culture of the lung tissue for diagnosis of pulmonary cryptococcosis in patients without HIV infection. *Infect Drug Resist* 2018; 11: 2483-2490.
- [8] Wang J, Ju HZ and Yang MF. Pulmonary cryptococcosis and cryptococcal osteomyelitis mimicking primary and metastatic lung cancer in (18)F-FDG PET/CT. *Int J Infect Dis* 2014; 18: 101-103.
- [9] Harris RM, Stillman IE, Goldsmith JD, Qian Q and Kirby JE. Pathological rib fracture and soft tissue mass simulating malignancy—Cryptococcus, an unsuspected culprit. *Diagn Microbiol Infect Dis* 2015; 81: 189-191.
- [10] DiNardo AR, Schmidt D, Mitchell A, Kaufman Y and Tweardy DJ. First description of oral *Cryptococcus neoformans* causing osteomyelitis of the mandible, manubrium and third rib with associated soft tissue abscesses in an immunocompetent host. *Clin Microbiol Case Rep* 2015; 1.
- [11] Legarth RA, Christensen M, Calum H, Katzenstein TL and Helweg-Larsen J. Cryptococcal rib osteomyelitis as primary and only symptom of idiopathic CD4 penia. *Med Mycol Case Rep* 2014; 4: 16-18.
- [12] Zhang Y, Yu YS, Tang ZH and Zang GQ. Cryptococcal osteomyelitis of the scapula and rib in an immunocompetent patient. *Med Mycol* 2012; 50: 751-755.
- [13] To CA, Hsieh RW, McClellan JS, Howard W, Fischbein NJ, Brown JM, Felsher DW and Fan AC. Cryptococcal osteomyelitis and meningitis in a patient with non-hodgkin's lymphoma treated with PEP-C. *BMJ Case Rep* 2012; 2012.
- [14] Jou HJ, Lee FT, Wang MN, Yang PY and Wang NP. Bifocal cryptococcal osteomyelitis: management of a patient with concurrent femur and rib infections. *Hip Int* 2011; 21: 495-497.
- [15] Sethi S. Cryptococcal osteomyelitis in the ribs. *J Glob Infect Dis* 2010; 2: 63-64.
- [16] Kaur G, Manucha V and Verma K. Cryptococcal osteomyelitis of the rib diagnosed on fine needle aspiration cytology. *Acta Cytol* 2010; 54: 1056-1057.
- [17] Murphy SN and Parnell N. Fluconazole treatment of cryptococcal rib osteomyelitis in an HIV-negative man. A case report and review of the literature. *J Infect* 2005; 51: e309-311.
- [18] Chang WC, Tzao C, Hsu HH, Chang H, Lo CP and Chen CY. Isolated cryptococcal thoracic empyema with osteomyelitis of the rib in an immunocompetent host. *J Infect* 2005; 51: e117-119.