

Case Report

Extracorporeal membrane oxygenation: an efficient approach to treat acute respiratory distress syndrome after inhalation of zinc chloride from smoke bomb: a case report

Zhe Zhao^{1,2,3,4}, Xiaoyang Hong^{2,3,4}, Haoyuan Ren^{2,3,4}, Change Liu^{2,3,4}, Zhichun Feng^{1,2,3,4}

¹The Second School of Clinical Medicine, Southern Medical University, Guangzhou, Guangdong, China; ²PICU, Affiliated Bayi Children's Hospital, PLA Army General Hospital, Beijing, China; ³National Engineering Laboratory for Birth Defects Prevention and Control of Key Technology, Beijing, China; ⁴Beijing Key Laboratory of Pediatric Organ Failure, Beijing, China

Received February 28, 2018; Accepted October 26, 2018; Epub February 15, 2019; Published February 28, 2019

Abstract: Acute respiratory distress syndrome (ARDS) induced by inhalation of zinc chloride remains refractory to common treatment. No standard protocols exist for treating it due to its rare occurrence. This case report discusses three soldiers who were exposed to a smoke bomb in an enclosed space for nearly 3 minutes. As no protective equipment was used, the soldiers rapidly developed ARDS and were subsequently complicated by pneumothorax and pneumomediastinum. A combination of comprehensive therapies was used for initial treatment, which included a protective lung ventilation strategy, bilateral tube thoracotomy, prone position ventilation, corticoids, etc. As adequate oxygenation could not be achieved, we decided to initiate extracorporeal membrane oxygenation (ECMO) for them. Oxygenation showed gradual improvement in their health conditions. Arterial blood gas analysis revealed increased PO₂ and decreased PCO₂, indicating an improvement in the ventilatory and gas exchange functions. ECMO support was provided for 17 and 21 days respectively, where two patients achieved satisfactory oxygenation and ECMO was discontinued. Both survived were discharged from the hospital after approximately 70 days. The other patient, whose condition was more severe, died of pneumorrhagia on day 3 of post-accident despite receiving the same treatment approach as the surviving patients. These case studies indicate that ECMO may be a successful treatment option for patients with severe ARDS experiencing similar disease process/progression.

Keywords: Extracorporeal membrane oxygenation, acute respiratory distress syndrome, zinc chloride, smoke bomb, inhalation

Introduction

The white or grey smoke released from a smoke bomb has a variety of uses in both military as well as civilian contexts. The most common components of this smoke include zinc oxide and a chloride donor such as calcium chloride and hexachloroethane, allowing for the formation of fine particles of zinc chloride (ZnCl₂) [1]. Inhalation of smoke containing zinc chloride chemicals in confined spaces produces pathological changes in the lungs [2]. Several reports have been published from approximately over half a century on the detailed examination of the injuries caused by inhalation of chemical gases [3, 4]. Almost all the victims have died

because of lack of standard treatment. The most recent case reported by Mahboob et al. [5] demonstrated successful treatment using long periods of high dose steroids and lung protective ventilation.

Herein, three young soldiers who developed ARDS after zinc chloride inhalation in the mainland China were examined using extracorporeal membrane oxygenation (ECMO). Two of the three soldiers survived and were discharged from the hospital by implementing the same treatment approach. All procedures performed in this report involving human participants were in accordance with the ethical standards of the institutional and/or national research commit-

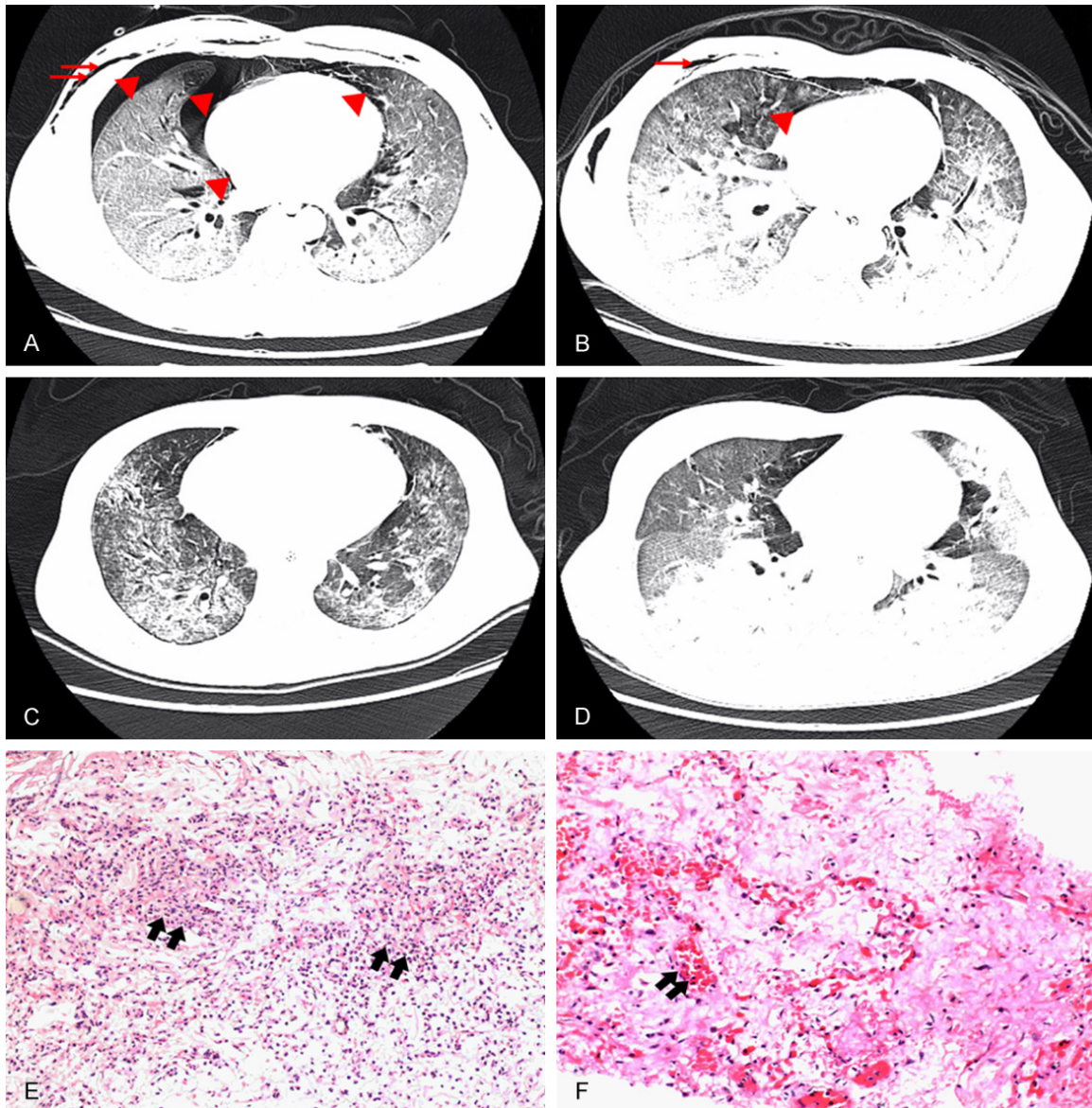


Figure 1. (A-D) CT scan results of case 1 and case 2 before (A, B) and after (C, D) ECMO. The triangles indicate pneumothorax and the arrow indicate subcutaneous emphysema. (E, F) The pathological findings of lung tissues from case 3 revealed acute lung injury and inflammation and fibrosis; (E) The interstitial spaces were filled with neutrophils, revealing severe interstitial inflammation; (F) The intraalveolar spaces were filled with red blood cells and white blood cells, indicating pulmonary alveolitis.

tee and with the 1964 Helsinki declaration and its later amendments or comparable ethical standards. Informed consent was obtained from all individual participants included in this report.

Case report

Case 1

A 22-year-old soldier was exposed to $ZnCl_2$ gas from a smoke grenade in a tunnel trench for

approximately 3 minutes without protection in March, 2016. On day three in ICU, the CT scan showed a progressive deterioration with increasing consolidations and pneumothorax (**Figure 1A**). He felt chest distress and dyspnea occasionally and his arterial blood gases (ABG) showed pH of 7.47, PCO_2 of 47, and PO_2 of 100 on 80% oxygen (**Figure 2A**).

On day 5 in ICU, a chest tube was inserted to provide closed drainage of the pleural cavity. Mechanical ventilation and bronchoscopy were

ECMO: an efficient approach to treat ARDS

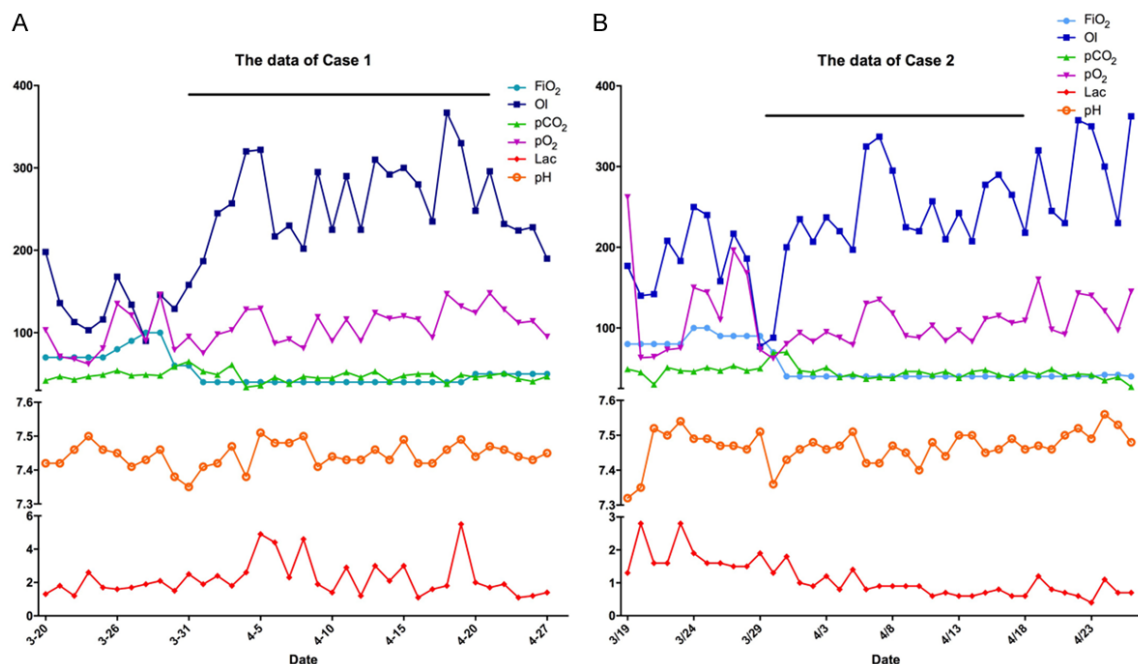


Figure 2. The alteration of pH, pO_2 , pCO_2 , Oxygenation Index (OI) and lactate (Lac) for 38 days of case 1 (A) and case 2 (B) during the ICU stay. The duration of administration of ECMO was shown at the top.

performed on day 7 in ICU. Although the patient was placed in the prone position ventilation (PPV) for 12-16 hr/d, the oxygenation and $TcSO_2$ showed no clear improvement. So, we decided to initiate ECMO on day 8 in ICU. We chose venovenous (VV) mode with a 16 Fr tube in the right jugular vein and a 22 Fr tube in the right femoral vein. The Bio-Medicus Bio-console 560 perfusion systems (Medtronic, Inc, Minneapolis, Minnesota, USA) were used for ECMO. Settings for ECMO were as follows: pump speed, 4470 r/min; blood flow, 5.15 L/min; gas flow, 5 L/min and FiO_2 of 100%. Heparin was administered to maintain the activated partial thromboplastin time (APTT) between 40 and 50 seconds.

ABGs were drawn two times per day and significant improvement in PO_2 of 146 mmHg was seen on the first day. However, daily bronchoscopic examination showed no obvious changes (Figure 1C). The patient received continuous mechanical ventilation, intravenous meprednisone, total parenteral nutrition, sedative agents, antibiotics and antifungals, and chest tubes remained in the thoracic cavity and mediastinum.

After 22 days of ECMO support, the patient experienced a progressive deterioration of ar-

terial oxygenation with independent oxygenation testing. The ABG before withdrawal of ECMO was as follows: pH of 7.47; PCO_2 of 48 and PO_2 of 148. After discontinuation of ECMO, the chest X-ray showed worsened pneumomediastinum as the tidal volume (V_t) was 520 mL. To prevent the development of pneumomediastinum, the parameters of ventilation were set to the lung protection mode. PPV and bronchoscopy were continued for the patient and transported to the general ward after 39 days of ICU treatment and discharged from the hospital after 126 days.

After five months from exposure to zinc chloride, pulmonary function tests were performed and the results revealed a severe diffusion dysfunction and a moderate to severe restrictive ventilatory dysfunction. The pulmonary function results showed forced vital capacity (FVC), 2.46 L (39% of the predicted value); forced expiratory volume in the first second (FEV1), 2.16 L (50% of the predicted value); ratio of forced expiratory volume in the first second to forced vital capacity (FEV1/FVC), 87.7% (106% of the predicted value); total lung capacity (TLC), 3.24 L (48% of the predicted value); diffusion capacity, 62% of the predicted value. The mean concentration of exhaled nitric oxide (NO)

ECMO: an efficient approach to treat ARDS

of him was 25 ppb, which indicated mixed airway inflammation.

Case 2

A 23-year-old soldier stayed in the same tunnel trench as described in case 1 for nearly the same period when the accident occurred. The CT scan showed patchy shadows 5 hours later (**Figure 1B**).

He had a very similar treatment course as detailed for Case 1 above. On day 12, ECMO was started, and VV mode was applied. ECMO settings were as follows: pump speed, 3580 r/min; blood flow, 5 L/min; gas flow, 5 L/min and FiO_2 of 100%. On day 2 of ECMO, the catheters were replaced because of coagulation (**Figure 1D**). After 18 days of ECMO support, blood culture results showed positive for *Enterobacter aerogenes*. ECMO was removed due to catheter associated infection. The patient was discharged after 138 days.

This young man received pulmonary function tests at the same time with case 1. His results were quite similar with case 1. Exhaled NO determinations were also done at the same time. The mean concentration of exhaled NO revealed 3 ppb, indicating a non-eosinophilic airway inflammation.

Case 3

A 24-year-old young man was the leader of the group and consisted of 4 soldiers in his team. He was positioned closest to the smoke grenade, and was exposed to smoke for over 3 minutes. He was admitted to ICU directly. As his transcutaneous monitoring of oxygen saturation of hemoglobin (TcSO_2) could not reach a satisfactory level, ECMO was begun on the day 3 of ICU. There was no improvement in the oxygenation level despite ECMO support. On day 6 of ICU, the patient died due to severe pneumorrhagia related to coagulation disorders and severe lung damage.

Lung tissue samples from Case 3 were examined under a microscope. The results showed blood vessel congestion, hemorrhagic areas, intraalveolar and interstitial edema, reflecting the changes associated with acute lung injuries. Hyaline walls, inflammatory cells, and aggregations of macrophages and red blood

cells were seen. Intraalveolar and interstitial spacing revealed severe chemical alveolitis (**Figure 1E**). Diffuse alveolar damage, widespread occlusion of micro vessels and micro thrombus were detected as well. The inflammation of bronchiole terminals was also found in the biopsy results (**Figure 1F**). All findings revealed acute lung injury and proliferation of endothelial cells.

Discussion

In 1945, 10 of 70 patients who were exposed to smoke bombs died in the Corradino tunnel (Malta) [6]. After this, several other reports on ZnCl_2 inhalational injuries caused by smoke bombs or fire accidents were published from various sources. Most of the patients in these reports died [3, 4, 6]. Till today, the researchers are still working hard to find a successful treatment. However, they revealed that the primary damage caused by inhalation of ZnCl_2 include pulmonary inflammation that progresses to respiratory failure, causing ARDS.

There are few strategies that improve the survival rates of patients with ARDS induced by either chemical (inhaled zinc chloride) or biological (bacterial or viral infections) factors. The published data showed that the core treatment of ARDS involves lung protective ventilation strategies of high PEEP, low Vt and plateau pressure less than 30 cm H_2O [7]. In our case report, the patients could not obtain a satisfactory TcSO_2 when the ventilator settings were as above. As early as 2000, Bartlett RH et al. shared their experiences at the University of Michigan in treating patients with ARDS by extracorporeal life support (ECLS) and the survival rate was 56% in 146 adults [8]. Chian et al. in his study reported a survivor in 2010 by ECLS [9]. And according to the guidelines of extracorporeal life support organization (ELSO), ECMO is provided when the risk of mortality is 50% or greater or during an obvious air leak syndrome. The risk of mortality of 50% is defined as $\text{PaO}_2/\text{FiO}_2$ (P/F) < 150 on FiO_2 > 90% and/or Murray score of 2-3. Although our cases were under high ventilator conditions, the PaO_2 did not reach a satisfactory level and the P/F was below 100. At the same time the ventilator causes pneumothorax and subcutaneous emphysema, an obvious air leak syndrome, revealing the need of ECMO.

One important factor in the management of ECMO is the pump speed. With the past experiences, the VV-ECMO or ECMO for pulmonary support always need longer periods for the lungs to recover. To attain this, we need a low pump speed for sustaining the ECMO operation to prevent blood clots. The gas flow should be regulated according to the CO₂ level in the ABG to keep the gas/blood ratio range between 1:1 and 10:1. Another key factor involves the management of anti-coagulation. We used heparin in our cases and activated clotting time (ACT) for the whole blood to monitor the levels of heparin. During ECMO, the problem about ACT and dosage of heparin is always an important concern for the physicians in the ICU. The guideline from ELSO described that the dosage of heparin usage should be regulated based on the level of APTT if conflicts exist between ACT and APTT [10]. The ideal level of ACT is between 180-220 seconds and APTT for 40-60 seconds. Besides, PPV is another way to decrease the mortality for ARDS [11]. In our cases, protective ventilation strategy and PPV were implemented upon admission to the ICU and continued till their ICU stay to maximize their ventilation function.

In the two survival cases, hypoxemia and low oxygenation were gradually improved throughout the treatment (**Figure 2**). Withdrawing ECMO was considered for case 1 who was on 22 days support and passed the independent oxygen testing. Moreover, the ECMO was stopped for case 2 as soon as the evidence of catheter associated blood infection was found, which was an *E. coli*. This experience showed that antibacterial treatment during ECMO was still a problem, especially when we used femoral vein in VV-ECMO. The biopsy of the patient who died showed acute (eg, edema and hemorrhage in the alveoli) and chronic (eg, neutrophils and fibroblasts accumulation) inflammatory reactions coexisting in the same tissue. This indicated that the management of coagulation and anti-coagulation remains to be key points during treatment of ARDS with ECMO.

Acknowledgements

The authors would like to acknowledge the permission of patient and family to publish this article. This work was supported by grants from the Special Research Projects of Capital Health

Development (2014-4-5091) and grants from the Military Research Projects of Weapons and Equipments (012016018300B12204).

Disclosure of conflict of interest

None.

Address correspondence to: Dr. Zhichun Feng, The Second School of Clinical Medicine, Southern Medical University, No. 1023-1063 South Shatai Road, Baiyun District, Guangzhou 510515, Guangdong, China. Tel: +86-010-84009048; E-mail: bzfengzc@yahoo.com

References

- [1] Pedersen C, Hansen CP and Gronfeldt W. [Zinc chloride smoke poisoning following the use of smoke ammunition]. *Ugeskr Laeger* 1984; 146: 2397-2399.
- [2] Wittek F, Torabi S, Kolb M and Walther UI. Pro-oxidative toxicity of cells in suspension does not point to a cell cultural artefact as an explanation of the increased susceptibility of alveolar epithelial-like cells after glucocorticoid pretreatment. *Toxicol In Vitro* 2014; 28: 1089-1096.
- [3] Matarese SL and Matthews JI. Zinc chloride (smoke bomb) inhalational lung injury. *Chest* 1986; 89: 308-309.
- [4] Hsu HH, Tzao C, Chang WC, Wu CP, Tung HJ, Chen CY and Perng WC. Zinc chloride (smoke bomb) inhalation lung injury: clinical presentations, high-resolution CT findings, and pulmonary function test results. *Chest* 2005; 127: 2064-2071.
- [5] Mahboob H, Richeson Iii R and McCain R. Zinc chloride smoke inhalation induced severe acute respiratory distress syndrome: first survival in the United States with extended duration (five weeks) therapy with high dose corticosteroids in combination with lung protective ventilation. *Case Rep Crit Care* 2017; 2017: 7952782.
- [6] Evans E. Casualties following exposure to zinc chloride smoke. *Lancet* 1945; 246: 368-370.
- [7] Acute Respiratory Distress Syndrome N, Brower RG, Matthay MA, Morris A, Schoenfeld D, Thompson BT and Wheeler A. Ventilation with lower tidal volumes as compared with traditional tidal volumes for acute lung injury and the acute respiratory distress syndrome. *N Engl J Med* 2000; 342: 1301-1308.
- [8] Bartlett RH, Roloff DW, Custer JR, Younger JG and Hirschl RB. Extracorporeal life support: the University of Michigan experience. *JAMA* 2000; 283: 904-908.

ECMO: an efficient approach to treat ARDS

- [9] Chian CF, Wu CP, Chen CW, Su WL, Yeh CB and Perng WC. Acute respiratory distress syndrome after zinc chloride inhalation: survival after extracorporeal life support and corticosteroid treatment. *Am J Crit Care* 2010; 19: 86-90.
- [10] Berei TJ, Lillyblad MP, Wilson KJ, Garberich RF and Hryniewicz KM. Evaluation of systemic heparin versus bivalirudin in adult patients: supported by extracorporeal membrane oxygenation. *ASAIO J* 2018; 64: 623-629.
- [11] Xu Y, Deng X, Han Y, Zhou L, He W, Chen S, Nong L, Huang H, Zhang Y, Yu T, Li Y and Liu X. A multicenter retrospective review of prone position ventilation (PPV) in treatment of severe human H7N9 Avian Flu. *PLoS One* 2015; 10: e0136520.