

## Case Report

# Endoscopic removal of large, rare rectosigmoid foreign body with Sengstaken-Blakemore tube

Liping Chen\*, Min Liu\*, Yajie Wang, Chunyan Lu, Zhiyin Shang, Jingmao Yang, Jilin Cheng

Department of Gastroenterology and Hepatology, Shanghai Public Health Clinical Center, Fudan University, Shanghai, China. \*Equal contributors.

Received May 29, 2018; Accepted August 4, 2018; Epub March 15, 2019; Published March 30, 2019

**Abstract:** A 36-year-old man presented to our hospital with a 1-day history of abdominal bloating after inserting a carrot into his rectum. The carrot did not pass spontaneously, and manual extraction was unsuccessful. The patient reported no anorectal or abdominal pain. Abdominal computed tomography confirmed a cone-shaped, low-density foreign body (length, 14 cm; maximum diameter, 4 cm) in the rectosigmoid junction with no evidence of bowel perforation. Emergency colonoscopy revealed the distal part of the carrot in the rectum. After switching to a 5.0-mm-diameter transanal gastroscope and insertion along the gap between the foreign body and bowel wall, liquid paraffin was injected by catheter into the lumen, surrounding the foreign body. A 5.6-mm-diameter Sengstaken-Blakemore tube was then inserted into the transanal endoscope and smeared with liquid paraffin. Both devices were then slowly advanced forward beyond the carrot. The gastric and esophageal balloons were successively inflated (up to 200 and 150 ml, respectively). Finally, the endoscope was gently pulled and the foreign body (carrot) was fully extracted without complications.

**Keywords:** Colonoscopy, foreign bodies

## Introduction

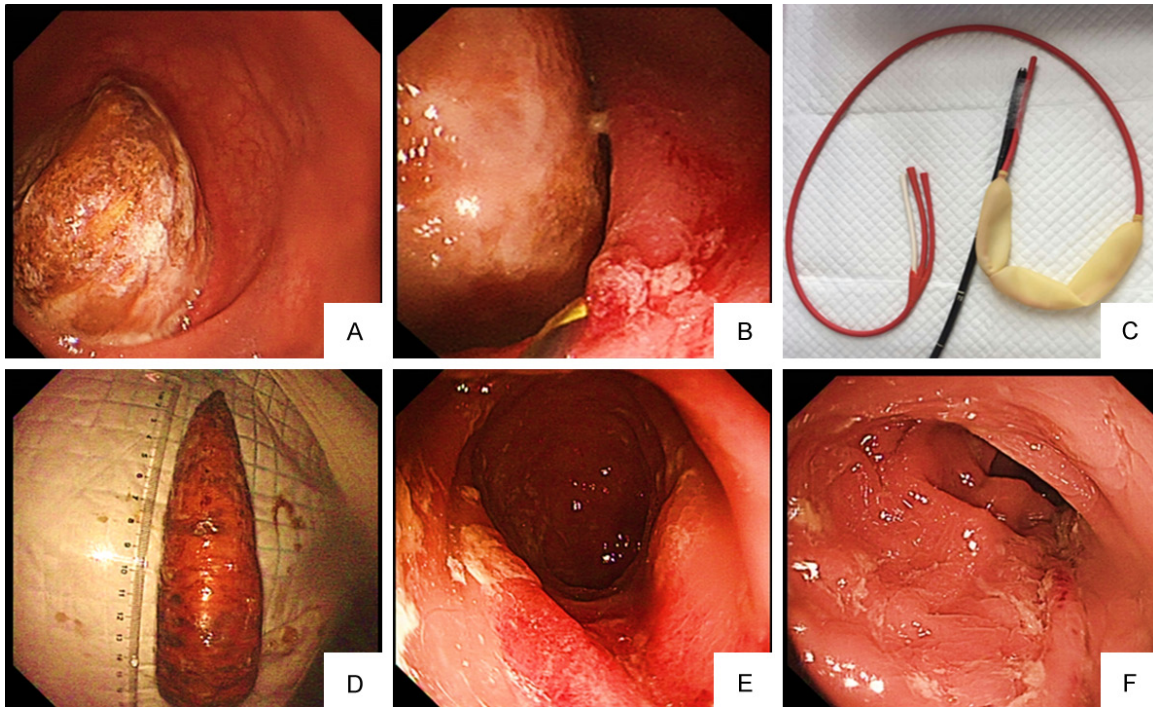
The incidence of foreign bodies in the rectum has recently increased [1] and most rectal foreign bodies have been inserted for sexual stimulation [2, 3]. Removal of retained foreign bodies requires experience and knowledge of different methods of extracting various shapes and sizes of the objects [4]. Most retained rectal foreign bodies can be successfully extracted. However, large objects impacted high in the rectosigmoid junction pose a challenge for endoscopic extraction [3]. Herein, we describe a method with Sengstaken-Blakemore tube to relieve a large, rare rectosigmoid foreign body under endoscopy.

## Case report

A 36-year-old man presented to our hospital with a 1-day history of abdominal bloating after inserting a carrot into his rectum. The carrot did not pass spontaneously, and manual extraction was unsuccessful. The patient reported no anorectal or abdominal pain. Physical examination

showed a thin man with normal vital signs. The abdomen was soft with normal bowel sounds. Abdominal computed tomography confirmed a cone-shaped, low-density foreign body (length, 14 cm; maximum diameter, 4 cm) in the rectosigmoid junction with no evidence of bowel perforation. Emergency colonoscopy revealed the distal part of the carrot in the rectum, 10 cm away from the anal edge (**Figure 1A**). The lumen was almost completely blocked and the colonoscopic body was unable to pass. After switching to a 5.0-mm-diameter transanal gastroscope and insertion along the gap between the foreign body and bowel wall, liquid paraffin was injected by catheter into the lumen, surrounding the foreign body, through the nasal endoscopic biopsy channel (**Figure 1B**). However, multiple attempts to remove the carrot, including utilizing biopsy forceps and a polypectomy snare, failed because the carrot was very long and inflexible. Additionally, it was difficult to pass the endoscope through the angle of the rectosigmoid junction. A 5.6-mm-diameter Sengstaken-Blakemore tube was then inserted

## Endoscopic removal of large, rare rectosigmoid foreign body



**Figure 1.** Endoscopic removal of large rectosigmoid foreign body with the Sengstaken-Blakemore tube. A. Endoscopic image of the carrot in the rectum completely obstructing the lumen. B. Liquid paraffin was injected by catheter through the nasal endoscopic biopsy channel. C. A Sengstaken-Blakemore tube was attached to the transnasal endoscope. D. The extracted foreign body. E. Endoscopic image of the mucosa immediately after extraction. F. Endoscopic image of the mucosa the day after extraction.

into the transnasal endoscope and smeared with liquid paraffin (**Figure 1C**). Both devices were then slowly advanced forward beyond the carrot. The gastric and esophageal balloons were successively inflated (up to 200 and 150 ml, respectively). Finally, the endoscope and foreign body were gently pulled out (**Figure 1D**). The carrot was fully extracted without complications. After extraction, endoscopy showed only mild superficial mucosal scratches, congestion, and edema without active bleeding or perforation (**Figure 1E**). The patient was observed for one night under anti-infection treatment after the procedure. Subsequent endoscopy showed alleviation of the inflammation the next day (**Figure 1F**).

### Discussion

Management of patients with bowel foreign bodies can be challenging depending on the size, shape, and location of the object [4]. Endoscopic removal is a safe, feasible, and less morbid method to extract foreign bodies in the absence of perforation [3] and it should be the first step in management of such patients before attempting open surgery.

The aim of clinical evaluation of these patients is to determine whether removal can be performed safely under endoscopy [5]. Larger and rare objects make these objects more difficult to remove. Therefore, many ingenious methods to extract different rectal and colonic foreign bodies have been exerted. Yilmaz B et al. [6] used a long Kocher clamp to remove the bulb completely without complication under colonoscopic observation. Singaporewalla RM et al. [3] used endoscopic snare to extract a shampoo bottle impacted at the rectosigmoid junction. Billi P [7] reported a case with endoscopic removal of a large rectal foreign body using a large balloon dilator. Wouden EJ et al. [8] used a custom-made giant snare to extract a rectal foreign body. Sengstaken-Blakemore tube used in treatment of esophageal gastric varices hemorrhage [9] was applied in endoscopic object removal. Even so, endoscopic grasping large and inflexible high-lying objects is rather difficult. Lumen expansion is essential for endoscopic removal. Sayilir et al. [2] used a Foley catheter inflated with 20 ml of air to successfully remove a rectal mandarin under colonoscopy. In the present case, the Sengstaken-Blakemore tube used in treatment of esopha-

## Endoscopic removal of large, rare rectosigmoid foreign body

geal gastric varices hemorrhage [9] was applied in endoscopic object removal. The gastric and esophageal balloons were inflated successively to facilitate the carrot's removal because the bulging of the balloon has the ability to widen the bowel, stabilize the foreign body, and straighten the colorectum. In conclusion, an innovative endoscopic strategy with the Sengstaken-Blakemore tube was used to extract the foreign body and thus avoid surgery.

### Acknowledgements

We thank all the partners who participated in this procedure and Angela Morben, from Liwen Bianji, Edanz Editing China, for editing the English text of a draft of this manuscript. This study was funded by Shanghai science and technology development fund (No.1741196-9500), Shanghai health planning commission fund (No.201640207).

### Disclosure of conflict of interest

None.

**Address correspondence to:** Jilin Cheng, Department of Gastroenterology and Hepatology, Shanghai Public Health Clinical Center, Fudan University, 2901 Caolang Road, Jinshan District, Shanghai, China. Tel: 86-18916035612; E-mail: chengjilin@shaphc.org.cn; 2360931679@qq.com

### References

- [1] Terrosu G, Cherchi V, Calandra S, Esposito A, Marino M, Berretti D and Risaliti A. A particular use of endobag®: extraction of rectal foreign bodies. *Case Rep Med* 2017; 2017: 8909706.
- [2] Sayilir A, Duzgun IN and Guvendi B. Treatment of unusual rectal foreign body using a Foley catheter. *Endoscopy* 2014; 46 Suppl 1 UCTN: E182-183.
- [3] Singaporewalla RM, Tan DE and Tan TK. Use of endoscopic snare to extract a large rectosigmoid foreign body with review of literature. *Surg Laparosc Endosc Percutan Tech* 2007; 17: 145-148.
- [4] Nivatvongs S, Metcalf DR and Sawyer MD. A simple technique to remove a large object from the rectum. *J Am Coll Surg* 2006; 203: 132-133.
- [5] Ayantunde AA. Approach to the diagnosis and management of retained rectal foreign bodies: clinical update. *Tech Coloproctol* 2013; 17: 13-20.
- [6] Yilmaz B, Ozmete S, Altinbas A, Aktas B and Ekiz F. Successful removal of an unusual rectal foreign body with a Kocher clamp. *Endoscopy* 2014; 46 Suppl 1 UCTN: E549.
- [7] Billi P, Bassi M, Ferrara F, Biscardi A, Villani S, Baldoni F and D'Imperio N. Endoscopic removal of a large rectal foreign body using a large balloon dilator: report of a case and description of the technique. *Endoscopy* 2010; 42 Suppl 2: E238.
- [8] van der Wouden EJ and Westerveld BD. Extraction of a rectal foreign body using a custom-made giant snare. *Endoscopy* 2010; 42 Suppl 2: E122.
- [9] Haddock G, Garden OJ, McKee RF, Anderson JR and Carter DC. Esophageal tamponade in the management of acute variceal hemorrhage. *Dig Dis Sci* 1989; 34: 913-918.