

Case Report

Paget's disease on the right breast complicated with invasive ductal carcinoma on the left side: a case report

Yufang Ding¹, Qinghai Zeng¹, Shuanghai Hu¹, Aiyuan Guo¹, Li Lei², Ling Jiang¹, Xiaoli Yu¹, Jing Chen¹

¹Department of Dermatology, The Third Xiangya Hospital of Central South University, Changsha 410013, Hunan, P. R. China; ²Department of Dermatology, Xiangya Hospital, Central South University, Changsha 410000, Hunan, P. R. China

Received November 15, 2017; Accepted October 9, 2018; Epub April 15, 2019; Published April 30, 2019

Abstract: Mammary Paget's disease (MPD) is a rare form of breast carcinoma. While the nonsynchronous coexistence of malignant tumor in one breast and Paget's disease on the other side is extremely rare. In this study, we presented a case of Paget's disease in one breast and invasive ductal carcinoma in the other breast. An 58-year-old woman presented with 5 cm × 8 cm sized, erythematous plaque on her right breast, and she'd had this lesion for 10 years. Histopathology revealed atypical neoplastic cells with cytoplasmic vacuole, nuclei varying in size and presence of mitotic figures throughout the parakeratotic. Immunohistochemical studies demonstrated that the neoplastic cells were positive for low molecular weight cytokeratin, cytokeratin 7, carcinoembryonic antigen; in contrast, they were negative for high molecular weight cytokeratin, cytokeratin 5/6, Melan-A and HMB45. However, histological examination showed invasive carcinoma on the left breast in 2009. So when breast carcinoma is been diagnosed, it is important not to ignore the possibility of the existence of a nonpalpable mass lesion on the other breast.

Keywords: Mammary Paget's disease, invasive ductal carcinoma, breast carcinoma

Introduction

Rare cases of coexistence of malignant tumor in one breast and MPD in the other breast have been reported [1-3]. In the English literature, only two cases of nonsynchronous MPD occurred in contralateral breast following mastectomy for breast carcinoma have been reported to date [1, 2]. Herein, we reported a rare case presented with MPD in the right breast [without any underlying ductal carcinoma in situ (DCIS) or invasive ductal carcinoma (IDC)] and nonsynchronous IDC in the left breast.

Case report

A 58-year-old female was admitted in the Department of Dermatology in our hospital for an erythematous lesion on her right breast in September, 2016. The lesion started 10 years ago, when she noticed a rash of the size of mung bean on the right nipple-areola, with light red fluid exudation, itching, and pale yellow nipple discharge. The patient didn't take the lesion seriously, and treated it herself with compound

dexamethasone acetate cream and complex iodine. The lesion gradually enlarged and completely effaced the nipple and areola disappeared 2 years later. A palpable mass of the size of walnut on the left breast was noted while taking a bath in March, 2009. An incisional biopsy of the left breast mass was done excised on May 27, 2009. Intraoperative frozen section revealed IDC. Subsequently a left modified radical mastectomy including axillary lymph node dissection was performed. Histological examination showed invasive carcinoma was about 2 cm × 3 cm in size with negative surgical margins and no involvement of the nipple or axillary lymph nodes (0/16). Immunohistochemical analysis showed that tumor cells were positive for C-erbB-2, E-catenin, and Ki-67 expression of 10%. By contrast, they were negative for estrogen receptor (ER) and progesterone receptor (PR). The patient received postoperative docetaxel (60 mg) and epirubicin (50 mg) chemotherapy twice, and no recurrence was reported during follow-up to date. Unfortunately, the lesion on the right breast was not inspected. Her past medical record reported type-2 diabe-

Paget's disease on the breast complicated with invasive ductal carcinoma

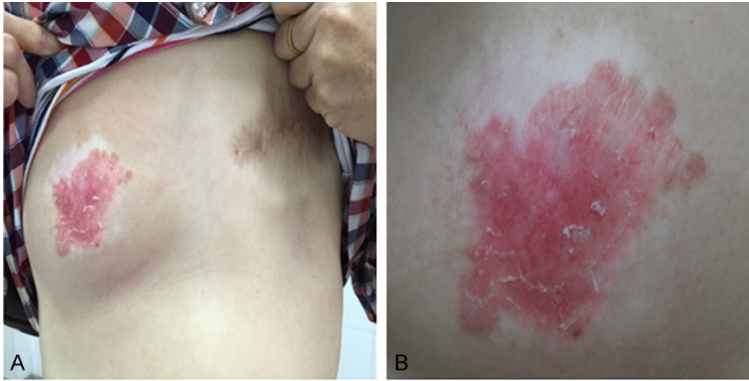


Figure 1. Paget's disease on the right breast with surgical scar on the left chest status post left modified radical mastectomy. A. An irregular erythematous lesion measured 5 cm × 8 cm on the right breast with complete effacement of the nipple and areola, and an old surgical scar on the left chest following prior mastectomy. B. An erythematous lesion on the right breast with atrophy, desquamation, and peripheral hypopigmentation.

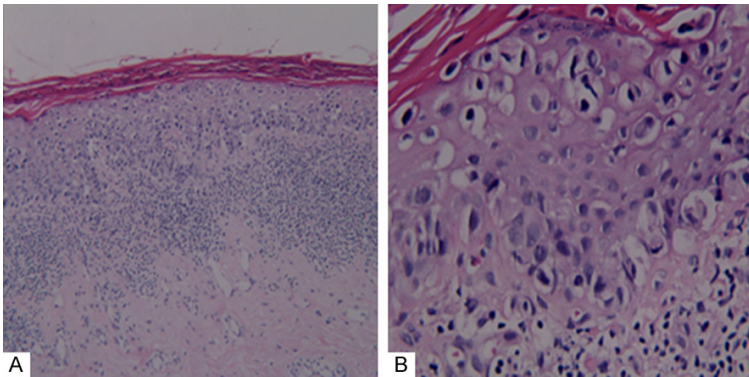


Figure 2. Histopathological findings of the erythematous lesion on the right breast (HE staining). A. There were parakeratosis and epidermal hyperplasia. A band-like inflammatory cell infiltrate was seen in the superficial dermis (H & E). B. Numerous large, atypical neoplastic cells were evident throughout the epidermis with cytoplasmic vacuole, nuclei varying in size; presence of mitotic figures (H & E).

tes mellitus was found in 2004, and glycemic index was well controlled. The family history was unremarkable.

Dermatological inspection revealed a 5 cm × 8 cm irregular erythematous lesion on the right breast which was sharply demarcated with atrophy and desquamation. Depigmentation was found around the lesion, but no signs of scars, tangerine pericarp or dimples were found. In addition, the normal anatomical structure of the right nipple and areola was destroyed (**Figure 1**). No palpable mass was detected beneath the lesion, and there was no axillary lymphadenopathy. A 10 cm-long surgical scar could be observed on the left breast secondary to prior mastectomy.

Histopathology on lesion of the right breast revealed numerous large, atypical neoplastic cells with cytoplasmic vacuole, nuclei varying in size and presence of mitotic figures throughout the parakeratotic and mildly hyperplastic epidermis. No tumor cells were seen in the dermis. There was a band of lymphocytic infiltrate in the papillary dermis (**Figure 2**). The neoplastic cells showed the following immunocytochemical profile (**Figure 3**): low molecular weight cytokeratin (LCK) (3+), cytokeratin 7 (CK7) (3+), carcinoembryonic antigen (CEA) (+) and Ki-67 expression of 15%, high molecular weight cytokeratin (HCK) (-), cytokeratin 5/6 (CK5/6) (-), Melan-A (-) and HMB45 (-). Based on the histopathological and immunocytochemical findings, a diagnosis of MPD was made.

With MPD in her right breast and status post left modified radical mastectomy, the patient was transferred to the Breast Surgery Department of our hospital, a modified radical mastectomy was performed on her right breast in consideration of her age as well as prior IDC in the left side.

Pathological examination of the right radical mastectomy specimen showed Paget's disease with negative surgical margins and breast hyperplasia accompanied by fibrosis and collagen, but no involvement in axillary lymph nodes (0/20) was found. In March 2017, telephone follow-up the patient did not complain of special discomfort, nor did she go to the hospital for examination. It is still in further follow-up.

Discussion

Histogenesis of MPD remains controversial. Two main hypotheses have been proposed for the origin of MPD. One is the epidermotropic ductal theory, which suggests that Paget's cells are neoplastic cells migrated from an underlying

Paget's disease on the breast complicated with invasive ductal carcinoma

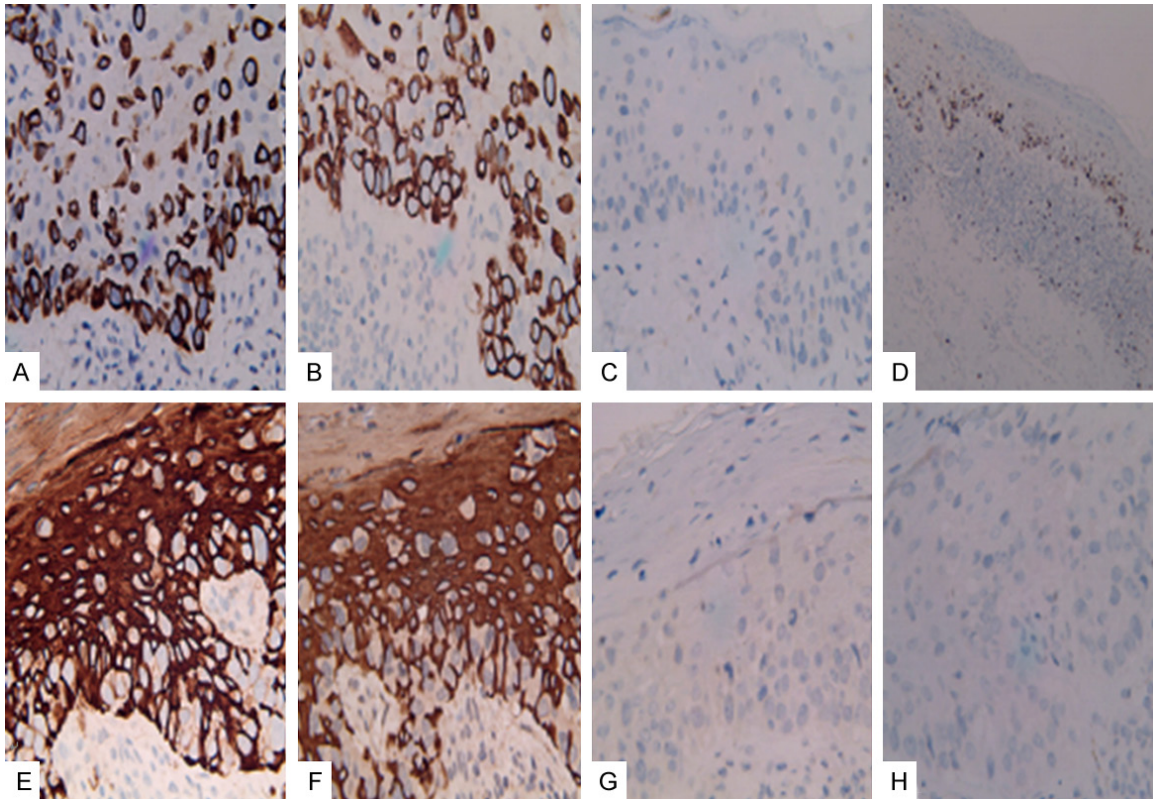


Figure 3. Immunohistochemistry of the right breast lesion. (SP) The intraepidermal carcinoma cells were strongly positive for low molecular weight cytokeratin (A), cyokeratin7 (B), and positive for carcinoembryonic antigen (C), Ki-67 showed a proliferative rate of 15% (D). They were negative for high molecular weight cytokeratin (E), cytokeratin 5/6 (F), Melan-A (G), HMB-45 (H).

ing in situ or invasive carcinoma of the breast via the lactiferous ducts to the epidermis of the nipple [4]. This theory is widely accepted since most cases of MPD have indeed an underlying breast invasive or in situ carcinoma [5]. The other is the transformation theory suggesting that Paget's cells originate from malignant transformation of keratinocytes [4-6]. This latter theory assumes that MPD is a process independent from the underlying breast tissue [4]. In addition, some authors believe that MPD arises from Toker cells, which are clear cells present in the squamous epithelium of the nipple and they may be related to a less common form of MPD which is not associated with underlying DCIS or IDC [7]. This theory is supported by a study, which reported that in two out of ten cases studied, Paget's cells were genetically different from the underlying breast carcinoma [8]. In the present case, the findings of MPD without underlying invasive or in situ carcinoma in the right breast and IDC in the left breast completely excised with no evidence of metastatic disease indicate that they were two independent tumors.

MPD accounts for 2-3% of all neoplastic conditions of the breast [9], and presents at a median age of 55 years [10]. Due to the close resemblance of the disease to chronic dermatitis, both under-diagnosis and misdiagnosis are common, causing a median delay of up to 6 months in initiation of appropriate treatment [11]. Kanwar AJ et al. [12] have reported an unusual case of Paget's disease lasting 14 years, which attained gigantic proportions involving the bilateral breasts and adjacent parts of chest and abdominal walls. In the present report, a correct diagnosis was made by a biopsy after a delay of 10 years. Our case reinforces the notion that any chronic eczematous lesion on the breast should be evaluated thoroughly both clinically as well as histologically to rule out malignancy. This will facilitate early detection and treatment with better outcome.

To the best of our knowledge, only two cases with IDC in one breast and MPD in the other breast have been reported in the literature. Crignis GS et al. [1] reported a case of 77-year-old woman who had MPD involving the left

Paget's disease on the breast complicated with invasive ductal carcinoma

breast and an IDC in the right breast. Salopek D et al. [2] reported a case of 65-year-old woman who had MPD on her left breast and IDC in the right breast. In both cases MPD developed years later in the contralateral breast following mastectomy of IDC in one breast. Our case with presentation of MPD in one breast and then later on IDC in the other breast is unique and has not been reported in the literature yet. So when breast carcinoma is diagnosed, it is important not to ignore the possibility of the existence of a nonpalpable mass lesion on the other breast. We believe this case report is interesting and has great significance in clinical.

Disclosure of conflict of interest

None.

Address correspondence to: Dr. Jing Chen, Department of Dermatology, The Third Xiangya Hospital of Central South University, 138 Tongzipo Road, Changsha 410013, Hunan, P. R. China. Tel: +86-13755090906; E-mail: 43700351@qq.com

References

- [1] Crignis GS, Abreu Ld, Buçard AM, Barcaui CB. Polarized dermoscopy of mammary Paget disease. *An Bras Dermatol* 2013; 88: 290-2.
- [2] Salopek D, Murgić J, Tomas D, Bolanca A, Kusić Z. Paget's disease in contralateral breast occurring 11 years after mastectomy for invasive ductal carcinoma. *Coll Antropol* 2009; 33: 327-9.
- [3] Kijima Y, Owaki T, Yoshinaka H, Aikou T. Synchronous bilateral breast cancer with paget's disease and invasive ductal carcinoma: report of a case. *Surg Today* 2003; 33: 606-8.
- [4] Lim HS, Jeong SJ, Lee JS, Park MH, Kim JW, Shin SS, Park JG, Kang HK. Paget disease of the breast: mammographic, US, and MR imaging findings with pathologic correlation. *RadioGraphics* 2011; 31: 1973-87.
- [5] Lim HS, Jeong SJ, Lee JS, Park MH, Kim JW, Shin SS, Park JG, Kang HK. HER2 molecular subtype is a dominant subtype of mammary Paget's cells. An immunohistochemical study. *Histopathology* 2010; 57: 564-71.
- [6] Karakas C. Paget's disease of the breast. *J Carcinog* 2011; 10: 31.
- [7] Saeed D, Shousha S. Toker cells of the nipple are commonly associated with underlying sebaceous glands but not with lactiferous ducts. *J Clin Pathol* 2014; 67: 1010-2.
- [8] Morandi L, Pession A, Marucci GL, Foschini MP, Pruneri G, Viale G, Eusebi V. Intraepidermal cells of paget's carcinoma of the breast can be genetically different from those of the underlying carcinoma. *Hum Pathol* 2003; 34: 1321-30.
- [9] Lloyd J, Flanagan AM. Mammary and extramammary Paget's disease. *J Clin Pathol* 2000; 53: 742-9.
- [10] Siponen E, Hukkinen K, Heikkil P, Joensuu H, Leidenius M. Surgical treatment in Paget's disease of the breast. *Am J Surg* 2010; 200: 241-6.
- [11] Singla V, Virmani V, Nahar U, Singh G, Khandelwal NK. Paget's disease of breast masquerading as chronic benign eczema. *Indian J Cancer* 2009; 46: 344-7.
- [12] Kanwar AJ, De D, Vaiphei K, Bhatia A, Sharma RK, Singh G. Extensive mammary paget's disease. *Clin Exp Dermatol* 2007; 32: 326-7.