

Original Article

OCT-guided PCI versus angiography-guided PCI for small diffuse coronary artery disease

Guozhong Wang, Quanming Zhao, Qing Cheng, Xiaoxia Zhang, Lei Tian, Xiaofan Wu

Department of Cardiology, Beijing Anzhen Hospital, Capital Medical University, Beijing Institute of Heart Lung and Blood Vessel Diseases, Beijing, China

Received September 24, 2018; Accepted February 13, 2019; Epub May 15, 2019; Published May 30, 2019

Abstract: Many studies demonstrate that the cumulative incidence of major adverse cardiovascular events (MACE) increase with a greater lesion length and smaller vessel size after DES implantation. OCT would provide operators with more accurate information about target lesions and a more comprehensive assessment of the stented segment during PCI. Whether it could provide benefit for the PCI procedure on small diffuse lesions remains undetermined. The aim of this study is to assess the efficacy and safety of optical coherence tomography (OCT)-guided percutaneous coronary intervention (PCI) in patients with small diffuse coronary artery disease. The total study cohort included 587 consecutive patients who underwent PCI treatment for small diffuse lesions. Of these patients, 474 underwent procedures that were guided by angiography alone, while the remaining 113 patients underwent procedures that were guided by OCT. The patients presented for a 1-year follow-up after the index procedure. The primary endpoint was the 1-year incidence of major adverse cardiovascular events (MACE). Propensity score matching was performed for 113 pairs to eliminate the imbalance between the groups. During 1-year follow up, the MACE rate was lower in the OCT-guided group compared with the angiography-guided group (7.9% vs. 19.5%, $P=0.001$). This was mainly derived from the significantly lower TVR rate in the OCT-guided group (7.1% vs. 16.8%, $P=0.04$). Log-rank analyses demonstrated that the OCT-guided group had superior results to the angiography-guided group both before and after matching ($P=0.01$). The OCT-guided approach may improve efficiency and safety in long diffuse coronary lesions in small vessels.

Keywords: Optical coherence tomography, percutaneous coronary intervention, coronary artery disease, small vessels

Introduction

Drug-eluting stents (DES) have dramatically reduced the rate of in-stent restenosis and subsequent target lesion revascularization (TLR) compared with bare metal stents (BMS) [1]. However, many studies demonstrated that the cumulative incidence of major adverse cardiovascular events (MACE) increases with a greater lesion length and smaller vessel size after DES implantation [2-4]. It is clear that suboptimal stent implantation is an important risk factor for DES failure in complex lesions, including lesions in small and diffuse coronary disease [5, 6]. Therefore, how to optimize the DES deployment for small and diffuse coronary artery disease is a clinically relevant issue that remains unsolved.

In the small diffuse coronary artery lesions subset, the precise choice of the stent size and

optimal stent implantation are difficult to achieve due to the vascular remodeling and plaque features, while angiography only displays the luminal information, without information about plaque morphology, vascular remodeling, or the atherosclerosis burden; therefore, it has various limitations in the rational choice of stent size and in identifying in suboptimal stent deployment (e.g., stent underexpansion, malapposition, stent-edge dissection, and plaque protrusion) [7, 8]. In theory, intraluminal imaging methods, such as intravascular ultrasound (IVUS), can provide benefits for the percutaneous coronary intervention (PCI) procedure of small diffuse lesions [9, 10]. However, until now, there has been no clinical study clearly demonstrating that IVUS-guided DES implantation provides a clinical benefit. OCT has a higher resolution than IVUS, and it offers more detailed information on microstructural findings (e.g., stent underexpansion, intra-stent tissue protrusion).

sion, incomplete stent apposition, and stent-edge dissection) during PCI [11, 12]. The use of OCT during PCI provides operators with reliable information on reference vessel dimensions and target lesion characteristics, while following stenting, OCT allows for a comprehensive assessment of the stented arterial segment. Although some clinical studies show that OCT-guided PCI is superior to angiography-guided PCI (angio-guided PCI) in complex subsets of lesions [13-15], whether OCT-guided PCI improves clinical performance in small diffuse lesions is undetermined.

The aim of the present study was to compare the clinical outcomes of OCT-guided PCI to those of angio-guided PCI in the treatment of small diffuse coronary artery disease and to demonstrate that stent optimization using OCT may improve clinical outcomes in patients with small diffuse coronary lesions.

Material and methods

Clinical, laboratory, and angiographic data were collected in 21920 consecutive subjects who had undergone PCI with DES for *de novo* coronary artery stenosis at the Beijing Anzhen Hospital between January 1, 2013 and May 30, 2015.

The exclusion criteria were: ST-segment elevation myocardial infarction (MI), coronary lesions involving the left main vessel, bifurcation lesions requiring two stents, and total occlusion lesions. Severe left ventricular dysfunction (ejection fraction < 30%), cardiogenic shock, neoplastic disease, a platelet count < 150000/mL, and hemoglobin < 10 g/L were also exclusion criteria.

Thus, the total study cohort included 587 consecutive patients with one small vessel diffuse lesion (a diameter of less than 2.75 mm and greater than 20 mm) who were treated with at least one or multiple overlapping DES. Of note, the choice to perform OCT was left to the operator's decision. A procedure was considered OCT-guided when OCT examinations were done at pre-intervention and/or post-intervention. OCT was performed during the PCI procedure for optimal stent implantation for 113 patients. Pre-PCI OCT examination was done to evaluate the characterization of plaque and to estimate the reference diameter or length of the lesion in

92 patients (83.7%) of the OCT-guided group. Post-PCI OCT examination was performed to detect suboptimal stent deployment in all 113 patients. OCT was not used for the 474 remaining patients who underwent PCI guided by only angiography. Accordingly, we performed propensity score matching to adjust for significant differences in the clinical and PCI procedural characteristics between angio-guided PCI and OCT-guided PCI, through which 113 well-matched pairs were selected (113 patients from the OCT-guided group and 113 patients from the angio-guided group). All of the patients gave their written consent for the PCI procedure, and the study was conducted under local Institutional Review Board approval.

The procedure

All of the patients received 300 mg of aspirin and at least 300-600 mg of clopidogrel before arriving at the catheterization room. The PCI was performed via femoral or radial access using unfractionated heparin or bivalirudin anticoagulation, per the operator's preference. All of the procedures were performed using standard techniques. Pre-dilatation, post-dilatation, and the use of OCT were left to the operator's discretion. After the procedure, all of the patients were advised to continue on aspirin (100 mg daily) for life unless there were contraindications. Either ticagrelor (90 mg twice daily) or clopidogrel (75 mg daily) was also prescribed for at least 12 months after the stent implantation.

OCT was performed using a frequency-domain OCT system (C7-XR OCT imaging system, Light Lab Imaging, Inc, St. Jude Medical, St. Paul, Minnesota). OCT runs were performed at a rate of 100 frames/sec. During the pre-PCI OCT examination, the mini lumen diameters (MLD) were measured, then the proximal and distal reference mean external elastic lamina diameters (mean vessel diameter, MVD) were measured also. The size of stent was determined according to the MVD. If the external elastic lamina could not be visualized, the size of the stent was determined according to the lumen diameters. The stent length was determined as the distance from the distal reference site to the proximal reference site.

After stent deployment, OCT imaging was done, and the images of the OCT run were manually

analyzed by physicians. The stent expansion, stent apposition, tissue or thrombus protrusion, stent edged dissection, and untreated reference segment disease were assessed. Stent under-expansion was defined as a minimum stent area of less than 90% in both the proximal and distal halves of the stent relative to the closest reference segment. Major edge dissection was defined as $\geq 60^\circ$ of the circumference of the vessel at the site of dissection or ≥ 3 mm in length. Stent malapposition was defined as struts clearly separated from the vessel wall by ≥ 0.2 mm. The untreated diseased segment was defined as a plaque load greater than 50% at the adjacent segment within 5 mm. After the OCT images analysis was performed, the treating physician decided whether any additional treatment was necessary. If necessary, post-dilatation was performed to achieve at least acceptable stent expansion and apposition, or another stent was placed to treat major stent-edged dissection and untreated diseased segment. When tissue or thrombus protrusion was found, the use of a glycoprotein IIb/IIIa inhibitor was left to the operator's discretion. Afterwards, another OCT examination was performed to eliminate any adverse complications before the procedure was finished.

Outcomes

The patients presented for follow-up by a clinic visit or by telephone at 1, 3, and 6 months, and 1 year after the index procedure. The primary endpoint was the 1-year incidence of major adverse cardiovascular events (MACE), which was defined as the composite of death from cardiovascular (CV) causes, non-fatal myocardium infarction, ischemia-driven target vessel revascularization (TVR), and stent thrombosis. All deaths were considered CV unless an unequivocal non-CV cause could be confirmed. We defined myocardium infarction according to Third Universal Definition of Myocardial Infarction [16], and we defined stent thrombosis according to the definite or probable criteria of the Academic Research Consortium [17].

Statistical analysis

The summary statistics are presented as the mean \pm SD for the continuous variables and as the percentage or proportions for the categori-

cal variables. The clinical characteristics of the 2 groups were compared using the *t* test and χ^2 test for continuous and categorical variables, respectively. Propensity scores (PS) were estimated by fitting a logistic regression model using the following variables for OCT-guided PCI versus angiography-guided PCI: age, gender, hypertension, diabetes mellitus, dyslipidemia, current smoking status, renal dysfunction (serum creatinine > 2.0 mg/dL), cerebrovascular disease, previous MI, previous PCI, prior coronary bypass surgery, left ventricular ejection fraction, acute coronary syndrome, duration of dual antiplatelet therapy (< 12 months), P²Y¹² antiplatelet drug (clopidogrel or ticagrelor), lesion type (c type or not) stent length (mm), and DES type. Propensity score matching was performed using 1:1 nearest neighbor matching with a caliper of 0.01. The *p* value from the Hansen and Bowers balance test was 1.000, indicating a good covariate balance. Major adverse cardiovascular event-free survival curves for patients with and without the use of OCT were generated by the Kaplan-Meier method and compared using a log-rank test. All of the *p* values were two-sided, and a *p* value < 0.05 was considered statistically significant. The statistical analysis was performed using SPSS (version 21.0.0, SPSS Inc., Chicago, Illinois).

Results

One hundred and thirteen patients were enrolled into the OCT-guided group and 474 into the angio-guided group. In the OCT-guided group, there were more patients with renal insufficiency (14/113, 12.3% vs. 31/474, 6.6%, $P=0.05$) and a higher prevalence of ACS (38/113, 33.6% vs. 141/474, 29.8%, $P=0.04$) compared with the angio-guided group, but the BNP level was greater in the angio-guided PCI group compared with the OCT-guided group. The total lengths of the lesion and stent were longer in the OCT-guided group than in the angio-guided group (shown in **Table 2**). However, the frequency of multiple stent (stents ≥ 2) deployments was not significantly different between the two groups (47.0% vs. 46.3%, $P=0.92$). There were more small stents (2.25 mm stent) deployed in the OCT-guided cohort compared to the angio-guided group (61.1% vs. 45.1%, $P=0.03$). The OCT-guided PCI group did not use more post-dilatation, but they had

OCT-guided PCI for small vessels

Table 1. The baseline clinical characteristics of the study population

Characteristics	Before matching			After matching			
	OCT group (n=113)	Angiography group (n=474)	P	OCT group (n=113)	Angiography group (n=113)	P	
Age (years)	68±11	67±13	0.45	68±11	67±13	0.53	
Male sex (n, %)	73 (64.6%)	312 (65.8%)	0.83	73 (64.6%)	76 (67.3%)	0.78	
Diabetes mellitus (n, %)	37 (32.7%)	156 (33.0%)	0.92	37 (32.7%)	34 (30.1%)	0.77	
Hypertension (n, %)	70 (61.9%)	289 (61.0%)	0.91	70 (61.9%)	66 (58.4%)	0.68	
Current smoker (n, %)	36 (31.9%)	165 (34.9%)	0.58	36 (31.9%)	35 (31.0%)	1.00	
Hypercholesterolemia (n, %)	71 (62.8%)	306 (64.4%)	0.74	71 (62.8%)	74 (65.5%)	0.78	
Previous MI (n, %)	14 (12.4%)	60 (12.6%)	1.00	14 (12.4%)	13 (11.5%)	1.00	
Previous PCI (n, %)	21 (18.6%)	84 (17.7%)	0.89	21 (18.6%)	22 (19.4%)	1.00	
Prior coronary bypass surgery	2 (1.8%)	5 (1.1%)	0.62	2 (1.8%)	2 (1.8%)	1.00	
Renal insufficiency	14 (12.3%)	31 (6.6%)	0.05*	14 (12.3%)	10 (8.8%)	0.51	
Left ventricular ejection fraction (%)	43±11	45±13	0.13	43±11	42±14	0.55	
Acute coronary syndrome	38 (33.6%)	141 (29.8%)	0.04*	38 (33.6%)	34 (30.1%)	0.67	
Peak troponin I (ng/ml)	0.45±0.52	0.50±0.46	0.31	0.45±0.52	0.36±0.46	0.17	
hs-CRP (mg/L)	2.8±3.3	3.4±3.6	0.11	2.8±3.3	3.0±3.6	0.66	
BNP (pg/mL)	132±24	168±33	0.00*	132±24	128±33	0.30	
Duration of dual antiplatelet therapy (months)	11.3±1.2	11.1±1.0	0.07	11.3±1.2	11.1±1.0	0.17	
P ² Y ¹² Antiplatelet drug	Ticagrelor	37 (32.7%)	153 (32.3%)	0.91	37 (32.7%)	35 (31.0%)	0.89
	Clopidogrel	76 (67.3%)	321 (67.7%)		76 (67.3%)	78 (69.0%)	

MI: myocardium infarction; PCI: Percutaneous coronary intervention; hs-CRP: high sensitive C reaction protein; BNP: B- type natriuretic peptide.

Table 2. The procedure characteristics of the study population

		Before matching			After matching		
		OCT group(n=113)	Angiography group (n=474)	P	OCT group (n=113)	Angiography group (n=113)	P
Targeted vessel	LAD	49 (43.3%)	193 (40.7%)	0.81	51 (45.1%)	51 (45.1%)	0.97
	LCX	29 (25.7%)	135 (28.5%)		28 (24.8%)	28 (24.8%)	
	RCA	35 (31.0%)	146 (30.8%)		34 (30.1%)	34 (30.1%)	
Lesion type	A	15 (13.4%)	47 (9.9%)	0.27	15 (13.4%)	16 (14.1%)	0.96
	B1	21 (18.6%)	62 (13.1%)		21 (18.6%)	19 (16.8%)	
	B2	37 (32.7%)	174 (36.7%)		37 (32.7%)	35 (31.0%)	
	C	40 (35.3%)	191 (40.3%)		40 (35.3%)	43 (38.1%)	
RVD (mm)		2.49±0.53	2.61±0.67	0.08	2.49±0.53	2.51±0.67	0.81
Lesion length (mm)		49.3±8.5	45.7±7.9	0.00*	49.3±8.5	48.7±7.9	0.58
MLD (mm)		0.31±0.06	0.30±0.07	0.17	0.31±0.06	0.30±0.17	0.25
Stent length (mm)		52.1±7.3	49.7±6.8	0.00*	52.1±7.3	50.3±6.2	0.01*
Stents ≥ 2		53 (47.0%)	219 (46.3%)	0.92	53 (47.0%)	51 (45.1%)	0.89
At least one 2.25 mm stent used		69 (61.1%)	214 (45.1%)	0.03*	69 (61.1%)	65 (57.5%)	0.35
Post dilation		94 (83.1%)	403 (85.0%)	0.36	94 (83.1%)	96 (84.9%)	0.86
Pressure for post dilation (atm)		23.7±2.46	21.8±3.23	0.00*	23.7±2.46	21.9±2.97	0.02*
Balloon/stent ratio for post-dilation		1.26±0.33	1.12±0.21	0.00*	1.26±0.33	1.14±0.23	0.03*
DES type	1 st gen	36 (31.9%)	143 (30.2%)	0.87	36 (31.9%)	35 (31.0%)	1.00
	2 ^{sec} gen	77 (68.1)	331 (69.8%)		77 (68.1)	78 (69.0%)	

LAD: left anterior descending artery; LCX: left circumflex artery; RCA: right coronary artery; RVD: reference vessel diameter; MLD: mini lumen diameter; atm: atmosphere.

a greater balloon/stent ratio and a greater inflation pressure for post-dilation compared with the angiogroup (1.26±0.33 vs. 1.12±0.21, $P=0.00$ and 23.7±2.46 atm vs. 21.8±3.23 atm, $P=0.00$, respectively).

After propensity score matching was performed, 113 patients of each cohort were included in the analysis. The baseline clinical and laboratory characteristics on the basis of the use of OCT after matching are presented in **Tables 1**

OCT-guided PCI for small vessels

Table 3. The 1-year major adverse cardiovascular events according to OCT

	Before matching				After matching			
	OCT-group (n=113)	Angio-group (n=474)	Hazard Ratio (95% CI)	P	OCT-group (n=113)	Angio-group (n=113)	Hazard Ratio (95% CI)	P
MACE	9 (7.9%)	87 (18.4%)	0.18-0.79	0.01*	9 (7.9%)	22 (19.5%)	0.16-0.87	0.01*
Death	1 (0.9%)	5 (1.1%)	0.10-7.8	1.00	1 (0.9%)	1 (0.9%)	0.03-7.9	1.00
Myocardial Infarction	5 (4.4%)	41 (8.7%)	0.19-1.27	0.17	5 (4.4%)	9 (8.0%)	0.17-1.36	0.41
STEMI	1 (0.8%)	11 (2.3%)	0.05-2.94	0.48	1 (0.8%)	2 (1.7%)	0.04-5.54	1.00
NSTEMI	4 (3.5%)	30 (6.3%)	0.19-1.57	0.37	4 (3.5%)	7 (6.2%)	0.16-2.0	0.54
TVR	8 (7.1%)	78 (16.5%)	0.18-0.86	0.01*	8 (7.1%)	19 (16.8%)	0.16-0.90	0.04*
Definite/Probable Stent thrombosis	2 (1.7%)	11 (2.3%)	0.09-1.68	0.28	2 (1.7%)	3 (2.6%)	0.07-2.05	0.45

MACE: Major adverse cardiac events; STEMI: ST-elevation myocardial infarction; NSTEMI: non-ST-elevation myocardial infarction. TVR: Target vessel revascularization.

and 2. The c-statistic for the propensity score model was 0.72. There were no longer any relevant differences in the baseline clinical characteristics of the two groups. The frequency of multiple stent (stents ≥ 2) deployments and small stents (2.25 mm stent) deployment were not significantly different between the two groups (47.0% vs. 46.3%, $P=0.92$ and 61.1% vs. 57.5%, $P=0.35$, respectively). Although the total lengths of the lesion were no longer significantly different between the two groups after the match, the lengths of the stents were longer in the OCT-guided group than they were in the angio-guided group (52.1 ± 7.3 vs. 50.3 ± 6.2 , $P=0.01$). Moreover, as before the match, the OCT-guided PCI group had a greater balloon/stent ratio and a greater inflation pressure during post-dilation compared with the angio-group (1.26 ± 0.33 vs. 1.14 ± 0.23 , $P=0.03$ and 23.7 ± 2.46 atm vs. 21.9 ± 2.97 atm, $P=0.02$, respectively) also.

The clinical outcomes in the follow up period are shown in **Table 3**. There was one patient death in the OCT-guided group and 4 patient deaths in the angio-guided group during the follow up period, and all the deaths were recorded as a sudden death in the medical files. The rate of MACE was lower in the OCT-guided group than in the angio-guided group (9/113, 7.9% vs. 87/474, 18.4%, $P=0.001$). This difference was mostly driven by the rate of TVR, and the TVR rate was 7.1% (8/113) in the OCT-guided group, which was significantly lower than the 16.5% (78/474) in the angio-guided group ($P=0.01$).

After propensity score matching was performed, the MACE rate was lower in the OCT-guided group compared with the angio-guided

group also (7.9% vs. 19.5%, $P=0.001$). Moreover, the TVR rate in the OCT-guided group was significantly lower than it was in the angio-guided group (7.1% vs. 18.6%, $P=0.04$). The cardiac MI endpoint rates were comparable between the two cohorts (4.4% vs. 8.0%, $P=0.48$). The rate of MI was driven mainly by NSTEMI, which was 3.5% in the OCT-guided group and 6.2% in the angio-guided group ($P=0.54$). The overall stent thrombosis rate (ARC-defined definite and probable) during follow up was 2.2%, and the stent thrombosis rate was numerically lower in the OCT-guided group compared with the angio-guided group (1.7% vs. 2.6%, $P=0.45$).

The Kaplan-Meier curves of the cumulative MACE rates during the follow up in each group are shown in **Figures 1** and **2**. Log-rank analyses demonstrated that the OCT-guided group had superior results to the angio-guided group both before and after matching ($P=0.01$).

Discussion

Small and diffuse lesions have been associated with a higher incidence of adverse angiographic and clinical outcomes following the implantation of stents [6, 18-20]. Thus, strategies that can reduce the risk for stent failure for those high-risk lesion subsets are of great importance. In this analysis, the primary endpoint MACE rate of 7.9% in the OCT-guided group was significantly lower than the rate of 19.5% in the angio-guided group ($P=0.01$). This is mostly driven from the TVR rate for the OCT-guided group (6.2%), which was significant lower than the rate for the angio-guided group (13.3%, $P=0.01$). Moreover, the incidence of definite and probable stent thrombosis was not

OCT-guided PCI for small vessels

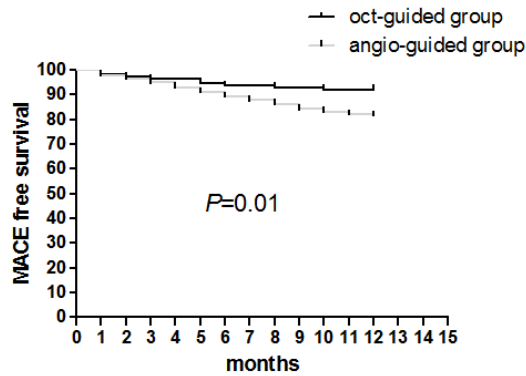


Figure 1. Kaplan-Meier survival curves for crude MACE-free survival in the OCT-guided and angio-guided groups (log-rank test, $P=0.01$). OCT-guided group means OCT-guided PCI procedure group; angio-guided means angiography guided PCI procedure group.

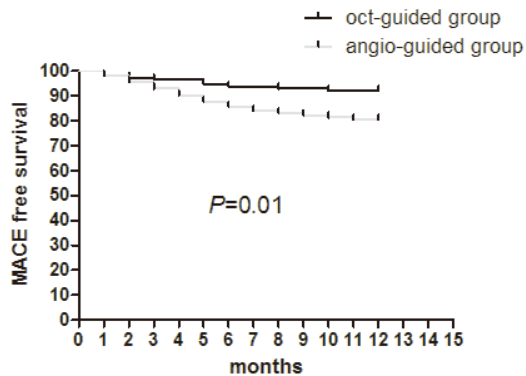


Figure 2. Kaplan-Meier survival curves for MACE-free survival in the OCT-guided and angio-guided groups after propensity score matching (log-rank test, $P=0.01$). OCT-guided group means OCT-guided PCI procedure group; angio-guided means angiography guided PCI procedure group.

significantly different between the groups, but it was numerically lower for the OCT guided group. These results support the efficacy of the OCT-guided percutaneous intervention approach for the treatment of small vessels and diffuse lesions. So far, the RCT study DOCTORS or ILUMIEN III trial [21, 22] did not show the superiority of OCT-guided PCI yet, but those more complex patients were excluded by the OCT-guided PCI RCT study. In this study, we revealed the truth that OCT-guided PCI can reduce both the rate of MACE and the rate of TVR in small and diffuse lesions after stent deployment.

Higher rates of adverse cardiac events, such as restenosis and stent thrombosis (ST), have be-

en observed in patients with small vessel CAD undergoing coronary bare metal stent (BMS) or DES placement [6, 18-20]. DES has demonstrated a clinical benefit compared to BMS. However, many trials that assessed the impact of vessel size on outcomes following treatment with DES showed that the MACE and TVR rates were significantly greater in patients with small vessels than in those with larger vessels [18, 19]. Small vessel lesions, especially long diffuse lesions within small vessels, are a subset with a high rate of revascularization after stenting [6, 20]. In this study, the cumulative TVR rate of 16.8% in the angio-guided group was relatively higher than the TVR rate of the OCT-guided group, but it is comparable to published rates for DES in small vessels. In the TAXUS V trial, the 9-month rates of MACE in the PES group were 18.9% for the patient group treated with the 2.25-mm stent [19]. In a consecutive series of 1,092 patients with a reference vessel size < 2.8 mm following the implantation of SES, the restenosis rate was 29.4% in patients with very long lesions (> 60 mm) [20]. Due to the patients in our study having more complex lesions (RVD 2.49 ± 0.53 mm with mean lesion length of 49.3 ± 8.5 mm) than those in that published study, the relatively high rates of MACE and TLR are acceptable.

For small and diffuse lesions, the size of the stent is important for optimal selection. However, the stent size is difficult to accurately select during angiography-guided PCI because the vessel diameters range from 2.00 to 2.80 mm, which are usually overestimated or underestimated when assessed by visualization [21, 22]. OCT can provide accurate and validated measurements of the lumen and vessel dimensions. In the phantom models, the OCT cross-sectional mean luminal area was found to be equal to phantom true luminal area, with a high reproducibility in OCT measurement being achieved [21-23]. In an *in vivo* study, there were strong correlations between the luminal dimensions measured by IVUS and OCT, and both modalities also demonstrated good interobserver variability [23, 24]. In this study, the stent size selection was based on the proximal and distal reference mean external elastic lamina diameters (mean vessel diameter, MVD) as published in the IVUS-guided PCI study [25, 26]. It is worth noting that the limited depth of tissue penetration with OCT resulted in many reference segments of the external elastic lam-

ina being unable to be visualized [27-29]. However, if the reference segment doesn't have too much diseased plaque, then the Mean Lumen Diameter has little difference from the Mean Vessel Diameter. To avoid the selection of stents being too small in size, the reference segment selection should be in the normal or near normal segment. We think that both the accurate diameter measured by OCT and the optimal stent size selection strategy could result in a better stent deployment and better long-term clinical outcomes following the implantation of DES.

Suboptimal stent deployment following stent implantation, such as under-expansion, incomplete stent apposition and edge dissection, is associated with an increased risk for stent thrombosis and in-stent restenosis [30, 31]. Due to lesion characteristics, suboptimal stent deployment is not rare in the small and diffuse lesion subset [20]. However, angiography provides a two-dimensional representation of a complex three-dimensional structure and only displays luminal dimensions and characteristics, while angiography alone may be inadequate in detecting all clinically relevant suboptimal stent deployments [29, 30]. The tomographic cross-sectional imaging and higher resolution of OCT confers greater sensitivity for the detection of post-procedural dissections, stent under-expansion, and malapposition. Post-PCI OCT prompts changes in the procedural strategy, which result in reductions in diameter stenosis, improved measures of stent expansion and significantly higher post-PCI fractional flow reserve values [30, 31]. In this study, although the total lengths of the lesions were no longer significantly different between the two groups after the match, the total length of the stent was longer in the OCT-guided group than in the angio-guided group, and this demonstrated that OCT provides accurate and validated information about the stenosis segment to the operators, and who would intend to make a choice of full coverage stent strategy in the OCT-guided group. It is clear that the full coverage strategy reduces geography loss and restenosis. In addition, the OCT-guided group was not associated with a higher rate of bail-out stenting compared with the angio-guided group, which has been previously reported [32, 33], and this may be due primarily to the reduced incidence of inadequate lesion coverage and stent edge-related dissection because

of an accurate stent size selection and efficient stent optimization guided by OCT. Moreover, the OCT-guided PCI group did not use more post-dilatation balloon inflations but had a greater balloon/stent ratio and inflation pressure at post-dilatation compared with the angio-guided group. This demonstrated that the stent optimization guided by OCT is more reasonable and effective than that guided by angiography.

Data reported from real-world studies of small vessel lesions treated with drug-eluting stents (DES), such as the SIRTAX37 trial, suggest that there was similar stent thrombosis seen in the SES and PES arms in small vessels (2.2% vs. 2.7%; $P=0.75$) [34]. In a sub-analysis of the RESEARCH and T-SEARCH registries, 2.2% of patients in the PES arm had acute stent thrombosis [35, 36]. In our study, although more small and complex lesions were treated, the overall defined and probable ST rate was 2.2%, which is lower than that of the published data. Although the ST rates were numerically lower in OCT-guided group, the OCT guided PCI procedure did not reduce the ST rate compared with angio-guided group as expected. The frequent use of ticagrelor and new generation stents in our study reduces the incidence of stent thrombosis to some extent and stent thrombosis is a low-probability event, so the difference of stent thrombosis between both groups may be shown in another larger sample size study.

As an observational study with a retrospective design, there are many limitations of this study that should be acknowledged. First, the decisions on the choice of treatment were not random but based on the operator's preference, so the presence of unrecognized confounders is likely. Second, there was a small cohort of patients from a single medical center, and the sample size was limited and requires a larger study to confirm these findings. Third, this trial was not based on an all-comer design, as this would lead to selection bias even after propensity scores matching.

Conclusions

Despite the aforementioned limitations, our study, for the first time in the medical literature, evaluated the impact of OCT-guided PCI on the clinical outcomes of patients with small and diffuse lesions who underwent the PCI procedure. The present results suggest that the OCT-

guided approach can improve the efficiency and safety of PCI for long diffuse coronary lesions in small vessels compared with angioguided PCI. It requires a larger prospective and a randomized trial to confirm these findings.

Disclosure of conflict of interest

None.

Address correspondence to: Dr. Guozhong Wang, Department of Cardiology, Beijing Anzhen Hospital, Capital Medical University, Beijing Institute of Heart Lung and Blood Vessel Diseases, Chaoyang District Anzhenroad 2#, Beijing 100029, China. E-mail: wgz1974@hotmail.com

References

- [1] Kastrati A, Mehilli J, Pache J, Kaiser C, Valgimigli M, Kelbæk H, Menichelli M, Sabate M, Suttorp MJ, Baumgart D, Seyfarth M, Pfisterer ME and Schomig A. Analysis of 14 trials comparing sirolimus eluting stents with bare-metal stents. *N Engl J Med* 2007; 356: 1030-1039.
- [2] Suh J, Park DW, Lee JY, Jung IH, Lee SW, Kim YH, Lee CW, Cheong SS, Kim JJ, Park SW and Park SJ. The relationship and threshold of stent length with regard to risk of stent thrombosis after drug-eluting stent implantation. *JACC Cardiovasc Interv* 2010; 3: 383-389.
- [3] Kastrati A, Dibra A, Mehilli J, Mayer S, Piniček S, Pache J, Dirschinger J and Schomig A. Predictive factors of restenosis after coronary implantation of sirolimus- or paclitaxel-eluting stents. *Circulation* 2006; 113: 2293-2300.
- [4] Choi IJ, Koh YS, Lim S, Kim JJ, Chang M, Kang M, Hwang BH, Kim CJ, Kim TH, Seo SM, Shin DI, Park MW, Choi YS, Park HJ, Her SH, Kim DB, Kim PJ, Lee JM, Park CS, Moon KW, Chang K, Kim HY, Yoo KD, Jeon DS, Chung WS and Seung KB. Impact of the stent length on long term clinical outcomes following newer-generation drug eluting stents implantation. *Am J Cardiol* 2014; 113: 457-464.
- [5] Xu B, Yang Y, Han Y, Li B, Liu Q, Zhu G, Cui J, Li L and Lu S. TCT-607 clinical outcome in Chinese patients with long lesion or small vessel/multivessel disease receiving XIENCE V everolimus-eluting stent: early results from the SEEDS study. *J Am Coll Cardiol* 2012; 60: B176-181.
- [6] Claessen BE, Smits PC, Kereiakes DJ, Parise H, Fahy M, Kedhi E, Serruys PW, Lansky AJ, Cristea E, Sudhir K, Sood P, Simonton CA and Stone GW. Impact of lesion length and vessel size on clinical outcomes after percutaneous coronary intervention with everolimus- versus paclitaxel-eluting stents pooled analysis from the SPIRIT (Clinical Evaluation of the XIENCE V Everolimus Eluting Coronary Stent System) and COMPARE (Second-generation everolimus-eluting and paclitaxel-eluting stents in real-life practice) randomized trials. *JACC Cardiovasc Interv* 2011; 4: 1209-1215.
- [7] Fujii K, Carlier SG, Mintz GS, Yang YM, Moussa I, Weisz G, Dangas G, Mehran R, Lansky AJ, Kreps EM, Collins M, Stone GW, Moses JW and Leon MB. Stent underexpansion and residual reference segment stenosis are related to stent thrombosis after sirolimus-eluting stent implantation: an intravascular ultrasound study. *J Am Coll Cardiol* 2005; 45: 995-998.
- [8] Kastrati A, Dibra A, Mehilli J, Mayer S, Piniček S, Pache J, Dirschinger J and Schig A. Predictive factors of restenosis after coronary implantation of sirolimus- or paclitaxel-eluting stents. *Circulation* 2006; 113: 2293-2300.
- [9] Iakovou I, Schmidt T, Bonizzoni E, Ge L, Sangiorgi GM, Stankovic G, Airoldi F, Chieffo A, Montorfano M, Carlino M, Michev I, Corvaja N, Briguori C, Gerckens U, Grube E and Colombo A. Incidence, predictors, and outcome of thrombosis after successful implantation of drug-eluting stents. *JAMA* 2005; 293: 2126-2130.
- [10] Topol EJ, Nissen SE. Our preoccupation with coronary luminology. The dissociation between clinical and angiographic findings in ischemic heart disease. *Circulation* 1995; 92: 2333-2342.
- [11] Mintz GS, Painter JA, Pichard AD, Kent KM, Satler LF, Popma JJ, Chuang YC, Bucher TA, Sokolowicz LE and Leon MB. Atherosclerosis in angiographically "normal" coronary artery reference segments: an intravascular ultrasound study with clinical correlations. *J Am Coll Cardiol* 1995; 25: 1479-1485.
- [12] Mintz GS. Clinical utility of intravascular imaging and physiology in coronary artery disease. *J Am Coll Cardiol* 2014; 64: 207-222.
- [13] Gonzalo N, Escaned J, Alfonso F, Nolte C, Rodriguez V, Jimenez-Quevedo P, Bañuelos C, Fernández-Ortiz A, Garcia E, Hernandez-Antolin R and Macaya C. Morphometric assessment of coronary stenosis relevance with optical coherence tomography: a comparison with fractional flow reserve and intravascular ultrasound. *J Am Coll Cardiol* 2012; 59: 1080-1089.
- [14] Kubo T, Akasaka T, Shite J, Suzuki T, Uemura S, Yu B, Kozuma K, Kitabata H, Shinke T, Habara M, Saito Y, Hou J, Suzuki N and Zhang S. OCT compared with IVUS in a coronary lesion assessment: the OPUS-CLASS study. *JACC Cardiovasc Imaging* 2013; 6: 1095-1104.
- [15] Soeda T, Uemura S, Park SJ, Jang Y, Lee S, Cho JM, Kim SJ, Vergallo R, Minami Y, Ong DS, Gao L, Lee H, Zhang S, Yu B, Saito Y and Jang IK. Incidence and clinical significance of poststent

- optical coherence tomography findings: one-year follow up study from a multicenter registry. *Circulation* 2015; 132: 1020-1029.
- [16] Thygesen K, Alpert JS, Jaffe AS, Simoons ML, Chaitman BR, White HD; Joint ESC/ACCF/AHA/WHF Task Force for the Universal Definition of Myocardial Infarction, Katus HA, Lindahl B, Morrow DA, Clemmensen PM, Johanson P, Hod H, Underwood R, Bax JJ, Bonow RO, Pinto F, Gibbons RJ, Fox KA, Atar D, Newby LK, Galvani M, Hamm CW, Uretsky BF, Steg PG, Wijns W, Bassand JP, Menasché P, Ravkilde J, Ohman EM, Antman EM, Wallentin LC, Armstrong PW, Simoons ML, Januzzi JL, Nieminen MS, Gheorghide M, Filippatos G, Luepker RV, Fortmann SP, Rosamond WD, Levy D, Wood D, Smith SC, Hu D, Lopez-Sendon JL, Robertson RM, Weaver D, Tendera M, Bove AA, Parkhomenko AN, Vasilieva EJ, Mendis S. Third universal definition of myocardial infarction. *Circulation* 2012; 126: 2020-2035.
- [17] Laskey WK, Yancy CW and Maisel WH. Thrombosis in coronary drug eluting stents: report from the meeting of the circulatory system medical devices advisory panel of the food and drug administration center for devices and radiologic health, December 7-8, 2006. *Circulation* 2007; 115: 2352-2357.
- [18] Schunkert H, Harrell L and Palacios IF. Implications of small reference vessel diameter in patients undergoing percutaneous coronary revascularization. *J Am Coll Cardiol* 1999; 34: 40-48.
- [19] Elezi S, Kastrati A, Neumann FJ, Hadamitzky M, Dirschinger J and Schömig A. Vessel size and long-term outcome after coronary stent placement. *Circulation* 1998; 98: 1875-1880.
- [20] Lee CW, Suh J, Lee SW, Park DW, Lee SH, Kim YH, Hong MK, Kim JJ, Park SW and Park SJ. Factors predictive of cardiac events and restenosis after sirolimus-eluting stent implantation in small coronary arteries. *Catheter Cardiovasc Interv* 2007; 69: 821-825.
- [21] Meneveau N, Souteyrand G, Motreff P, Caussin C, Amabile N, Ohlmann P, Morel O, Lefrançois Y, Descotes-Genon V, Silvain J, Braik N, Chopard R, Chatot M, Ecarnot F, Tauzin H, Van Belle E, Belle L and Schiele F. Optical coherence tomography to optimize results of percutaneous coronary intervention in patients with non-ST-elevation acute coronary syndrome: results of the multicenter, randomized DOCTORS study (Does Optical Coherence Tomography Optimize Results of Stenting). *Circulation* 2016; 134: 906-117.
- [22] Ali ZA, Maehara A, Génèreux P, Shlofmitz RA, Fabbiochi F, Nazif TM, Guagliumi G, Meraj PM, Alfonso F, Samady H, Akasaka T, Carlson EB, Leeser MA, Matsumura M, Ozan MO, Mintz GS, Ben-Yehuda O, Stone GW; ILUMIEN III: OPTIMIZE PCI Investigators. Optical coherence tomography compared with intravascular ultrasound and with angiography to guide coronary stent implantation (ILUMIEN III: OPTIMIZE PCI): a randomized controlled trial. *Lancet* 2016; 388: 2618-28.
- [23] Kim IC, Nam CW, Cho YK, Park HS, Yoon HJ, Kim H, Chung IS, Han S, Hur SH, Kim YN and Kim KB. Discrepancy between frequency domain optical coherence tomography and intravascular ultrasound in human coronary arteries and in a phantom in vitro coronary model. *Int J Cardiol* 2016; 221: 860-866.
- [24] D'Ascenzo F, Barbero U, Cerrato E, Lipinski MJ, Omedè P, Montefusco A, Taha S, Naganuma T, Reith S, Voros S, Latib A, Gonzalo N, Quadri G, Colombo A, Biondi-Zoccai G, Escaned J, Moretti C and Gaita F. Accuracy of intravascular ultrasound and optical coherence tomography in identifying functionally significant coronary stenosis according to vessel diameter: a meta-analysis of 2,581 patients and 2, 807 lesions. *Am Heart J* 2015; 169: 663-673.
- [25] McDaniel MC, Eshtehardi P, Sawaya FJ, Douglas JS Jr and Samady H. Contemporary clinical applications of coronary intravascular ultrasound. *JACC Cardiovasc Interv* 2011; 4: 1155-1167.
- [26] Hong SJ, Kim BK, Shin DH, Nam CM, Kim JS, Ko YG, Choi D, Kang TS, Kang WC, Her AY, Kim YH, Hur SH, Hong BK, Kwon H, Jang Y and Hong MK; IVUS-XPL Investigators. Effect of intravascular ultrasound-guided vs angiography-guided everolimus-eluting stent implantation: The IVUS-XPL randomized clinical trial. *JAMA* 2015; 314: 2155-2163.
- [27] Tahara S, Bezerra HG, Baibars M, Kyono H, Wang W, Pokras S, Mehanna E, Petersen CL and Costa MA. In vitro validation of new Fourier-domain optical coherence tomography. *EuroIntervention* 2011; 6: 875-882.
- [28] Okamura T, Onuma Y, Garcia-Garcia HM, van Geuns RJ, Wykrzykowska JJ, Schultz C, van der Giessen WJ, Ligthart J, Regar E and Serruys PW. First-in-man evaluation of intravascular optical frequency domain imaging (OFDI) of Terumo: a comparison with intravascular ultrasound and quantitative coronary angiography. *EuroIntervention* 2011; 6: 1037-1045.
- [29] Kubo T, Akasaka T, Shite J, Suzuki T, Uemura S, Yu B, Kozuma K, Kitabata H, Shinke T, Habara M, Saito Y, Hou J, Suzuki N and Zhang S. OCT compared with IVUS in a coronary lesion assessment: the OPUSCLASS study. *JACC Cardiovasc Imaging* 2013; 6: 1095-1104.
- [30] Kume T, Okura H, Miyamoto Y, Yamada R, Saito K, Tamada T, Koyama T, Neishi Y, Hayashida A, Kawamoto T and Yoshida K. Natural history of

- stent edge dissection, tissue protrusion and incomplete stent apposition detectable only on optical coherence tomography after stent implantation-preliminary observation. *Circ J* 2012; 76: 698-703.
- [31] Maehara A, Ben-Yehuda O, Ali Z, Wijns W, Bezerra HG, Shite J, Généreux P, Nichols M, Jenkins P, Witzensichler B, Mintz GS and Stone GW. Comparison of stent expansion guided by optical coherence tomography versus intravascular ultrasound: the ILUMIEN II study (observational study of optical coherence tomography [OCT] in patients undergoing fractional flow reserve [FFR] and percutaneous coronary intervention). *JACC Cardiovasc Interv* 2015; 8: 1704-1714.
- [32] Soeda T, Uemura S, Park SJ, Jang Y, Lee S, Cho JM, Kim SJ, Vergallo R, Minami Y, Ong DS, Gao L, Lee H, Zhang S, Yu B, Saito Y and Jang IK. Incidence and clinical significance of post-stent OCT findings: one year follow-up study from a multicenter registry. *Circulation* 2015; 132: 1020-1029.
- [33] Tearney GJ, Regar E, Akasaka T, Adriaenssens T, Barlis P, Bezerra HG, Bouma B, Bruining N, Cho JM, Chowdhary S, Costa MA, de Silva R, Dijkstra J, Di Mario C, Dudek D, Falk E, Feldman MD, Fitzgerald P, Garcia-Garcia HM, Gonzalo N, Granada JF, Guagliumi G, Holm NR, Honda Y, Ikeno F, Kawasaki M, Kochman J, Koltowski L, Kubo T, Kume T, Kyono H, Lam CC, Lamouche G, Lee DP, Leon MB, Maehara A, Manfrini O, Mintz GS, Mizuno K, Morel MA, Nadkarni S, Okura H, Otake H, Pietrasik A, Prati F, Räber L, Radu MD, Rieber J, Rigà M, Rollins A, Rosenberg M, Sirbu V, Serruys PW, Shimada K, Shinke T, Shite J, Siegel E, Sonoda S, Suter M, Takarada S, Tanaka A, Terashima M, Thim T, Uemura S, Ughi GJ, van Beusekom HM, van der Steen AF, van Es GA, van Soest G, Virmani R, Waxman S, Weissman NJ and Weisz G; International Working Group for Intravascular Optical Coherence Tomography (IWG-IVOCT). Consensus standards for acquisition, measurement, and reporting of intravascular optical coherence tomography studies: a report from the international working group for intravascular optical coherence tomography standardization and validation. *J Am Coll Cardiol* 2012; 59: 1058-1072.
- [34] Togni M, Eber S, Widmer J, Billinger M, Wenaweser P, Cook S, Vogel R, Seiler C, Eberli FR, Maier W, Corti R, Roffi M, Lüscher TF, Garachemani A, Hess OM, Wandel S, Meier B, Jüni P and Windecker S. Impact of vessel size on outcome after implantation of sirolimus-eluting and paclitaxel-eluting stents: a subgroup analysis of the SIRTAX trial. *J Am Coll Cardiol* 2007; 50: 1123-1131.
- [35] Rodriguez-Granillo GA, Valgimigli M, Garcia-Garcia HM, Ong AT, Aoki J, van Mieghem CA, Tsuchida K, Sianos G, McFadden E, van der Giessen WJ, van Domburg R, de Feyter P and Serruys PW. One year clinical outcome after coronary stenting of very small vessels using 2.25 mm sirolimus- and paclitaxel-eluting stents: a comparison between the RESEARCH and T-SEARCH registries. *J Invasive Cardiol* 2005; 17: 409-412.
- [36] Tanimoto S, Daemen J, Tsuchida K, García-García HM, de Jaegere P, van Domburg RT and Serruys PW. Two-year clinical outcome after coronary stenting of small vessels using 2.25 mm sirolimus- and paclitaxel-eluting stents: insight into the RESEARCH and T-SEARCH registries. *Catheter Cardiovasc Interv* 2007; 69: 94-103.