Int J Clin Exp Med 2019;12(6):7209-7216
www.ijcem.com /ISSN:1940-5901/IJCEM0083131

Original Article

Expression of MMP-9 and TIMP-1 in rat models of pressure ulcer and their significance

Yi-Qing Tian[1], Xiao-Hui Ning[2], De-Yun Yin[3], Ya-Nan Zhang[4], Zhi-Hong Zhao[4], Yao Wang[4], Yan-Ling Li[5], Xian Li[4]

[1]Department of Performance Appraisal, [2]Third Department of Geriatric, [3]Sixth Department of Cardiovascular Diseases, [4]Department of Nursing, Hebei General Hospital, Shijiazhuang, China; [5]Department of Tuberculosis, Affiliated Hospital of Hebei University, Baoding, China

Received August 30, 2017; Accepted February 12, 2019; Epub June 15, 2019; Published June 30, 2019

Abstract: Aim: The goal of this study was to investigate the expression of matrix metalloproteinase-9 (MMP-9) and tissue inhibitor of metalloproteinase-1 (TIMP-1) in rat models of pressure ulcer and to assess their significance. Methods: Sixty-four rats were randomly divided into 8 groups with 8 rats in each group. A pressure on the muscle and skin was produced by embedding an iron piece under the gluteus muscle and placing a circular magnet on the body to generate local tissue ischemia. The magnet was removed after each pressure for 2 hours, followed by blood perfusion for 0.5 hours. These steps were repeated for 5 cycles every day and the steps were repeated in the next morning to establish pressure ulcer models in rats with different stages. MMP-9 and TIMP-1 expression in the pressure ulcer tissues were determined by immunohistochemistry. Results: There was no detectable expression of MMP-9 and TIMP-1 in the pressure ulcer tissues of the blank and control groups. With progression of the pressure ulcer, MMP-9 expression gradually increased, while TIMP-1 expression first increased but then decreased. Conclusions: Increased MMP-9 expression and the imbalance of MMP-9/TIMP-1 expression may contribute to the initiation and progression of pressure ulcer.

Keywords: MMP-9, TIMP-1, pressure ulcer, rat model, tissue

Introduction

The incidence of hospital pressure ulcer has increased greatly with the arrival of aging population in the world. It has been estimated that the pressure ulcer incidence of outpatients and inpatients in USA are 5% and 1.4%, respectively [1-5]. According to the study of Eberlein-Gonskade et al. [6], pressure ulcer incidence rates of outpatients and inpatients in Germany are 1.21% and 0.78%, respectively. In China, the incidence of pressure ulcer in hospital is 0.628% [7]. The occurrence of pressure ulcer not only increases the patient's pain and financial burden, but also extends the length of stay. Importantly, serious cases may lead to infection or death. Therefore, development of a rapid and effective treatment for pressure ulcers is a global goal for both clinicians and nurses. Pressure ulcer formation is associated with loss of balance between matrix metalloproteinases (MMPs) and matrix metalloproteinase inhibitors. matrix metalloproteinase-9 (MMP-9) is a member of MMP family and plays an important role in maintain the integrity of extracellular matrix in pressure ulcer tissues [13]. Tissue inhibitor of metalloproteinase-1 (TIMP-1) forms a complex with MMP-9 thereby inhibiting the activity of MMP-9 [15]. However, the role of MMP-9 and TIMP-1 in the pathology of pressure ulcer is largely unknown. To identify potential targets for the prevention and treatment of pressure ulcer, in this study, expression of MMP-9 and TIMP-1 in pressure ulcers of different stages in rat models was investigated, and the relationship between MMP/TIMP expression and the severity of pressure ulcers was examined.

Materials and methods

Animals

The Animal Committee of Hebei Province Experimental Animal Management Committee approved all the experimental protocols and

animal handling procedures. All experimental procedures and postoperative animal care were conducted in accordance with the National Institute of Health's Guidelines for the Care and Use of Laboratory Animals. Adult male Sprague-Dawley rats (body weight, 380 ± 20 g) were purchased from Experimental Animal Center of Hebei Medical University (Animal certificate number 1607106, Shijiazhuang, China). All rats were maintained on a 12 hour light/dark cycle in a temperature room at 20-25°C and allowed free access to food and water before treatment.

Instruments and reagents

Disc-shaped iron tablets (Diameter 15 mm, thickness 0.3 mm, weight 0.6 g, autoclave sterilization) and circular magnets (Diameter 15 mm, thickness 5.0 mm, weight 2.6 g, magnetic flux up to 1500 Gauss) were purchased from Hebei Super-strong Magnetic Industry Technology (No. 3, North Street of Victory Freeport Negative Layer Area A, Shijiazhuang). Anti MMP-9 (PAA553Ra01) and TIMP-1 (PAA552-Ra01) antibodies were purchased from Cloud-Clone (Export Processing Zone, Wuhan, China).

Establishment of rat models of pressure ulcers of different stages

The rats were fed with standard feed (Experimental Animal Center of Hebei Medical University) for one week. Sixty-four rats were randomly divided into 8 groups with 8 rats in each group: blank, control, first-stage, second-stage, deep injury, three-stage, non-stage and four-stage groups. There was no significant weight difference among the rats ($P > 0.05$). Rat pressure ulcer models were established according to previously published molding of iron plate with external magnet pressing [8, 9]. In brief, after one week of adaptive feeding, the rats in eight groups were fasted for 8 hours and were anesthetized with 10% chloral hydrate (0.3 ml/100 g) via intraperitoneal injection. The hair on the back midline hips on both sides was removed with hair removal agent (8 g NaS + 20 ml alcohol + 80 ml water) to prepare a skin area of 4 cm × 4 cm. After disinfection with 5% povidone iodine, a 2 cm incision in the surgical area in the left hip near the head was cut. After separating the fascia and tissues with blunt tweezers, sterile iron tablets were placed underneath the muscle. The cut was sutured with a 4-0 Dexon polyglycolic acid suture and the sutures were disinfected with 5% povidone iodine to prevent infection. Round magnets were placed outside to produce pressure on the muscles and skin, resulting in local tissue ischemia. The magnet was removed after each pressure for 2 hours, followed by blood perfusion for 0.5 hours. These steps were repeated for 5 cycles every day and the steps were repeated in the next morning to establish pressure ulcer models in rats with different stages. Eight groups of rats were implanted with iron tablets at the same time. The pressure ulcer model of stage-4 was first established, following by non-stage, three-stage and so on. To reduce the influence of the iron sheet on the experimental results, rats in eight groups were killed at the same time to ensure the same time of implantation of iron tablets in each group.

Histology observation

The pathological changes in pressure ulcer tissues were assessed by H&E staining. MMP-9 and TIMP-1 levels were determined by immunohistochemical method. The primary antibodies were diluted at 1:200. Positive MMP-9 and TIMP-1 were stained brown in the cytoplasm or membrane. The results of immunohistochemistry were observed under a light microscope with magnification of 400. For each group, the number of positive cells in random five fields of vision of 3 slides was counted and expressed as percentage for MMP-9 and TIMP-1, respectively. The ratio of MMP-9/TIMP-1 was calculated.

Statistical analysis

All data were analyzed using SPSS19.0 statistical software. Measurement data are presented as mean ± SD (standard deviation). Normality test and homogeneity test of variance were performed for each set of data. The data between the two groups were in accordance with the normal distribution and variance. Comparison was made by *t* test between two groups and by one-way analysis of variance among multiple groups. Comparisons were made between pairs in each group and a *P* value of < 0.05 was considered statistically significant.

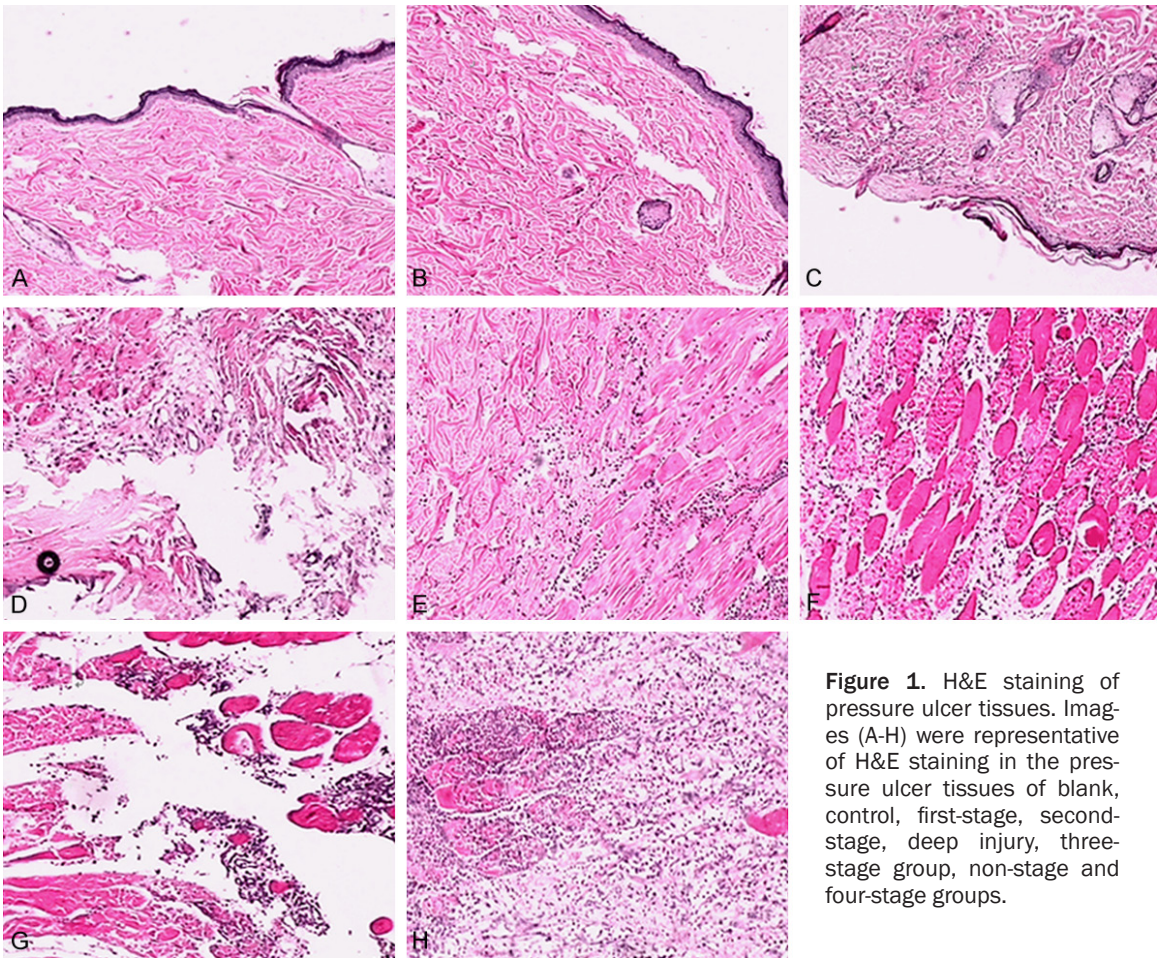

Figure 1. H&E staining of pressure ulcer tissues. Images (A-H) were representative of H&E staining in the pressure ulcer tissues of blank, control, first-stage, second-stage, deep injury, three-stage group, non-stage and four-stage groups.

Results

Pathological alterations of different stages of pressure ulcer models

According to the established previously pressure ulcer models [8, 9], 1 cycle of magnetic press results in stage-1 pressure ulcer; five cycles result in stage-2; 15-20 cycles result in deep injury; 20 cycles result in stage-3; 20-25 cycles result in non-staging; 30 cycles form stage-4 pressure ulcer. During the experiments, only one rat died in the first-stage group, which may be caused by the injury of internal organs or overdose of the anesthetic.

Successful establishment of pressure ulcer models included the following criteria. Stage-1: under naked eye observations, the pressure red in the pressure parts of the integrity skin did not fade following pressure; compared with the surrounding tissue, the pressure red site might have increased pain or skin temperature. Under pathological observation, there was loss of local surface squamous epithelium, residual squamous epithelium thinning, epidermal local vesicular ulcer, epidermal focal neutrophil aggregation, and dermal layer of lymphocytes infiltration.

Stage-2: In the pressure site of the skin, there was dark red color, swelling, no bleeding pus, obvious local skin pain when be pressed; under pathological observation, there was an absence of most of the epidermis, multifocal ulcers deep within the dermis, dermis was with moderate lymphocytes and neutrophil infiltration, dermal collagen fibrosis, and lots of inflammatory cell infiltration.

Deep tissue injury: local skin was integrity with purple or black color, increased redness around the pressure sites with swelling and a small amount of light yellow tissue fluid, significant pain, and increased skin temperature; under pathological observation, most of the epidermis was absent, and there was multifocal ulcer formation deep within the dermis, the dermis

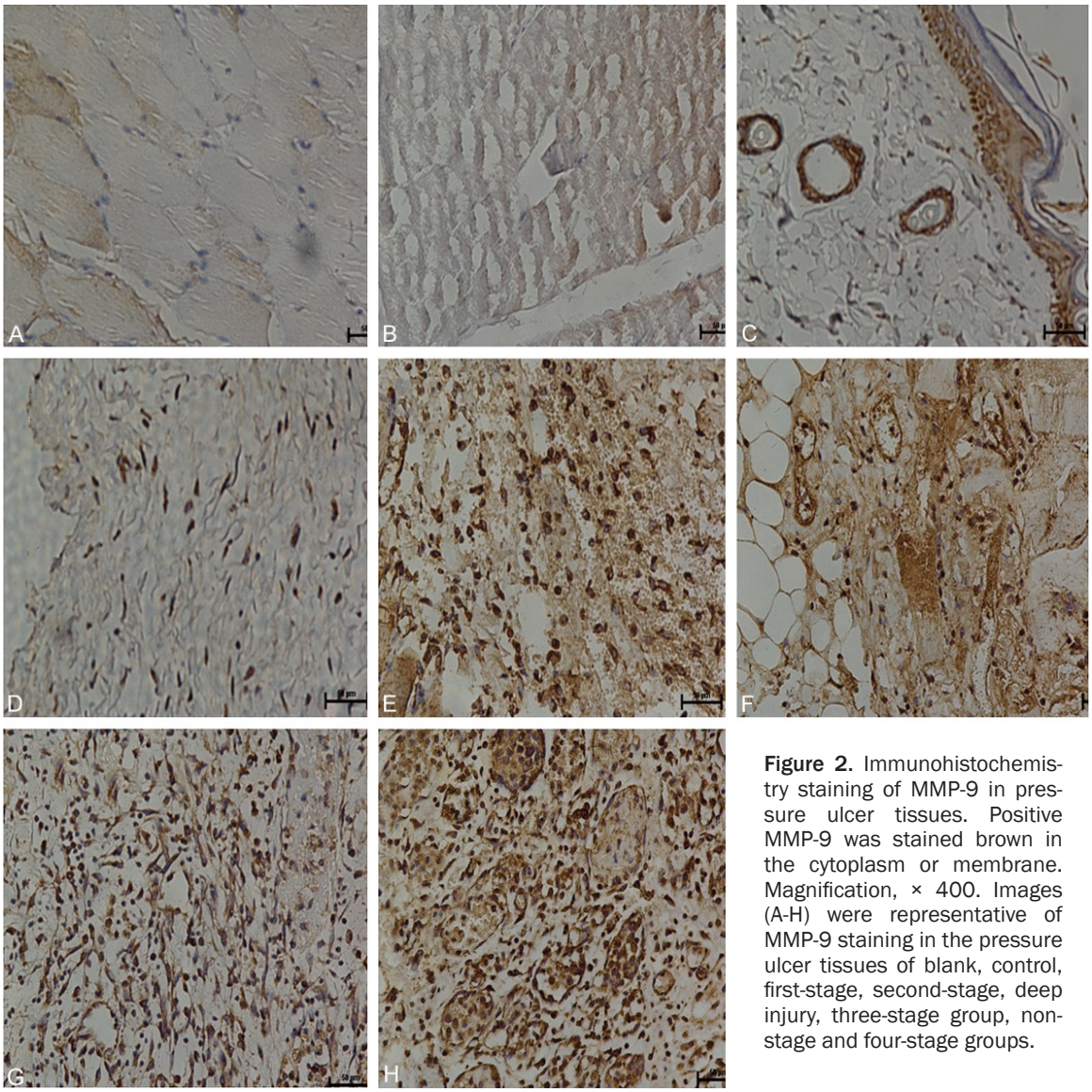

Figure 2. Immunohistochemistry staining of MMP-9 in pressure ulcer tissues. Positive MMP-9 was stained brown in the cytoplasm or membrane. Magnification, × 400. Images (A-H) were representative of MMP-9 staining in the pressure ulcer tissues of blank, control, first-stage, second-stage, deep injury, three-stage group, non-stage and four-stage groups.

layer contained local inflammatory infiltrate accompanied by focal pyogenic, gluteus maximus sarcoplasmic dissolution, disappearance of striated muscle, and a number of lymphocytes and neutrophil invasion.

Stage-3: the skin at pressure site became black and hardening, and there was no bleeding and no pain in response to acupuncture. After removal of the black debris, the skin showed fat but the muscles, tendons or bones could not be seen. Under pathological observation, and the surface squamous epithelium was missing, the dermal layer became thinning with lymphocytes and granulocyte invasion. Moreover, local ulcers reaching deep within the muscle with part of the gluteus maximus atrophy fibrosis, and deep muscle lymphocyte mononuclear cell infiltration.

Non-staging: the skin at pressure site became black and hardening, and there was no bleeding and no pain in response to acupuncture [10]. There was peripheral leaking yellow liquid. After removal of the necrotic tissue and scar, there was the overflow pus exposing the surface muscles. Under pathological observation, epidermis and dermis disappeared, which was replaced by granulation tissue accompanied with severe inflammation and hemorrhage. The gluteus maximus underwent atrophy or even disappeared, with deep muscle atrophy, and disappearance of stripes with fibrosis and chronic inflammation.

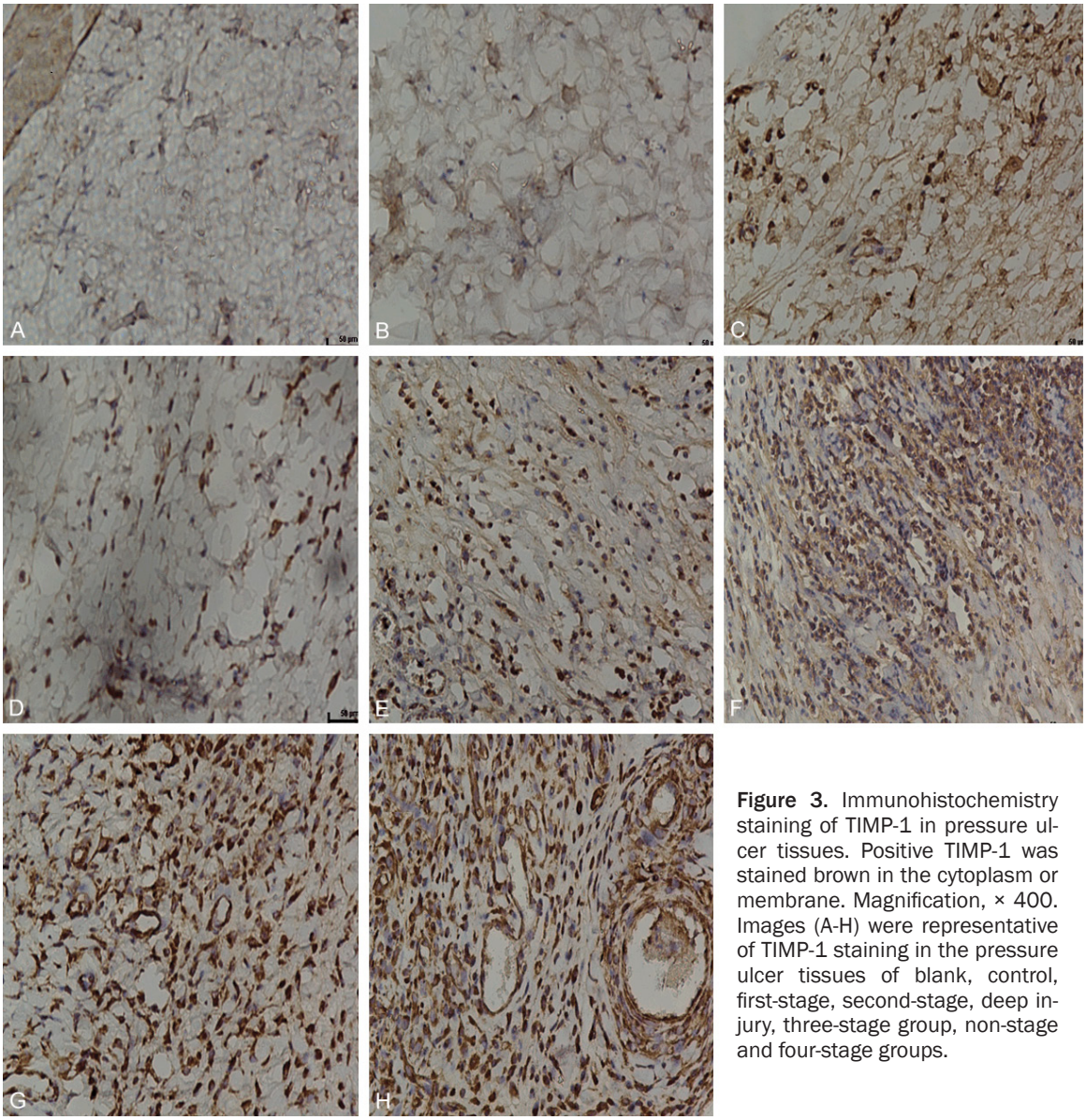

Figure 3. Immunohistochemistry staining of TIMP-1 in pressure ulcer tissues. Positive TIMP-1 was stained brown in the cytoplasm or membrane. Magnification, × 400. Images (A-H) were representative of TIMP-1 staining in the pressure ulcer tissues of blank, control, first-stage, second-stage, deep injury, three-stage group, non-stage and four-stage groups.

Stage-4: There were erosion and swelling at the edge of iron plates, with edema, exudates, oozing, or necrosis, which were accompanied with iron exposure or slippage. There was no pain in response to acupuncture. The skin became hard or black scar, accompanied by bone, tendon, or muscle exposure; under pathological observation, the epidermis, dermis, and gluteus maximus disappeared with the deep muscle multi-focal inflammatory necrosis, superlative inflammation, some interstitial edema bleeding and large fibrosis.

Expression of MMP-9 and TIMP-1 in pressure ulcer tissues

There was no detectable expression of MMP-9 and TIMP-1 in the pressure ulcer tissues of the blank and control groups. With the advance of pressure ulcer degree, MMP-9 expression gradually increased (**Figures 1**, **2**, **4** and **Table 1**). TIMP-1 expression first increased but then decreased with the advance of pressure ulcer degree (**Figures 3**, **4** and **Table 1**). The ratio was gradually upregulated with the increasing degree of pressure ulcer (**Table 1**).

Discussion

The European Pressure Sores Advisory Council (EPUAP) guideline changed the original 'pressure ulcer' to 'pressure injury' in 2014 and defined that pressure injury is a localized lesion of the skin and/or underlying subcutaneous soft tissue that typically occurs in the bone pro-

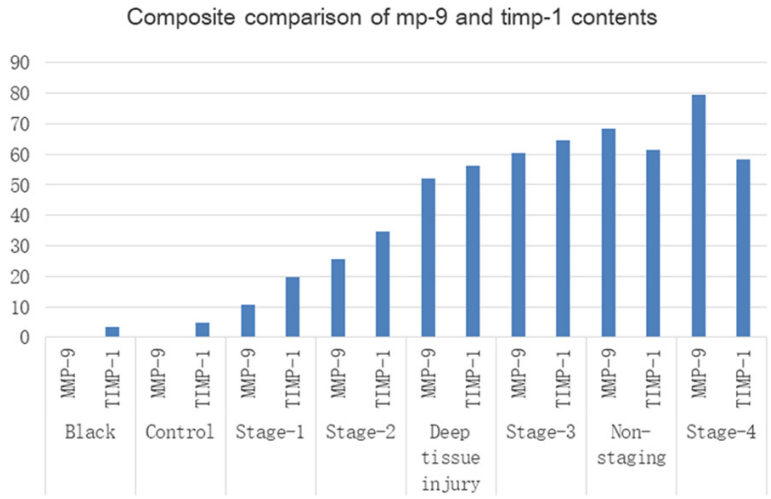

Figure 4. Expression level of MMP-9 and TIMP-1 in the pressure ulcer tissues of different stages.

trusion or injury associated with a medical or other medical device. This stress lesion may be characterized by localized tissue damage but with intact or open ulcerations and possibly accompanied by pain. Severe and/or prolonged stress or pressure combined with shear stress can lead to injury [11]. The tolerance of subcutaneous soft tissue to stress and shear stress is affected by environmental, nutritional, perfusion, complications and soft tissue conditions [11]. Pressure ulcers are a great harm to human health and thus it is thus essential to study the injury mechanism of the formation of pressure ulcer and to find effective targets for the prevention and treatment of pressure ulcers [12].

Matrix metalloproteinase (MMP) is a group of proteases that degrade extracellular matrix (including various types of collagen, gelatin, elastin, fibrin, etc.) and is regulated by many cytokines. MMPs play an important role in the physiological processes such as tissue remodeling and the pathological processes of many diseases [13]. MMP-9 is a member of the MMP family and excessive MMP-9 expression results in degradation of extracellular matrix leading to irreversible injury of pressure ulcer tissues [13]. In the present study, expression of MMP-9 was significantly increased in the local pressure tissue with the increase of pressure cycle. Accordingly, the extracellular matrix components such as collagen and elastin were degraded in the local pressure tissues, and the skin and muscle tissues increased the vulnerability to external forces. Consistent with our results, it has been reported that in chronic wounds, the activity of MMP-9 was nearly 125-fold higher than that of the acute wounds and the growth factor level was significantly lower [14]. Since pressure ulcer is also a chronic wound, it is possible that the high expression of MMP-9 during the formation of pressure sores can accelerate the irreversible development of tissue damage through the decomposition of growth factors.

Many studies have shown that TIMP-1 and MMP-9 are closely related [15]. TIMP-1 is mainly produced by inflammatory cells and connective tissue cells and is widely expressed in tissues and body fluids. The main function of TIMP-1 is to form a complex with MMP-9 thereby inhibiting the activity of MMP-9. However, expression of TIMP-1 was also controlled by MMP-9 and overexpression of MMP-9 inhibited secretion of TIMP-1, forming a vicious cycle to promote the occurrence and development of pressure ulcers [16]. In this study, expression of TIMP-1 increased first and then decreased with the increase of pressure cycles and the severity of pressure sores. Therefore, the increased expression of MMP-9 in turn may inhibit the expression of TIMP-1, exacerbating the progression of pressure ulcers.

In normal skin tissue, the ratio of MMP-9/TIMP-1 is low and has little effect on normal skin. However, under the influence of trauma and inflammation, inflammatory cells and repair cells synthesize MMP-9 and increase MMP-9/TIMP-1 ratio to precisely regulate tissue homeostasis [16]. In the present study, the ratio of MMP-9/TIMP-1 was found to be increased with the degree of pressure sores, suggesting that an imbalance of MMP-9/TIMP-1 was an important factor in the development of pressure sores. Currently, many scholars have found that some growth factors in the treatment of pressure sores cannot achieve the desired effect, which may be associated with local increased MMPs accelerating growth factor degradation [12, 17, 18]. Therefore, combination with intervention with growth factors and inhibitors of MMPs in early stage of pressure sore may achieve the inhibition of MMPs activity, thereby

Table 1. Positive expression level of MMP-9 and TIMP-1 in the pressure ulcer tissues of different stage (X ± SD)

Group Animal	No.	MMP-9	TIMP-1	MMP-9/TIMP-1 ratio
Black	8	0.0 ± 0.0(3),(4),(5),(6),(7),(8)	3.5 ± 2.27(3),(4),(5),(6),(7),(8)	0.0 ± 0.0(2),(3),(4),(5),(6),(7),(8)
Control	8	0.3 ± 0.48(3),(4),(5),(6),(7),(8)	4.7 ± 1.16(3),(4),(5),(6),(7),(8)	0.07 ± 0.13(1),(3),(4),(5),(6),(7),(8)
Stage-1	7	10.8 ± 3.58(1),(2),(5),(6),(7),(8)	19.8 ± 2.90(1),(2),(5),(6),(7),(8)	0.56 ± 0.23(1),(2),(4),(5),(6),(7),(8)
Stage-2	8	25.5 ± 9.59(1),(2),(5),(6),(7),(8)	34.6 ± 7.63(1),(2),(5),(6),(7),(8)	0.76 ± 0.29(1),(2),(3),(6),(7),(8)
Deep tissue injury	8	51.9 ± 9.61(1),(2),(3),(8)	56.3 ± 9.50(1),(2),(3),(5),(6),(7),(8)	0.94 ± 0.22(1),(2),(3),(7),(8)
Stage-3	8	60.3 ± 15.28(1),(2),(3),(4)	64.5 ± 9.48(1),(2),(3),(4)	0.94 ± 0.26(1),(2),(3),(4),(7),(8)
Non-staging	8	68.5 ± 7.94(1),(2),(3),(4)	61.6 ± 14.56(1),(2),(3),(4)	1.17 ± 0.28(1),(2),(3),(4),(5),(6)
Stage-4	8	79.6 ± 9.52(1),(2),(3),(4)	58.2 ± 17.77(1),(2),(3),(4)	1.41 ± 0.27(1),(2),(3),(4),(5),(6)

(1) Indicates that each group was $P < 0.05$ compared with the blank group; (2) each group showed $P < 0.05$ compared with the control group; (3) each group showed $P < 0.05$ compared with the stage-1 group; (4) each group showed $P < 0.05$ compared with the stage-2 group; (5) each group showed $P < 0.05$ compared with the deep injury group; (6) each group showed $P < 0.05$ compared with the stage-3 group; (7) each group showed $P < 0.05$ compared with the non-staging group; (8) each group showed $P < 0.05$ compared with four-stage group.

preventing the development of deep pressure sores.

In summary, this study demonstrates that dynamic expression of MMP-9 and TIMP-1 in the progression of pressure ulcers results in an altered MMP-9/TIMP-1 balance, which is an important factor in the development of pressure sores. Our findings suggest that pharmacological inhibition of MMP-9 expression and tilting the MMP-9/TIMP-1 ratio may be a promising strategy for the prevention and treatment of pressure ulcers.

Disclosure of conflict of interest

None.

Address correspondence to: Xian Li, Department of Nursing, Hebei General Hospital, 348 West Heping Road, Shijiazhuang 050051, China. Tel: +86-311-85988114; E-mail: qcy2r3@163.com

References

[1] Thomas DR. Clinical management of pressure ulcers. Clin Geriatr Med 2013; 29: 397-413.

[2] VanGilder C, Amlung S, Harrison P and Meyer S. Results of the 2008-2009 international pressure ulcer prevalence survey and a 3-year, acute care, unit-specific analysis. Ostomy Wound Manage 2009; 55: 39-45.

[3] Lyder CH, Wang Y, Metersky M, Curry M, Kliman R, Verzier NR and Hunt DR. Hospital-acquired pressure ulcers: results from the national medicare patient safety monitoring system study. J Am Geriatr Soc 2012; 60: 1603-8.

[4] Tschannen D, Bates O, Talsma A and Guo Y. Patient-specific and surgical characteristics in the development of pressure ulcers. Am J Crit Care 2012; 21: 116-25.

[5] Gunningberg L, Donaldson N, Aydin C and Idvall E. Exploring variation in pressure ulcer prevalence in Sweden and the USA: benchmarking in action. J Eval Clin Pract 2012; 18: 904-10.

[6] Eberlein-Gonska M, Petzold T, Helaß G, Albrecht DM, Schmitt J. The incidence and determinants of decubitus ulcers in hospital care: an analysis of routine quality management data at a university hospital. Dtsch Arztebl Int 2013; 110: 550-6.

[7] X JY, Chen YJ, Su CY, Guo XJ, Guan XP, Zhu YJ, Jia J, Bai SP, Zhang R, Liu L, Xu L, Wu LY and Liu Y. The current prevention status and intervention strategies of pressure ulcer in multi - center hospitals. Chinese Journal of Nursing 2013; 48: 724-726.

[8] Wassermann E, van Griensven M, Gstaltner K, Oehlinger W, Schrei K and Redl H. A chronic pressure ulcer model in the nude mouse. Wound Repair Regen 2009; 17: 480-4.

[9] Chinese Nursing Association Stoma, Wound, Wet Care. Professional Committee of Chinese Pressure Sore Care Guidance 2013; 6-10.

[10] Reid RR, Sull AC, Mogford JE, Roy N and Mustoe TA. A novel murine model of cyclical cutaneous ischemia-reperfusion injury. J Surg Res 2004; 116: 172-80.

[11] EPUAP2014 Pressure Sore Care Guide. AmeriCan Pressure Ulcer Advisory Committee and European Pressure Sores Advisory Council 2014.

[12] Wang Y, Chen J and Jiang L. The expression and function of hypoxia - inducible factor-1a and matrix metalloproteinase-9 in early pressure ulcer. Journal of Nursing 2012; 27: 3-6.

[13] Matresian LM. The matriX degrading metalloproteinascs. Bioessays 1992; 14: 455-63.
[14] Yager DR, Chen SM, Ward SI, Olutoye OO, Diegelmann RF, Kelman Cohen I. Ability of chronic wound fluids to degrade peptide growth factors is associated with increased levels of elastase activity and diminished levels of proteinase inhibitors. Wound Repair Regen 1997; 5: 23-32.
[15] Wu ZY and Yao LP. Advances in research of the relationship between MMP-9/TIMP-1 and pathogenesis of kawasaki disease. Medical Innovation of China 2016; 13: 83-86.
[16] Madlener M, Parks WC and Werner S. Matrix metalloproteinases (MMPs) and their physiological inhibitors (TIMPs) are differentially expressed during excisional skin wound repair. Exp Cell Res 1998; 242: 201-10.
[17] Xie XY. Using a technique called RNA interference to silence a rat skin fibroblasts of MMP9 synthesis. Sun Yat-sen University 2009; 1-2.
[18] Zhang Y, Zhu P and Xu G. Mechanism involved in use of Aloe vera gel to promote the healing of the wound in diabetic ulcer. Chinese Journal of Gerontology 2015; 2: 428-430.