Int J Clin Exp Med 2019;12(6):7914-7916
www.ijcem.com /ISSN:1940-5901/IJCEM0085912

Case Report

Unusual cause of colonic perforation secondary to an eel: a case report and literature review

Hui-Ming Yao[1*], Liang Huang[2*], Xiao-Lei Wang[3], Yang Li[2]

Departments of [1]Respiratory and Critical Care Medicine, [2]Emergency Medicine, The First Affiliated Hospital of Nanchang University, No. 17 Yongwaizheng Street, Donghu District, Nanchang 330006, Jiangxi Province, China; [3]Second Department of Cardiovascular Medicine, Jiangxi Provincial People's Hospital, No. 92 Aiguo Road, Donghu District, Nanchang 330006, Jiangxi Province, China. [*]Equal contributors.

Received September 24, 2018; Accepted April 8, 2019; Epub June 15, 2019; Published June 30, 2019

Abstract: Colonic perforation is a common presentation at the emergency department. However, foreign-body-related perforation is responsible for < 1% of these cases. Here we describe a case of colonic perforation secondary to self-introduction of an eel into the anus. A 54-year-old previously healthy man presented himself to the emergency department with a 12 hour history of abdominal pain. Physical examination revealed abdominal tenderness, rebound tenderness, and involuntary guarding. A computed tomography (CT) scan of his abdomen and pelvis revealed a foreign body in the abdominal cavity. Upon further questioning, the patient admitted an eel was inserted into his anus by accident. The patient underwent a laparotomy, and the eel was subsequently removed. He was transferred to the standard ward from the emergency intensive care unit after 7 days without postoperative complications. Diagnosing a colonic foreign body can be challenging as patients often deny the insertion. A CT scan is recommended for patients suspected of having a colonic foreign body.

Keywords: Colonic perforation, eel, foreign body

Introduction

Colonic perforation may occur in a variety of clinical scenarios with the most common reasons being diagnostic and therapeutic colonoscopies. Severe acute appendicitis, colorectal cancer, or diverticulitis may also lead to colonic perforation. Foreign bodies generally travel through the intestinal tract smoothly, and it has been reported that foreign-body-related perforation is responsible for < 1% of such cases [1]. However, to the best of our knowledge, insertion of a live animal into the colon resulting in colonic perforation has only been reported once in current English literature [2]. Here, such a case of colonic perforation is presented that is secondary to a foreign body in a middle-aged male who complained of acute abdominal pain.

Case report

A 54-year-old previously healthy man presented at the emergency department with a 12 hour history of lower abdominal pain. His vital signs were as follows: blood pressure 13.5/9.6 kPa, pulse rate 125 beats/min and rectal temperature 36.7°C. A physical examination revealed abdominal tenderness, rebound tenderness, and involuntary guarding. A CT scan and three-dimensional reconstruction of the abdomen revealed a snake-shaped foreign body extending from the lower abdomen into the left upper quadrant (**Figure 1**). Upon further questioning, the patient admitted that an eel was inserted into his anus by accident before the onset of severe pain. The patient underwent a laparotomy under general anesthesia to extract the eel. During surgery, an eel, measuring 50 cm in length, was visualized and removed. The eel is snake-shaped and the widest part is up to 4 cm in diameter (**Figure 1**). A sigmoidostomy was successfully performed through the extra-peritoneal route. After surgery, the patient was treated with nutritional support therapy and broad-spectrum antimicrobial agents and was transferred to a regular ward from the emergency intensive care unit after 7 days with-

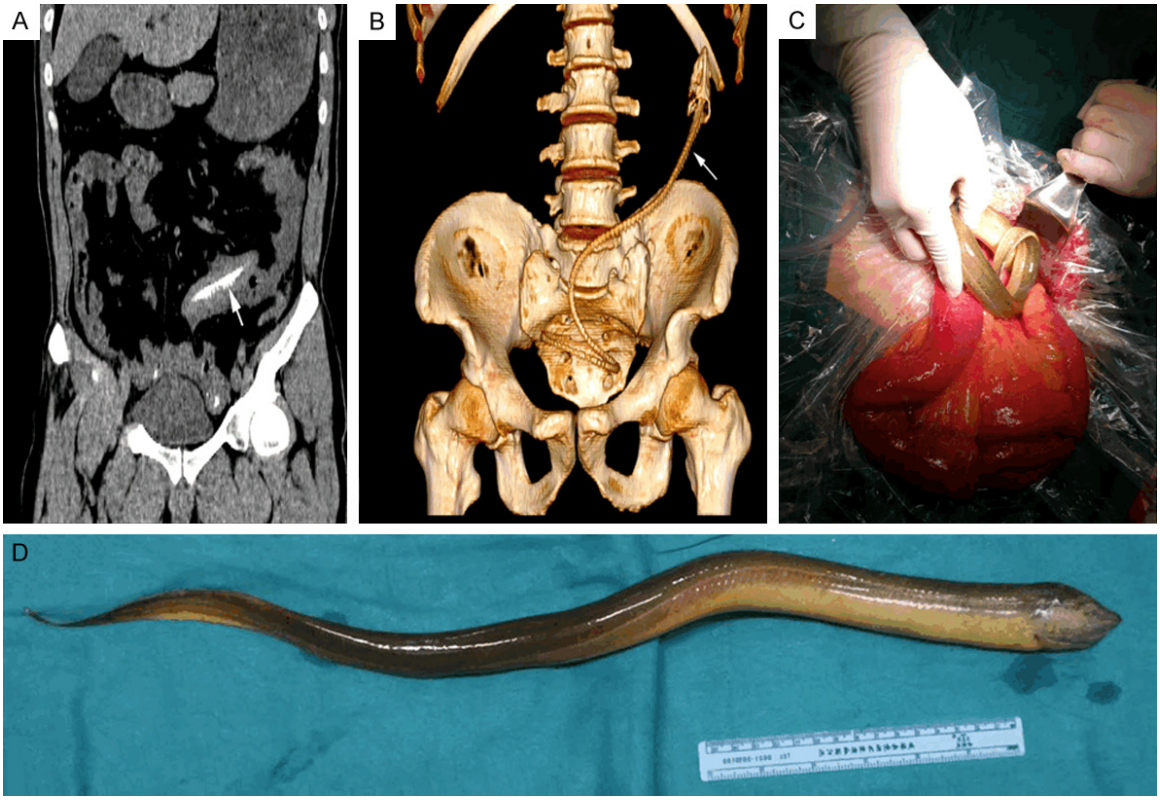

Figure 1. Colonic perforation secondary to an eel. A. Coronal view of abdominal computed tomography images pretreatment. The arrowhead demonstrates a foreign body in the abdominal cavity. B. Three-dimensional reconstruction of abdominal computed tomography images. The arrowhead shows a snake-shaped foreign body extending from the lower abdomen into the left upper area. C, D. The eel was extracted and measured 50 cm in length and 4 cm in diameter.

out postoperative complications. At follow-up 4 weeks later, the patient remained asymptomatic.

Discussion

Self-introduction of an eel into the anus causing colonic perforation is uncommon. When it occurs, the reason may be related to a bizarre belief, an inadvertent sexual behavior, or a criminal assault [3]. Other known types of foreign bodies reportedly self-introduced have included fish bones, crab shells, chicken bones, vibrators, bottles, and metal rods [2, 4]. The situation is more common in men (4:1 or 5:1).

Eels are elongated fish, ranging in length from 5 cm for the one-jawed eel to 4 m for the slender giant moray. Known to have both medical and culinary uses, they lack macroscopic scales and are surrounded by a thick layer of mucus similar in function to mammal mucus [5]. Eels are euryhaline teleosts that inhabit pools, aquaria, or natural water bodies throughout their life cycle and are thus in contact with a great variety of microorganisms [6]. Once a live eel is inserted into the colon, it will bite the wall of the colon, migrating into the abdominal cavity through the perforation, resulting in an accidental or opportunistic human pathogen similar to a Vibrio vulnificus infection [7]. There are reports of wild eels held in zoological collections being diagnosed with lead toxicosis following ingestion of lead anchor strips used in the packaging and display of freshwater aquarium plants [8]. The issue of whether lead toxicosis has a role in the initial presentation of the perforation is still uncertain.

Diagnosing a colonic foreign body can be challenging because patients often deny the insertion. They may have obscure anal pain, mucous discharge, lax anal tone, and fresh bleeding from the rectum. The most common presenting clinical features of colonic perforation are peritoneal irritation with rebound tenderness and

rigidity of the abdomen, accompanied by fever and tachycardia. These features should raise the suspicion of the presence of a colonic foreign body. Plain radiographs are usually diagnostic of perforations, however a CT scan is recommended if the findings are not definitive or if the presence of a foreign body cannot be ruled in or out by radiographs alone [9].

To date, documentation of an eel-related intestinal tract perforation has been limited [2]. In this report [2], an emergency laparotomy revealed a perforation found over the anterior wall of the rectum and an eel biting the splenic flexure of the colon. The rectum was divided at the site of perforation, and the proximal end was exteriorized as a colostomy. The patient underwent a similar operation.

Emergency physicians should be cognizant of the possibility of colonic perforation secondary to a foreign body whenever a patient is admitted with obscure anal pain, mucous anal discharge, or abdominal pain. Once confirmed, surgical extraction of the foreign body should be performed as expediently as possible.

Acknowledgements

This work was supported by the Department of Education Science and Technology Research Project of Jiangxi Province of China (170110).

Disclosure of conflict of interest

None.

Address correspondence to: Dr. Yang Li, Department of Emergency Medicine, The First Affiliated Hospital of Nanchang University, No. 17 Yongwaizheng Street, Donghu District, Nanchang 330006, Jiangxi Province, China. Tel: +8615179137626; Fax: +86-0791-88692715; E-mail: liyang092792@126.com

References

[1] Leelouche N, Ayoub N, Bruneel F, Mignon F, Troche G, Boisrenault P, Bédos JP. Thigh cellulitis caused by toothpick ingestion. Intensive Care Med 2003; 29: 662-663.
[2] Lo SF, Wong SH, Leung LS, Law IC, Chun Yip AW. Traumatic rectal perforation by an eel. Surgery 2004; 135: 110-111.
[3] Abcarian H, Lowe R. Colon and rectal trauma. Surg Clin North Am 1978; 58: 519-537.
[4] Ooi BS, Ho YH, Eu KW, Nyam D, Leong A, Seow-Choen F. Management of anorectal foreign bodies: a cause of obscure anal pain. Aust N Z J Surg 1998; 68: 852-855.
[5] Carda-Diéguez M, Ghai R, Rodriguez-Valera F, Amaro C. Metagenomics of the mucosal microbiota of European eels. Genome Announc 2014; 2: e01132-14.
[6] Zeeli T, Samra Z, Pitlik S. Ill from eel? Lancet Infect Dis 2003; 3: 168.
[7] Ghai R, Hernandez CM, Picazo A, Mizuno CM, Ininbergs K, Díez B, Valas R, DuPont CL, McMahon KD, Camacho A, Rodriguez-Valera F. Metagenomes of Mediterranean coastal lagoons. Sci Rep 2012; 2: 490.
[8] Minter LJ, Stoskopf MK, Serrano M, Burrus O, Lewbart GA. Suspected lead toxicosis in an electric eel, Electrophorus electricus. J Fish Dis 2012; 35: 603-606.
[9] Tiwari A, Sharma H, Qamar K, Sodeman T, Nawras A. Recognition of extraperitoneal colonic perforation following colonoscopy: a review of the literature. Case Rep Gastroenterol 2017; 11: 256-264.