

Original Article

Application of AngioJet thrombus aspiration device for treatment of acute iliofemoral vein thrombosis

Jinhua Song^{1*}, Xu He^{2*}, Boxiang Zhao², Wanying Shi², Jianping Gu²

¹Hepatobiliary Center, The First Affiliated Hospital of Nanjing Medical University, Nanjing 210006, Jiangsu, China;

²Department of Interventional Radiology, Nanjing First Hospital, Nanjing Medical University, Nanjing 210006, Jiangsu, China. *Equal contributors.

Received December 11, 2018; Accepted January 11, 2019; Epub June 15, 2019; Published June 30, 2019

Abstract: The aim of this study was to investigate the efficacy and safety of the AngioJet mechanical thrombus aspiration device for treatment of acute iliofemoral vein thrombosis. A total of 50 patients with iliofemoral vein thrombosis were randomly divided into control and observation groups. For the control group, the catheter was implanted, along with the guidewire and retained. This was followed by urokinase injections. For the observation group, urokinase was sprayed within the thrombus, which was then aspirated. Thrombolytic catheters were retained for 0-3 days. Compared with the control group, thrombolysis times, urokinase dosage, and hospitalization times were significantly reduced in the observation group. For the control group, angiographies after CDT indicated 10, 9, and 6 cases of grade III, II, and I thrombus clearance, respectively. A total of 9 patients exhibited iliac vein occlusion. They were subjected to balloon dilatation and stent implantation. Inferior vena cava filters were removed from 22 cases. For the observation group, patients received thrombus aspiration treatment, followed by 0-3 days of thrombolytic therapy. There were 18, 6, and 1 cases of grade III, II, and I thrombus clearance, respectively. No recurrence was observed during the follow-up period. Blood flow in patients with stents was patent. The AngioJet mechanical thrombus aspiration device is safe and effective in treating acute iliofemoral vein thrombosis. Compared with simple CDT, PMT, combined with low-dose CDT, significantly elevates thrombus clearing efficacy, reduces thrombolytic agent dosage, reduces thrombolytic times, shortens hospitalization times, decreases bleeding, and enhances patient tolerance.

Keywords: Deep venous thrombosis, catheter thrombolysis, percutaneous mechanical thrombectomy, interventional therapy

Introduction

Venous thromboembolism (VTE) includes lower extremity deep venous thrombosis (LEDVT) and pulmonary embolisms (PE), with a potential annual incidence of about 400-500/10 million. Incidence has continually increased in recent years. VTE has become a serious vascular disease, threatening the health and quality of life of patients. Pulmonary embolisms are the most serious complication of VTE and one of the most common causes of sudden death, following cardiovascular and cerebrovascular disease [1]. Risk factors of LEDVT can be divided into the following two categories: (1) Congenital hereditary factors, including antithrombin deficiency, prothrombin G20210A mutation, coagulation factor V Leiden mutation, protein S deficiency, and protein C defects; and (2) Acquired

factors, including surgical procedures, trauma, prolonged braking, long-term bed rest, sedentariness, banding, heart failure, obesity, malignant tumors, nephrotic syndrome, infections, and estrogen elevation. These factors may induce venous thrombosis via classic Virchow factors (vascular wall injury, abnormal blood flow, and blood hypercoagulable status) [2].

Acute LEDVT refers to lower extremity deep venous thrombosis formed within 2 weeks, usually accompanied by sudden swelling of the lower extremities, pain, and activity disorders. Severe cases might lead to lower extremity venous return obstruction and blood stasis, even serious conditions, such as pale lower limbs, ischemia, and necrosis. At present, the basic treatment for acute LEDVT is to remove or reduce thrombus, restoring venous blood flow

Iliofemoral vein thrombus aspiration

of the lower limbs. The acute phase is the golden treatment period for LEDVT. Without effective treatment within the acute phase, most patients will suffer from post thrombosis syndrome (PTS), mainly characterized by intravenous hypertension, venous claudication, and venous ulcers, seriously affecting patient quality of life.

Current feasible treatment methods for acute LEDVT mainly include anticoagulant therapy, surgical thrombectomy, thrombolysis, and percutaneous mechanical thrombectomy. Anticoagulation therapy has been widely accepted and recognized as the gold standard for treatment of LEDVT [3]. It has obvious effects on treatment of simple gastrocnemius venous thrombosis, preventing expansion and reducing formation of thrombectomy, as well as reducing pulmonary embolisms. However, anticoagulation therapy cannot completely eliminate existing thrombus. Even after systemic anticoagulation therapy, incidence of PTS remains relatively high [4]. Surgical thrombectomy is currently limited in clinical application due to poor efficacy, large trauma, and easy relapse. On the other hand, compared with simple anticoagulant therapy and thrombolytic therapy through dorsal veins downstream, better efficacy has been reported for catheter-directed thrombolysis (CDT) in the treatment of LEDVT. This method can quickly open blood vessels and reduce venous pressure, protecting valve function and reducing incidence of PTS. The effectiveness of CDT in treatment of acute DVT has been confirmed by many clinical trials with high-level evidence. CDT has already been accepted as the first option for disease treatment [5]. However, there are some patients with contraindications against thrombolytic therapy due to a high risk of bleeding [6]. Moreover, prolonged duration of catheter use might increase incidence of bleeding and infections. Therefore, some patients need to terminate treatment before the scheduled time. These shortcomings have limited the wide application of thrombolysis.

Percutaneous mechanical thrombectomy (PMT) is a minimally invasive surgery. It mechanically crushes and aspirates the thrombus. It is characterized by short operation times, satisfactory efficacy, less consumption of thrombolytic agents, and no potential bleeding after thrombolysis [7]. It has been reported that, compared with AngioJet thrombus ablation de-

vice and CDT, PMT could significantly reduce hospital costs and hospitalization times [8]. In this study, aiming to investigate the efficacy and safety of PMT, combined with low-dose CDT, treatment efficacy, thrombolysis times, hospitalization times, and number of thrombolytic agents were analyzed and compared between combination treatment and simple CDT treatment groups.

Materials and methods

Study subjects

A total of 50 patients with iliofemoral vein thrombosis were included in this study. They underwent interventional therapy in the Peripheral Vascular Intervention Center. Diseases were confirmed by vascular ultrasounds and lower-extremity venous CTA. There were 22 males and 28 females (38 cases of left side and 12 cases of right side), with an average age of 49.32 ± 14.49 years (ranging from 16 to 69 years). Inclusion criteria were as follows: (1) Acute LEDVT and thrombosis course ≤ 14 days; (2) No thrombolysis contraindications; (3) No pulmonary embolisms which could influence disease treatment; (4) Unilateral lower extremity deep vein thrombosis, as well as thrombosis involving the iliofemoral veins, except for peripheral deep-vein thrombosis; and (5) Patients cooperating with treatment.

In these patients, 5 cases had undergone caesarean sections, 3 cases received appendectomies, 4 cases had ipsilateral high ligation of great saphenous veins, 3 cases underwent fixation of femoral neck fractures, 2 cases received total hip replacement, 2 cases had natural childbirth, 5 cases had malignant tumors, 4 cases had S protein deficiencies, and 4 cases had oral contraceptive history. Moreover, there were 2 long-term bedridden patients, 2 patients suffered from relapses after long-distance flights, and 11 cases reporting no clear thrombotic factors before admission. Furthermore, 6 patients were diagnosed with heparin-induced thrombocytopenia (HIT) after admission. These 50 patients were randomly divided into two groups, with no statistically significant differences in clinical data (**Table 1**). Prior written and informed consent was obtained from every patient. The study was approved by the local Ethics Review Board.

Iliofemoral vein thrombus aspiration

Table 1. Basic information of patients

	N	Age (years)	Gender		Disease course (d)	Thrombosis site		Inducing factors		
			Male	Female		Left	Right	Post-surgical factor	Non-surgical factor	Unknown
Observation group	25	50.1±14.2	10	15	5.4±2.9	18	7	10	10	5
Control group	25	48.5±15.0	12	13	4.5±3.0	20	5	9	10	6
χ^2/t	-	0.387	0.325		-1.009	0.439		0.144		
P	-	0.701	0.569		0.318	0.508		0.931		

Lower-extremity venography and inferior vena cava filter implantation

All 50 patients were placed in the supine position. Thrombus sites and thrombosis degrees were confirmed by venous angiography of the ipsilateral dorsal veins. Of these patients, 8 patients had been implanted with the inferior vena cava filter (OptEase vena cava filter; Cordis, Warren, NJ, USA), while the other 42 cases were first-visit outpatients. Contralateral femoral veins were chosen as puncture approach. The pigtail catheter was placed in the iliac vein of the puncture side. Lower-extremity venography was performed. The filter was implanted at 1-2 cm below the renal vein. In total, 24 OptEase (Cordis, Roden, USA) and 18 Aegisy (Lifetech, Shenzhen, Guangdong, China) filters were used.

For the 25 patients in the control group, thrombolytic catheters were implanted through the iliofemoral vein. After the inferior vena cava filter implantation, the 7F sheath canal (Cordis) was used to puncture through the contralateral iliofemoral vein occlusion by the *cross-mountain* method. It was then replaced by the exchange guide wire (0.035 in; Terumo Corporation, Tokyo, Japan). The thrombolytic catheters were implanted along the guide wire. In these control subjects, 12 cases underwent successful *cross-mountain* treatment. In the other 13 cases, puncture was performed through the ipsilateral popliteal veins under the guidance of ultrasound or roadmap, then the thrombolytic catheters were held in place. Moreover, 250,000 units of urokinase (250,000 units/injection; NDPHARM, Nanjing, Jiangsu, China) were injected through thrombolytic catheters.

PMT

For the 25 subjects in the observation group, 16 cases underwent successful *cross-mountain* treatment, while the other 9 cases were

punctured through ipsilateral popliteal veins. Catheters were placed in the ipsilateral femoral popliteal veins. They were replaced by the 7F sheath canal and exchange guide wire after angiography. The iliofemoral venous thrombus was confirmed by another angiography after thrombolytic catheter implantation. Next, 6F Xpeedior AngioJet catheters (0.035 in; Boston INC, Indianola, PA, USA) were implanted. Each patient was injected with 250,000 units of urokinase (NDPHARM; dissolved in 100 mL saline) and thrombolytic therapy was conducted using the spray mode. After thrombolytic infusion and waiting for 15 minutes, the AngioJet mechanical thrombus aspiration device was changed from spray mode into aspiration mode. The infusion solution was changed into 5,000 U heparin in 500 mL saline. For the 6 cases of HIT, 20 mg argatroban injections (TIPR Pharmaceutical Co., Ltd., Tianjin, China) in 500 mL saline were used instead. Thrombus aspiration was performed as the AngioJet catheter moved along the guidewire at a rate of 1 mm/s. Immediate angiographies were carried out for thrombolysis assessment.

Evaluation of thrombus clearance and patient tolerance

Thrombosis clearance was evaluated according to the following criteria [9]: Grade III, thrombosis clearance rate of > 90%; Grade II, thrombosis clearance rate of 50%-90%, most thrombus was cleared; and Grade I, thrombosis clearance rate of < 50%, thrombus was only partially cleared. Patient tolerance was assessed based on the following criteria: 1-4 points, comfortable; 5-8 points, uncomfortable but bearable; and 9-12 points, very uncomfortable, treatment was stopped.

Catheter-directed thrombolysis and patient follow-up

All patients from control and observation groups were subjected to the catheter-directed

Iliofemoral vein thrombus aspiration

thrombolysis. For the control group, the catheter was retained for 3-7 days, with urokinase at a dose of 500,000-750,000 U/d. For the observation group, the catheter was retained for 0-3 days, with urokinase at dose of 250,000-500,000 U/d. Angiographies were performed every day and the clotting time was monitored. If the thrombus was completely dissolved and iliac vein compression syndrome was observed, balloon dilatation was performed and the iliac vein stent was implanted. The inferior vena cava filter was removed and thrombolytic therapy was terminated. If the thrombus was not completely dissolved, thrombolytic therapy was terminated at 3 days after surgery for the observation group and at 7 days post-surgery for the control group.

For patients in the observation group, blood and urine routine examinations, as well as liver and kidney function assessments, were conducted at 1 days and 7 days after PMT, respectively. Changes in levels of red blood cells, hemoglobin, alanine aminotransferase, aspartate aminotransferase, creatinine, and urea nitrogen were recorded and compared before and after surgery. All patients were subjected to lower-extremity venous CTA at 1 month and 6 months after surgery. Patient follow-ups lasted for 1-6 months. Oral anticoagulation therapy (INR value was adjusted to 2-2.5 for Warfarin, or 20 mg/d Xarelto) was continued for at least 6 months after surgery.

Statistical analysis

Data are expressed as mean \pm SD. SPSS 16.0 software was used for statistical analysis. Paired and independent sample *t*-tests were performed for comparisons before and after surgery and group comparisons. The χ^2 test was used for categorical data comparisons. *P* < 0.05 indicates statistical significance.

Results

Clinical data, treatment efficacy, and patient tolerance

Thrombolytic effects, thrombolysis times, urokinase dosage, and average hospitalization times were analyzed and compared between the two groups. Results showed that, for the 25 patients in the control group, CDT catheter indwelling time was 3-7 days, with a mean CDT

time of 129.6 ± 32.2 hours. Moreover, the urokinase dose was 1,750,000-5,500,000 U, with an average urokinase dose of $4,100,000 \pm 1,060,000$ U. Furthermore, the average hospitalization time was 7.9 ± 1.4 days. Angiographic review, after CDT, showed there were 10 cases of grade III thrombus clearance, 9 cases of grade II lower-extremity iliofemoral vein thrombus clearance, and 6 cases of grade I thrombus clearance. In the control group, there were 9 cases that displayed iliac vein occlusion. They underwent balloon dilatation and stent implantation. Finally, the inferior vena cava filters were removed from 22 cases.

In the observation group, all 25 patients were subjected to thrombus aspiration treatment, with an average aspiration time of 230 seconds (ranging from 100 to 340 seconds). Angiographic evaluations, after aspiration, showed there were 12 cases of grade III lower-extremity iliofemoral vein thrombus clearance, 5 cases of grade II thrombus clearance, and 3 cases of grade I thrombus clearance. After thrombolytic therapy for 1-3 days, there were 18 cases of grade III lower-extremity iliofemoral vein thrombus clearance, 6 cases of grade II thrombus clearance, and 1 case of grade I thrombus clearance. The average thrombolysis time was 42.2 ± 16.7 hours. The average urokinase dose was $880,000 \pm 354,000$ U (ranging from 500,000 to 1,750,000 U). The average hospitalization time was 3.8 ± 0.8 days. Ultimately 11 cases exhibited iliac vein compression following thrombolysis. They were subjected to balloon dilatation and stent implantation. The inferior vena cava filters were finally removed from 23 cases. Statistical analysis showed that, compared with the control group, thrombolysis times, urokinase dosage, and average hospitalization times were significantly reduced in the observation group (**Table 2**) (all *P* < 0.05). Results suggest that, compared with the control group, therapeutic effects were significantly increased in the observation group.

For all patients during follow-up period, no recurrences were noted at 1 month or 6 months after surgery. Results from CTA reviews showed no recurrence of thrombosis. Blood flow was patent and stable in the patients carrying stents. In the experimental group, all patients were able to tolerate PMT. Regarding catheter-directed thrombolysis, there were 16 patients feeling comfortable, 7 patients feeling uncom-

Iliofemoral vein thrombus aspiration

Table 2. Analysis and comparison of treatment and therapeutic efficacy

	Catheter-indwelling time (h)	Urokinase dosage ($\times 10^4$ U)	Hospitalization time (d)	Stent implantation cases	Filter removing cases	Thrombus clearance			Patient tolerance		
						Grade III	Grade II	Grade I	1	2	3
Observation group	42.2 \pm 16.7	88.0 \pm 35.4	3.8 \pm 0.8	11	23	18	6	1	16	7	2
Control group	129.6 \pm 32.2	410.0 \pm 106.0	7.9 \pm 1.4	9	22	10	9	6	5	9	11
χ^2/t	-11.457	-14.397	-12.908	0.333	0.000	6.457			12.243		
<i>P</i>	< 0.001	< 0.001	< 0.001	0.564	1.000	0.040			0.002		

Table 3. Comparison of blood test indexes before and after PMT in the observation group

	RBC ($\times 10^9/L$)	Hb (g/L)	ALT (U/L)	AST (U/L)	Bun (mmol/L)	Cr (mmol/L)
Before surgery	4.16 \pm 0.35	127 \pm 8	34 \pm 17	38 \pm 15	4.75 \pm 1.25	84.1 \pm 30.0
1 d after surgery	3.96 \pm 0.38	115 \pm 10	36 \pm 15	39 \pm 15	4.83 \pm 1.20	85.9 \pm 29.1
7 d after surgery	4.14 \pm 0.36	125 \pm 9	35 \pm 16	37 \pm 15	4.75 \pm 1.24	83.7 \pm 28.7
<i>t</i>	9.603	7.646	-1.915	-1.508	-1.819	-2.351
	1.168	1.674	-1.401	1.088	0.161	0.406
<i>P</i>	< 0.001	< 0.001	0.067	0.145	0.081	0.184
	0.254	0.107	0.174	0.288	0.873	0.689

Note: The *t* and *P* values reflect the comparison before surgery and 1 day and 7 days after surgery, respectively.

comfortable but bearable, and only 2 cases reported unbearable discomfort. On the other hand, in the control group, due to longer periods of bedtime and surgical procedures of puncture, there were 5 patients feeling comfortable, 9 patients feeling uncomfortable but bearable, and 11 cases reporting unbearable discomfort (of whom 2 patients terminated CDT treatment before the scheduled time). Statistically significant differences were observed in tolerance of the detaining catheter between these two groups (**Table 2**). Taken together, results suggest that, compared with the control group, thrombolysis times, urokinase dosage, and hospitalization times were significantly reduced for the observation group. The observation group was associated with superior therapeutic effects and significantly improved patient tolerance.

Analysis of treatment safety

To evaluate the safety of PMT, laboratory test indicators in the observation group, before and after surgery, were analyzed and compared. For the observation group, no cases reported bleeding or renal function failure, during and after aspiration. However, there were 14 cases reporting hemoglobinuria, which recovered to normal after 3 days. Moreover, significant differences were observed in blood cells and hemoglobin values before surgery and at 1 day

after surgery, while no statistically significant differences were observed in blood cells and hemoglobin values between surgery and at 7 days after surgery. Furthermore, no statistically significant differences were noted in the levels of alanine aminotransferase, aspartate aminotransferase, creatinine, or urea nitrogen before surgery and at 1 day or 7 days after surgery (**Table 3**). In addition, 2 cases reported sinus bradycardia during iliofemoral vein thrombus clearance. Symptoms disappeared when the operation was temporarily stopped. Therefore, aspiration procedures could be completed. Moreover, 1 case reported chilling due to unknown reasons. Chills disappeared when the operation was temporarily stopped.

In the experimental group, there were only 2 cases suffering from bleeding at the puncture point. On the other hand, for the control group, there were 4 cases reporting bleeding at the puncture point during CDT treatment, 2 cases with subcutaneous ecchymosis at the back, and 1 case with oozing of blood at the tongue tip. Results indicate that incidence of bleeding for the control group was significantly higher than that for the observation group. Hemoglobin and red blood cell counts would temporarily decline, but soon return to normal levels. Taken together, results suggest that PMT, combined with low-dose thrombolytic therapy, is safe and offers lower bleeding incidence.

Iliofemoral vein thrombus aspiration

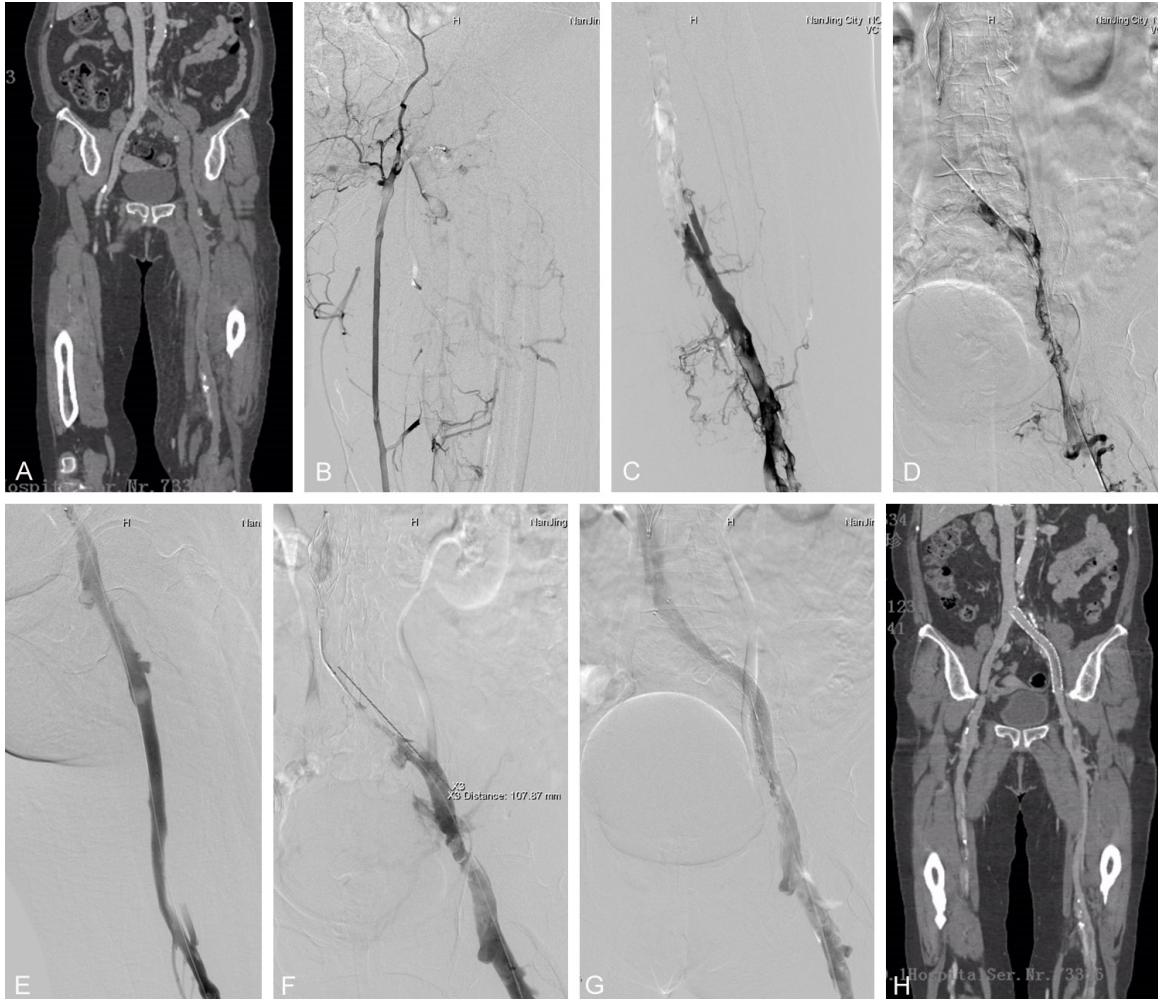


Figure 1. A 70-year-old female whose left lower extremity swelled for 3 days due to no obvious reasons. A, B. Lower-extremity vein CTA and left foot dorsal vein angiography indicated iliofemoral venous thrombosis. C, D. Inferior vena cava filter was implanted through the right lateral femoral vein. Angiography showed large amount of thrombus in the left iliofemoral vein. E, F. AngioJet thrombectomy device was implanted through the exchange guide wire and PMT was performed. Angiography indicated iliac vein compression syndrome. G. Stent implantation in the left iliac vein completely restored vein patency. H. CTA review at 6 months after surgery showed patent blood flow in the iliofemoral vein, with satisfactory stent position.

Analysis of typical cases

The first typical case was a 70-year-old female. Her left lower extremities had swelled for 3 days due to no obvious reasons. As shown in **Figure 1**, lower-extremity vein CTA and left foot dorsal vein angiographies indicated iliofemoral venous thrombosis (**Figure 1A, 1B**). The right lateral femoral vein was selected as the puncture approach and the inferior vena cava filter was implanted. Catheter-directed angiography through the puncture in the left popliteal vein showed a large amount of thrombus in the left iliofemoral vein (**Figure 1C, 1D**). The AngioJet

thrombectomy device was implanted through the exchange guide wire, then 250 mL saline containing 250,000 U urokinase was sprayed. After 15 minutes, PMT was performed, basically diminishing thrombus in the left iliofemoral vein. Angiography assessment indicated iliac vein compression syndrome (**Figure 1E, 1F**). The case was then subjected to stent implantation (12×100 mm) in the left iliac vein, completely restoring vein patency (**Figure 1G**). The inferior vena cava filter was removed. Oral anticoagulant therapy was continued after surgery. CTA review at 6 months after surgery showed patent blood flow in the iliofemoral

Iliofemoral vein thrombus aspiration

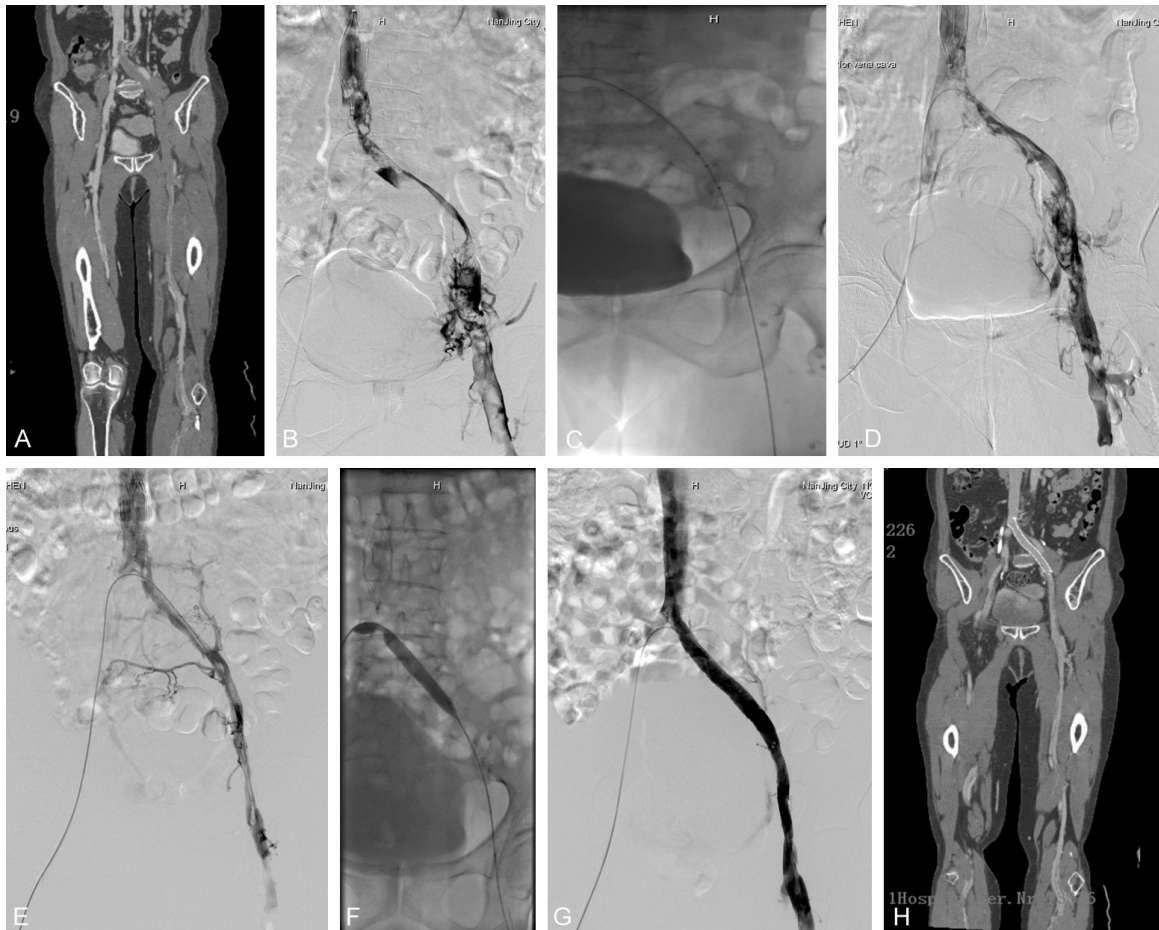


Figure 2. A 67-year-old female that received appendectomy and reported lower extremity swelling after surgery. A. Lower-extremity vein CTA showed left iliofemoral venous thrombosis, which partially extended to the inferior vena cava. B. Inferior vena cava filter was implanted through right femoral vein. Angiography directed by the *cross-mountain* catheter indicated large amount of thrombosis in the left iliofemoral vein. C. AngioJet thrombectomy device was implanted and PMT was performed. D. Thrombus in the iliofemoral vein was significantly reduced after surgery. E. Thrombolytic catheter was retained and the review 72 hours later showed that the thrombus in the iliofemoral vein was basically removed. Moreover, left iliac vein compression was observed. F, G. Stent (12×80 mm) was implanted. Angiography showed complete recovery of the fluency in the left iliofemoral vein. The inferior vena cava filter was removed. H. CTA review at 6 months after surgery showed patent blood flow in the iliofemoral vein, with satisfactory stent position.

vein, with satisfactory stent position (**Figure 1H**).

The second typical case was a 67-year-old female. She received an appendectomy and reported lower extremity swelling at 3 days after surgery. The patient was admitted to the hospital at 10 days after the appendectomy. Lower-extremity vein CTA showed left iliofemoral venous thrombosis, partially extending to the inferior vena cava (**Figure 2A**). The inferior vena cava filter was implanted through the puncture at the right femoral vein and the left femoral vein angiography directed by the

mountain catheter indicated large amount of thrombosis in the left iliofemoral vein (**Figure 2B**). The AngioJet thrombectomy device was implanted through the exchange guide wire, then 250 mL saline containing 250,000 U urokinase was sprayed. After 15 minutes, PMT was performed (**Figure 2C**), obviously decreasing thrombus in the iliofemoral vein (**Figure 2D**). The thrombolytic catheter was retained. The review, 72 hours later, showed that the thrombus in the iliofemoral vein was basically removed. Moreover, left iliac vein compression was observed (**Figure 2E**). Balloon dilatation was then performed in the left common iliac

vein and a stent (12×80 mm) was implanted. Angiographies showed complete recovery of fluency in the left iliofemoral vein. The inferior vena cava filter was removed (**Figure 2F, 2G**). Oral anticoagulant therapy was continued after surgery. CTA review at 6 months after surgery showed patent blood flow in the iliofemoral vein, with satisfactory stent position (**Figure 2H**).

Discussion

CDT has satisfactory therapeutic effects for acute LEDVT, even though often accompanied by the risk of bleeding. In a previous study, 473 patients with LEDVT were kept under CDT in the Intensive Care Unit. However, 11% of them suffered from massive hemorrhages during treatment and needed blood transfusion therapy [10]. Moreover, less severe bleeding was reported in 16% of those patients, while cerebral hemorrhages occurred in 2 cases (one death). Some patients had thrombolytic therapy contraindications. Longer CDT duration and long-term intravascular catheter indwelling greatly increases incidence of bleeding and infection at the puncture point. Due to long-term bed-times during treatment and the fact that patients must keep the lower extremities on the puncture side in a straight position, unbearable discomfort might lead to early termination of treatment. These disadvantages have limited the clinical application of CDT. In this study, results showed that, in the observation group, only 2 cases reported blood oozing at the puncture point. In the control group, more cases of blood oozing at the puncture point and subcutaneous ecchymosis were noted. Moreover, compared with the control group, the dosage of thrombolytic agents was dramatically lower in the observation group, reducing incidence of complications, such as bleeding. For the observation group, due to shortened catheter indwelling periods, the patients were more tolerant to treatment.

AngioJet works by injecting high-pressure saline into the inflow cavity. At the catheter tip, the saline is reversed into the outflow cavity, resulting in obvious negative pressure (i.e., the Bernoulli effect) and the thrombus is inhaled into the outflow cavity [8]. For the 6F Xpeedior catheter, unlike other simple thrombus aspiration catheters, there is a high-pressure spray mode before thrombus aspiration. This mode injects

a certain amount of thrombolytic agent (10000 psi; 350-450 km/h) into the thrombus. With increasing contact areas, the thrombus would be crushed and then aspirated, significantly enhancing thrombus aspiration efficiency. Compared with other PMT equipment, AngioJets are characterized by the maintenance of body fluid balance, less blood loss, and reduced injuries of the vascular wall. Murphy et al. [11] studied 33 subjects with LEDVT, in which the AngioJet thrombus clearing device has been adopted on 18 patients. The Trellis thrombus clearing device had been applied in 15 cases. They showed that the therapeutic effects of the AngioJet device were superior to the Trellis equipment. In another study from Lin et al., 98 patients with lower-extremity acute DVT were investigated. A total of 46 cases had been treated with CDT therapy, while the other 52 cases had received PMT therapy with AngioJet [8]. They reported comparable therapeutic efficiencies for both groups, showing that PMT is associated with dramatically reduced dosage of thrombolytic agents, declined complication (bleeding) incidence, and decreased ICU and hospitalization times, as well as reduced treatment costs. Moreover, a late multi-center PEAL-registered clinical trial has shown that PMT can effectively reduce thrombolysis times and reduce the risk of bleeding. However, no significant differences were reported, compared with CDT treatment [12]. After thrombus aspiration, AngioJets can not only quickly reduce the thrombus load and restore (partially or completely) blood flow in the originally occluded blood vessels, when combined with CDT, it may also increase the contact of the thrombolytic agents and thrombus. These factors might significantly improve thrombolytic effects. These differential conclusions might be due to only simple PMT having been applied or having been only combined with short-term (2-4 hours) CDT. Elongated thrombotic periods might improve therapeutic effects. In this study, 25 patients in the observation group were subjected to the AngioJet thrombus aspiration combined with 0-3 days of low-dose CDT. Results showed that there were 18 cases of grade III lower-extremity iliofemoral vein thrombus clearance, 6 cases of grade II thrombus clearance, and 1 case of grade I thrombus clearance. Compared with the simple CDT control group, the thrombus clearing effects were significantly enhanced, with thrombolytic agent dosage, thrombolysis

Iliofemoral vein thrombus aspiration

times, and hospitalization times dramatically declined.

During the injecting and aspirating processes of AngioJet, the thrombus is impacted by high-pressure and high-speed saline flow, which may generate shedding fragments. In a previous report, 30 patients had been subjected to the AngioJet thrombus clearing treatment. In the 20 patients implanted with inferior vena cava filter, no pulmonary embolisms were observed. For the other 9 cases carrying no filter, 5 patients suffered from pulmonary embolisms, confirmed by CTA assessment. These findings suggest that the inferior vena cava filter is necessary for the AngioJet thrombus clearance. In the current study, all patients had been implanted with the inferior vena cava filters before receiving PMT treatment. Since more and more evidence has shown that long-term placement of the inferior vena cava filter might induce complications [13], it has been recommended that the implanted inferior vena cava filter should be removed if possible. In this study, in both groups, the filters were not removed in the 5 patients with tumors. The filters were successfully removed in the other 45 patients after CDT. In the observation group, 14 cases reported hematopoietic leukemia after mechanical thrombectomy. They returned to normal 3 days later. This phenomenon might have been caused by the fact that high-speed water flow destroys red cells and increases the content of free hemoglobin in the blood. To reduce renal function impairment, adequate hydration ensuring enough urine and urine alkalization after surgery might represent effective prevention methods. In the observation group, patients reported temporary decline of red cells and hemoglobin after surgery. They were restored to normal 7 days later. Moreover, no significant differences were observed in liver and kidney function indicators before and after surgery. Jeyabalan et al. [12] studied 57 cases of AngioJet thrombectomy. They showed that 7 cases have suffered from arrhythmias. In these 7 patients, there were 2 cases of temporary cardiac arrest, which was alleviated after intravenous injections of atropine. The other 5 patients report sinus bradycardia, which was ameliorated when thrombus aspiration was temporarily stopped. More than half of these patients with arrhythmias have been subjected to the clearance of the inferior vena cava thrombus. Occurrence of arrhythmias might be associated

with the pressure of the high-speed flow cycle on the right atrium stretching receptor. In the current study, 2 patients reported sinus bradycardia during the iliofemoral vein thrombus clearing process. They were alleviated when the operation was temporarily paused, allowing for the complete aspiration process. It is necessary to prepare for the injection of atropine in cases cardiac arrest occurs. Moreover, 1 case reported chilling due to unknown reasons. Chills disappeared when the operation was completed. No special treatments are necessary for these transient reactions.

In conclusion, present results show that the AngioJet mechanical thrombus aspiration device is safe and effective in the treatment of acute iliofemoral vein thrombosis. It quickly reduces symptoms such as lower extremity swelling. Compared with simple CDT, PMT, combined with low-dose CDT, can significantly elevate thrombus clearing efficacy, reduce thrombolytic agent dosage and thrombolytic times, shorten hospitalization times, decrease bleeding, and enhance patient tolerance. Due to the limited sample size and follow-up period, present findings should be confirmed by further in-depth multicenter studies.

Acknowledgements

This work was supported by the Clinical Medicine Science and Technology Projects of Jiangsu Province [grant number BL2014013] and Nanjing Medical Science Fund [grant number YKK14087].

Disclosure of conflict of interest

None.

Address correspondence to: Dr. Jianping Gu, Department of Interventional Radiology, Nanjing First Hospital, Nanjing Medical University, No. 68, Changle Road, Nanjing 210006, Jiangsu, China. Tel: 86-135 0517 1786; E-mail: cjr.gujianping@vip.163.com

References

- [1] Deitelzweig SB, Johnson BH, Lin J and Schulman KL. Prevalence of clinical venous thromboembolism in the USA: current trends and future projections. *Am J Hematol* 2011; 86: 217-220.
- [2] Hackett TR and Godin JA. Editorial commentary: should the virchow triad have been a quartet? Is high altitude a risk factor for deep

Iliofemoral vein thrombus aspiration

- venous thrombosis after knee arthroscopy? *Arthroscopy* 2016; 32: 2355-2356.
- [3] Lopes LC, Eikelboom J, Spencer FA, Akl EA, Kearon C, Neumann I, Schulman S, Bhatnagar N and Guyatt G. Shorter or longer anticoagulation to prevent recurrent venous thromboembolism: systematic review and meta-analysis. *BMJ Open* 2014; 4: e005674.
- [4] Srinivas BC, Patra S, Nagesh CM, Reddy B and Manjunath CN. Catheter-directed thrombolysis along with mechanical thromboaspiration versus anticoagulation alone in the management of lower limb deep venous thrombosis-a comparative study. *Int J Angiol* 2014; 23: 247-254.
- [5] Enden T, Haig Y, Klow NE, Slagsvold CE, Sandvik L, Ghanima W, Hafsahl G, Holme PA, Holmen LO, Njaastad AM, Sandbaek G, Sandset PM; CaVenT Study Group. Long-term outcome after additional catheter-directed thrombolysis versus standard treatment for acute iliofemoral deep vein thrombosis (the CaVenT study): a randomised controlled trial. *Lancet* 2012; 379: 31-38.
- [6] Sillesen H, Just S, Jorgensen M and Baekgaard N. Catheter directed thrombolysis for treatment of ilio-femoral deep venous thrombosis is durable, preserves venous valve function and may prevent chronic venous insufficiency. *Eur J Vasc Endovasc Surg* 2005; 30: 556-562.
- [7] Kar S and Webel R. Septic thrombophlebitis: percutaneous mechanical thrombectomy and thrombolytic therapies. *Am J Ther* 2014; 21: 131-136.
- [8] Lin PH, Zhou W, Dardik A, Mussa F, Kougiass P, Hedayati N, Naoum JJ, El Sayed H, Peden EK and Huynh TT. Catheter-direct thrombolysis versus pharmacomechanical thrombectomy for treatment of symptomatic lower extremity deep venous thrombosis. *Am J Surg* 2006; 192: 782-788.
- [9] Cynamon J, Stein EG, Dym RJ, Jagust MB, Binkert CA and Baum RA. A new method for aggressive management of deep vein thrombosis: retrospective study of the power pulse technique. *J Vasc Interv Radiol* 2006; 17: 1043-1049.
- [10] Alesh I, Kayali F and Stein PD. Catheter-directed thrombolysis (intrathrombus injection) in treatment of deep venous thrombosis: a systematic review. *Catheter Cardiovasc Interv* 2007; 70: 143-148.
- [11] Murphy EH, Broker HS, Johnson EJ, Modrall JG, Valentine RJ and Arko FR 3rd. Device and imaging-specific volumetric analysis of clot lysis after percutaneous mechanical thrombectomy for iliofemoral DVT. *J Endovasc Ther* 2010; 17: 423-433.
- [12] Jeyabalan G, Saba S, Baril DT, Makaroun MS and Chaer RA. Bradyarrhythmias during rheolytic pharmacomechanical thrombectomy for deep vein thrombosis. *J Endovasc Ther* 2010; 17: 416-422.
- [13] Grewal S, Chamarthy MR and Kalva SP. Complications of inferior vena cava filters. *Cardiovasc Diagn Ther* 2016; 6: 632-641.