

Original Article

The learning curve of suctioning flexible ureteroscopy with automatic control of renal pelvic pressure: a single-center experience

Xiaolin Deng^{1,2*}, Leming Song^{2*}, Xianxin Zhu^{2*}, Ning Xie^{2*}, Chuance Du², Wanlong Tan¹

¹Department of Urology, Nanfang Hospital, Southern Medical University, Guangzhou 510515, Guangdong, China;
²Department of Urology, The Affiliated Ganzhou Hospital of Nanchang University, Ganzhou 341000, Jiangxi, China.
*Equal contributors.

Received January 25, 2019; Accepted April 8, 2019; Epub June 15, 2019; Published June 30, 2019

Abstract: This study describes development of suctioning flexible ureteroscopy (SF-URS) with automatic control of renal pelvic pressure. The learning curve of SF-URS with automatic control of renal pelvic pressure was investigated in eighty consecutive patients undergoing SF-URS. The procedure was performed by a single experienced endourologist and patients were divided into four groups in terms of the timing of the operation (from June 2016 to April 2017). Each group consisted of 20 patients. Twenty cases performed by the senior surgeon who had performed more than 100 cases were used as a control comparison group. Sheath placement, Double-J stent placement, operative times, stone-free rates, and complication rates were compared among the groups. The groups did not differ significantly in terms of age, body mass index, sex, stone position, or stone size. For the four consecutive groups, the sheath placement times were 8.1 ± 2.0 , 6.7 ± 1.5 , 6.0 ± 2.2 , and 5.3 ± 1.7 minutes, respectively ($P < 0.001$), and the operation times were 50.8 ± 11.5 , 45.1 ± 7.0 , 35.4 ± 7.1 , and 33.9 ± 9.4 min ($P < 0.001$). Sheath placement time and operation time of the control group were equivalent to those of the novice surgeon after forty cases. There were no significant differences over time in the Double-J stent placement time, stone-free rate, or complication rate. Forty cases thus provide a reasonable estimate of the experience needed to attain the plateau of the SF-URS learning curve.

Keywords: Flexible ureteroscopy, renal pelvic pressure, renal stone, learning curve

Introduction

Flexible ureteroscopy is recognised as a very valuable tool for the treatment of upper urinary tract calculi. During endoscopic lithotripsy, saline perfusion is important in terms of stone-breaking efficiency and visualisation of the operative field, and to prevent injury. However, high-perfusion increases renal pelvic pressure (RPP). The RPP can be reduced to a certain extent by placing a ureteral access sheath. Nevertheless, it does not allow intra-pelvic pressure to be monitored or controlled, limiting the clinical applications of the technique. Thus, in our previous study, suctioning flexible ureteroscopy (SF-URS) with automatic control of RPP to allow successful RPP monitoring and control, reducing the incidence of complications, and improving the efficiency of lithotripsy [1-4]. Training is essential when it is sought to

master the improved flexible ureteroscopy [5]. Earlier, it was reported that 60-100 cases were reasonable estimates of the experience required to attain the plateau of the learning curve associated with traditional flexible ureteroscopy [6, 7]. However, the learning curve of SF-URS had not yet been investigated. The purpose of this study was to describe this learning curve.

Materials and methods

Clinical data

Data on 80 consecutive, successful SF-URS operations performed by a single surgeon from June 2016 to April 2017 were studied. The inclusion criteria were either sex, age 18-75 years, and renal stones ≤ 3 cm in diameter. The exclusion criteria were pregnancy, any urinary

Learning curve for suctioning flexible ureteroscopy




Figure 1. Real picture of the pressure-measuring suctioning sheath. 1. The pressure sensitive tip. 2. The channel for pressure monitoring and feedback. 3. The channel for vacuum suctioning.

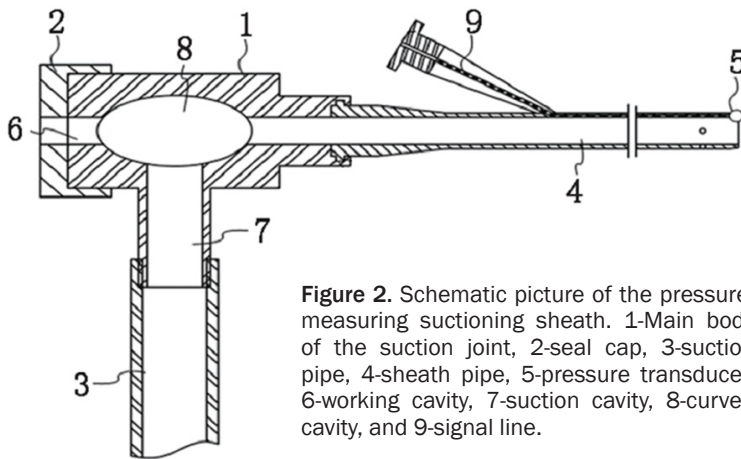


Figure 2. Schematic picture of the pressure-measuring suctioning sheath. 1-Main body of the suction joint, 2-seal cap, 3-suction pipe, 4-sheath pipe, 5-pressure transducer, 6-working cavity, 7-suction cavity, 8-curved cavity, and 9-signal line.

tract abnormality, and a positive urine culture. The surgeon was a graduate urologist who had completed a fellowship in endourology but had no prior experience with SF-URS. He did have experience with other endourological procedures including ureteroscopy and percutaneous nephrostomy. The study was approved by our Institutional Ethics Committee. All patients signed written informed consent forms before surgery. The 80 consecutive cases were divided into four groups. Twenty cases performed by the senior surgeon who had performed more than 100 cases were used as a control group during the study period. Demographic data, stone characteristics, and intra- and post-operative data (including complications associated with surgery) were compared among the groups. The operation time ran from the beginning of lithotripsy to the end of surgery. Surgical complications were classified using the modified Clavien-Dindo system [8]. Stone-free status was defined as no residual stone or a resid-

ual stone < 4 mm in diameter as revealed by KUB (X-ray of kidneys, ureters, and bladder) on postoperative day 30 (prior to stent removal). Patients with radiolucent or residual stones underwent computed tomography (CT).

The SF-URS procedure

As previously described, all flexible ureteroscopic lithotripsy procedures were performed with patients under general anaesthesia in the oblique, supine lithotomy position positioned at 30-90° with the diseased side upward. The aim was to have the renal pelvic outlet in a lower position than that of either calyx. Initially, ureteroscopy was performed using a semi-rigid 8/9.8F ureteroscope (Richard Wolf, Germany) and a flexible 0.032-inch guidewire was inserted into the renal collection system. Next, a patented transparent ureteral access sheath (12-14F) was inserted into the proximal ureter along the guidewire, without fluoroscopic guidance (**Figures 1 and 2**) [9, 10]. A flexible ureteroscope (Storz, Germany) was then inserted into the sheath to allow comprehensive inspection of the position of the sheath, and the mucosa of the renal pelvis and ureter. After confirming that the transparent sheath was correctly placed, the pressure-sensing and suctioning channels were connected to the irrigation and suctioning platform (**Figure 3**). The platform selection mode was set to fully automatic. The perfusion flow was set to 50-150 mL/min. The

Learning curve for suctioning flexible ureteroscopy




Figure 3. Irrigation and suctioning platform.

RPP control value was set to -15 to -5 mmHg. The RPP pressure warning value was set to release at 20 mmHg and the maximum value was set to 30 mmHg. Intraoperatively, a holmium laser was used to break down the stones. The pulse energy was 0.6-0.8 J and pulses were delivered at 20-30/s (Lumenis; fibre diameter, 200 μ m). During the stone fragmentation process, the scope body was moved back and forth slightly (range, 2-3 mm) in a smooth fashion within the sheath, to facilitate suction removal of small particles inside the sheath gap. Particles of diameter larger than the sheath gap but less than that of the ureteral access sheath were sucked out upon intermittent scope withdrawal, without any need for stone basketing. A 4.6-F Double-J ureteral stent was placed at the end of the procedure and remained in place for 30 days.

Statistical analysis

Statistical analysis was performed using SPSS 16.0 software. ANOVA, Chi-square test or Fisher's exact test, and Student's t-test were used to compare inter-group differences. A P -value < 0.05 was considered to reflect statistical significance.

Results

Demographic data are presented in **Table 1**. There was no significant difference among the groups with respect to age, body mass index, sex, stone position, or stone size. Actual RPP of groups was controlled under 20 mmHg with clear operative visualization and gravel particles were sucked out without a need of stone basketing.

There were 11 patients who had residual stone > 4 mm in size requiring subsequent SWL (5 cases), second-flexible ureterostomy (3 cases) or other managements (second ureteroscopy, 1 case; medication, 1 case). Clavien I complications were noted in 11 cases including hematuria in 5 cases, fever requiring antipyretics in 3 cases, nausea/vomiting in 2 cases, and pain in 1 case. Clavien II complication was noted in 6 cases with renal colic and infection, respectively. No Clavien III-V complications were noted.

Intra- and post-operative data are shown in **Table 2**. Both sheath placement and operative time gradually decreased as the surgeon gained experience, with statistical significance ($P < 0.05$). The senior surgeon's sheath place-

Learning curve for suctioning flexible ureteroscopy

Table 1. Demographic data of patients according to patients' group

Items	Group 1	Group 2	Group 3	Group 4	Control group	P value
Age (years)	48.2 ± 12.1	45.4 ± 9.2	51.9 ± 10.9	47.4 ± 7.8	46.8 ± 8.9	0.512
BMI (kg/m ²)	21.7 ± 4.8	22.7 ± 8.5	20.3 ± 4.4	19.8 ± 5.7	20.7 ± 5.9	0.235
Sex (Male/Female)	11/9	10/10	9/11	14/6	12/8	0.557
Stone location (%)						0.921
Upper calyx	9 (45%)	12 (60%)	12 (60%)	11 (55%)	10 (50%)	
Middle calyx	3 (15%)	3 (15%)	4 (20%)	5 (25%)	4 (20%)	
Lower calyx	3 (15%)	4 (20%)	2 (10%)	2 (10%)	3 (15%)	
Multiple calices	5 (25%)	1 (5%)	2 (10%)	2 (10%)	3 (15%)	
Stone size (mm)	18.1 ± 4.7	20.4 ± 6.8	19.9 ± 7.9	21.8 ± 6.2	20.6 ± 7.2	0.266

Table 2. Intraoperative and postoperative data according to patients' group

Items	Group 1	Group 2	Group 3	Group 4	Control group	P value
Sheath placement time (min)	8.1 ± 2.0	6.7 ± 1.5	6.0 ± 2.2	5.3 ± 1.7	5.5 ± 1.9	< 0.001
DJ stent placement time (min)	3.4 ± 1.6	3.6 ± 2.0	2.4 ± 1.2	2.9 ± 1.1	2.6 ± 1.5	0.328
Operative time (min)	50.8 ± 11.5	45.1 ± 7.0	35.4 ± 7.1	33.9 ± 9.4	36.9 ± 7.3	< 0.001
Stone-free rate (N, %)	16 (80%)	17 (85%)	17 (85%)	19 (95%)	18 (90%)	0.681
Complication						0.816
Grade I	4	3	2	1	1	
Grade II	2	1	1	1	1	
Grade III	0	0	0	0	0	
Grade IV	0	0	0	0	0	
Grade V	0	0	0	0	0	

ment and operative time was similar to that of the novice surgeon after 40 procedures had been undertaken. The DJ stent placement time, the stone-free rate, and the complication rate improved slightly over time, but statistical significance was not attained. The sheath placement and operation times gradually decreased as the number of cases increased (both $P < 0.05$), as shown in **Figures 4 and 5**.

Discussion

Flexible ureteroscopy is popular worldwide due to continuous improvements in technology and surgical techniques, and is now considered to be a first-line treatment option for removal of renal and ureteral calculi. Flexible ureteroscopy and the associated devices have developed rapidly [11]. However, despite the therapeutic benefits afforded, flexible ureteroscopy may be associated with certain minor or major complications, especially during the learning curve [7]. The total complication rate is 26.1%, and includes infection, postoperative haematuria, mucosal injury, ureteral or renal perforation or avulsion, intraparenchymal haematoma, and sub-capsular infected hematoma [12-17]. Se-

rious operative complications such as urosepsis are known, but are uncommon (0-4.5%), albeit associated with high-level mortality (to 20%) [18]. Hence, it is very important for surgeons to know how to safely gain access and this requires training. However, the length of the training period is not a useful measure of competence, because the numbers of operations performed vary greatly among teaching centres [19]. It was important to define the number of operations required to achieve competence.

It was reported earlier that 60-100 cases was a reasonable estimate of the experience needed to attain the plateau of the learning curve of traditional flexible ureteroscopy [6, 7]. SF-URS with automatic RPP monitoring and control reduced the incidence of complications and improved the efficiency of lithotripsy in our previous study. However, the learning curve of SF-URS has not been well-studied. Operation time best reflects surgical competence, falling as the surgeon becomes familiar with the instrumentation and as dexterity improves. The stone clearance rate is a critical clinical indicator of competency, as are the numbers and

Learning curve for suctioning flexible ureteroscopy

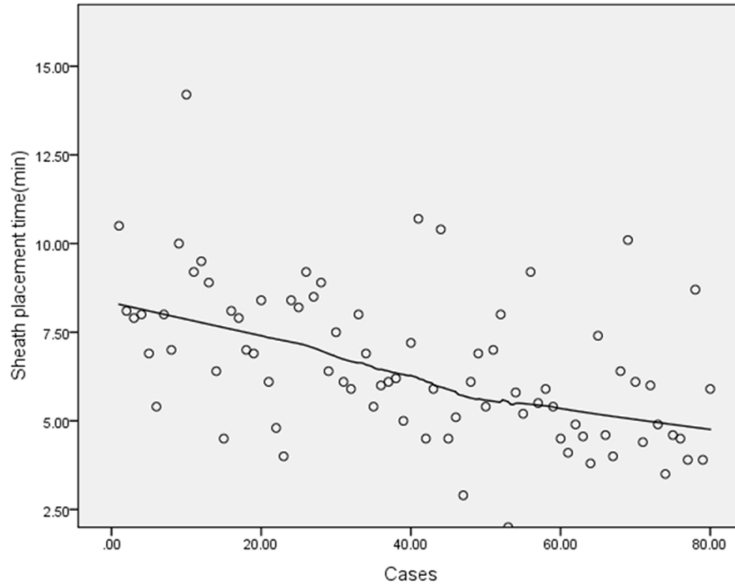


Figure 4. Scatter plot between sheath placement time and cases.

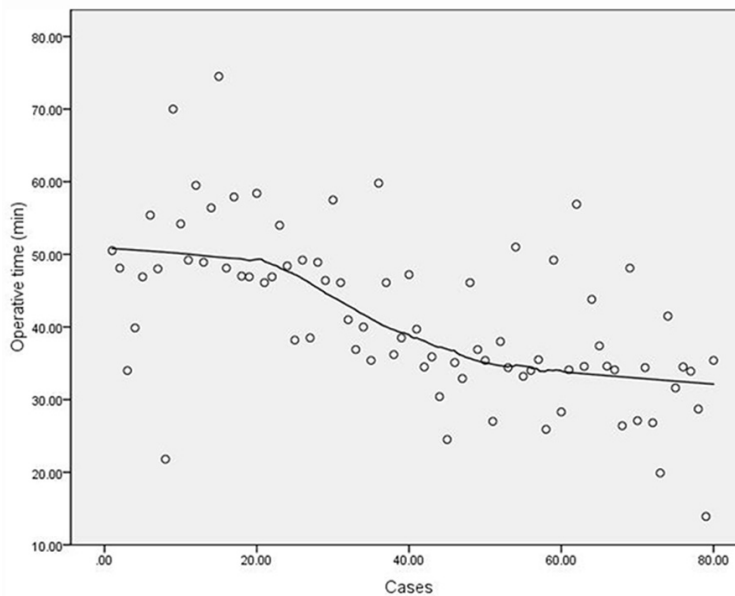


Figure 5. Scatter plot between operation time and cases.

severity of complications. The Clavien-Dindo classification of surgical complications can be used to objectively group adverse events in terms of severity [20]. Therefore, sheath placement was measured, as well as Double-J stent placement, operation times, stone-free rate, and complication rate.

The sheath placement and operation times fell significantly as the surgeon gained experience (from Group 1 to Group 4). No significant chang-

es were observed among-group differences in terms of the stone-free rate or complications. However, the numbers of residual calculi and complications fell over time. No major complications (Clavien-Dindo grades III-V) were found in the 40 cases, which was a reasonable estimate of the experience required to attain the plateau of the learning curve, as revealed by evaluation of sheath placement and operation times. The shorter learning curve associated with SF-URS may be explained by the following: (1) SF-URS automatically monitors and controls RPP intraoperatively, reducing the rates of postoperative fever, urosepsis, and kidney rupture; (2) under high-perfusion flow, the field of vision is clear and stones are broken continuously; (3) gravel particles are efficiently and automatically sucked out while stones are being crushed, eliminating the need for stone basketing; and (4) the sheath material is transparent, enabling targets to be identified under direct visualisation, without fluoroscopic guidance.

Our study has certain limitations. The surgeon performed other endourological procedures before learning the new procedure. Therefore, he had extensive experience and his learning curve may have been less steep than that of a surgeon who had just completed a residency.

Conclusions

SF-URS was safe and efficient, even during the learning curve. A surgeon without previous experience in SF-URS demonstrated competence after 40 procedures.

Acknowledgements

Jiangxi Provincial Science and Technology Agency youth science fund projects (20181B-AB215011).

Learning curve for suctioning flexible ureteroscopy

Disclosure of conflict of interest

None.

Address correspondence to: Dr. Wanlong Tan, Department of Urology, Nanfang Hospital, Southern Medical University, No.1838, North of Guangzhou Avenue, Guangzhou City 510515, Guangdong Province, China. E-mail: dxl19851118@163.com

References

- [1] Zhu X, Song L, Xie D, Peng Z, Guo S, Deng X, Liu S, Fan D, Huang J, Liu T, Du C, Zhu L, Yang Z, Peng G, Hu M, Yao L, Zeng M, Zhong J, Qing W and Ye Z. Animal experimental study to test application of intelligent pressure control device in monitoring and control of renal pelvic pressure during flexible ureteroscopy. *Urology* 2016; 91: 11-15.
- [2] Deng X, Song L, Xie D, Huang J, Zhu L, Su G, Liao X, Zhang Y, Wang X and Fan D. Suctioning flexible ureteroscopy with automatic control of renal pelvic pressure: a porcine model. *Int J Clin Exp Med* 2016; 9: 6563-6568.
- [3] Deng X, Song L, Xie D, Zhu L, Yao L, Huang J, Guo S and Peng Z. Suctioning flexible ureteroscopy with automatic control of renal pelvic pressure. *Urology* 2015; 195: e782-e782.
- [4] Deng X, Song L, Xie D, Fan D, Zhu L, Yao L, Wang X, Liu S, Zhang Y and Liao X. A novel flexible ureteroscopy with intelligent control of renal pelvic pressure: an initial experience of 93 cases. *J Endourol* 2016; 30: 1067-1072.
- [5] Song Y, Ma Y, Song Y and Fei X. Evaluating the learning curve for percutaneous nephrolithotomy under total ultrasound guidance. *PLoS One* 2015; 10: 226-231.
- [6] Cruz JASD, Thiago C, Barros UDQ, Roca RLFDL, Lima JPC and Migueli RD. MP33-17 The learning curve for retrograde intra-renal surgery (rirs): how many cases are necessary? *Journal of Urology* 2016; 195: e443.
- [7] Komori M, Izaki H, Daizumoto K, Tsuda M, Kusuhara Y, Mori H, Kagawa J, Yamaguchi K, Yamamoto Y and Fukumori T. Complications of flexible ureteroscopic treatment for renal and ureteral calculi during the learning curve. *Urol Int* 2015; 95: 26-32.
- [8] Xu Y, Min Z, Wan SP, Nie H and Duan G. Complications of retrograde intrarenal surgery classified by the modified Clavien grading system. *Urolithiasis* 2017; 46: 1-6.
- [9] Smk A and Salavati A. Endovisually guided zero radiation ureteral access sheath placement during ureterorenoscopy. *Minim Invasive Ther Allied Technol* 2017; 27: 1-5.
- [10] Peng Y, Xu B, Zhang W, Li L, Liu M, Gao X and Sun Y. Retrograde intrarenal surgery for the treatment of renal stones: is fluoroscopy-free technique achievable? *Urolithiasis* 2015; 43: 265-270.
- [11] Sanguedolce F, Bozzini G, Chew B, Kallidonis P and de la Rosette J. The evolving role of retrograde intrarenal surgery in the treatment of urolithiasis. *Eur Urol Focus* 2017; 3: 46-55.
- [12] Salvadó JA, Lucas C, Hector G, Francisco R and Gastón A. Subcapsular renal-infected hematoma after retrograde intrarenal surgery: a rare but serious complication. *J Endourol Case Rep* 2016; 2: 52-54.
- [13] Berardinelli F, Francesco PD, Marchioni M, Cera N, Proietti S, Hennessey D, Dalpiaz O, Cracco C, Scoffone C and Schips L. Infective complications after retrograde intrarenal surgery: a new standardized classification system. *Int Urol Nephrol* 2016; 48: 1757-1762.
- [14] Song F, Gong B, Hao Z, Li Z, Zhou J, Zhang Y and Liang C. Risk factors of infectious complications following flexible ureteroscope with a holmium laser: a retrospective study. *Int J Clin Exp Med* 2015; 8: 11252-11259.
- [15] Altay B, Erkurt B, Kiremit MC and Guzelburc V. A rare complication of ureteral double-J stenting after flexible ureteroscopy: renal parenchymal perforation. *Turk J Urol* 2015; 41: 96-98.
- [16] Azili MN, Ozcan F and Tiryaki T. Retrograde intrarenal surgery for the treatment of renal stones in children: factors influencing stone clearance and complications. *J Pediatr Surg* 2014; 49: 1161-1165.
- [17] Yahsi S, Tonyali S, Ceylan C, Yildiz KY and Ozdal L. Intraparenchymal hematoma as a late complication of retrograde intrarenal surgery. *Int Braz J Urol* 2017; 43: 367-370.
- [18] Levy MM, Artigas A, Phillips GS, Rhodes A, Beale R, Osborn T, Vincent JL, Townsend S, Lemeshow S and Dellinger RP. Outcomes of the Surviving Sepsis Campaign in intensive care units in the USA and Europe: a prospective cohort study. *Lancet Infect Dis* 2012; 12: 919-924.
- [19] Kauer PC, Laguna MP, Alivizatos G, Joyce A, Muschter R, Swartz R, Tolley D de la Rosette JJ; ESUT. Present practice and treatment strategies in endourological stone management: results of a survey of the European Society of Uro-technology (ESUT). *Eur Urol* 2005; 48: 182-188.
- [20] Dindo D, Demartines N and Clavien PA. Classification of surgical complications: a new proposal with evaluation in a cohort of 6336 patients and results of a survey. *Ann Surg* 2004; 240: 205-13.