

Case Report

Nonoperative management of a liponecrotic lump after augmentation mammoplasty with autologous fat injection: a case report and review of the literature

Xiao-Ling Chen¹, Qing-Qing Fang^{1,2}, Xiao-Feng Wang^{1,2}, Wan-Yi Zhao^{1,2}, Min-Xia Zhang¹, Chun-Ye Chen¹, Kai Xu¹, Li-Hong Wu¹, Wei-Qiang Tan^{1,2}

¹Department of Plastic Surgery, The Fourth Affiliated Hospital, School of Medicine, Zhejiang University, Zhejiang Province, PR China; ²Department of Plastic Surgery, The Sir Run Run Shaw Affiliated Hospital, School of Medicine, Zhejiang University, Zhejiang Province, PR China

Received March 19, 2019; Accepted May 13, 2019; Epub July 15, 2019; Published July 30, 2019

Abstract: Augmentation mammoplasty with autologous fat injection is becoming increasingly popular. Many unfavorable cases resulting from the procedure have been reported, but little attention has been paid to these issues. Here, we present a case report contradicting the opinion that autologous fat injection is simple, easy, and safe in breast cosmetic surgery; we also describe nonoperative management, which should be considered in many cases, contrasting the usual opinion that the solid lump should be excised openly. In our case, a 26-year-old girl found a palpable lump in her breast after augmentation mammoplasty with autologous fat injection. Sonography demonstrated the lump in the right breast. Ultrasound-guided fine-needle aspiration biopsy (US-FNAB) was performed to identify the lump. The patient was managed conservatively due to the patient's wish, based on the fact that the biopsy was confirmed as a solid, inflammatory mass. We also reviewed the existing literature on the subject of complications and treatments of augmentation mammoplasty with autologous fat injection. Autologous fat grafting of the breast is not a simple procedure, and it should be performed by well-trained and skilled plastic surgeons. Purifying the extracted fat granules during surgery, strictly controlling the injection volume, and injecting diffusely in multiple layers to allow the fat granules to be distributed evenly within the breast are effective methods of reducing postoperative complications. US-FNAB is recommended for seeking an accurate diagnosis of the breast lump after breast augmentation with autologous fat injection; no surgical intervention is necessary in many cases if the biopsy shows a liponecrotic lump.

Keywords: Autologous fat injection, augmentation mammoplasty, liponecrotic lump, ultrasound-guided fine needle aspiration biopsy

Introduction

Autologous fat is an excellent soft tissue filler, given its abundance, ease of harvest, and minimal invasiveness [1]. Furthermore, because of favorable histocompatibility, there are no subsequent problems such as immunological rejection or toxic substance absorption. So, autologous fat injection mammoplasty is widely applied for cosmetic purposes in clinic. Previous refinements reported by many surgeons, particularly Coleman and Saboeiro [2], have enabled structural fat grafting to be effective. However, many studies have described complications after a fat injection and surgery of the breast [3-5]. This article aims to describe a liponecrotic lump after augmentation mamma-

plasty with autologous fat injection to highlight the fact that autologous fat injection of the breast is not an easy or uncomplicated technique. Ultrasound-guided, fine needle aspiration biopsy (US-FNAB) should be considered when seeking an accurate diagnosis of the breast lump; and surgical intervention may not be necessary if the biopsy shows a liponecrotic lump. We also review the existing literature on the subject of complications and treatment of augmentation mammoplasty with autologous fat injection.

Case report

A 26-year-old female underwent a bilateral augmentation mammoplasty with autologous fat

Nonoperative management of a liponecrotic lump

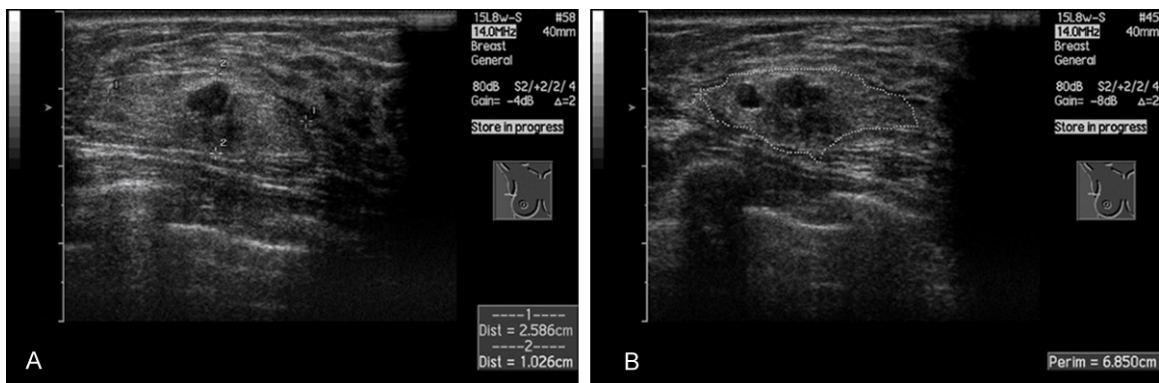


Figure 1. Images of nodules in the right breast. A: An equal echo nodule measured 2.6 cm × 1.0 cm was in the upper external quadrant of the right breast. B: There were several low echo-level nodules in the equal echo nodule.

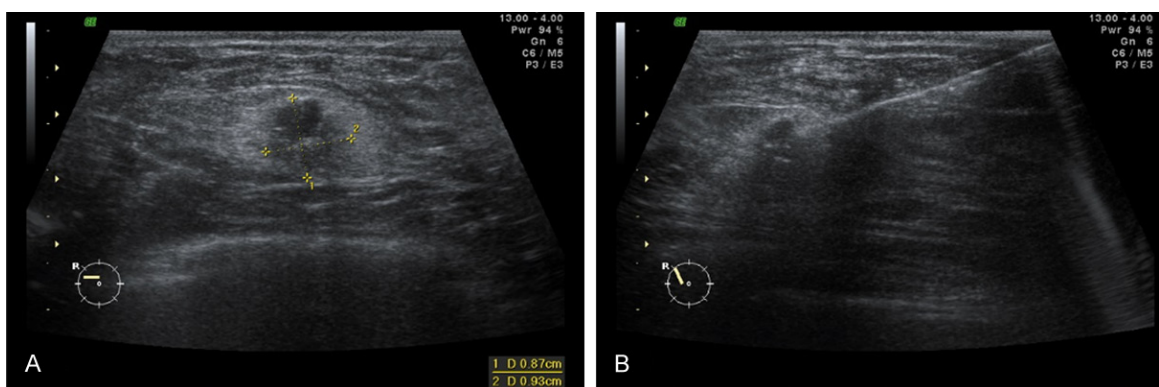


Figure 2. Images of the fine needle aspiration procedure. A: Location of the low echo-level nodules inside the equal echo nodule. B: A fine needle penetrated into the low echo-level nodule.

injection in our hospital 6 months before attending our clinic for a palpable lump, without any obvious pain or relationship with her menstrual cycle. About 90 mL of fatty tissue, obtained from her abdomen by a liposuction device under a negative pressure of 0.09 atm, was injected into each side of the posterior space of the breast. Sonographic examination of the breasts revealed thickened mammary gland tissue with honeycombed ductal hyperplasia and axillary lymph nodes. Also, there was an equal echo lump measuring 2.6 cm × 1.0 cm (**Figure 1A**) in the upper external quadrant of the right breast, with several low-echo-level nodules in it (**Figure 1B**).

The patient had a strong desire to identify the lump in her breast, but she was unwilling to undergo a surgery. Therefore, she underwent a US-FNAB under local anesthesia, then three pieces of parenchymal tissue were aspirated from the lump using a freehand biopsy gun (**Figure 2**).

Pathologic analysis disclosed necrotic adipose tissue with some neutrophil or multinucleated giant-cell infiltration (**Figures 3**). There were normal tissues for comparison (**Figure 4**). No sign of malignancy was detected. The final pathologic diagnosis was confirmed to be chronic inflammation of the right breast accompanied by lipogranuloma formation. On the basis of these findings, the patient was managed conservatively according to her wish, without any other therapy including surgery. Regular follow-up was suggested to the patient.

Discussion

Autologous fat transplantation was initially performed by Neuber in 1893 to fill in depressed scars [6]. Since then, some plastic surgeons have utilized this method to improve facial and body contour depressions and scars [7, 8]. Orthopedic surgeons have used fat-free grafts to fill in bony defects, and neurosurgeons have used them for the treatment of skull, dura, and

Nonoperative management of a liponecrotic lump

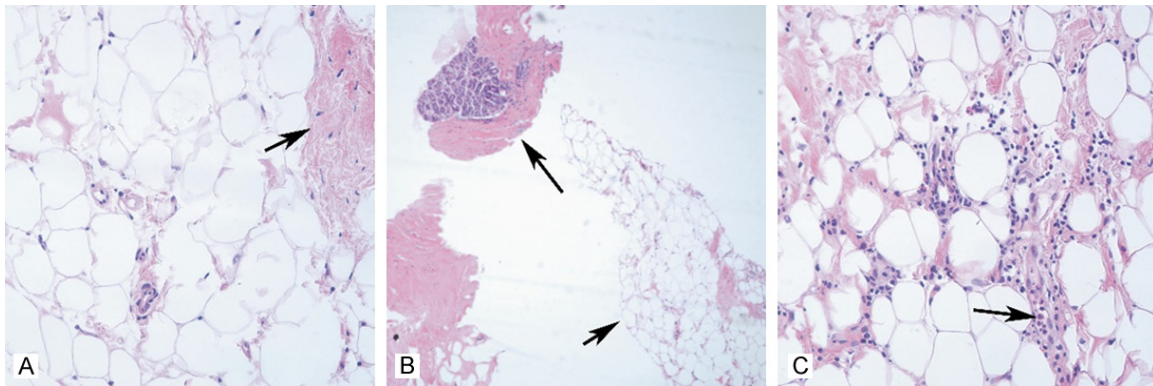


Figure 3. Images of tissue slice with microscope. A: Adipose cell pervasion in the whole visual field and fibrous tissue in the right upper field of vision (arrow) (H&E, 400 ×); B: Lobule of mammary gland with fibrous tissue around (arrow, long) showing in the left top visual field; and adipose tissueshowing in the right bottom visual field (arrow, short) (H&E, 100 ×); C: Necrotic adipose tissue and some neutrophils or multinucleated giant cells (arrow) infiltrated among them (H&E, 400 ×).

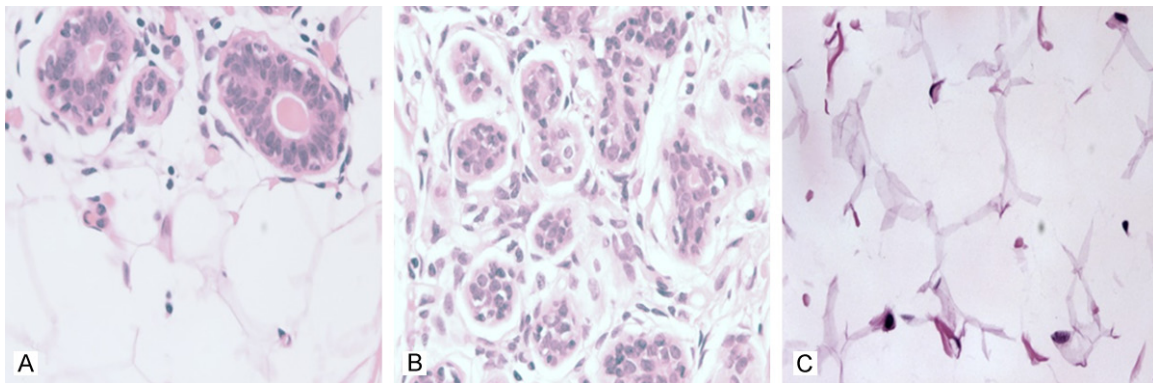


Figure 4. Images of tissue slice with microscope. A: Normal lobule of mammary gland and adipose tissue. B: Normal mammary gland. C: Normal adipose tissue. (H&E, 400 ×).

brain defects [9]. The first report about the use of autologous fat in breast reconstruction, dating back to 1895, was performed by Czerny [4]. Since then, several surgeons have used fat-free grafts for the reconstruction of breast defects. But this technique was not widely used until the 1980s, when liposuction techniques became more refined and acquisition of adipose tissue became more straightforward [4, 10]. In 1987, Bircoll [11] presented the detailed technique of breast augmentation with fat injection. Later that year, however, the American Society of Plastic and Reconstructive Surgeons recommended that autologous fat grafting of the breast was prohibited because calcifications secondary to fat necrosis can developed into breast cancer, and fat grafting-induced radiologic changes can obscure and delay the diagnosis of subsequent breast cancer [12]. However, the “structural fat grafting” technique devised by Coleman [2] was tested and found

to be safe and effective by others, such as Missana et al. [13]. Spear [14] reported encouraging results using fat injection into breasts. Based on such reports, many surgeons readopted fat grafting.

Augmentation mammoplasty with autologous fat injection has been welcomed for its benefits of being minimally traumatic, providing additional body contouring by removing fat from the donor and without immunologic rejection. Nevertheless, it is not as safe a procedure as has been thought. It is associated with risks of fat necrosis, infection, multiple cyst formation, calcification, and induration, some of which are difficult to distinguish from a breast tumor [15], plus the belief that breast cancer screens will always detect abnormalities [3, 14]. These problems not only directly influence surgical efficacy, but also result in patients’ physical and mental burden. Some reports have

Nonoperative management of a liponecrotic lump

described the presence of liponecrotic pseudocysts after fat injection into the breast [5, 7, 16]. Giant cyst formation and subcutaneous induration are known to be the results of single large-volume injections of fat into inadequate planes [2, 5, 7, 11, 14, 17]. All the above make the value of this technique controversial [5-7, 16, 18, 22].

However, there is no set of fixed procedures that can be guaranteed to be without problems. How to deal with the problems seems to be more significant because some complications are inevitable. The solid lump is usually excised [3, 4, 6, 7, 16-19] openly, including adjoining breast tissue, because of the adherent nature of this lesion and the lack of an intact capsule, ultimately resulting in the deformity and obvious scars of the breast. Some surgeons choose to incise around the areola or the submammary fold or in the axilla so that the scars will be virtually hidden. However, this approach results in greater injury to mammary tissue in the long run, and it is sometimes hard to reach the distant lump.

Bircoll, who started the modern era of autologous fat grafting to the breast [23], believed that nonoperative management should be considered in most of the cases; the injection technique, especially, met his criteria [24]. He suspected that the complications noted were more a matter of technique than a basic fault in the concept of fat transfer. In his series of 650 cosmetic breast augmentations using autologous fat injection, there was a 1.25% incidence of microcalcifications, and all of which were detectable only on follow-up mammography, and no surgical interventions were necessary [24]. He believed that in these cases, the cause was simply the excess of fat injected into a single site; large depositions of fat violated the original description of the technique and were bound to result in necrosis and other complications.

We diagnosed and managed the reported complications properly without postoperative deformity or concern about malignancy of the breast. Physical examination and imaging analyses (e.g., mammography, ultrasound, CT, or MRI) assist in diagnosing the complications, but cannot alone lead to a final diagnosis. Excisional biopsy would result in an obvious scar and breast contour deformity, which are unacceptable for most young patients. Thus, US-FNAB is

a simple, reliable and effective alternative for breast lump diagnosis after augmentation mammoplasty with autologous fat injection. US-FNAB offers a definitive pathologic diagnosis and the basis for a subsequent treatment plan. Most importantly, it frees a large number of patients from surgery. We think the US-FNAB should be considered as an exact diagnosis of breast lump after augmentation mammoplasty with autologous fat injection. Nonoperative management with follow-up examination is acceptable by the patient whose cytologic diagnosis is benign, especially young patients, who have great fear of surgery and do not want their breasts misshaped by scars.

Since autologous fat injection offers so much benefit in all of its applications, we recommend more widespread teaching of the proper technique. The results achieved by this technique depend on the fat harvesting technique, the volume injected, and the area injected. Complications can be prevented by multiple injections of small fat amounts over time. Inadequate fat injection into the breasts can be considered the consequence of poor training [17]. Autologous fat grafting of the breast is not a simple procedure; it should be performed by well-trained and skilled plastic surgeons. There is a concern that fat injection is being performed by untrained individuals [17].

Mu et al. [4] reported on their experience: During intramammary autologous fat injection, fat should be injected diffusely in multiple layers, allowing fat granules to be distributed into the layers under the pectoralis major muscle, within the pectoralis major muscle, in the retro-mammary space, and within the subcutaneous tissue. Fat granules were injected as the needle was retracted, allowing them to fill the deeper tissues as a conduit was being created. The amount of fat injected per side using this diffuse injection method should not exceed 120 mL; also, the amount injected was determined by breast size, with smaller breasts requiring smaller injection volumes and larger breasts needing larger volumes.

Conclusion

Autologous fat grafting of the breast is not a simple procedure, and it should be performed by well-trained and skilled plastic surgeons. Purifying the extracted fat granules during sur-

gery, strictly controlling the injection volume, and injecting diffusely in multiple layers to allow the fat granules to be distributed evenly within the breast are effective methods to reduce postoperative complications. The US-FNAB should be considered for obtaining an exact diagnosis of the breast lump after autologous fat augmentation with injection, and surgical intervention may not be necessary if the biopsy shows a liponecrotic lump.

Acknowledgements

This work was supported by grants from Zhejiang Provincial Medical and Healthy Science Foundation of China (2019ZD028), Science and Technology Project of Yiwu City (Y18034), National Natural Science Foundation of China (No. 81671918), and National Key Research Program of China (2016YFC1101004).

Disclosure of conflict of interest

None.

Address correspondence to: Wei-Qiang Tan, Department of Plastic Surgery, The Fourth Affiliated Hospital, School of Medicine, Zhejiang University, Zhejiang Province, PR China; Department of Plastic Surgery, The Sir Run Run Shaw Affiliated Hospital, School of Medicine, Zhejiang University, Zhejiang Province, PR China. Tel: +86-13666658609; E-mail: tanweixxx@zju.edu.cn

References

- [1] Li FC, Chen B and Cheng L. Breast augmentation with autologous fat injection: a report of 105 cases. *Ann Plast Surg* 2014; 73 Suppl 1: S37-42.
- [2] Coleman SR and Saboeiro AP. Fat grafting to the breast revisited: safety and efficacy. *Plast Reconstr Surg* 2007; 119: 775-785.
- [3] Hyakusoku H, Ogawa R, Ono S, Ishii N and Hirakawa K. Complications after autologous fat injection to the breast. *Plast Reconstr Surg* 2009; 123: 360-370.
- [4] Mu DL, Luan J, Mu L and Xin MQ. Breast augmentation by autologous fat injection grafting: management and clinical analysis of complications. *Ann Plast Surg* 2009; 63: 124-127.
- [5] Al Sufyani MA, Al Hargan AH, Al Shammari NA, Al Sufyani MA. Autologous fat transfer for breast augmentation: a review. *Dermatol Surg* 2016; 42: 1235-1242.
- [6] Pulagam SR, Poulton T and Mamounas EP. Long-term clinical and radiologic results with autologous fat transplantation for breast augmentation: case reports and review of the literature. *Breast J* 2006; 12: 63-65.
- [7] Castello JR, Barros J and Vazquez R. Giant liponecrotic pseudocyst after breast augmentation by fat injection. *Plast Reconstr Surg* 1999; 103: 291-293.
- [8] Mazzola RF and Mazzola IC. History of fat grafting: from ram fat to stem cells. *Clin Plast Surg* 2015; 42: 147-153
- [9] Billings E Jr, May JW Jr. Historical review and present status of free fat graft autotransplantation in plastic and reconstructive surgery. *Plast Reconstr Surg* 1989; 83: 368-381.
- [10] Bircoll M, Novack BH. Autologous fat transplantation employing liposuction techniques. *Ann Plast Surg* 1987; 18: 327-329.
- [11] Bircoll M. Cosmetic breast augmentation utilizing autologous fat and liposuction techniques. *Plast Reconstr Surg* 1987; 79: 267-271.
- [12] Report on autologous fat transplantation. ASPRS ad-hoc committee on new procedures, september 30, 1987. *Plast Surg Nurs* 1987; 7: 140-141.
- [13] Missana MC, Laurent I, Barreau L and Balleuier C. Autologous fat transfer in reconstructive breast surgery: indications, technique and results. *Eur J Surg Oncol* 2007; 33: 685-690.
- [14] Spear SL, Wilson HB and Lockwood MD. Fat injection to correct contour deformities in the reconstructed breast. *Plast Reconstr Surg* 2005; 116: 1300-1305.
- [15] Kneeshaw PJ, Lowry M, Manton D, Hubbard A, Drew PJ and Turnbull LW. Differentiation of benign from malignant breast disease associated with screening detected microcalcifications using dynamic contrast enhanced magnetic resonance imaging. *Breast* 2006; 15: 29-38.
- [16] Erol OO, Agaoglu G and ysal AO. Liponecrotic pseudocysts following fat injection into the breast. *Plast Reconstr Surg* 2010; 125: 168e-170e.
- [17] Kim H, Yang EJ and Bang SI. Bilateral liponecrotic pseudocysts after breast augmentation by fat injection: a case report. *Aesthetic Plast Surg* 2012; 36: 359-362.
- [18] Montanana Vizcaino J, Baena Montilla P and Benito Ruiz J. Complications of autografting fat obtained by liposuction. *Plast Reconstr Surg* 1990; 85: 638-639.
- [19] Millard GF. Liponecrotic cyst after augmentation mammoplasty with fat injections. *Aesthetic Plast Surg* 1994; 18: 405-406.
- [20] Kwak JY, Lee SH, Park HL, Kim JY, Kim SE, Kim EK. Sonographic findings in complications of cosmetic breast augmentation with autologous fat obtained by liposuction. *J Clin Ultrasound* 2004; 32: 299-301.

Nonoperative management of a liponecrotic lump

- [21] Shakhov AA. Fat transplantation and breast augmentation. *Aesthetic Plast Surg* 2002; 26: 323-325.
- [22] Yamaguchi M, Matsumoto F, Bujo H, Shibasaki M, Takahashi K, Yoshimoto S, Ichinose M, Saito Y. Revascularization determines volume retention and gene expression by fat grafts in mice. *Exp Biol Med (Maywood)* 2005; 230: 742-748.
- [23] Lee KS, Seo SJ, Park MC, Park DH, Kim CS, Yoo YM and Lee IJ. Sepsis with multiple abscesses after massive autologous fat grafting for augmentation mammoplasty: a case report. *Aesthetic Plast Surg* 2011; 35: 641-645.
- [24] Bircoll M. Liponecrotic pseudocysts following fat injection into the breast. *Plast Reconstr Surg* 2010; 126: 2289.