

Original Article

Time intervals between lengthening of growing rods can influence effectiveness in the treatment of early onset scoliosis

Derong Xu^{1,2*}, Zheng Li^{1*}, Jianguo Zhang¹, Jianxiong Shen¹, Youdong Song¹, Qianyu Zhuang¹, Shugang Li¹

¹Department of Orthopedic Surgery, Peking Union Medical College Hospital, Beijing, China; ²The Affiliated Hospital of Qingdao University, Qingdao, Shandong Province, China. *Co-first authors.

Received April 8, 2019; Accepted June 10, 2019; Epub September 15, 2019; Published September 30, 2019

Abstract: Objective: The aim of the current study was to investigate the influence of different time intervals between lengthening of growing rods on effectiveness levels in the treatment of early onset scoliosis. Method: A retrospective study of patients undergoing GR treatment, from July 2002 to February 2016, was conducted. This study defined lengthening at a 12-month interval as a research event in group A and two continuous lengthenings at 6-month intervals as a research event in group B. Therapeutic outcomes at the end of the events were compared between the two groups. The impact of different factors on therapeutic outcomes was analyzed using multiple linear regression analysis. Present findings were confirmed by independent sample t-tests and covariance. Result: Multiple linear regression analysis showed that different time intervals between lengthenings were the only factors of improvement of T₁-S₁ length and sitting heights. In addition, both preoperative Cobb angles (starting point) and gender could affect changes in the Cobb angle and standing heights (P=0). Further analysis by ANCOVA and independent sample t-tests showed that the Cobb angle change in group A was 12.04° ± 1.08°. T₁-S₁ increased by 1.05 ± 0.72 cm and the sitting height increased by 2.52 ± 1.40 cm. Standing height increased by 5.64 ± 1.84 cm. In group B, the change in the Cobb angle was 23.49° ± 1.16°. T₁-S₁ increased by 1.97 ± 0.88 cm and the sitting height increased by 3.84 ± 1.82 cm. Standing height increased by 7.72 ± 2.99 cm. A total of 10 implant-related complications occurred in group A. No implant-related complications occurred in group B. Differences between group A and group B were statistically significant (P<0.05). Conclusion: There was greater growth and correction, as well as fewer complications, in those lengthened at 6 months, compared with those lengthened at 12 months.

Keywords: Growing rod, scoliosis, early onset, lengthening interval, effectiveness of surgery

Introduction

Scoliosis is a three-dimensional spinal deformity. It involves the thorax, ribs, and pelvis, including coronal, sagittal, and axial anomalies [1, 2]. It can influence the growth of the spine and lungs, development of cardiopulmonary function, and neurological function [3, 4]. Scoliosis is common in adolescence, but also frequently in children under 10 years old. It is characterized by early onset, rapid progress, and severe deformities, causing serious harm to children's physical and mental health [5]. Treatment of early onset scoliosis, with long and severe curves, has been a problem [6, 7]. Conservative treatment, such as wearing a brace, has been less efficient. Spinal fusion surgery may limit the growth and development of children [8]. Growing rods (GR), however, have

emerged as an effective choice for children with early onset scoliosis [6, 9, 10]. This method can achieve deformity correction, to a certain degree, maintaining the growth potential of the spine and improving thoracic development [11, 12]. This method can buy time for these children, waiting to perform spinal fusions at an appropriate age. The GR technique is different from other fusion techniques. It requires continuous lengthening to reduce implant restriction on growth [13]. Concerning time intervals between lengthening, the consensus has been to lengthen every 6 to 12 months. However, controversy still remains regarding which one is better, 6 or 12 months. Therefore, the current study analyzed influences of different intervals on clinical effects, aiming to identify the ideal lengthening interval for GR.

Growing rods in the treatment of early onset scoliosis

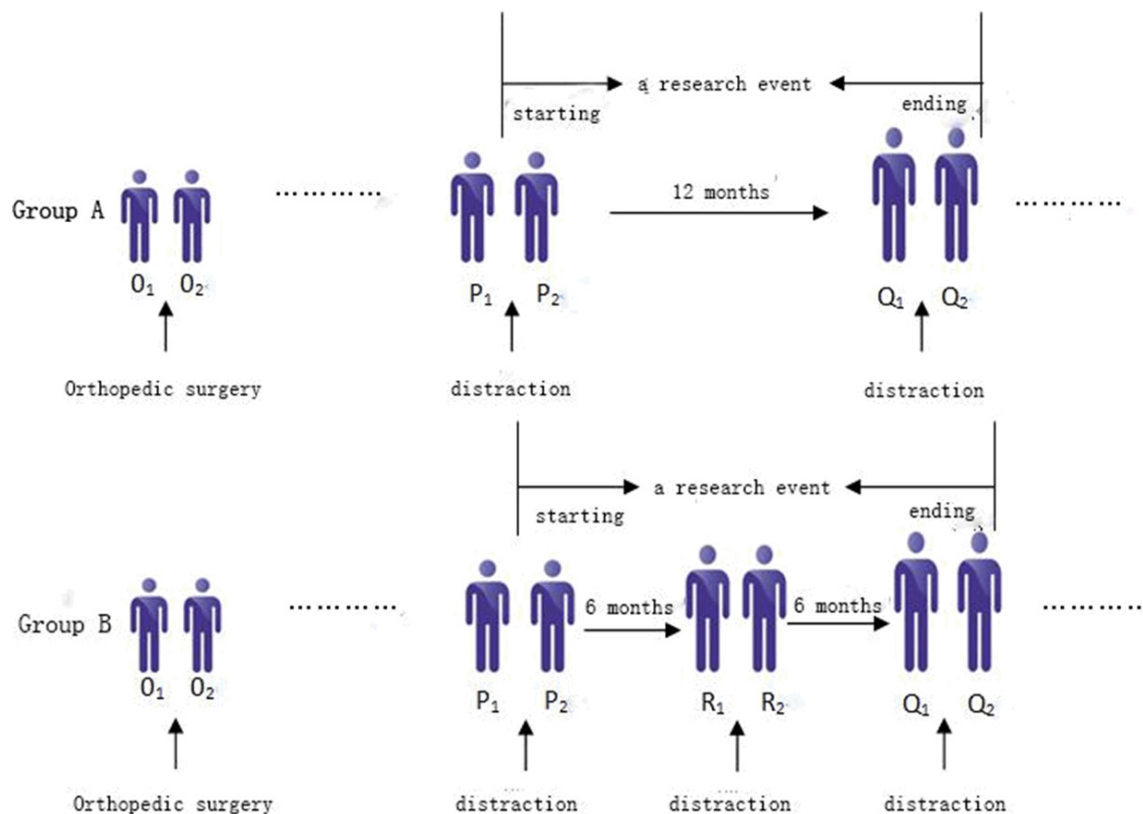


Figure 1. Selection of research events and time points. O: initial surgery; O_1 : pre-operation; O_2 : post-operation; P: outset of research events; P_1 : pre-operation; P_2 : post-operation; Q: destination of research events; Q_1 : pre-operation; Q_2 : post-operation; R: a distraction of group B at 6th months; R_1 : pre-operation; R_2 : post-operation.

Materials and methods

General materials

From July 2002 to February 2016, 56 pediatric patients with early-onset scoliosis underwent GR treatment. Radiological tests were completed within one week, preoperatively and postoperatively. Indications for GR orthopedic surgery for all patients were as follows [14]: (1) Cobb angle was over 50° and progressed in spite of conservative treatment; (2) Age of onset was less than 10 years old, with an obvious longitudinal spinal growth potential (Risser sign I or less); and (3) Spinal flexibility was over 30%.

A retrospective review of clinical and radiological data of the 56 patients was performed. Clinical information included gender, diagnosis, age at each surgery, and lengthening intervals, as well as preoperative and postoperative sitting heights and standing heights. Radiographic data included T_1 - S_1 length, Cobb angle, and implant-related complications, such as rod breakage, hook dislodgement, and screw pull-outs. Data was collected and measured by two

physicians, independently. All perioperative complications and related treatments were recorded.

Methods

Based on statistical analysis of clinical data, due to Chinese patient noncompliance, economic conditions, lack of transportation, and other unexpected factors, lengthening intervals were not consistently 6 or 12 months. Therefore, this study defined study subjects as therapeutic segments whose lengthening interval were exactly 6 or 12 months. Except for the initial surgery, lengthening, at 12 month intervals, was defined as a research event and placed into group A. Two continuous lengthening events, at 6-month intervals, were defined as the other research event and placed into group B (Figure 1). Related data at different time points of every research events in the two groups was recorded (Table 1).

In this study, one patient may have any numbers of A and (or) B events, respectively, during the entire lengthening process. First, the cur-

Growing rods in the treatment of early onset scoliosis

Table 1. Required data in research events

Time point	Required data					
O ₁	Sex	Age	Cobb angle	Risser		
P ₂	Age	Length of T ₁ -S ₁	Sitting height	Standing height	Risser	The number of distractions before
R ₁	Cobb angle					
R ₂	Cobb angle					
Q ₁	Cobb angle					
Q ₂	Cobb angle	Length of T ₁ -S ₁	Sitting height	Standing height		

Table 2. Possible affecting factors on outcomes and indicators of therapeutic effects

Possible affecting factors on outcomes Independent variables	Indicators of therapeutic effect Dependent variables
Sex	Change of Cobb angle
Age at O ₁	Added length of T ₁ -S ₁
Cobb angle at O ₁	Added length of sitting height
Risser at P ₂	Added length of standing height
Cobb angle at R ₁	
Cobb angle at Q ₁	
Number of distractions before P ₂	
Number of distractions in research event	

Change of Cobb angle in group A = Cobb angle at Q₁-Cobb angle at Q₂; Change of Cobb angle in group B = (Cobb angle at R₁-Cobb angle at R₂) + (Cobb angle at Q₁-Cobb angle at Q₂); Gained length of T₁-S₁=T₁-S₁ at Q₂-T₁-S₁ at P₂; Gained length of sitting height = sitting height at Q₂-sitting height at P₂; Gained length of standing height = standing height at Q₂-standing height at P₂.

rent study analyzed potential factors that may influence therapeutic outcomes (Table 2), in which the number of lengthening in the research event was of primary interest. With those factors as independent variables and the two main indicators of therapeutic effects (Cobb angle change and T₁-S₁ length elongation) and two secondary indicators (sitting height and standing height) as dependent variables, multiple linear regression analysis was conducted (Table 2). Based on results of multiple linear regression, this study further explored the impact of different numbers of lengthening events on therapeutic outcomes using independent sample t-tests and covariance.

The current study was approved by the Ethical Committee of Peking Union Medical College Hospital. All patients provided written informed consent for the study and surgery.

Results

All patients

A total of 34 patients, containing 69 research events, were observed. The average follow-up

was 3.2 years (range, 2.1-5.5 years). Lengthening intervals with exactly two continuous 6-month periods or one 12-month period were included in this study. There were 25 females and 9 males, with initial orthopedic surgery occurring at an average age of 6.30 ± 2.56 years (range, 3-10 years). Diagnoses included 32 cases of congenital scoliosis, 1 case of idiopathic scoliosis, and 1 case of neuromuscular scoliosis.

Of those 69 research events, the average Cobb angle change per year was 17.35° ±

8.675, while T₁-S₁ lengths increased from 30.95 ± 4.29 cm to 32.46 ± 4.52 cm. Paired sample t-tests showed that significant correction and spinal growth were achieved after one year of lengthening (P<0.001).

Multiple linear regression results

Taking four indicators of therapeutic effects as dependent variables, respectively, and the different numbers of lengthening events and other factors as independent variables, stepwise multiple linear regression analysis was performed (inclusion criteria: P≤0.05) (Table 3).

Multiple linear regression analysis showed that different numbers of lengthening events was the only factor affecting added length of T₁-S₁ and sitting height. Therefore, independent sample t-tests were performed with different numbers of lengthening in the research event as a grouping variable. Regarding changes in Cobb angles and standing heights, Cobb angle at O₁ point and gender differences influenced both separately. Thus, taking Cobb angle at O₁ point and gender as covariates and different numbers of lengthening events as a grouping vari-

Growing rods in the treatment of early onset scoliosis

Table 3. Result of multiple linear regression analysis

	Cobb angle		T ₁ -S ₁		Sitting height		Standing height	
	B	P	B	P	B	P	B	P
Sex		0.255		0.615		0.913	1.969	0.015
Age at O ₁		0.688		0.34		0.588		0.824
Cobb angle at O ₁	0.095	0.043		0.602		0.438		0.349
Risser at P ₂		0.914		0.528		0.199		0.739
Cobb angle at Q ₁		0.534		0.912		0.571		0.808
Number of distractions before P ₂		0.091		0.058		0.921		0.362
Number of distractions in research events	10.017	<0.001	1.077	<0.001	1.563	0.001	1.566	0.031
Model R ²		0.44		0.326		0.214		0.242

Because the Cobb angle of R₁ only exists in group B, multiple linear regression could not be performed. However, the results of simple single variable linear regression showed that the independent variable had no statistical significance (P>0.1).

Table 4. Comparisons between Group A and Group B

	Method	Group A	Group B	P
Change of Cobb angle (°)	Covariance	12.04 ± 1.08	23.49 ± 1.16	<0.001
Added length of T ₁ -S ₁ (cm)	Independent samples T test	1.05 ± 0.72	1.97 ± 0.88	<0.001
Added length of sitting (cm)	Independent samples T test	2.52 ± 1.40	3.84 ± 1.82	0.003
Added length of standing height (cm)	Covariance	5.64 ± 1.84	7.72 ± 2.99	0.002

able, covariance analysis (ANCOVA) was performed.

Group A vs. group B

There were 37 research events in group A and 32 research events in group B, respectively. Results from analysis of ANCOVA and independent sample t-tests showed that, after one year of lengthening, for group A, the change of Cobb angle was 12.04° ± 1.08°. For Group A, gained lengths of T₁-S₁, sitting heights, and standing heights were 1.05 ± 0.72 cm, 2.52 ± 1.40 cm, and 5.64 ± 1.84 cm, respectively. For group B, the change of Cobb angle was 23.49° ± 1.16°. Gained lengths of T₁-S₁, sitting heights, and standing heights were 1.97 ± 0.88 cm, 3.84 ± 1.82 cm and 7.72 ± 2.99 cm, respectively. These four indicators of therapeutic effects in group B were better than those in group A. Differences were statistically significant (P<0.05) (Table 4).

Complications

There were 10 research events with implant-related complications in group A. Hooks pulled out in 4 cases, screws loosened in 5 cases, and 2 rods broke (there was one case in which both screws loosened and hooks pulled out). The

rate of implant-related complications in group A was 27%, including patients that underwent revisions and implant replacement operations.

There were no implant-related complications in Group B, but there was 1 poor wound healing case. No other complications, including death, deep wound infections, spontaneous fusion, obvious crankshaft phenomenon, distal proximal junctional kyphosis, and severe spinal cord injuries, occurred. Differences in implant-related complications, analyzed by Fisher's exact test, were statistically significant (P=0.001).

Discussion

Treatment for scoliosis includes conservative management and spinal fusion surgery. Exercise, massages, electrical stimulation, and brace treatments are common non-surgical treatments. Previous studies have shown that, except for wearing a brace, other conservative therapies have been unable to inhibit the progression of scoliosis. However, even brace treatment cannot prevent the natural progression of curvature and achieve correction. Thus, the effects of conservative treatment are often limited [15]. For adolescent patients with severe scoliosis, satisfactory correction can be obtained without compromising spine and car-

Growing rods in the treatment of early onset scoliosis

diopulmonary function, via spinal fusion operations. For young children with longer and more severe deformities, however, spinal fusion surgery could restrict their growth potential. This could cause various problems, such as spine shortening and unbalanced trunk ratios and chest development. It could even result in functional disorders of other organs.

To solve this problem, in the 1960s, Dr. Harrington took lead in putting forward a kind of spinal orthopedic operation by implanting a single GR [16]. Based on that idea, John Moe et al. performed corrective operations for young patients, achieving strong results [17]. Later, according to the characteristics of pediatric spinal deformities, Pediatric ISOLA Scoliosis Implant System applied innovative dual rod implants in the treatment of early onset scoliosis. Today, this is called the GR technique. During the initial surgery, patients can achieve a certain degree of deformity correcting without too much paraspinal muscle and subperiosteal stripping, leading to less trauma [18, 19]. After surgery, they continue to wear a brace and undergo lengthening once every 6-12 months. Distraction surgery can be completed at the connector site with a small incision and short operative times. Thus, patients can recover quickly. When the patients finish growing, final spinal fusion can be carried out. Clinical applications have shown that, through regular distraction, the GR technique is able to control the progression of scoliosis and improve coronal and sagittal balance without disturbing the growth and development of the spine and thorax. Therefore, this is an ideal method for children with early onset scoliosis [19, 20].

The current study further proved that the GR technique can achieve satisfactory results in maintaining correction of the curve and keeping up with the growth of spine. After one year of lengthening treatment, the average change of Cobb angle in the 69 research events was 17.35°. Spinal deformities were improved greatly. The gained length of T₁-S₁ averaged 1.5 cm. This plays a significant role in promoting patient height growth, protecting the ability of spinal development, and maintaining the balance between the limbs and trunk.

Because of the ongoing growth of children, the GR technique requires continuous distractions. Most researchers have recommended length-

ening once every 6-12 months. However, the ideal distraction interval remains inconclusive. It has been suggested that repeated distractions may destroy the periosteum and cortical bone and increase incidence of spinal spontaneous fusions, making the spine stiffer and reducing growth potential [21, 22]. More surgeries, bringing higher costs, produces a heavier economic burden for families, affecting subsequent treatment [23]. Therefore, some have recommended minimizing the distractions before the final fusion, aiming to reduce surgical trauma and medical expenses. This means lengthening once every 12 months. Another view is that more frequent distractions can help doctors follow patient conditions, examining the progression of scoliosis more closely. This method may take advantage of the flexible and controllable GR technique to improve deformities and promote the growth of the spine. This view supports lengthening once every 6 months.

Therefore, controversy remains regarding which is better for patient therapeutic outcomes. The current study transformed the study subjects from patients to therapeutic segments, conforming to inclusion criteria as mentioned previously. The result was two groups of research events, one group consisting of distraction every 12 months and one group consisting of two continuous distractions every 6 months, with each research event lasting for one year. This study compared therapeutic results of both groups after one year of lengthening treatment. First, this study analyzed the factors which may have influenced therapeutic outcomes of these research events, including developmental differences between male and female patients (sex), severity of the deformity before primary Orthopedic surgery (Cobb angle at O₁), the time when children began to accept surgical intervention (the age at O₁), growth potential of the spine (the Risser sign at P₂), and numbers of distractions before every research event (multiple distractions may lead to spinal spontaneously fusion and adhesion of scar-tissue, making lengthening more difficult). Finally, the effects of different distraction intervals (once or twice in one year) were examined.

Multiple linear regression analysis showed that, in addition to different distraction intervals, Cobb angles prior to the initial surgery had sig-

Growing rods in the treatment of early onset scoliosis

nificant influence on changes of Cobb angle (possibly because the correction potential is greater when the Cobb angle before treatment is higher). At the same time, the standing height of male patients increased more obviously than female patients. Before stepping into puberty, the growth of boys, with long limbs but narrower trunks, is faster than girls. Girls have characteristics of shorter limbs but longer trunks. Therefore, this study compared the lengths of T_1 - S_1 and sitting heights, as well as the standing height, which includes extent of limbs. In multiple linear regression analysis with gained length of T_1 - S_1 and sitting heights as dependent variables, a different number of distractions was the only factor influencing outcomes.

Based on the above analysis, further investigations were conducted, aiming to compare differences of therapeutic effects between two groups using covariance analysis and independent sample t-tests, respectively. Although spinal deformities had been corrected and the length of the body was improved in both groups, changes of Cobb angle, gained lengths of T_1 - S_1 , sitting heights, and standing heights in group B were significantly better than those therapeutic indicators in group A. Results indicated that distractions once every 6 month had more advantages in preventing progression of scoliosis, stimulating spinal growing potential, and promoting physical development, compared to distractions once every 12 months.

Most complications of the GR technique were associated with implants, mainly including hooks that pulled out, screws that loosened, and rod breakages [24-26]. There are some possible reasons for these complications: 1) Loosened rods led to rotation and dislocation of the hooks and vertebral plate fractures were caused by hook blades cutting into where the hooks were placed; 2) Physical growth can loosen the connection between the spine and instruments; 3) Incorrect placement of internal implants and implant defects; and 4) Pediatric patient noncompliance, as excessive activity can cause displacement of the hooks and screws. Once internal fixation complications happen, patients always require revision surgery. This has a great influence on the physical and mental health of the children.

Comparing the data of group A and group B, the internal fixation complication rate of group B

was lower than that of group A. The reasons may be the following: 1) Prolonged stress can lead to excessive concentrations, causing decoupling and broken nails, broken rods, and other complications. As the spine has been actually locked between the two distraction surgeries, it cannot be released until the next operation [27]; and 2) The stability of fixation depends on the protection of the brace. Because of children's relatively poor therapeutic compliance, if they are not seen medically for a long time, the protective effects of the brace are greatly reduced. However, current statistical analysis did not indicate absolutely that the relatively longer interval is a risk factor for internal fixation complications. Although each of the complications happened in group A, internal fixation complications that occur over relatively long periods can be due to many factors. Thus, it is not accurate to conclude that those lengthened twice a year have lower rates of complications than those lengthened once a year. More in-depth research is necessary to answer this question. It can be assumed that distractions at appropriate times can release pressure on hooks and rods from spinal growth, as well as assist in finding and removing loosened implants. These factors can reduce incidence rates of implant-related complications.

The appropriate interval for the GR technique is a comprehensive problem which involves many factors, including orthopedic correction effects, surgical trauma, patient growth and development, and economic status [28]. According to the current investigation, it seems better to improve the deformity of scoliosis, promote the growth of the spine, and reduce incidence of complications from a purely clinical perspective. Present results suggest that patients should perform lengthening operations twice a year, if possible. Electromagnetic GR has developed rapidly with distinct advantages. No distraction surgeries are needed and it can be remotely controlled. However, the lengthening interval is still at the exploration stage. Current results and methods may provide important reference for this new technique. At the same time, the application experience of electromagnetic growth rods can give further insight into appropriate lengthening intervals. It is hoped that more advanced orthopedic technology can be developed through more research, bringing more benefits for children with scoliosis.

Growing rods in the treatment of early onset scoliosis

In conclusion, the current study showed that the GR technique can improve spinal deformities without disturbing the growth and development of the spine and thorax. Distractions every 6 months showed more advantages in preventing progression of scoliosis and promoting spinal growing and physical development, compared to distractions every 12 months. Distractions, at the appropriate time, can reduce incidence rates of implant-related complications, timely releasing pressure on hooks and rods from spinal growth.

Acknowledgements

This work was supported by grant from the National Natural Science Foundation of China (NSFC) (grant number: 81401847).

Disclosure of conflict of interest

None.

Address correspondence to: Shugang Li, Department of Orthopedic Surgery, Peking Union Medical College Hospital, No. 1 Shuai Fu Yuan, Wang Fu Jing Street, Beijing 100730, China. Tel: 86-10-6529-6092; Fax: 86-10-65296081; E-mail: lishugang-pumc@163.com

References

- [1] Li Z, Shen J, Wu WK, Wang X, Liang J, Qiu G and Liu J. Vitamin A deficiency induces congenital spinal deformities in rats. *PLoS One* 2012; 7: e46565.
- [2] Xue X, Shen J, Zhang J, Zhao H, Li S, Zhao Y, Liang J, Qiu G and Weng X. Rib deformities in congenital scoliosis. *Spine (Phila Pa 1976)* 2013; 38: E1656-1661.
- [3] Shen J, Wang Z, Liu J, Xue X and Qiu G. Abnormalities associated with congenital scoliosis: a retrospective study of 226 Chinese surgical cases. *Spine (Phila Pa 1976)* 2013; 38: 814-818.
- [4] Liang JQ, Qiu GX, Shen JX, Lee CI, Wang YP, Zhang JG and Zhao H. A retrospective study of echocardiographic cardiac function and structure in adolescents with congenital scoliosis. *Chin Med J (Engl)* 2009; 122: 906-910.
- [5] Burton MS. Diagnosis and treatment of adolescent idiopathic scoliosis. *Pediatr Ann* 2013; 42: 224-228.
- [6] Skov ST, Wijdicks SPJ, Bunge C, Castelein RM, Li HS and Krzyt MC. Treatment of early-onset scoliosis with a hybrid of a concave magnetic driver (magnetic controlled growth rod) and a contralateral passive sliding rod construct with apical control: preliminary report on 17 cases. *Spine J* 2018; 18: 122-129.
- [7] Thakar C, Kieser DC, Mardare M, Haleem S, Fairbank J and Nnadi C. Systematic review of the complications associated with magnetically controlled growing rods for the treatment of early onset scoliosis. *Eur Spine J* 2018; 27: 2062-2071.
- [8] Soliman HAG. Health-related quality of life and body image disturbance of adolescents with severe untreated idiopathic early-onset scoliosis in a developing country. *Spine (Phila Pa 1976)* 2018; 43: 1566-1571.
- [9] Helenius IJ, Oksanen HM, McClung A, Pawelek JB, Yazici M, Sponseller PD, Emans JB, Perez-Gruoso FJS, Thompson GH, Johnston C, Shah SA and Akbarnia BA. Outcomes of growing rod surgery for severe compared with moderate early-onset scoliosis: a matched comparative study. *Bone Joint J* 2018; 100-B: 772-779.
- [10] Doany ME, Olgun ZD, Kinikli GI, Bekmez S, Kocyigit A, Demirkiran G, Karaagaoglu AE and Yazici M. Health-related quality of life in early-onset scoliosis patients treated surgically EO-SQ scores in traditional growing rod versus magnetically controlled growing rods. *Spine (Phila Pa 1976)* 2018; 43: 148-153.
- [11] Wessell NM, Martus JE, Halanski MA, Snyder B and Truong W. What's new in pediatric spine growth modulation and implant technology for early-onset scoliosis? *J Pediatr Orthop* 2018; 38: e3-e13.
- [12] Alvarez AG, Dearn KD, Lawless BM, Lavecchia CE, Vommaro F, Martikos K, Gregg T and Shepherd DET. Design and mechanical evaluation of a novel dynamic growing rod to improve the surgical treatment of early onset scoliosis. *Materials & Design* 2018; 155: 334-345.
- [13] Pan AX, Hai Y, Yang JC, Zhang YP and Zhang YS. Upper instrumented vertebrae distal to T2 leads to a higher incidence of proximal junctional kyphosis during growing-rod treatment for early onset scoliosis. *Clin Spine Surg* 2018; 31: E337-E341.
- [14] Elsebai HB, Yazici M, Thompson GH, Emans JB, Skaggs DL, Crawford AH, Karlin LI, McCarthy RE, Poe-Kochert C, Kostial P and Akbarnia BA. Safety and efficacy of growing rod technique for pediatric congenital spinal deformities. *J Pediatr Orthop* 2011; 31: 1-5.
- [15] Heidt C, Kong E, Torode I and Balakumar J. Brace treatment of adolescent idiopathic scoliosis. A retrospective study and analysis according to the SRS criteria. *Orthopade* 2013; 42: 922-927.
- [16] Harrington PR. Treatment of scoliosis - correction and internal fixation by spine instrumentation. *J Bone Joint Surg Am* 2002; 84: 316-316.
- [17] Moe JH, Kharrat K, Winter RB and Cummine JL. Harrington instrumentation without fusion

Growing rods in the treatment of early onset scoliosis

- plus external orthotic support for the treatment of difficult curvature problems in young-children. *Clin Orthop Relat Res* 1984; 35-45.
- [18] Johnston CE, Tran DP and McClung A. Functional and radiographic outcomes following growth-sparing management of early-onset scoliosis. *J Bone Joint Surg Am* 2017; 99: 1036-1042.
- [19] Sewell MD, Platinum J, Askin GN, Labrom R, Hutton M, Chan D, Clarke A, Stokes OM, Molloy S, Tucker S and Lehovsky J. Do growing rods for idiopathic early onset scoliosis improve activity and participation for children? *J Pediatr* 2017; 182: 315-320.
- [20] Bekmez S, Dede O and Yazici M. Advances in growing rods treatment for early onset scoliosis. *Curr Opin Pediatr* 2017; 29: 87-93.
- [21] Hill G, Nagaraja S, Akbarnia BA, Pawelek J, Sponseller P, Sturm P, Emans J; Growing Spine Study Group, Bonangelino P, Cockrum J, Kane W, Dreher M. Retrieval and clinical analysis of distraction-based dual growing rod constructs for early-onset scoliosis. *Spine J* 2017; 17: 1506-1518.
- [22] Jain VV, Berry CA, Crawford AH, Emans JB, Sponseller PD; Growing Spine Study Group. Growing rods are an effective fusionless method of controlling early-onset scoliosis associated with neurofibromatosis type 1 (NF1): a multicenter retrospective case series. *J Pediatr Orthop* 2017; 37: e612-e618.
- [23] Kwan KYH, Alanay A, Yazici M, Demirkiran G, Helenius I, Nnadi C, Ferguson J, Akbarnia BA, Cheung JPY and Cheung KMC. Unplanned reoperations in magnetically controlled growing rod surgery for early onset scoliosis with a minimum of two-year follow-up. *Spine (Phila Pa 1976)* 2017; 42: E1410-E1414.
- [24] El-Hawary R, Sturm P, Cahill P, Samdani A, Vitale M, Gabos P, Bodin N, d'Amato C, Harris C, Al Khudairy A and Smith JT. What is the risk of developing proximal junctional kyphosis during growth friendly treatments for early-onset scoliosis? *J Pediatr Orthop* 2017; 37: 86-91.
- [25] Rustagi T, Kurra S, Sullivan K, Dhawan R and Lavelle WF. Surgical treatment of early-onset idiopathic scoliosis in the United States: a trend analysis of 15 years (1997-2012). *Spine J* 2019; 19: 314-320.
- [26] Bauer JM, Yorgova P, Neiss G, Rogers K, Sturm PF, Sponseller PD, Luhmann S, Pawelek JB, Shah SA; Growing Spine Study Group. Early onset scoliosis: is there an improvement in quality of life with conversion from traditional growing rods to magnetically controlled growing rods? *J Pediatr Orthop* 2019; 39: e284-e288.
- [27] Sankar WN, Acevedo DC and Skaggs DL. Comparison of complications among growing spinal implants. *Spine (Phila Pa 1976)* 2010; 35: 2091-2096.
- [28] Fedorak GT, Stasikelis PJ, Carpenter AM, Nielson AN and D'Astous JL. Optimization of casting in early-onset scoliosis. *J Pediatr Orthop* 2019; 39: E303-E307.