

Original Article

A CBCT study of buccal bone thickness versus horizontal bone alterations at implant neck following immediate implantation in the aesthetic zone, a retrospective study

Min Sheng^{1,2}, Denghui Zhang¹, Guoqiang Zhang³, Xiaochen Liu¹, Fuming He¹, Huiming Wang¹, Yi Zhou¹

¹Affiliated Hospital of Stomatology, Medical College, Zhejiang University, Hangzhou 310006, Zhejiang, People's Republic of China; ²Department of Stomatology, Yuecheng People's Hospital, Shaoxing 312000, Zhejiang, People's Republic of China; ³No.271, Qiushan Street, Linping Subdistrict, Yuhang District, Hangzhou 311100, Zhejiang, People's Republic of China

Received April 28, 2019; Accepted July 11, 2019; Epub September 15, 2019; Published September 30, 2019

Abstract: Objective: CBCT was used to investigate the effect of buccal bone thickness on horizontal bone loss at implant neck following immediate implantation in the aesthetic zone of the anterior maxilla and guided bone regeneration (GBR). Methods: Selecting CBCT data from patients who received immediate implant placement in the aesthetic zone with simultaneous GBR between April 2014 and January 2018. 72 patients (with a total of 90 dental implants) aged 18 to 65 years were selected as subjects. They received CBCT examination on the postoperative day, at 6th month and at least 12 months after implantation to measure horizontal buccal bone thicknesses at implant neck. The patients were divided into Groups 1 to 5 according to different thicknesses on the postoperative day (< 2 mm, 2-2.5 mm, 2.5-3 mm, 3-3.5 mm, and > 3.5 mm). Data were statistically analyzed using paired t test, One-way ANOVA and multiple comparisons of LSD. Results: Comparing the horizontal buccal bone loss rate at 6 months post-operatively, Group 1 ($10.32 \pm 29.18\%$) was significantly less than Groups 3 ($28.43 \pm 20.98\%$), 4 ($30.15 \pm 23.65\%$) and 5 ($36.15 \pm 18.06\%$) ($P = 0.021$, 0.014 and 0.002 , respectively). Greater than 12 months after implantation, Group 1 ($22.53 \pm 37.36\%$) was significantly less than Groups 3 ($40.89 \pm 20.57\%$), 4 ($42.50 \pm 25.73\%$) and 5 ($49.53 \pm 15.96\%$) ($P = 0.026$, 0.018 and 0.002 , respectively), while Group 2 ($27.45 \pm 18.81\%$) was also less than Group 5 ($P = 0.012$). Bone loss was more significant in the first six months after implantation than that in the latter six months ($P = 0.013$). Conclusion: After immediate implantation in the aesthetic zone with simultaneous GBR, there were horizontal bone loss at implant neck when the buccal bone thickness was above 3.5 mm.

Keywords: Cone beam computed tomography, aesthetics of the anterior maxilla, bone plate thickness, immediate implantation

Introduction

With the success and predictability of dental implants and the increasing demands and expectations of patients, combination of immediate implantation with immediate restoration has been an increasingly popular approach to further accelerate the treatment and shorten the whole therapeutic procedure over the past decade [1]. Despite of immediate implantation, high implant success rate, as well as aesthetics could be achieved in the mid-long term (2-5 years) [2] and long term (7 years) [3].

Missing pre-maxillary teeth usually results in buccal bone deficiencies because of inflammation, trauma, congenital factors, and physiologi-

cal bone resorption [4-6]. Some major aesthetic parameters of implantation and restoration in the anterior maxilla, e.g., the aspect, texture, morphology and color of the buccal soft tissue, are closely related to the volume of the sub-buccal hard tissue [5, 7]. Aesthetically, defective or thin buccal bone plates bear unfavorably on restorative effect and usually became the important cause of occurrence of aesthetic complications and implantation failure [8]. In contrast, some scholars proposed that bone loss decreased significantly and even the failure rate of implantation also decreased as the buccal bone thickness approached 1.8 to 2 mm [9]. However, a one-year randomized controlled trial indicated that with delayed provisionalization, immediate implant placement

showed no significant difference from delayed implant placement in labial bony defects more than 5 mm according to change in marginal bone level [10]. Most research has focused on the effect of preoperative buccal bone thickness on the aesthetics, while there hasn't been enough evidence on how postoperative buccal thickness influenced the clinical manifestation.

Therefore, in order to achieve bone augmentation, bone regeneration in bone defects is inevitable. Guided bone regeneration (GBR) has been proved to be an effective approach [11-14]. Rainer Lutz et al. analyzed placement of 274 implants in the anterior maxilla with simultaneous GBR in a systematic review of 37 articles, and showed that good bone augmentation was achieved in the context of adequate soft tissue healing and that bone augmentation achieved after two to seven years maintained good stability [15]. Jensen SS et al. made a systematic review of efficacy of augmentation with GBR based on 2,430 abstracts and full-text articles, and results showed that horizontal ridge augmentation was 2.9-4.4 mm (mean, 3.6 mm). In addition, after GBR was performed in patients with different defect types, e.g., fenestration-type defects, dehiscence-type defects and insufficient initial height of maxillary sinus, defect fill was accomplished in 57-97% of the cases and complete defect fill was accomplished in 68.5% of the cases, suggesting that GBR on restoring the defect was effective but of limited [14]. However, in clinical practice, when bone augmentation with GBR was performed in bone defects, limited referable literature is now available regarding how to control the grafted bone thickness to minimize the postoperative bone alteration.

In recent years, CBCT has been successfully used in stomatological fields [16]. It was well documented that CBCT could determine both qualitatively and quantitatively the bone mass of the buccal bone plate in the maxillary anterior region and its alterations before and after implantation [17]. It was pointed out in some literature that diagnostic accuracy of CBCT was excellent in detecting circumferential-intrabony and fenestration defects [18]. CBCT has become an essential auxiliary tool in the implantation field due to its low dosage, good imaging quality, easy operation, and feasibility of three-dimensional reconstruction and template making.

In this study, postoperative alterations were evaluated after immediate implantation in different buccal bone thicknesses by CBCT during follow-up, and obtain an appropriate postoperative buccal bone thickness to guide clinical bone grafting operation.

Materials and methods

Selection of subjects

CBCT data were selected from patients who received immediate implantation in the aesthetic zone (teeth#12, 11, 21, 22) with simultaneous GBR at the Department of Dental Implantation, Stomatology Hospital, Zhejiang University School of Medicine between April 2014 and January 2018. The dental implant system used was ITI System (Straumann Inc., Switzerland). The absorbable membrane used was Bio-Gide® (Geistlich Pharma AG, Switzerland). Bio-Oss® Collagen granules (Geistlich Pharma AG, Switzerland) were used as bone substitute.

The inclusion criteria were met if any subject: (1) Was in good periodontal condition and had good oral hygiene habits, without any systematic history contraindicated in oral implantology. (2) Had intact bone wall or a few bone defects after flap operation of the anterior maxilla (teeth#12, 11, 21, 22) and received immediate implantation with simultaneous GBR. (3) Received secondary operation to replace the healing cap at six months postoperatively. (4) Received single crown restoration of each upper implant and achieved retention by bonding between crown and implant abutment. (5) Did not have apparent peri-implant inflammatory response following implantation. (6) Received CBCT and obtained clear and artifact-free images in our hospital on the postoperative day (T1), at 6 (T2) and at least 12 months postoperatively (T3), respectively.

Exclusion criteria were: (1) Heavy smokers (> 10/day). (2) Uncontrolled, advanced or aggressive periodontal disease. (3) Uncontrolled diabetes, blood disease, heart disease, liver or kidney dysfunction or other medical history in which any surgical invention would be contraindicated. (4) Radiation therapy of the cervicocephalic region. (5) Previous implant installation. (6) Unable to achieve initial implant stability. (7) CBCT data is incomplete, unclear or there were artifacts in the image.

Bone alterations after immediate implantation

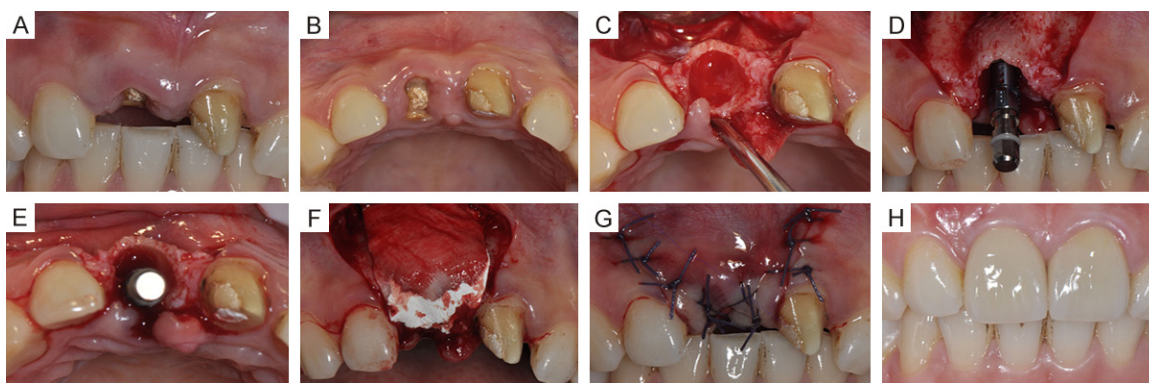


Figure 1. A typical case, female, 30 years old, suffered fracture of the maxillary right lateral incisor after biting a hard object. A and B: Preoperative buccal and occlusal views. C: The residual crown of Tooth 11 is extracted in a minimally invasive fashion. D and E: An implant is placed. F: Bio-Oss® Collagen granules and Bio-Gide® are administered and GBR is performed. G: A healing cap is placed, and the gingival flap is approximated and closed with close relaxation suture. H: An all-ceramic crown restoration is done.

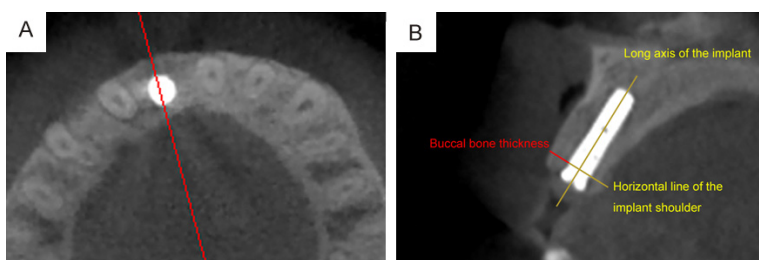


Figure 2. Instrumentation plan. A: Select a sagittal section passing through the center of the dental implant. B: Buccal bone thickness is bone measurement in a horizontal plane of the neck perpendicular to the long axis of the implant.

Surgical and restorative procedure

Implantation was completed in the operating room of dental implantation. The length and diameter of the implant were selected according to patient's specific condition. The flap was reflected and retracted under infiltration anesthesia with Primacaine™ (1:100,000 epinephrine). A vertical relaxing incision was made. After extracting the tooth and exposing the alveolar ridge, the surgeon performed sequential osteotomy and implant insertion according to the manufacturer's guidelines (Straumann® Bone Level Implant Line, Switzerland). The implant shoulders were placed approximately 1-2 mm below the alveolar ridge and 5 mm approximately below the gingival margin of the adjacent teeth according to the manufacturer's instructions. For rough implant surface and bone defects exposed, Bio-Gide® (Geistlich Pharma AG, Switzerland) was used for graft filling, and Bio-Oss® Collagen granules (Geistlich

Pharma AG, Switzerland) were covered on graft substitutes. Tension-free suture was performed with non-absorbable nylon sutures. Postoperatively, prophylactic antibiotics were used, and secondary operation was performed six months later. All patients receive NewTom 3G CBCT (QR, Italy) scan on the day of operation, on the day of secondary operation, and at least one year postoperatively. All scanning

parameters were automatically generated and random. Original data were imported into NNT Version 4.6 software for reconstruction. Sagittal plane across the medial axis of the implant was selected as required. In the same patient, a CBCT screenshot should be consistent with the position of the dental arch as far as possible. Contrast and magnification were adjusted to make images as clear as possible. Measuring software was iCAT Vision 1.9.3.13. All patients received single crown restoration of each upper implant and achieved retention by bonding between crown and implant abutment. Treatment of a typical case is shown in **Figure 1**.

Measurement

Patients were scanned by NewTom 3G CBCT (QR SLR, Italy). The original data scanned were imported into NNT Version 4.6 software. A series of cross-sectional views were obtained in secondary reconstruction mode. The slice

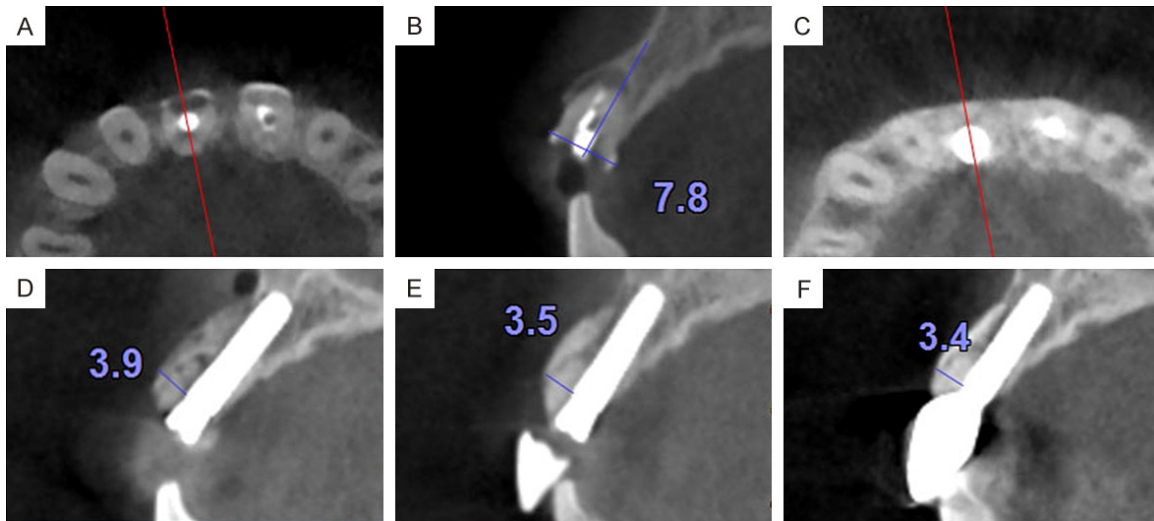


Figure 3. Measurement of the typical patient. A: A sagittal section passing through the center of the residual crown is selected preoperatively. B: Alveolar bone width of the neck of the preoperative residual crown. C: Sagittal section passing through the center of the implant is selected. D: The buccal bone thickness of the immediate postoperative implant neck. E: Buccal bone thickness of the implant neck at 6 months postoperatively. F: Buccal bone thickness of the implant neck at 12 months postoperatively.

Table 1. Dental implant positions and the male-female ratio (teeth)

Dental implant position	Maxillary right lateral incisor	Maxillary right central incisor	Maxillary left central incisor	Maxillary left lateral incisor
Male (38)	2	14	18	4
Female (52)	9	17	19	7
Total (90)	11	31	37	11

done by multiple comparisons of LSD. The level of significance for all tests was $P < 0.05$. Paired *t* test was employed to compare horizontal bone alteration of the first half of the year and the latter half of year.

Ethics committee

thickness of the cross section was set at 0.29 mm, the vertical slice width at 50 mm, and both axial width and slice increment at 0.29. A sagittal section passing through the center of the dental implant was selected. Bone measurement in a horizontal plane of the neck perpendicular to the long axis of the implant served as the buccal bone thickness of the implant (**Figure 2**). Buccal bone thicknesses on CBCT were measured on the postoperative day (T1), at 6 (T2) and at least 12 months postoperatively (T3), respectively. All data were measured by the same individual. Each measurement was done in duplicate. All measurements were averaged to obtain a final value. Measurement of the typical patient is shown in **Figure 3**.

Statistical analysis

SPSS22.0 software was used to test the homogeneity of variance. One-way ANOVA was carried out, and pairwise comparison was

The study was conducted in accordance with the Helsinki Declaration published in 2008. The study protocol was approved by the local Ethics Committee (the Ethics Committee of Stomatology Hospital, School of Medicine, Zhejiang University, Approval Number: 2018-003). Informed consent was obtained from all the patients.

Results

Patient and implant information

Seventy-two patients (30 males and 42 females) aged 18 to 65 (on average, 35.18 ± 12.44 years) were screened out, with a total of 90 dental implants. Dental implant position is shown in **Table 1**. Implants were distributed on lateral incisors (22 subjects) and central incisors (68 subjects) in the maxilla. All implants showed no significant complications during the evaluation period.

Bone alterations after immediate implantation

Table 2. Horizontal buccal bone loss at 6 (T2) and at least 12 months postoperatively (T3) ($x \pm s$, mm)

Group (case)	Buccal bone loss at 6 months postoperatively T1-T2	Buccal bone loss at least 12 months postoperatively T1-T3	Buccal bone loss between 6 and 12 months postoperatively T2-T3
1 (18)	0.19 \pm 0.49	0.40 \pm 0.58	0.21 \pm 0.59
2 (16)	0.53 \pm 0.57	0.61 \pm 0.44	0.09 \pm 0.41
3 (20)	0.78 \pm 0.57	1.11 \pm 0.56	0.34 \pm 0.62
4 (18)	0.97 \pm 0.78	1.36 \pm 0.83	0.39 \pm 0.61
5 (18)	1.44 \pm 0.75	2.00 \pm 0.73	0.56 \pm 0.79
Total (90)	0.79 \pm 0.75	1.11 \pm 0.84	0.32 \pm 0.63

NOTE: T1 represents the postoperative day, T2 represents 6 months postoperatively, and T3 represents at least 12 months postoperatively; according to the buccal bone thickness, < 2 mm, 2-2.5 mm, 2.5-3 mm, 3-3.5 mm, and > 3.5 mm represent Group 1 to 5, respectively.

Table 3. Horizontal buccal bone loss rate at 6 (T2) and at least 12 months postoperatively (T3) ($x \pm s$, %)

Group (case)	buccal bone loss rate at 6 months postoperatively (T1-T2)/T1	buccal bone loss rate at least 12 months postoperatively (T1-T3)/T1	buccal bone loss rate between 6 and 12 months postoperatively (T2-T3)/T1
1 (18)	10.32 \pm 29.18*	22.53 \pm 37.36*	12.21 \pm 43.01
2 (16)	23.94 \pm 25.69	27.45 \pm 18.81#	3.51 \pm 18.01
3 (20)	28.43 \pm 20.98	40.89 \pm 20.57	12.46 \pm 22.26
4 (18)	30.15 \pm 23.65	42.50 \pm 25.73	12.35 \pm 19.04
5 (18)	36.15 \pm 18.06	49.53 \pm 15.96	13.38 \pm 18.71
Total (90)	25.90 \pm 24.76	36.88 \pm 26.30	10.98 \pm 25.73

NOTE: *represents $P < 0.05$, this group vs Groups 3, 4 and 5; #represents $P < 0.05$, this group vs Group 5.

Immediate postoperative buccal bone thicknesses

To facilitate CBCT image recognition, measurement and clinical operation, immediate postoperative buccal bone thicknesses at implant shoulder level was divided into five groups (< 2 mm, 2-2.5 mm, 2.5-3 mm, 3-3.5 mm, and > 3.5 mm, with a 0.5 mm interval for each group). In these 5 groups, number of implants was 18, 16, 20, 18, and 18 respectively.

Horizontal bone alterations

Results of horizontal buccal bone loss of different groups is shown in **Table 2**. In this study of 90 dental implants at the implant shoulder level, horizontal buccal bone loss ranged from -1.05 mm to 3.1 mm six months postoperatively and from -0.65 mm to 3.5 mm at least 12 months postoperatively. Horizontal bone loss

following immediate implantation with simultaneous bone grafting was more significant in the first half of the year (0.79 ± 0.75 mm) than in the latter half of the year (0.32 ± 0.63 mm) ($P = 0.013$), which were both in normal distribution (T1-T2: $P = 0.20$, T2-T3: $P = 0.06$).

Levene's test

Levene tested buccal bone loss rate at 6 months postoperatively ($F = 0.850$, $P = 0.497$) and 12 months postoperatively ($F = 1.602$, $P = 0.181$), both of which met the homogeneity of variance.

One-way ANOVA analysis

Results of one-way ANOVA (**Table 2**) showed whether it was at six months or twelve months postoperatively, there was no significant difference among 5 groups in spite of different buccal bone thickness on the postoperative day. However, there was a significant intergroup difference in buccal bone loss rate at 6

months postoperatively ($F = 3.012$, $P = 0.022$) and that there was a significant intergroup difference in buccal bone loss rate at 12 months postoperatively ($F = 3.592$, $P = 0.009$).

Multiple comparisons of LSD

Further pairwise comparison was performed by multiple comparisons of LSD (**Table 3**). Regarding buccal bone loss rate at 6 months postoperatively, Group 1 (< 2 mm) differed significantly from Group 3 (2.5-3 mm) ($P = 0.021$), Group 4 (3-3.5 mm) ($P = 0.014$) and Group 5 (> 3.5 mm) ($P = 0.002$). Regarding buccal bone loss rate at least 12 months postoperatively, Group 1 (< 2 mm) differed significantly from Group 3 (2.5-3 mm) ($P = 0.026$), Group 4 (3-3.5 mm) ($P = 0.018$) and Group 5 (> 3.5 mm) ($P = 0.002$), and Group 2 (2-2.5 mm) differed significantly from Group 5 (> 3.5 mm) ($P = 0.012$).

There was no other statistical difference among groups.

Discussion

This study included 72 patients who required implant restoration of missing teeth in the anterior maxilla and a total of 90 dental implants. With the statistical analysis of the data at these three time points, buccal bone alterations were examined immediately postoperatively, as well as at 6 and at least 12 months postoperatively and thus clarified the effect of postoperative buccal bone thickness at implant shoulder level on horizontal bone change, providing some references for clinical practice. In order to further refine and clarify the data, immediate postoperative buccal bone thicknesses at implant shoulder level were divided into five groups (< 2 mm, 2-2.5 mm, 2.5-3 mm, 3-3.5 mm, and > 3.5 mm, with a 0.5 mm interval for each group), which facilitated CBCT image recognition, measurement, and clinical operation. Such grouping model has not been reported in available literature.

This research suggested that horizontal bone loss occurred at the buccal implant shoulder 6 (-1.05 mm~3.1 mm) and at least 12 months (-0.65 mm~3.5 mm) after implantation in the anterior maxilla with simultaneous GBR. A total of 15 cases presented no bone loss or even presented increasing buccal bone thickness in the first half year, while 7 cases were of the same result in the first year. Reduce of buccal bone thickness was partially related to physiological bone loss in extraction sockets, resulting in destruction of dimensional integrity of soft and hard tissues around the extraction sockets [19]. A meta-analysis indicated that the alveolar ridge width reduced from 4.56 mm to 2.6 mm significantly at least three months after tooth extraction in non-molar regions [20]. Similar measurements were also reported in a recent CBCT-based, randomized controlled, clinical study, which investigated 80 permanent dental prostheses after implant placement in the aesthetic zone and concluded that buccal bone thickness varied from 0.79 mm to 2.12 mm at 1 month and from 0.71 mm to 2.04 mm at 1 year [17]. It was also reported that marginal bone loss was -0.80 mm-1.31 mm on average at 1-year follow-up for low-risk patients with a single immediate implant in the aesthetic zone, which was similar to our findings [21].

In addition, resorption was partly contributed by bone substitute materials. An *in vitro* CBCT study by Mir-Mari et al. indicated that wound closure induced apparent displacement of the bone substitute resulting in a partial collapse of the collagen membrane, and that the volume of the buccal coronal portion of the implant (at the implant shoulder level) was especially the most unstable and the collapse tended to be the most evident [22]. There are three potential reasons for the collapse. First, it was attributable to the indirect pressure of the upper lip when patients spoke and chewed postoperatively. Second, it was attributable to the direct pressure of the soft tissue flap during wound closure. Third, it was attributable to the insufficient mechanical support performance of DBBM granules for periosteum.

This research also revealed that horizontal bone loss following implantation with simultaneous bone grafting was more apparent in the first half of the year than in the latter half of the year, suggesting that horizontal bone loss mainly occurred in the 6-month healing period postoperatively. Bone loss stabilized gradually after 6 months, which was benefit for the long-term stability of the implant. In our study, however, there were 34 implants (34/90) which exhibited no bone loss and even became thicker (new bone formed) during the latter half year. A recent clinical and radiographic study evaluated the hard tissue volume stability of 28 single maxillary incisors during the 6-month healing stage in the anterior maxilla and concluded that augmented bone ridge underwent volume reduction at different vertical levels of the implant [23], suggestive of bone stabilization, which was close to our findings.

This study showed that the buccal bone alteration rate was low when the postoperative buccal bone thickness was less than 2 mm. But it was reported that initial stability could not be guaranteed unless buccal bone thickness in the anterior maxilla was more than 2 mm [24-26]. In view of long-term outcome, the study included patients with a buccal bone thickness of less than 2 mm, primarily providing analysis and comparison of alterations in buccal bone thickness among groups. It was also reported that, allowing for the volume stability sufficient for bone augmentation region, compensation for the bone loss in healing procedure after GBR could be achieved by excessive augmenta-

tion of bone graft on a small scale in bone defects. However, “excessive augmentation on a small scale” had not been quantified [27]. As a result in this study it can be concluded that although there was no significant difference of horizontal buccal bone loss at the implant neck level and the immediate postoperative buccal bone thicknesses increase, bone loss rate increased remarkably when the immediate postoperative buccal bone thickness was above 3.5 mm. The possible reasons are as follows: (1) overweight bone substitute materials, led to collapse or displacement under the pressure of the buccal soft tissue flap or the upper lip, (2) excessive graft materials resulted in increased tension in suture, thereby increasing the probability of dehiscence, (3) excessively thick hard tissues turning out that bone substitute materials and collagen membranes on the very surface were too far from the periosteum available for blood supply, resulting in insufficient blood supply and thus resorption, and (4) fast absorption of collagen membranes. Therefore, these results indicate that excessive buccal bone thickness at implant neck following immediate implantation in the aesthetic zone could lead to higher rate of horizontal bone alterations, which should be considered clinically.

There are still some limitations. First, a referable immediate post-GBR thickness to reduce postoperative horizontal bone alteration relatively was obtained, but preoperative buccal bone thickness and absolute amount of bone grafts are unknown. It was shown that aesthetic outcome at two years postoperatively was not significantly related to the preoperative buccal bone thickness if there was a > 2 mm gap between the implant and the inner surface of the buccal bone plate and bone substitute materials were filled during implant placement [28]. Second, due to a short follow-up period, long-term outcome studies are still needed to increase the sample size and prolong the follow-up period.

Acknowledgements

This study was financially supported by Zhejiang Provincial Natural Science Foundation of China (LY19H140003, LQ14H140005).

Disclosure of conflict of interest

None.

Address correspondence to: Yi Zhou, Affiliated Hospital of Stomatology, Medical College, Zhejiang University, Hangzhou 310006, Zhejiang, People's Republic of China. Tel: 0571-87217419; E-mail: zyuthscsa@zju.edu.cn

References

- [1] Arora H and Ivanovski S. Clinical and aesthetic outcomes of immediately placed single-tooth implants with immediate vs. delayed restoration in the anterior maxilla: a retrospective cohort study. *Clin Oral Implants Res* 2018; 29: 346-352.
- [2] Daniel B, Vivianne C, Bornstein MM, Julia-Gabriela W, Marc F and Belser UC. Long-term stability of contour augmentation with early implant placement following single tooth extraction in the esthetic zone: a prospective, cross-sectional study in 41 patients with a 5- to 9-year follow-up. *J Periodontol* 2013; 84: 1517-27.
- [3] Benic GI, Mokti M, Chen CJ, Weber HP, Hammerle CH and Gallucci GO. Dimensions of buccal bone and mucosa at immediately placed implants after 7 years: a clinical and cone beam computed tomography study. *Clin Oral Implants Res* 2012; 23: 560-6.
- [4] Buser D, Martin W and Belser UC. Optimizing esthetics for implant restorations in the anterior maxilla: anatomic and surgical considerations. *Int J Oral Maxillofac Implants* 2004; 19 Suppl: 43-61.
- [5] Merheb J, Quirynen M and Teughels W. Critical buccal bone dimensions along implants. *Periodontol* 2000 2014; 66: 97-105.
- [6] Crespi R, Cappare P and Gherlone EF. Bone recontouring in fresh sockets with buccal bone loss: a cone beam computed tomography study. *Int J Oral Maxillofac Implants* 2014; 29: 863-8.
- [7] Misawa M, Lindhe J and Araújo MG. The alveolar process following single-tooth extraction: a study of maxillary incisor and premolar sites in man. *Clin Oral Implants Res* 2016; 27: 884-889.
- [8] Professor SJFDC and Research DoC. 21. Implant complications related to immediate implant placement into extraction sites. 2015.
- [9] Spray JR, Black CG, Morris HF and Ochi S. The influence of bone thickness on facial marginal bone response: stage 1 placement through stage 2 uncovering. *Ann Periodontol* 2000; 5: 119-128.
- [10] Slagter KW, Meijer HJ, Bakker NA, Vissink A and Raghoobar GM. Immediate single-tooth implant placement in bony defects in the esthetic zone: a 1-year randomized controlled trial. *J Periodontol* 2016; 87: 619-29.

- [11] Elgali I, Omar O, Dahlin C and Thomsen P. Guided bone regeneration: materials and biological mechanisms revisited. *Eur J Oral Sci* 2017; 125: 315-337.
- [12] Hur Y, Ogata Y, Kim DW, Pham CM, Yoon TH and Ogata H. Bone resorption during submerged healing after guided bone regeneration: a prospective case series. *Implant Dent* 2017; 26: 820-825.
- [13] Schlegel KA, Fichtner G, Schultze-Mosgau S, Wiltfang J. Histologic findings in sinus augmentation with autogenous bone chips versus a bovine bone substitute. *Int J Oral Maxillofac Implants* 2003; 18: 53-8.
- [14] Jensen SS and Terheyden H. Bone augmentation procedures in localized defects in the alveolar ridge: clinical results with different bone grafts and bone-substitute materials. *Int J Oral Maxillofac Implants* 2009; 24: 218-36.
- [15] Lutz R, Neukam FW, Simion M and Schmitt CM. Long-term outcomes of bone augmentation on soft and hard-tissue stability: a systematic review. *Clin Oral Implants Res* 2015; 26: 103-122.
- [16] Sennerby L, Andersson P, Pagliani L, Giani C, Moretti G, Molinari M and Motroni A. Evaluation of a novel cone beam computed tomography scanner for bone density examinations in preoperative 3d reconstructions and correlation with primary implant stability. *Clin Implant Dent Relat Res* 2015; 17: 844-853.
- [17] Slagter KW, Raghoobar GM, Bakker NA, Vissink A, Meijer HJ. Buccal bone thickness at dental implants in the aesthetic zone: a 1-year follow-up cone beam computed tomography study. *J Craniomaxillofac Surg* 2017; 45: 13-19.
- [18] Pelekos G, Acharya A, Tonetti MS and Bornstein MM. Diagnostic performance of cone beam computed tomography in assessing peri-implant bone loss: a systematic review. *Clin Oral Implants Res* 2018; 29: 443-464.
- [19] Araujo MG, Silva CO, Misawa M and Sukekava F. Alveolar socket healing: what can we learn? *Periodontol* 2000 2015; 68: 122-134.
- [20] Ten Heggeler JM, Slot DE, Van der Weijden GA. Effect of socket preservation therapies following tooth extraction in non-molar regions in humans: a systematic review. *Clin Oral Implants Res* 2011; 22: 779-88.
- [21] Cosyn J, Eghbali A, Hermans A, Vervaeke S, De BH and Cleymaet R. A 5-year prospective study on single immediate implants in the aesthetic zone. *J Clin Periodontol* 2016; 43: 702-9.
- [22] Mir-Mari J, Wui H, Jung RE, Hämmerle CH and Benic GI. Influence of blinded wound closure on the volume stability of different GBR materials: an in vitro cone-beam computed tomographic examination. *Clin Oral Implants Res* 2016; 27: 258-65.
- [23] Jiang X, Zhang Y, Di P and Lin Y. Hard tissue volume stability of guided bone regeneration during the healing stage in the anterior maxilla: a clinical and radiographic study. *Clin Implant Dent Relat Res* 2018; 20: 68-75.
- [24] Buser D, Chappuis V, Belser UC and Chen S. Implant placement post extraction in esthetic single tooth sites: when immediate, when early, when late? *Periodontol* 2000 2017; 73: 84-102.
- [25] Groenendijk E, Staas TA, Fej G, Bronkhorst E, Verhamme L, Maal T and Meijer GJ. Immediate implant placement: the fate of the buccal crest. A retrospective cone beam computed tomography study. *Int J Oral Maxillofac Surg* 2017; 46: 1600-1606.
- [26] Petrungaro PS. Options for the esthetic zone using the immediate restoration procedure: observational data of 15 years and 5000 implants. *Compend Contin Educ Dent* 2017; 38: 318-325.
- [27] Benic GI and Hammerle CH. Horizontal bone augmentation by means of guided bone regeneration. *Periodontol* 2000 2014; 66: 13-40.
- [28] Arora H and Ivanovski S. Correlation between pre-operative buccal bone thickness and soft tissue changes around immediately placed and restored implants in the maxillary anterior region: a 2-year prospective study. *Clin Oral Implants Res* 2017; 28: 1188-1194.