

## Original Article

# Peripheral sH2a in diagnosis and evaluation of fibrosis condition in liver cirrhosis

Xin Yang, Qiong Liu

Department of Infection, The First Affiliated Hospital of University of South China, Hengyang 421001, Hunan, China

Received July 2, 2019; Accepted October 9, 2019; Epub January 15, 2020; Published January 30, 2020

**Abstract:** Asialo-glycoprotein soluble form of H2a (sH2a) is a liver specific protein, and it is presents in abnormal levels in the peripheral blood of liver disease patients. This study investigated if peripheral sH2a levels can be used for diagnosis and disease evaluation of liver cirrhosis. Enzyme-linked Immune Sorbent Assay (ELISA) measured sH2a content in the peripheral blood from liver cirrhosis patients and control people, along with serum albumin (ALB), total bilirubin (TBIL), direct bilirubin (DBIL), alanine aminotransferase (ALT), and aspartate aminotransferase (AST). Peripheral sH2a content was compared between liver cirrhosis patients at stage 1~2 and stage 3~5. Fibrosis parameters including hyaluronic acid (HA), laminin (LN), type IV collagen (IV-C) and type III collagen (PC III) were measured. The correlation between sH2a and HA, LN, IV-C and PC III was analyzed by Spearman method. Receiver operating characteristic (ROC) calculated area under curve (AUC) to evaluate sH2a in liver cirrhosis diagnosis. Compared to the control group, liver cirrhosis patients had significantly elevated serum ALT, AST, TBIL and DBIL, plus lower ALB and sH2a levels. Stage 3~5 liver cirrhosis patients had remarkably higher serum HA, PC III, IV-C and LN than stage 1~2 patients, whilst sH2a content was decreased to 67.2% ( $P<0.05$ ). Significantly negative correlation existed between serum sH2a and HA, IV-C or LN ( $P<0.05$ ) but not with PC III in liver cirrhosis patients. AUC of peripheral sH2a in liver cirrhosis diagnosis was 0.816 (95% CI: 0.782~0.850), suggesting moderate diagnostic value. Liver cirrhosis patients had abnormally decreased serum sH2a, which was correlated with clinical stages. sH2a is correlated with fibrosis, and has moderate diagnostic values. sH2a may have clinical implication in auxiliary diagnosis and disease evaluation in liver cirrhosis.

**Keywords:** Liver cirrhosis, liver fibrosis, diagnosis, ROC, sH2a

## Introduction

Liver cirrhosis is a commonly occurring chronic digestive disease found in clinics. It is caused by repeated stimuli of virus (HBV or HCV) or ethanol to induce widely distributed hepatocyte denaturing or necrosis, which progresses into diffused liver fibrosis lesions, forming regenerative lesions and pseudo-lobule, eventually destructing normal hepatic lobular structure and further liver cirrhosis [1-3]. When liver fibrosis progresses into decomposition stage, multi-organ failure or dysfunction may occur [4-6]. Liver fibrosis is the pathological basis for multiple diseases including liver cirrhosis and liver cancer, and is a necessary step in these chronic liver diseases. Necessary measures are required to identify fibrotic changes, to remove factors causing liver fibrosis, and to correct further progression of fibrosis, and all of these

have critical implications for impeding liver disease progression and improving patient prognosis [7-10]. Therefore, dynamic monitoring and early diagnosis of liver fibrosis is of critical importance in clinics. Currently liver biopsy is still the gold standard for liver fibrosis diagnosis, but it is not widely applied due to major trauma for patients, and is not beneficial for early screening and diagnosis of fibrosis [11-13].

Human asialo-glycoprotein receptor (ASGPR) is a protein for clearing asialo-glycoprotein from plasma, and is specifically synthesized and expressed in hepatocytes. Asialo-glycoprotein soluble form of H2a (sH2a) is a soluble fragment of human ASGPR. Within the endoplasmic reticulum of hepatocytes, ASGPR is cleaved by 5 amino acids to be transformed into sH2a, which is subsequently released into the blood

circulation. Previous studies have shown abnormal changes of sH2a in the peripheral blood of liver disease patients [14, 15]. As sH2a has liver specificity, and can be detected within peripheral blood circulation, it may be used for auxiliary diagnosis of liver disease as a means of a non-invasive approach. This study compared peripheral sH2a levels in liver cirrhosis patients at different clinical stages, and analyzed the correlation with liver fibrosis related parameters of patients, in order to investigate the value of peripheral sH2a content in auxiliary diagnosis for liver cirrhosis.

### Materials and methods

#### *Clinical information*

A total of 38 male and 18 female liver cirrhosis patients (42.5±11.8 years) were recruited from The Second People's Hospital affiliated to Luzhou Medical College in Neijiang city after liver biopsy and biochemistry examination. Among those patients there were 36 HBV induced liver cirrhosis patients, 12 alcoholic liver cirrhosis patients, plus 8 lipid liver cirrhosis patients. Clinical staging showed 24 patients at stage 1~2, and 32 patients at stage 3~5. Patient selection or inclusion criteria were defined according to the American Association for the Study of Liver Diseases Practice Guidelines. Exclusion criteria: (1) Liver cirrhosis caused by other viral hepatitis, autoimmune disorder, drug abuse or inheritance factors; (2) Those complicated with HIV or EB infection; (3) Complicated with severe heart, lung, kidney diseases that cannot comply to liver biopsy; (4) Pregnant or lactating women. Another cohort of 40 healthy control people were recruited in parallel, including 26 males and 14 females (average age = 42.5±11.8 years). No significant difference existed in age or gender between the two groups.

This study was pre-approved by the ethical committee of The Second People's Hospital Affiliated to Luzhou Medical College in Neijiang City. All subjects have signed the consent forms before recruitment in this study.

#### *Blood biochemistry examination*

Fasted venous blood samples were collected in the morning from all research subjects. Blood samples were incubated at room temperature for 2 h until blood clotting. Samples were centrifuged at 400 g for 10 min. The upper plasma

phase was saved. AU800 fully automatic biochemical analyzer (Olympus) was used to determine serum albumin (ALB), total bilirubin (TBIL), direct bilirubin (DBIL), aspartate aminotransferase (AST) and alanine aminotransferase (ALT).

#### *Liver fibrosis parameters and sH2a assay*

Radioimmune analyzing kit for determining hyaluronic acid (HA), type III pro-collagen (PC III), laminin (LN) and type IV collagen (IV-C) was purchased from Haiyan Biotech Institute (China). MAGLUMI 2000 Plus fully automatic chemiluminescence immunoassay apparatus was used to determine serum HA, PC III, LN and IV-C contents.

Human sH2a quantifying assay kit was provided by Weizhen Biomed (China). Following the manual instruction of the test kit, enzyme linked immunosorbent assay (ELISA) was used to determine serum sH2a concentrations.

#### *Statistical analysis*

All data were processed by SPSS 18.0 software. Measurement data were presented as mean ± standard deviation (SD). Student t-test was used to compare means between two groups. Spearman rank correlation analysis was used between parameters. Receiver operating characteristic (ROC) curve was used to analyze the value of sH2a in differential diagnosis of liver cirrhosis. A statistical significance was defined when  $P < 0.05$ .

### Results

#### *Significantly decreased sH2a contents in peripheral blood of liver cirrhosis patients*

Lab assay for liver functions showed that, compared to healthy control people, liver cirrhosis patients showed significantly elevated serum ALT, AST, TBIL and DBIL contents, whilst ALB level was remarkably decreased ( $P < 0.05$  in all cases, **Table 1**). ELISA results showed significantly decreased sH2a contents in peripheral blood samples from liver cirrhosis patients by 52.8% compared to healthy individuals ( $P < 0.05$ , **Table 1**).

#### *Correlation between liver fibrosis index, sH2a and disease stage in liver cirrhosis patients*

Test results showed significantly higher serum liver fibrosis indexes including HA, PC III, IV-C

## sH2a in liver cirrhosis

**Table 1.** Peripheral sH2a, liver function and biochemical indexes between two groups

	Control	Liver cirrhosis
sH2a (ng/mL)	126.3±38.7	59.6±21.4*
ALT (U/L)	31.4±4.5	142.6±26.8*
AST (U/L)	29.8±3.7	121.9±35.6*
TBIL (μmol/L)	13.2±2.8	52.6±8.1*
DBIL (μmol/L)	4.1±0.7	26.3±2.9*
ALB (g/L)	49.3±11.5	30.6±5.8*

\*P<0.05 compared to control group.

**Table 2.** Fibrosis indexes and sH2a results in liver cirrhosis patients at different stages

	Stage 1~2	Stage 3~5
sH2a (ng/mL)	68.9±22.3	46.3±18.9*
HA (ng/mL)	271.3±44.3	386.5±56.9*
PC III (ng/mL)	18.5±3.1	26.7±4.5*
IV-C (ng/mL)	19.2±4.6	25.1±5.3*
LN (ng/mL)	144.6±39.4	203.9±52.2*

\*P<0.05 comparing to stage 1~2 patients.

**Table 3.** Correlation between peripheral sH2a and liver fibrosis indexes in liver cirrhosis patients

Index	sH2a	
	r	P
HA	-0.584	0.039
PC III	-0.142	0.192
IV-C	-0.692	0.013
LN	-0.631	0.021

and LN in stage 3~5 liver cirrhosis patients compared to those in stage 1~2 patients (P<0.05, **Table 2**). ELISA results showed that, compared to stage 1~2 liver cirrhosis patients, stage 3~5 patients presented significantly lower peripheral sH2a contents, with about 67.2% (P<0.05, **Table 2**).

*Peripheral sH2a in liver cirrhosis patients was correlated with liver fibrosis index*

Spearman rank correlation analysis showed a significantly negative relationship between serum sH2a in liver cirrhosis patients and liver fibrosis indexes including HA, IV-C and LN (P<0.05), whilst no significant correlation was found between sH2a and PC III (P>0.05, **Table 3** and **Figure 1**).

*Relatively higher diagnostic value of peripheral sH2a on liver cirrhosis*

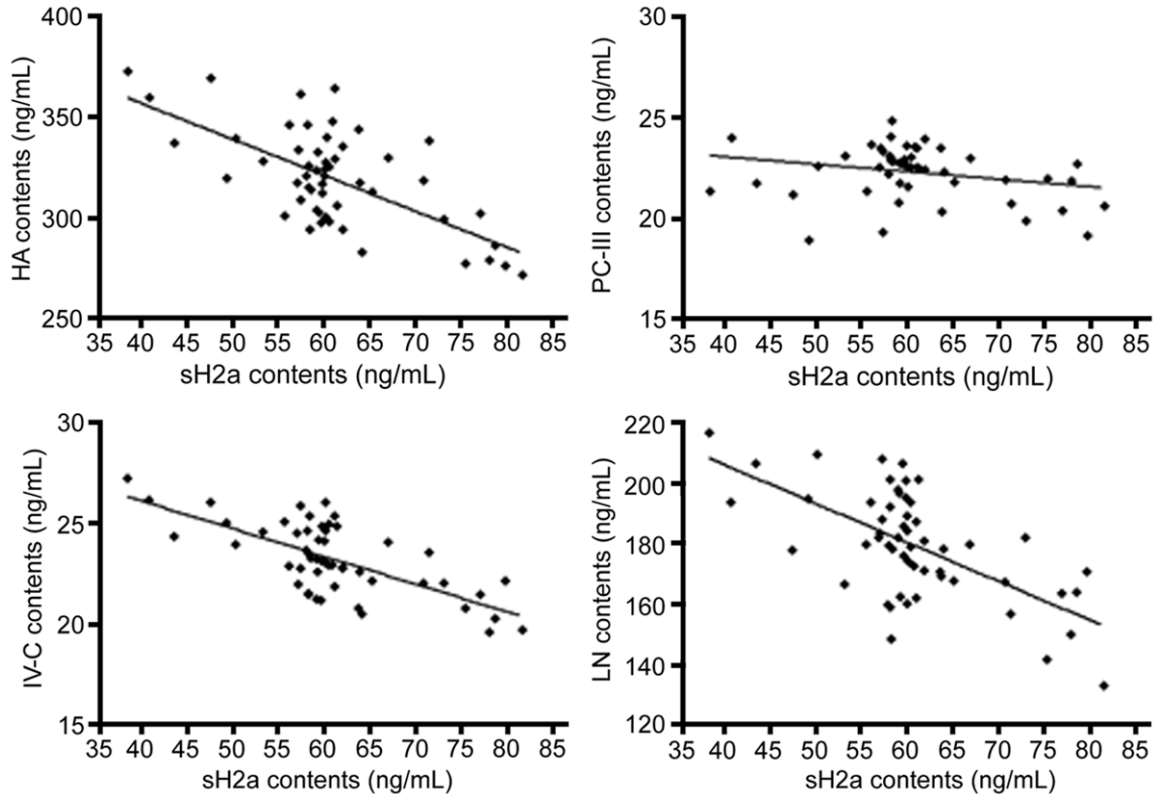
ROC curve was plotted for serum sH2a on liver cirrhosis patients and healthy control individuals to evaluate the diagnostic value of serum sH2a in differential diagnosis between healthy control and liver cirrhosis patients. Results showed that AUC of peripheral serum sH2a on liver cirrhosis was 0.816 (95% confidence interval: 0.782~0.850), with moderate diagnostic value (**Figure 2**).

### Discussion

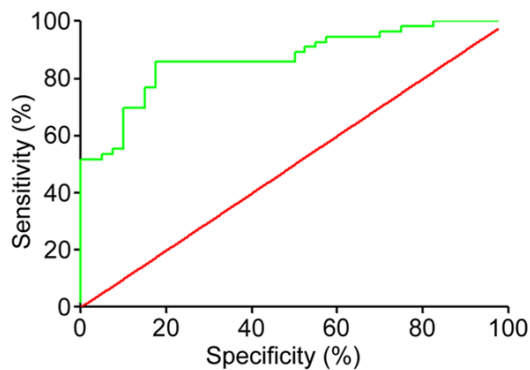
Liver cirrhosis mainly presents as liver dysfunction and portal artery hypertension, accompanied with multi-organ failure [16, 17]. When liver cirrhosis progresses into certain stages that go beyond the compensatory potency of hepatocytes, clinical presentation of a decompensation period also occurs including fatigue, mental depression, dry skin, face darkening, digestive tract hemorrhage, hypoproteinemia, ascites, blood clotting dysfunction, hepatic encephalopathy, and secondary infection; which severely affects patient health and life quality, and causes major economic burden for both family and society [18-20]. Liver fibrosis is a disease condition caused by imbalanced synthesis and degradation of the extracellular matrix (ECM) of liver tissues, and is featured as over-proliferation of hepatic mesenchymal tissues. Various factors including viral infection, alcohol abuse, autoimmune disorders and over-deposition of liver fatty acids may all contributed to liver fibrosis [21-23]. The onset and progression of liver fibrosis is a chronic process. If the damaged factor cannot be removed, persistent liver fibrosis may develop into liver cirrhosis, which is still reversible at an early stage. Therefore, early diagnosis of liver fibrosis and dynamic monitoring are of critical importance [24, 25].

Currently, various diagnostic approaches including tissue pathology, serum assays and imaging examinations are used for diagnosis of liver fibrosis. However, due to major trauma, deviation of sampling, lower reproductivity, complicated manipulation and expensive costs, their applications are largely limited. Hepatic ultrasound is one approach for qualitative diagnosis but with lower precision and sensitivity for early liver fibrosis during cirrhosis onset [26-

## sH2a in liver cirrhosis



**Figure 1.** Correlation between serum sH2a and liver fibrosis indexes HA, IV-C, LN and PC III.



**Figure 2.** Diagnostic value of sH2a on liver cirrhosis by ROC analysis.

28]. Liver fibrosis parameters are a group of serum proteins to evaluate condition of liver fibrosis. All these serum proteins belong to ECM proteins or their degrading products, not liver-specific expression or secretory factors, whose expression levels can be deviated by extra-hepatic inflammation, causing lower specificity and sensitivity.

ASGFR is a functional protein responsible for clearing asialo-glycoprotein from plasma, with

liver specificity. In developing liver tissues, ASGPR level is significantly lower than that in fully developed livers. ASGPR is composed of two related amino acid subunits, H1 (46 kD) and H2 (50 kD). H2a and H2b are two variable splicing isoforms of ASGPR H2 subunits, and are different only in the extra five amino acids within the extracellular domain adjacent to the transmembrane fragments. H2a can be rapidly cleaved into a 35 kD fragment at the site near those pentapeptides, including complete extracellular domain. Due to its secretory property, H2a can form a soluble form of receptor, or sH2a [14, 15]. Membrane binding H2a is unlike that of H2b, and it does not participate in H1 receptor complex assembly. H2a is thus not a receptor subunit, but the precursor of a soluble secretory form, and does not participate in the assembly of the ASGPR H2 subunit.

This study compared peripheral sH2a content between liver cirrhosis patients and healthy people, and found significantly lower sH2a content in liver cirrhosis patients by 52.8%, and those patients with advanced clinical stage showed significantly lower peripheral sH2a con-

tent than those with early stages. These results suggested that liver cirrhosis patients presented lower sH2a content, which was further suppressed with disease progression. All these variations may be caused by damaged hepatocyte function, and suppressed synthesis and secretion of sH2a. Benyair et al found that compared to healthy control population, liver cirrhosis patients had lower serum sH2a contents [14], as similar with our results. As serum liver fibrosis parameters are widely applied noninvasive indexes evaluating liver fibrosis, this study further investigated the correlation between serum sH2a and liver fibrosis parameters including HA, IV-C, LN, and PC III. Spearman rank correlation test showed maximally negative correlation between serum sH2a and IV-C in liver cirrhosis between serum sH2a and IV-C in liver cirrhosis patients ( $r = -0.584$ ), lower correlation with LN ( $r = -0.631$ ), and minimal correlation with HA ( $r = -0.584$ ), but not significant correlation with PC III. As a novel sH2 signaling protein family member, sH2a has not been fully investigated, with unclear function or clear boundary between normal and dysregulated concentrations. Routine Kappa consistent test cannot be used to reveal the consistency between diagnostic value of sH2a on liver cirrhosis and the gold standard of liver biopsy. Therefore, this study plotted ROC curves of serum sH2a between liver cirrhosis patients and healthy controlled individuals, in order to evaluate the diagnostic value of serum sH2a in differential diagnosis between liver cirrhosis and healthy people. Our results showed that AUC of peripheral serum sH2a for the diagnosis of liver cirrhosis was 0.816, indicating moderate diagnostic values.

This study recruited a limited sample number, and lacked large-sample study. Future study can be performed to enlarge the sample size, for further investigation of the relationship between sH2a and liver cirrhosis or fibrosis. It is still unclear if sH2a is under the influence of factors including virus, alcohol, or fatty acid liver. In the future, a large-sample patient cohort should be grouped based on disease condition for illustrating the correlation between sH2a quantity and those factors, thus rescuing the weakness of the current study. In summary, sH2a has satisfactory correlation with liver fibrosis condition, and moderately diagnostic value for liver cirrhosis. Due to con-

venient practice, sH2a may have clinical implications for auxiliary diagnosis and evaluation of liver fibrosis.

### Conclusion

Liver cirrhosis patients had significantly decreased serum sH2a contents, which are correlated with clinical stages. sH2a has good correlation with liver fibrosis condition, and has moderate diagnostic value for liver cirrhosis. Due to the convenient operation, serum sH2a may have clinical implications in auxiliary diagnosis for liver cirrhosis and evaluation of liver fibrosis.

### Acknowledgements

This work was supported by the Hunan Provincial Health and Health Commission 2019 Research Project (No. C20191118).

### Disclosure of conflict of interest

None.

**Address correspondence to:** Dr. Qiong Liu, Department of Infection, The First Affiliated Hospital of University of South China, No. 69, Chuanshan Road, Shigu District, Hengyang 421001, Hunan, China. Tel: +86-0734-8578751; Fax: +86-0734-8578751; E-mail: qiaolumejiangs@163.com

### References

- [1] Fujiyama S, Saitoh S, Kawamura Y, Sezaki H, Hosaka T, Akuta N, Kobayashi M, Suzuki Y, Suzuki F, Arase Y, Ikeda K and Kumada H. Portal vein thrombosis in liver cirrhosis: incidence, management, and outcome. *BMC Gastroenterol* 2017; 17: 112.
- [2] Jiménez-Romero C, Justo-Alonso I, Cambra-Molero F, Calvo-Pulido J, García-Sesma Á, Abradelo-Usera M, Caso-Maestro O and Manrique-Municio A. Incidence, risk factors and outcome of de novo tumors in liver transplant recipients focusing on alcoholic cirrhosis. *World J Hepatol* 2015; 7: 942-53.
- [3] Roedl K, Wallmuller C, Drolz A, Horvatits T, Rutter K, Spiel A, Ortbauer J, Stratil P, Hubner P, Weiser C, Motaabbed JK, Jarczack D, Herkner H, Sterz F and Fuhrmann V. Outcome of in- and out-of-hospital cardiac arrest survivors with liver cirrhosis. *Ann Intensive Care* 2017; 7: 103.
- [4] Kavli M, Strom T, Carlsson M, Dahler-Eriksen B and Toft P. The outcome of critical illness in de-



## sH2a in liver cirrhosis

- compensated alcoholic liver cirrhosis. *Acta Anaesthesiol Scand* 2012; 56: 987-94.
- [5] Kaido T and Uemoto S. Current status and issues of liver transplantation for decompensated liver cirrhosis. *Nihon Shokakibyō Gakkai Zasshi* 2017; 114: 35-42.
- [6] Kozaki K, Ilnuma M, Takagi T, Fukuda T, Sanpei T, Terunuma Y, Yatabe Y and Akano K. Cell-free and concentrated ascites reinfusion therapy for decompensated liver cirrhosis. *Ther Apher Dial* 2016; 20: 376-82.
- [7] Yasaka K, Akai H, Kunimatsu A, Abe O and Kiryu S. Liver fibrosis: deep convolutional neural network for staging by using gadoxetic acid-enhanced hepatobiliary phase MR images. *Radiology* 2018; 287: 146-155.
- [8] Pencheva B, Mihajlov R, Ruseva A, Mitova R, Petrov K, Taneva G and Genov J. Reference values of certain serum indicators of liver fibrosis. *Clin Lab* 2017; 63: 1793-1800.
- [9] Aberg F. Liver fibrosis scores in the general population: better risk indices are needed! *Hepatology* 2018; 67: 1186.
- [10] Wang Y, Liang X, Yang J, Wang H, Tan D, Chen S, Cheng J, Chen Y, Sun J, Rong F, Yang W, Liu H, Liu Z, Zheng Y, Liang J, Li S, Liu Z and Hou J. Improved performance of quantitative collagen parameters versus standard histology in longitudinal assessment of non-advanced liver fibrosis for chronic hepatitis B. *J Viral Hepat* 2018; 25: 598-607.
- [11] Morisaka H, Motosugi U, Ichikawa S, Nakazawa T, Kondo T, Funayama S, Matsuda M, Ichikawa T and Onishi H. Magnetic resonance elastography is as accurate as liver biopsy for liver fibrosis staging. *J Magn Reson Imaging* 2018; 47: 1268-1275.
- [12] Haugk B, Bury Y, Coats L, O'Sullivan J and Hudson M. Defining the role of liver biopsy in the assessment of liver fibrosis in patients with fontan circulation. *Hum Pathol* 2017; 69: 140.
- [13] Amarapurkar D and Amarapurkar A. Indications of liver biopsy in the era of noninvasive assessment of liver fibrosis. *J Clin Exp Hepatol* 2015; 5: 314-9.
- [14] Benyair R, Kondratyev M, Veselkin E, Tolchinsky S, Shenkman M, Lurie Y and Lederkremer GZ. Constant serum levels of secreted asialoglycoprotein receptor sH2a and decrease with cirrhosis. *World J Gastroenterol* 2011; 17: 5305-9.
- [15] Veselkin E, Kondratyev M, Lurie Y, Ron E, Santo M, Reif S, Elashvili I, Bar L and Lederkremer GZ. A secreted form of the asialoglycoprotein receptor, sH2a, as a novel potential noninvasive marker for liver fibrosis. *PLoS One* 2011; 6: e27210.
- [16] Zaidi SNF and Mahboob T. Prevention of liver cirrhosis by silymarin. *Pak J Pharm Sci* 2017; 30: 1203-1211.
- [17] Davies T, Wythe S, O'Beirne J, Martin D and Gilbert-Kawai E. Review article: the role of the microcirculation in liver cirrhosis. *Aliment Pharmacol Ther* 2017; 46: 825-835.
- [18] van den Berg EH, Douwes RM, de Meijer VE, Schreuder TCMA and Blokzijl H. Liver transplantation for NASH cirrhosis is not performed at the expense of major post-operative morbidity. *Dig Liver Dis* 2018; 50: 68-75.
- [19] Xiang Y, Song F, Yang XH, Qin KH, Zhang ST and Wei YL. Evaluation of the significance of hepatic functional reserve for the operation of liver cancer complicated with cirrhosis. *J BUON* 2017; 22: 932-935.
- [20] Soriano V, Benitez L, Arias A, Barreiro P and de Mendoza C. Need to face liver cirrhosis after HCV cure with antivirals. *EBioMedicine* 2017; 24: 24-25.
- [21] Ikeda H, Kobayashi M, Kumada H, Enooku K, Koike K, Kurano M, Sato M, Nojiri T, Kobayashi T, Ohkawa R, Shimamoto S, Igarashi K, Aoki J and Yatomi Y. Performance of autotaxin as a serum marker for liver fibrosis. *Ann Clin Biochem* 2018; 55: 469-477.
- [22] Poilil Surendran S, George Thomas R, Moon MJ and Jeong YY. Nanoparticles for the treatment of liver fibrosis. *Int J Nanomedicine* 2017; 12: 6997-7006.
- [23] Boursier J, de Ledinghen V, Leroy V and Cales P. Screening of advanced liver fibrosis: one step at a time. *J Hepatol* 2017.
- [24] Staufer K, Dengler M, Huber H, Marculescu R, Stauber R, Lackner C, Dienes HP, Kivaranovic D, Schachner C, Zeitlinger M, Wulkersdorfer B, Rauch P, Prager G, Trauner M and Mikulits W. The non-invasive serum biomarker soluble axl accurately detects advanced liver fibrosis and cirrhosis. *Cell Death Dis* 2017; 8: e3135.
- [25] Yada N, Tamaki N, Koizumi Y, Hirooka M, Nakashima O, Hiasa Y, Izumi N and Kudo M. Diagnosis of fibrosis and activity by a combined use of strain and shear wave imaging in patients with liver disease. *Dig Dis* 2017; 35: 515-520.
- [26] Qiu T, Wang H, Song J, Ling W, Shi Y, Guo G and Luo Y. Assessment of liver fibrosis by ultrasound elastography and contrast-enhanced ultrasound: a randomized prospective animal study. *Exp Anim* 2018; 67: 117-126.
- [27] Huang C, Zhang H and Bai R. Advances in ultrasound-targeted microbubble-mediated gene therapy for liver fibrosis. *Acta Pharm Sin B* 2017; 7: 447-452.
- [28] Liu J, Zhao J, Zhang Y, Ji Y, Lin S, Dun G and Guo S. Noninvasive assessment of liver fibrosis stage using ultrasound-based shear wave velocity measurements and serum algorithms in patients with viral hepatitis b: a retrospective cohort study. *J Ultrasound Med* 2017; 36: 285-293.