Int J Clin Exp Med 2020;13(11):8774-8781
www.ijcem.com /ISSN:1940-5901/IJCEM0112373

Original Article

Diffusion tensor imaging reveals delayed neurodevelopment in preterm neonates with respiratory distress syndrome: a retrospective study

Peiying Zhu[1], Xin Zhao[1], Qingna Xing[1], Chengcheng Wang[1], Desheng Xuan[1], Honglei Shang[1], Xiaoan Zhang[1,2]

[1]*Department of Radiology, The Third Affiliated Hospital of Zhengzhou University, Zhengzhou, China;* [2]*Institute of Neuroscience, Zhengzhou University, Zhengzhou, China*

Received April 11, 2020; Accepted September 1, 2020; Epub November 15, 2020; Published November 30, 2020

Abstract: Neurodevelopment progresses rapidly in the neonatal period and may be influenced by the presence of neonatal respiratory distress syndrome (NRDS). We retrospectively analyzed cranial diffusion tensor imaging (DTI) data collected from a cohort of preterm neonates with NRDS that included 35 cases and controls (group N = 11). The preterm neonates with NRDS were divided into the nasal continuous positive airway pressure (nCPAP) group (group C = 24) and the mechanical ventilation (MV) group (group M = 11), according to the auxiliary ventilation treatment mode. Microstructural integrity was investigated using fractional anisotropy (FA) in 10 brain regions, with corrections for postmenstrual age. The FAs of the caudate nuclei in groups M and C were lower than the corresponding FAs in group N, and the FAs of the occipital lobes in group M were lower than they were in group N. In addition, the FAs of the caudate nuclei in group C negatively correlated with the nCPAP treatment durations. Collectively, preterm neonates with NRDS exhibit lower FAs than those without NRDS.

Keywords: Neonatal respiratory distress syndrome (NRDS), diffusion tensor imaging (DTI), nasal continuous positive airway pressure (nCPAP), mechanical ventilation (MV)

Introduction

Neonatal respiratory distress syndrome (NRDS) has high morbidity in the neonatal period, and sequelae of different severities present in some children who survive [1, 2]. Current research supports the theory neonatal diseases have a significant effect on the neurodevelopment of preterm neonates. The neurodevelopmental status of some neonates with complicated diseases is normal in the early stage but shows abnormal manifestations during follow-up. Following the elimination of the influence of body weight and gestational age, it has been found that the neurodevelopment of newborns correlates with the type and severity of the disease [3]. In recent decades, it has been found that neonatal diseases may also affect cognitive, attention, and social skills, in addition to increasing the risk of neurodevelopmental disorders such as cerebral palsy, blindness, and deafness [4]. As evidenced by prior research, there is an increased risk of neurodevelopmental disorders in preterm neonates with NRDS [5]. Furthermore, there was found to be an increased risk of epilepsy in children born prematurely, at 32-36 weeks of gestation, with a medical history of NRDS but no intraventricular hemorrhage [6].

Diffusion tensor imaging (DTI) is a further development of diffusion-weighted imaging (DWI) technology that reveals the micro-structure of nerve fibers. Changes in DTI parameters correlate with the axon integrity and myelin sheath maturity [7]. In a DTI study, chronic lung disease (CLD) of preterm neonates was suggested to be related to the decrease of fractional anisotropy (FA) in brain tissue, while the FA trend was linearly related to the time required for auxiliary ventilation treatment [8]. In addition, children with chronic lung disease commonly have a history of NRDS [9], but few studies have investigated neurodevelopment in neonates with NRDS using DTI. Accordingly, in this study, DTI was used to study the neurode-

velopment of neonates in the early stages of NRDS.

Methods

Participants

Thirty-five preterm neonates diagnosed with NRDS in the neonatal intensive care unit and neonate ward of our hospital from December 2018 to April 2019 were selected for this study. Of the 35 enrolled children, the mean gestational age was 30.84 ± 1.22 weeks, the mean weight was 1.41 ± 0.31 kg, and MRIs were performed at a mean corrected gestational age of 35.94 ± 1.84 weeks. Inclusion criteria: infants diagnosed as a preterm neonate with NRDS in whom respiratory distress occurred within 24 hours after birth; infants with a complete, continuous, and rapid response to surfactants or pulmonary supplements or both; and infants accompanied by imaging findings [10, 11]; Exclusion criteria: infants with genetic and metabolic diseases, central nervous system infections, congenital malformations, chromosome abnormalities, etc.; infants diagnosed with hypoglycemic encephalopathy, bilirubin encephalopathy (and severe hyperbilirubinemia), cerebral hemorrhage, intraventricular hemorrhage, periventricular leukomalacia, etc.; infants who did not meet the inclusion criteria, and infants transferred to another hospital or whose treatment was terminated during the treatment period. The 35 preterm neonates with NRDS were further divided into two groups: the nasal continuous positive airway pressure (nCPAP) group (C group, 24 cases) and the endotracheal intubation mechanical ventilation group (M group, 11 cases). The groups were determined based on the auxiliary ventilation treatment each patient received while in the hospital. The infants in group C were treated with nCPAP immediately after admission, with successful ventilator weaning at one time [10, 12].

In the control group, there were 11 preterm neonates (group N, 11 cases) without NRDS. The average gestational age was 36.00 ± 0.56 weeks, the average weight was 1.38 ± 0.31 kg, and MRI was performed at an average corrected gestational age of 36.62 ± 1.96 weeks. In group N, the inclusion criteria were preterm neonates with an upper limit of the normal width of the lateral ventricle, septum pellucidum, or posterior cranial fossa indicated by prenatal ultrasound, but without MRI plain scans abnormalities after birth. Meanwhile, the exclusion criteria were preterm neonates with NRDS, genetic metabolic disease, central nervous system infection, congenital malformation, chromosomal abnormality, combined hypoglycemia encephalopathy, bilirubin encephalopathy (and severe hyperbilirubinemia), cerebral hemorrhage, intraventricular hemorrhage, periventricular leukomalacia, etc.

The study was conducted according to the recommendations of the Declaration of Helsinki and was approved by the ethics committee of the hospital. We explained the advantages of MRI and the disadvantages of sedatives to the parents of enrolled infants, to ensure they had a full understanding of the procedures used in our study. All infants' guardians were required to provide written informed consent.

MRI examination

All the patients were anesthetized with 5% chloral hydrate enema (0.5 mL/kg body weight) 30 minutes before the MRI examination. A cotton ball was inserted into the external auditory canal to protect hearing, and a sound-insulation sponge was placed on the bilateral sides of the head, for fixing. All the infants underwent conventional cranial MRI and DTI sequences. We performed MRI using a Siemens SKYRA 3.0T superconductivity magnetic resonance scanner and a 20-channel head coil. The conventional MRI contained T1-weighted, T2-weighted, and DWI images. DTI scan sequences included sagittal T1WI-MPRAGE (TR: 2000 ms, TE: 2.32 ms, slice thickness: 0.9 mm, slices: 192, field of view: 240 mm × 240 mm, number of excitation: 1, duration 4 min 40 s); and Ep2d-diff-mddw (TR: 3700 ms, TE: 92.0 ms, slice thickness: 4.0 mm, slices: 25, field of view: 200 mm × 200 mm, number of excitation: 1, duration 4 min 39 s, b value = 0 and 1000 s/mm^2). After scanning, the relevant image data were automatically imported into Siemens syngo via a post-processing workstation station, to generate the fractional anisotropy diagram (**Figure 1**) and other images. The region of interest (ROI) was selected on the FA diagram, which was controlled at (15 ± 3) mm^2 and placed in the center of the measured anatomical structure. The FA value of each ROI was measured three times, to determine the average value.

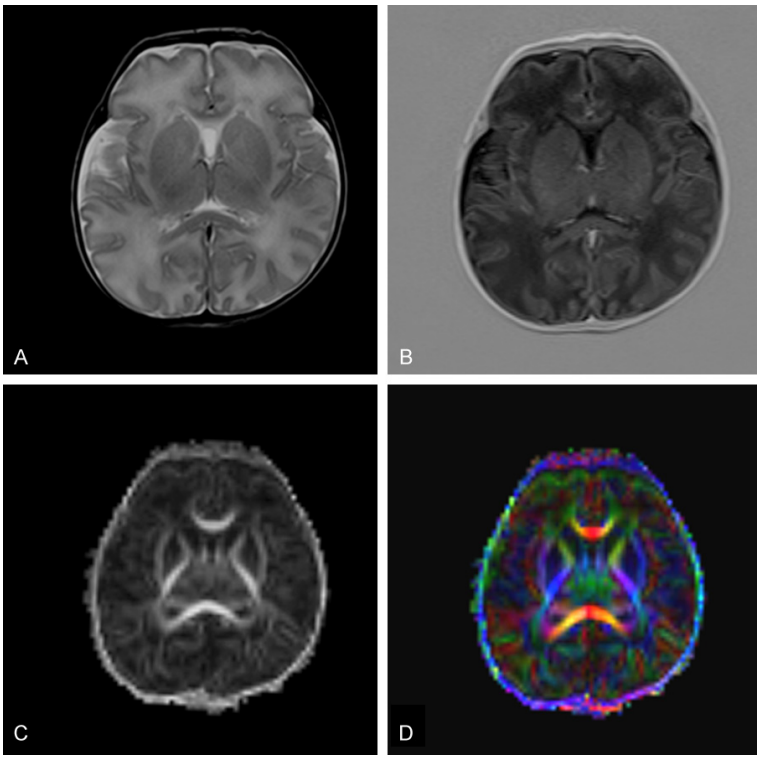

Figure 1. Examples of ROI measurement bedding plane images. DTI and conventional MRI images of a preterm neonate (the corrected gestational age was 37 weeks) with NRDS. A: The axial T_2WI image. B: The axial T_1WI image. C: The axial FA image. D: The axial directionally encoded color map (DEC) image.

The average FA values of both sides were obtained after measurement of the FA values in the symmetrical parts of the bilateral cerebral hemispheres.

nCPAP treatment duration records

The nCPAP treatment duration in group C was recorded. The times of the nCPAP start and completion were recorded, and the clinical situation after the ventilator weaning was observed. The infants in group C were treated with nCPAP immediately after admission, with successful ventilator weaning at one time. Finally, the nCPAP treatment duration was calculated from the time of the nCPAP start to the completion and recorded as the number of days.

Statistical analysis

SPSS 23.0 statistical software was used for the data analysis. The measurement data with an abnormal distribution were represented by the median (interquartile range, IQR). The IQR was expressed as (lower quartile, upper quartile). The Kruskal-Wallis test was used for the statistical analyses of multiple groups, followed by pairwise comparisons. At the same time, the *p* value was corrected. The counting data were expressed as a percentage (%), and chi-square tests were used for the comparisons among groups. Meanwhile, the Spearman test was carried out to analyze the correlation between fractional anisotropy (caudate nucleus and occipital lobe) and the duration of the nCPAP treatment in group C. $P < 0.05$ indicated a statistically significant differences in all the statistical analyses.

Results

Comparison of the preterm infants' characteristics and the mothers' pregnancy circumstances among three groups

There were no significant differences in terms of birth weight, corrected gestational age during the examination, sex, singleton or twin, or delivery mode among the three groups ($P > 0.05$) (**Table 1**). Furthermore, no significant differences were found in the mothers' pregnancy periods among the three groups ($P < 0.05$), nor in the antenatal corticosteroid application, hypertensive disorders complicating pregnancy (HDCP), gestational diabetes mellitus (GDM), premature rupture of membrane (PROM), meconium-stained amniotic fluid (MSAF), or placental abruption (**Table 2**).

Conventional MRI scan performance

In group N, the subarachnoid space was widened in seven cases, and cavum septum pellucidum was found in one case. In group C, there were 21 cases of subarachnoid cavity widening and four cases of cavum septum pellucidum. Meanwhile, in group M, there were six cases of subarachnoid cavity widening and two cases of subarachnoid cavity widening with cavum septum pellucidum.

Table 1. Comparison of the preterm infants' characteristics among the three groups

	N (n = 11)	C (n = 24)	M (n = 11)	x^2	p
Male[b]	7 (64%)	11 (46%)	8 (72%)	1.320	0.517
Cesarean section[b]	9 (81%)	20 (83%)	6 (55%)	1.164	0.559
Single birth[b]	9 (81%)	19 (79%)	9 (82%)	0.051	0.975
BW (kg)[a]	1.30 (1.19, 1.57)	1.33 (1.20, 1.55)	1.53 (1.14, 1.67)	1.423	0.491
Corrected GA (weeks)[a]	36.42 (35.00, 37.29)	35.36 (34.93, 37.25)	35.00 (34.57, 37.00)	2.741	0.254

[a]Data represented as the median (lower quartile, upper quartile). [b]Data represented as a number (percentage, %). Corrected GA: Corrected gestational age during examination; BW: birth weight.

Table 2. Comparison of the preterm infants' mothers' pregnancy circumstances among the three groups

	N (n = 11)	C (n = 24)	M (n = 11)	x^2	P
Application antenatal corticosteroids	7 (64%)	20 (83%)	9 (82%)	1.828	0.401
HDCP	6 (55%)	11 (46%)	1 (9%)	5.718	0.057
GDM	1 (9%)	3 (13%)	4 (36%)	3.683	0.159
PROM	3 (27%)	5 (21%)	6 (55%)	4.117	0.128
MSAF	0	1 (4%)	0	0.937	0.626
Placental abruption	2 (18%)	4 (17%)	0	2.184	0.336

Data represented as a number (percentage, %). HDCP: Hypertensive disorders complicating pregnancy; GDM: Gestational diabetes mellitus; PROM: premature rupture of membrane; MSAF: meconium-stained amniotic fluid.

Table 3. Comparison of the FA values among the three groups

	N	C	M	x^2	*P*
Splenium of corpus callosum	606.31 (456.42, 647.58)	572.44 (486.50, 627.33)	476.67 (430.33, 622.00)	1.748	0.417
Genu of corpus callosum	456.83 (380.50, 541.22)	433.31 (346.61, 506.84)	366.61 (292.00, 413.00)	4.527	0.104
Posterior limb of internal capsule	565.55 (520.16, 591.43)	544.67 (509.85, 587.94)	495.94 (473.67, 553.36)	5.545	0.062
Lenticular nucleus	165.02 (157.78, 177.74)	163.95 (140.47, 176.91)	146.72 (134.83, 154.92)	5.639	0.060
Thalamus	186.60 (171.50, 203.77)	171.63 (142.22, 192.50)	169.63 (111.53, 198.60)	1.866	0.393
Caudate nucleus	62.06 (59.94, 66.33)	55.56 (51.57, 59.85)[a]	53.14 (48.67, 58.83)[a]	13.27	0.001
Frontal lobe	66.09 (60.92, 80.44)	66.52 (59.07, 74.50)	66.45 (53.24, 81.45)	0.260	0.878
Parietal lobe	98.00 (71.38, 154.35)	105.28 (87.36, 173.81)	100.40 (53.56, 144.58)	1.341	0.512
Occipital lobe	137.25 (97.11, 152.94)	116.58 (94.03, 142.86)	101.85 (89.50, 110.69)[a]	6.320	0.042
Cerebral peduncle	123.64 (114.44, 150.34)	126.64 (116.08, 158.98)	136.00 (115.87, 163.42)	0.388	0.824

Data represented as the median (lower quartile, upper quartile). [a]$P < 0.05$ versus group N.

Comparison of the FA values among the three groups

Regarding the comparison of the FA values in the ROIs among the three groups (**Table 3**), the FA values of the occipital lobes and caudate nuclei significantly differed among the three groups ($P < 0.05$). Furthermore, the pairwise comparisons (at the same time, the *P* value is corrected.) revealed that there was no significant difference in the FAs of the occipital lobes and caudate nuclei between groups M and C ($P > 0.05$); however, the caudate nucleus and occipital lobe FA values in group M significantly differed from those in group N ($P < 0.05$). Furthermore, a significant difference was found in the caudate nucleus FA values between groups C and N ($P < 0.05$).

Correlation between the nCPAP treatment durations and the caudate nucleus and occipital lobe FA values in group C

There was a negative correlation between the caudate nucleus FA and the nCPAP treatment duration in group C (Spearman's rank correlation coefficient $r_s = -0.682$, $P < 0.0001$, $P < 0.05$) (**Figure 2**). Meanwhile, no significant correlation was discovered between the occipital lobe FAs and the nCPAP treatment durations in

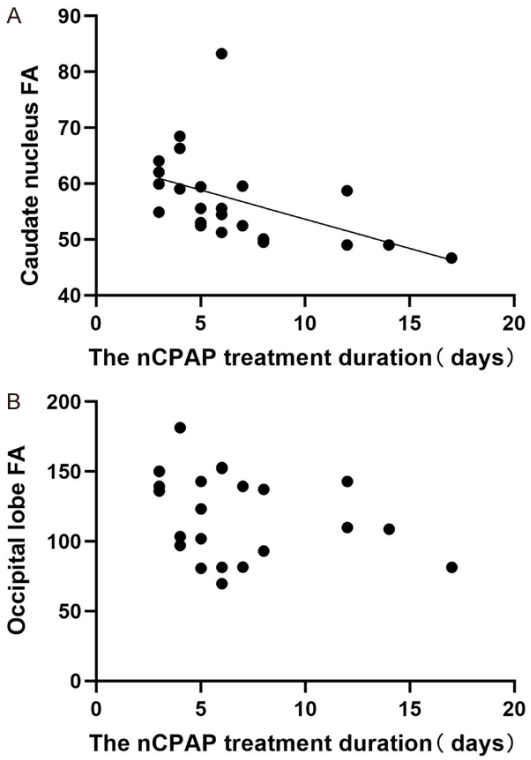

Figure 2. The relationship between the FA values of the two ROIs (the caudate nucleus, the occipital lobe) and the nCPAP treatment duration in group C. A. There was a negative correlation between the caudate nuclei FAs and the nCPAP durations in group C. B. There was no correlation between the occipital lobe FAs and the nCPAP treatment durations in group C.

group C (Spearman's rank correlation coefficient r_s = -0.276, P = 0.192, P > 0.05).

Discussion

In this study, conventional MRIs showed that there was no significant brain damage in preterm neonates with NRDS. However, DTI showed that the caudate nucleus FA values were lower in preterm neonates with NRDS when compared with the control group. Meanwhile, the occipital lobe FA values in infants with NRDS who needed mechanical ventilation were lower than they were in the control group. DTI is an imaging method developed from DWI for studying molecular diffusion properties. Notably, it is a noninvasive detection method for observing myelin sheath development and the structure of living tissue. FA is a common parameter of DTI, and FA value changes are associated with axon integrity and myelin maturity. FA values will decrease in patients who suffer brain damage and gradually increase with increased gestational age in preterm neonates. Furthermore, FA values represent the degree of white matter myelination [13-15]. The occurrence of hypoxemia, hyperoxia, hypercapnia, and high carbon dioxide partial pressure may lead to poor neurologic prognoses throughout the course of NRDS [16]. Meanwhile, hypocapnia can cause cerebral vasoconstriction, decreased cerebral blood flow, and aggravated cerebral ischemia, and mild hypercapnia can increase the cerebral blood flow. Mechanical ventilation is required in some neonates with NRDS. However, mechanical ventilation can cause hypocapnia and hyperoxia [17], which are risk factors for neonatal cystic periventricular leukomalacia (cPVL) [18]. The risk of NRDS is associated with lung immaturity in preterm neonates [19, 20]. Perinatal hypoxia can cause immature lung development and can lead to fragile neurons and glial damage. Prior research has found that the mechanism of perinatal hypoxia that affects neurodevelopment delays the maturation of astrocytes, oligodendrocytes, and neurons [21].

Caudate nuclei are fragile brain structures in preterm neonates that are adjacent to the germinal matrix, a structure that exists within the brain tissue of preterm neonates. Notably, the germinal matrix is a temporary structure that is involved in cell production during neurodevelopment. The germinal matrix contains thin-walled blood vessels that have a high risk of bleeding, which may inherently increase the risk of caudate nucleus injury [22-26]. Myelin sheath formation initiates from the tail and progresses to the head, and from the dorsal part to the ventral part. Occipital lobe myelination occurs earlier than in other ROIs, and occipital lobe damage has been associated with visual impairment [27]. In this study, there was no significant difference in FA among the three groups, including the corpus callosum splenium, corpus callosum genu, internal capsule posterior limb, lenticular nucleus, thalamus, frontal lobe, parietal lobe, or cerebral peduncle. This may be because NRDS has no significant effect on the neurodevelopment of these ROIs, or it may be related to this study's small sample size. Based on the results of this study, compared with preterm neonates without NRDS of the same corrected gestational age, preterm neonates with NRDS may present neuro-

developmental abnormalities in the early stages, even if conventional MRI shows no obvious brain damage [28].

The early application of nCPAP can reduce the use of mechanical ventilation in clinical practice [29]. However, some preterm neonates still require mechanical ventilation. As evidenced by previous studies, long-term assistance correlates with poor brain outcomes (reduced number and volume of oligodendrocytes, and white matter damage) regardless of the ventilation pattern. Furthermore, some scholars believe that endotracheal intubation during mechanical ventilation also affects the neurodevelopment of infants [30]. However, in this study, there was no significant difference in the FA values of each ROI between the preterm neonates with NRDS who required endotracheal intubation with mechanical ventilation and those who required nCPAP only. Before or after endotracheal intubation mechanical ventilation, nCPAP is generally applied. As for the lack of any significant differences in the FAs between the groups, this might be related to the combined use of other therapeutic approaches, in addition to mechanical ventilation, in the preterm neonates with NRDS who required mechanical ventilation in this study. Also, this discrepancy could be explained by the technical factors (scanner, imaging parameters, and coils), different techniques (ROI, voxel-based analysis, or tractography), DTI quantitative tools (FSL, DTI-Studio, or in-house software), and the pre- and post-processing methods. Furthermore, there was no significant difference between the occipital lobe FA values in the preterm neonates with NRDS in the nCPAP treatment group and those in the control group. The reason for this observation may be that there were no abnormal neurodevelopment changes in the occipital lobe in preterm neonates with NRDS who received nCPAP treatment. Therefore, in this study, the occipital lobe FA values in the preterm neonates with NRDS in the nCPAP treatment group had no significant correlation with the nCPAP treatment times.

Conclusion

Preterm neonates with NRDS may have neurodevelopmental abnormalities in the early stages of life compared to those without NRDS. Long-term follow-up is required to explore whether the abnormalities will improve to normal at a later period of life or whether NRDS results in irreversible changes. Meanwhile, the nCPAP treatment duration correlated with the neurodevelopment of preterm neonates with NRDS. Importantly, the results of this study provide imaging evidence of the neurodevelopment of preterm neonates with NRDS at the early stages of life.

Acknowledgements

The authors thank all parents and infants who participated in this study and all team members in charge of data collection. This work was supported by a grant from the National Natural Science Foundation of China (No. 80870983).

Disclosure of conflict of interest

None.

Address correspondence to: Dr. Xiaoan Zhang, Department of Radiology, The Third Affiliated Hospital of Zhengzhou University, Zhengzhou, China; Institute of Neuroscience, Zhengzhou University, Zhengzhou 450052, China. Tel: +86-(371)66962262; E-mail: zxa@zzu.edu.cn

References

[1] Li Y, Wang W and Zhang D. Maternal diabetes mellitus and risk of neonatal respiratory distress syndrome: a meta-analysis. Acta Diabetol 2019; 56: 729-740.

[2] Pang H, Zhang B, Shi J, Zang J and Qiu L. Diagnostic value of lung ultrasound in evaluating the severity of neonatal respiratory distress syndrome. Eur J Radiol 2019; 116: 186-191.

[3] McGrath MM, Sullivan MC, Lester BM and Oh W. Longitudinal neurologic follow-up in neonatal intensive care unit survivors with various neonatal morbidities. Pediatrics 2000; 106: 1397-1405.

[4] Sobotka SA and Msall ME. Supporting vulnerable children after life-threatening neonatal illness: opportunities for improving outcomes. J Pediatr 2016; 178: 12-14.

[5] Thygesen SK, Olsen M, Ostergaard JR and Sorensen HT. Respiratory distress syndrome in moderately late and late preterm infants and risk of cerebral palsy: a population-based cohort study. BMJ Open 2016; 6: e011643.

[6] Thygesen SK, Olsen M, Pedersen L, Henderson VW, Østergaard JR and Sørensen HT. Respiratory distress syndrome in preterm infants and

risk of epilepsy in a Danish cohort. Eur J Epidemiol 2018; 33: 313-321.
[7] Yan R, Han D, Ren J, Zhai Z, Zhou F and Cheng J. Diagnostic value of conventional MRI combined with DTI for neonatal hyperbilirubinemia. Pediatr Neonatol 2018; 59: 161-167.
[8] Ball G, Counsell SJ, Anjari M, Merchant N, Arichi T, Doria V, Rutherford MA, Edwards AD, Rueckert D and Boardman JP. An optimised tract-based spatial statistics protocol for neonates: applications to prematurity and chronic lung disease. Neuroimage 2010; 53: 94-102.
[9] Isayama T, Chai-Adisaksopha C and McDonald SD. Noninvasive ventilation with vs without early surfactant to prevent chronic lung disease in preterm infants: a systematic review and meta-analysis. JAMA Pediatr 2015; 169: 731-739.
[10] Sweet DG, Carnielli V, Greisen G, Hallman M, Ozek E, Plavka R, Saugstad OD, Simeoni U, Speer CP, Vento M and Halliday HL; European Association of Perinatal Medicine. European consensus guidelines on the management of neonatal respiratory distress syndrome in preterm infants--2013 update. Neonatology 2013; 103: 353-368.
[11] De Luca D, van Kaam AH, Tingay DG, Courtney SE, Danhaive O, Carnielli VP, Zimmermann LJ, Kneyber MCJ, Tissieres P, Brierley J, Conti G, Pillow JJ and Rimensberger PC. The Montreux definition of neonatal ARDS: biological and clinical background behind the description of a new entity. Lancet Respir Med 2017; 5: 657-666.
[12] Jensen CF, Sellmer A, Ebbesen F, Cipliene R, Johansen A, Hansen RM, Nielsen JP, Nikitina OH, Petersen JP and Henriksen TB. Sudden vs pressure wean from nasal continuous positive airway pressure in infants born before 32 weeks of gestation. JAMA Pediatr 2018; 172: 824-831.
[13] Qiu A, Mori S and Miller MI. Diffusion tensor imaging for understanding brain development in early life. Annu Rev Psychol 2015; 66: 853-876.
[14] O'Gorman RL, Bucher HU, Held U, Koller BM, Hüppi PS and Hagmann CF; Swiss EPO Neuroprotection Trial Group. Tract-based spatial statistics to assess the neuroprotective effect of early erythropoietin on white matter development in preterm infants. Brain 2015; 138: 388-397.
[15] Ouyang M, Jeon T, Sotiras A, Peng Q, Mishra V, Halovanic C, Chen M, Chalak L, Rollins N, Roberts TPL, Davatzikos C and Huang H. Differential cortical microstructural maturation in the preterm human brain with diffusion kurtosis and tensor imaging. Proc Natl Acad Sci U S A 2019; 116: 4681-4688.
[16] Sweet DG, Carnielli V, Greisen G, Hallman M, Ozek E, Plavka R, Saugstad OD, Simeoni U, Speer CP, Vento M, Visser GH and Halliday HL. European consensus guidelines on the management of respiratory distress syndrome - 2016 update. Neonatology 2017; 111: 107-125.
[17] Cashen K, Reeder R, Dalton HJ, Berg RA, Shanley TP, Newth CJL, Pollack MM, Wessel D, Carcillo J, Harrison R, Dean JM, Tamburro R and Meert KL; Eunice Kennedy Shriver National Institute of Child Health and Human Development Collaborative Pediatric Critical Care Research Network. Hyperoxia and hypocapnia during pediatric extracorporeal membrane oxygenation: associations with complications, mortality, and functional status among survivors. Pediatr Crit Care Med 2018; 19: 245-253.
[18] Wang LW, Lin YC, Wang ST and Huang CC; on behalf of the Taiwan Premature Infant Developmental Collaborative Study Group. Identifying risk factors shared by bronchopulmonary dysplasia, severe retinopathy, and cystic periventricular leukomalacia in very preterm infants for targeted intervention. Neonatology 2018; 114: 17-24.
[19] Rimar Z, Milas V, Medimurec M and Mesić I. Respiratory distress syndrome in newborns of gestational age of over 32 weeks. Coll Antropol 2014; 38: 621-626.
[20] Mahoney AD and Jain L. Respiratory disorders in moderately preterm, late preterm and early term infants. Clin Perinatol 2013; 40: 665-678.
[21] Salmaso N, Jablonska B, Scafidi J, Vaccarino FM and Gallo V. Neurobiology of premature brain injury. Nat Neurosci 2014; 17: 341-346.
[22] Nosarti C, Allin MP, Frangou S, Rifkin L and Murray RM. Hyperactivity in adolescents born very preterm is associated with decreased caudate volume. Biol Psychiatry 2005; 57: 661-666.
[23] Nosarti C, Giouroukou E, Healy E, Rifkin L, Walshe M, Reichenberg A, Chitnis X, Williams SC and Murray RM. Grey and white matter distribution in very preterm adolescents mediates neurodevelopmental outcome. Brain 2008; 131: 205-217.
[24] Nosarti C, Shergill SS, Allin MP, Walshe M, Rifkin L, Murray RM and McGuire PK. Neural substrates of letter fluency processing in young adults who were born very preterm: alterations in frontal and striatal regions. Neuroimage 2009; 47: 1904-1913.
[25] Isaacs EB, Gadian DG, Sabatini S, Chong WK, Quinn BT, Fischl BR and Lucas A. The effect of early human diet on caudate volumes and IQ. Pediatr Res 2008; 63: 308-314.

[26] Drury PP, Davidson JO, Mathai S, van den Heuij LG, Ji H, Bennet L, Tan S, Silverman RB and Gunn AJ. nNOS inhibition during profound asphyxia reduces seizure burden and improves survival of striatal phenotypic neurons in preterm fetal sheep. Neuropharmacology 2014; 83: 62-70.

[27] Nijman J, Gunkel J, de Vries LS, van Kooij BJ, van Haastert IC, Benders MJ, Kersbergen KJ, Verboon-Maciolek MA and Groenendaal F. Reduced occipital fractional anisotropy on cerebral diffusion tensor imaging in preterm infants with postnatally acquired cytomegalovirus infection. Neonatology 2013; 104: 143-150.

[28] Howlett A, Ohlsson A and Plakkal N. Inositol in preterm infants at risk for or having respiratory distress syndrome. Cochrane Database Syst Rev 2019; 7: CD000366.

[29] Sandri F, Plavka R, Ancora G, Simeoni U, Stranak Z, Martinelli S, Mosca F, Nona J, Thomson M, Verder H, Fabbri L and Halliday H; CURPAP Study Group. Prophylactic or early selective surfactant combined with nCPAP in very preterm infants. Pediatrics 2010; 125: e1402-1409.

[30] Loeliger M, Inder T, Cain S, Ramesh RC, Camm E, Thomson MA, Coalson J and Rees SM. Cerebral outcomes in a preterm baboon model of early versus delayed nasal continuous positive airway pressure. Pediatrics 2006; 118: 1640-1653.