

Original Article

Posterior vertebral single pedicle screw reduction and fixation promoting union, alleviating pain, and improving neurological function in patients with traumatic b-type thoracolumbar fractures

Xueqian Chen, Zhiou He, Zhiliang He, Zhenguo Wang

Department of Orthopedics, Beijing Tongzhou Integrative Medicine Hospital, Beijing, China

Received December 9, 2019; Accepted January 13, 2020; Epub April 15, 2020; Published April 30, 2020

Abstract: Objective: This study was designed to explore the effects of posterior vertebral single pedicle screw reduction and fixation in promoting union, alleviating pain and improving neurological function in patients with traumatic b-type thoracolumbar fractures. Methods: The clinical data of 101 patients with traumatic b-type thoracolumbar fractures in our hospital were retrospectively collected, and the patients were divided into 2 groups according to the treatment method, with 50 in the control group (CG), who underwent routine double-segment three-vertebra fixation through the injured vertebra, and 51 in the observation group (OG), who underwent posterior vertebral single pedicle screw reduction and fixation. The two groups were compared in terms of the surgical indicators, preoperative and postoperative Oswestry (ODI) disability index values, the anterior vertebral body compression ratios (AVBCR), Cobb angles, and changes in their visual analogue scale (VAS) and American Spinal Injury Association (ASIA) scores. Results: Compared with the CG, the OG reported shorter operation times, lower ODI, AVBCR, Cobb angle, and VAS scores one month after the operation and at the last follow-up ($P < 0.05$). The data reported by the OG were lower than the data of the CG in terms of the patients' composition ratios at grades A, B and C, but they were higher when referring to the patients at grades D and E ($P < 0.05$). Conclusion: Posterior vertebral single pedicle screw reduction and fixation can promote union, alleviate pain, and improve neurological function in patients with traumatic b-type thoracolumbar fracture.

Keywords: Traumatic, b-type thoracolumbar fracture, posterior vertebral single pedicle screw reduction and fixation, pains, neurological function, union

Introduction

The thoracolumbar segment of the spine is defined as the conjunction between the thoracic kyphosis and the lumbar lordosis, and it is extremely vulnerable to injury and faces a high risk segment of spine fractures, especially b-type thoracolumbar fractures [1]. B-type thoracolumbar fractures are generally caused by a sharp external traction and involve the anterior and posterior segments of the spine, complicating the injury of adjacent intervertebral disks, which are specifically embodied as a separation of the anatomical structure of the vertebral body and an enlargement of the space. This type of fracture can be classified as an unstable fracture [2, 3].

According to studies, a b-type thoracolumbar fracture with a neurologic or spinal injury is characterized by a high incidence rate. In such cases, the key to the surgical treatment lies in the spinal decompression and reconstruction of the stability of the anterior segment [4]. As the spine involves complicated injury mechanisms and an anatomic structure with severe injury complications, the clinical treatment is somehow special as well [5]. Previously, patients were treated with traditional posterior pedicle screw fixation across the injured segment, which, though it reduced the fracture, failed to structure a comparative stable system and led to higher difficulty when fixing and reducing the injured spinal segments in the middle, in which case, after the reduction, the

vertebral body may lose its angle and height, and result in severe complications such as delayed paralysis, delayed kyphosis of the vertebral body, etc. in severe conditions [6, 7]. In addition, the surgery requires fixation across the injured segment, during which, at least 3 adjacent spinal segments are exposed and the paravertebral muscles are dragged for a rather long period of time, which causes injuries to the local muscles, a stiff waist or back, chronic pain, etc. [8].

To improve the mechanical performance of fixing the three spinal segments, ensure the stability of the fixation and reduction, avoid injury to the waist and back muscles, and reduce the number of fixed vertebrae, this study applied the innovative posterior vertebral single pedicle screw reduction and fixation in the treatment of traumatic b-type thoracolumbar fracture.

Materials and methods

Materials

The clinical data of 101 patients with traumatic b-type thoracolumbar fracture in Beijing Tongzhou Integrative Medicine Hospital were retrospectively collected, and the patients were divided into 2 groups according to the treatment method, with 50 in the control group (CG), including 31 males and 19 females, who underwent a routine double-segment three-vertebra fixation through the injured vertebra, and 51 in the observation group (OG), including 33 males and 18 females, who underwent a posterior vertebral single pedicle screw reduction and fixation. (1) Inclusion criteria: patients who were diagnosed with b-type thoracolumbar fractures through CT and X-ray examinations before the operation were included on the basis that they had an obvious history of spinal trauma, an intact vertebral pedicle at the injured segment, and vertebral bodies incompletely bursting out, but no surgical contraindications or obvious osteoporosis. All the patients provided their informed consent to participate in the study, which was approved by the Ethics Committee of Beijing Tongzhou Integrative Medicine Hospital. (2) Exclusion criteria: some patients were excluded as they had secondary pathological fractures, multiple vertebral body fractures, vertebral pedicle fractures, injury at the upper and lower end plates of the fractured vertebra at the same time; a previous history of thoracic

and lumbar operations or trauma, surgical contradictions, or they withdrew from the study in the middle.

Methods

CG: after satisfactory general anesthesia administered through the trachea cannula and subject to continuous ECG monitoring, the patients lied prostrate with the belly projecting up, the shoulders, chest, and pelvis elevated to maintain the spinal segment at the chest and waist parts over the extension; under the guidance of a C-arm X-ray machine, the protruded site of the injured vertebra was pressurized for reduction; with the injured vertebra as the center, a surgical incision was made right in the middle (10-15 cm) to cut open the skin. From the back fascia of the subcutaneous tissue to the spinous process tip, an electrotome was used to make a separation along both sides of the spinous process and close to the periosteum to isolate the erector spinae until the outer edge of the processus transversus so as to fully expose the facet joint processes on both sides of the normal vertebra above and below the adjacent fractured vertebra; the nail entry point was on the crista lambdoidalis at the lumbar vertebra, and at the slightly outward position of the longitudinal bisection line intersection of the upper articular process base and facet joint for thoracic vertebra; referring to the spinal plane and under the guidance of the C-arm x-ray machine, the nail entry position was observed carefully to make sure it was correct; 4 pedicle screws were respectively placed into the vertebral arches on both sides. If the patients had nerve symptoms before the operation, the reduction of the injured vertebra was evaluated during the operation. If, through perspective observation, the reduction was not quite acceptable, then before fixation with the pedicle screws, a window was opened on the vertebral plate for decompression and careful exploration; the connecting rod was installed between the pedicle screws on both sides, and the pedicle screw caps of the vertebral body at the tail of the injured vertebra were locked. An expander was used to expand the upper and lower vertebral bodies while the screw caps were locked, and the horizontal connecting rod was properly installed to reinforce the system against rotation; again the C-arm X-ray machine was used for a perspective observation to

make sure the connecting rods and pedicle screws were installed and secured at the right places; the wound was then rinsed, placed with a drainage tube on both sides, and then sutured and closed from layer to layer.

OG: after satisfactory anesthesia through the trachea cannula and subject to continuous ECG monitoring, the patients lied prostrate with the belly projecting up in the air, the shoulders, chest, and pelvis elevated to maintain the spinal segment at the chest and waist parts over the extension; under the guidance of a C-arm X-ray machine, the injured vertebra was positioned. Referring to the injured vertebra and the vertebra adjacent to the endplate of the fractured vertebra, a shadow was cast onto the central point of the vertebral pedicle, and a mark was made on the skin; the vertebral pedicle was then punctured and at the mark, and four longitudinal cuttings were made to cut open the skin and the deep fascia. The paravertebral muscles were separated from layer to layer with an exaggerated sleeve until reaching the processus transversus and processus articularis; under the guidance of the anterior and posterior x-ray machine, and with the outer edge of the shadow of the vertebral pedicle as the puncturing point, the needle was slowly inserted parallel to the endplate at an internal angle of 10-15°. Once it entered the sclerotin by about 2 cm, the C-arm x-ray machine was started to observe and make sure the needle tip was inside the shadow of vertebral pedicle but not breaking the inner edge, and then it turned to the lateral perspective to make sure the puncture needle was parallel to the endplate, and between the upper and lower edges of the vertebral pedicle. The puncturing continued until about 0.5-1 cm in front of the rear edge of the vertebral body. Afterwards, the inner core was removed, the guide wire was inserted, and the puncture needle was removed, and replaced by 4 pedicle screws at the proper size, whose positions were confirmed under the C-arm x-ray machine. The connecting rod was installed, the screw caps were preliminarily tightened, followed by an expansion and reduction to recover the height of the vertebral body of the injured vertebra and the physiological curvature of the spine, and to correct the posterior kyphosis angle; the screw caps were tightened and observed under the C-armed x-ray machine to make sure the connecting rods and the pedicle screws were at the

right positions; the wound was then rinsed, placed with a drainage tube on both sides, and then sutured and closed from layer to layer. In the case of neurothripsis after the reduction or unsatisfactory reduction of fractured blocks in the canalis spinalis, it was cut open and reduced again by twisting off the tail end of the lengthened screw at one side, removing the connecting rod to separate the paravertebral muscle between the two screws and expose the foramen intervertebrale and processus articularis. Passing through the foramen intervertebrale to enter the canalis spinalis, the bone fracture block was reduced, and the canalis spinalis was decompressed. At this point, the connecting rod was reinstalled.

Both groups received 24 days of routine treatment against infection. 24-48 h after the operation, the drainage tubes were removed, and 3-5 d later, the patients were allowed to walk on the ground with supports. 10-12 d later, the sutures were removed.

Observation indicators

(1) Surgical indicators: the 2 groups were compared in terms of their amount of bleeding, operation times, follow-up times, and length of stay.

(2) Oswestry (ODI) disability index: both groups answered a 10-item questionnaire before and 1 month after the operation, and at the last follow-up. The questionnaire covered travelling, sex life, social life, sleeping, lifting, standing, walking, sitting, personal care, and pain intensity. For each item, the total possible score is 5, which indicates that the patients have obvious dysfunction, while 0 means exactly the opposite. "Excellent" is defined as a total scale score between 0 and 20, "good" between 21 and 40, and worse above 41. The dysfunction degree is positively associated with the score [9, 10]. The scale has a Cronbach's α of 0.852.

(3) AVBCR: the 2 groups were compared for AVBCR before and 1 month after the operation, and at the last follow-up. The anterior vertebral body height ratio (%) = Anterior vertebral body height/the average anterior height of the adjacent upper and lower vertebral bodies \times 100% [11].

(4) Cobb angle: the 2 groups were compared for Cobb angle before and 1 month after the oper-

Table 1. ASIA Grading criteria

Grade	Performance
A Complete injury	No sensory or motor functions reserved at the sacral segment S4.5
B Incomplete injury	Instead of motor function, only sensory function reserved under the neural plane
C Incomplete injury	Motor function reserved under the neural plane, and the animal force of 1/2 of the key muscles under grade 3
D Incomplete injury	Motor function reserved under the neural plane, and the animal force of 1/2 of the key muscles at or over grade 3
E Normal	Normal motor and sensory functions

Table 2. Comparison of the OG and the CG in terms of clinicopathological data [n (%)]/($\bar{x} \pm s$)

Data	OG (n=51)	CG (n=50)	t/χ^2	P
Gender (n)				
Male	33 (64.71)	31 (62.00)	1.759	0.185
Female	18 (35.29)	19 (38.00)		
Age (y)	37.89 \pm 3.28	37.82 \pm 3.26	0.108	0.915
Cause of injury				
Traffic accident	23 (45.10)	24 (48.00)	0.039	0.788
Falling from a height	18 (35.29)	15 (30.00)		
Other	10 (19.61)	11 (22.00)		
Injured segment				
T11	8 (15.69)	7 (14.00)	0.015	0.856
T12	17 (33.33)	16 (32.00)		
L1	16 (31.37)	15 (30.00)		
L2	10 (19.61)	12 (24.00)		

expressed as the mean \pm standard deviation, the comparison studies were carried out using independent-samples T tests for data which were normally distributed, and Mann-Whitney U tests for data which were not normally distributed. Paired tests were used for pre-and-pro comparisons in a group; in case of nominal data expressed as [n (%)], comparison studies were carried out using χ^2 tests for the intergroup comparisons. The numerical data before and 1 month after the operation, and at the last follow-up were analyzed using ANOVA. For all the statistical comparisons, significance was defined as $P < 0.05$.

ation, and at the last follow-up, which can be used to evaluate the recovery of the vertebral body sequence and the physiological curvature of the spine.

(5) Visual analogue scale (VAS): the pain intensity before and 1 month after the operation, and at the last follow-up was evaluated using VAS scores, indicated by any number from 0 to 11 based on the patient's subjective feeling. 0 indicates no pain, and 10 the worst possible pain. A higher pain intensity means a higher score [12]. The scale has a Cronbach's α of 0.823.

(6) American Spinal Injury Association (ASIA) grading: before and 1 month after the operation, and at the last follow-up, the patients' spine function was evaluated using the ASIA grading criteria specified in **Table 1** [13, 14]. For the ASIA grading criteria, the Cronbach's α is 0.758.

Statistical analysis

The statistical analysis was performed with SPSS22.0. In the case of numerical data

Results

Clinicopathological data

There were no significant statistical differences in terms of gender, age, cause of injury, or injured segment between the OG and the CG ($P > 0.05$, **Table 2**).

Comparison of the surgical indicators

The operation times and intraoperative amounts of bleeding were (72.15 \pm 5.23) min and (108.92 \pm 5.62) ml in the OG, (108.96 \pm 12.58) min and (195.26 \pm 13.28) ml in the CG ($t = 19.279$, 42.697 , $P < 0.05$); the lengths of stay and follow-up times were (17.85 \pm 1.52) d and (11.05 \pm 2.18) d in the OG, (18.02 \pm 1.58) d and (11.09 \pm 2.13) d in the CG ($t = 0.551$, 0.093 , $P > 0.05$) (**Figure 1**).

Comparison of the ODI scores

Before the operation, the two groups exhibited no statistical differences in terms of their ODI scores; 1 month after the operations and at the last follow-up, both groups attained an obvious

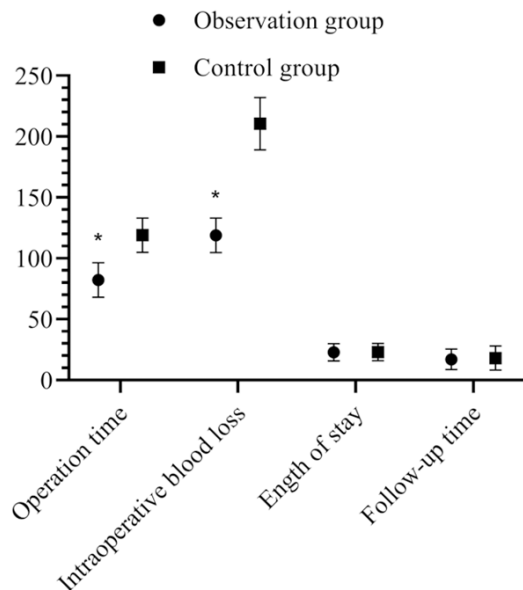


Figure 1. Comparison between the OG and the CG for in surgical indicators. The OG reported shorter operation times and less intraoperative amounts of bleeding than the CG ($P < 0.05$); but in terms of length of stay and follow-up time, no difference was observed ($P > 0.05$). * indicates $P < 0.05$ as compared with the CG.

Table 3. Comparison of the OG and the CG in ODI Scores ($\bar{x} \pm s$, score)

Group	Before operation	1 month after operation	At the last follow-up
CG (n=50)	38.82±5.12	28.15±3.26 [#]	11.28±1.96 ^{#,*}
OG (n=51)	38.56±5.23	22.52±4.12 [#]	7.32±1.28 ^{#,*,*}
t	0.252	7.606	12.045
P	0.801	0.000	0.000

Note: [#] indicates $P < 0.05$ as compared with the conditions before the operation; ^{*} indicates $P < 0.05$ as compared with the conditions at 1 month after the operation; ^{*} indicates $P < 0.05$ as compared with the CG.

decrease to a lower level ($P < 0.05$); compared with the CG, and the ODI scores reported by the OG 1 month after the operations and at the last follow-up were far lower ($P < 0.05$, **Table 3**).

Comparison of AVBCR

Before the operations, no statistical difference was shown between the 2 groups in AVBCR; at 1 month after operations and at the last follow-up, an obvious decrease was observed in both groups ($P < 0.05$), which was more significant in the OG compared with the CG ($P < 0.05$, **Table 4**).

Comparison of Cobb angle

The Cobb angles of the 2 groups were not statistically different from each other before the operations ($P > 0.05$) or at the last follow-up when compared with the results obtained 1 month after the operation ($P > 0.05$), but they gradually reduced 1 month after the operations and at the last follow-up ($P < 0.05$); compared with the CG, the Cobb angles reported by the OG 1 month after operation and at the last follow-up were smaller ($P < 0.05$, **Table 5**).

Comparison of the VAS scores between the OG and the CG

The VAS score was (7.63 ± 1.56) in the OG and (7.68 ± 1.53) in the CG ($t = 0.163$, $P > 0.05$); 1 month after operation and at the last follow-up, the VAS scores dropped to (1.35 ± 0.15) and (0.82 ± 0.12) in the OG, lower than those of the CG, which were (2.86 ± 0.63) and (1.96 ± 0.68) ($t = 16.644$, 11.788 , $P < 0.05$) (**Figure 2**).

Comparison of ASIA grading between the OG and the CG before and after operation

Before the operation, 10 (19.61%), 19 (37.25%), 15 (29.41%), 7 (13.73%), and 0 (0.00%) patients in the OG were classified in grades A, B, C, D, and E respectively, while in the CG, the corresponding data were 11 (22.00%), 17 (34.00%), 16 (32.00%), 6 (12.00%), and 0 (0.00%) ($\chi^2 = 0.088$, 0.023, 0.852, 0.632, $P > 0.05$) (**Figure 3**).

At the last follow-up, the patients classified in grades A, B, C, D, and E changed to 0, 0, 15, 20, and 16 in the OG, accounting for 0.00%, 0.00%, 29.41%, 39.22% and 31.37% respectively, and in grades 5, 7, 18, 15, and 5 in the CG, accounting for 10.00%, 14.00%, 36.00%, 30.00%, and 10.005%. The number of patients in grades A, B and C was lower, and the number of patients in grades D and E was higher in the OG ($\chi^2 = 5.366$, 7.672, 8.526, 9.635, 10.258, $P < 0.05$) (**Figure 4**).

Discussion

Clinically, thoracolumbar fracture is a common spinal fracture type not requiring surgical treatment in most cases. But in patients with b-type thoracolumbar fractures, the spinal stability has been destroyed or the never tissues are compressed and the spine is dislocated, surgi-

Table 4. Comparison between the OG and the CG for AVBCR ($\bar{x} \pm s$, %)

Group	Before operation	1 month after operation	At the last follow-up
CG (n=50)	35.69±4.09	14.52±3.28 [#]	14.06±3.19 [#]
OG (n=51)	35.62±4.15	10.05±2.12 ^{#,*}	10.03±2.09 ^{#,*}
t	0.085	8.116	7.494
P	0.932	0.000	0.000

Note: [#] indicates P<0.05 as compared with the conditions before the operation; ^{*} indicates P<0.05 as compared with the CG.

Table 5. Comparison between the OG and the CG in the Cobb angles ($\bar{x} \pm s$)

Group	Before operation	1 month after operation	At the last follow-up
CG (n=50)	23.65±3.15	15.96±1.52 [#]	15.92±1.49 [#]
OG (n=51)	23.68±3.09	9.85±1.52 ^{#,*}	9.13±1.46 ^{#,*}
t	0.048	20.198	23.132
P	0.962	0.000	0.000

Note: [#] indicates P<0.05 as compared with the conditions before the operation; ^{*} indicates P<0.05 as compared with the CG.

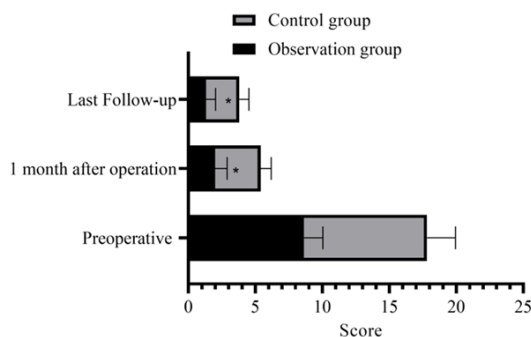


Figure 2. Comparison of the OG and the CG in VAS scores. Before the operation, the OG had a VAS score not significantly different from the CG's (P>0.05). 1 month after operation and at the last follow-up, the VAS scores were lower in the OG compared with the CG (P<0.05). * indicates P<0.05 as compared with the CG.

cal treatment is necessary [15]. The surgical treatment serves is mainly to reduce and fix the fractured spine, recover the normal force line of canalis spinalis, stabilize the spinal structure, and remove the compression on the spinal cord or nerve root, so as to effectively prevent secondary injury complications and help the patients recover [16]. In the past, traditional vertebral pedicle fixation across the injured vertebra was adopted to treat patients with traumatic b-type thoracolumbar fractures. How-

ever, it not only brings in unsatisfactory reduction effects, but it also easily results to fixture breakage, loss of angle and height after vertebral body reduction, or even delayed paralysis or delayed kyphosis of the vertebral body in the severe cases [2, 17]. Jia et al. [18] found through research that about 1/2 of the posterior short section fixations across the injured vertebra are accompanied by an ineffective fixture or the loss of a reduction angle. Responding to those shortages, scholars made some improvements in the surgical method by placing 2 vertebral pedicle screws into the injured vertebra, and named it the vertebral pedicle screw fixation in the injured vertebra. According to the mechanical analysis, the pedicle screws placed into the injured vertebra can obviously reinforce stability, improve the stress system, and promote the reduction of the injured vertebra. So far, the technique has been extensively applied in the clinic and has significantly improved the

clinical treatment effects [19]. With the accelerated development of the vertebral pedicle screw fixation in the injured vertebra, some scholars believe that general vertebral pedicle screw fixation refers to the double-segment three-vertebra pedicle screw fixation, which, though it can reduce the fractured vertebra at a higher quality and reinforce the stability of internal fixation to eliminate the loss of postoperative correction and height of the vertebral body, requires another 2 screws and segments to be fixed, which may obviously reduce the degree of the fixed segments from bending laterally, twisting, extending and folding. Most of the stress concentrates on the segments not fixed, while the movement amplitude of the adjacent segments will increase to compensate, accelerating the degradation of the disk between the upper and the lower sections [20, 21]. In addition, in this operation, the paravertebral muscles have to be extensively isolated, which may hinder the recovery of the function of the lumbar and dorsal muscles and lead to stiffness and pain. In view of this, the clinical studies are enhanced, and the single-vertebra fixation is born correspondingly.

In vertebral single pedicle screw reduction and fixation, vertebral pedicle screws are placed between the injured vertebra and the vertebra

Posterior vertebral single pedicle screw reduction improves fracture

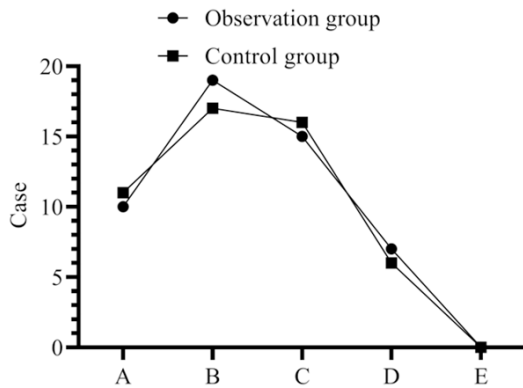


Figure 3. Comparison of the OG and the CG in the ASIA grades before the operations. Before the operations, 10, 19, 15, 7, and 0 patients in the OG were classified in grades A, B, C, D, and E, while in the CG, the corresponding numbers of patients were 11, 17, 16, 6, and 0 ($P>0.05$).

adjacent to the injured endplate. After reduction, the screw system is applied in only one space between the vertebrae [22]. The results of this study revealed that compared with the CG, the OG reported a shorter operation time, less intraoperative amount of bleeding, lower ODI, AVBCR, and VAS scores, and a smaller Cobb angle 1 month after the operation and at the last follow-up ($P<0.05$). It is suggested that the reduction and fixation of the single intervertebral pedicle screw through the posterior approach can promote fracture healing, relieve pain, and improve nerve function in patients with traumatic type B thoracolumbar fractures. This may be because vertebral single pedicle screw reduction and fixation only needs one intervertebral fixation, which can reduce the loss of spinal motion segments, promote the maximum preservation of spinal motor function, and because it has a reliable biomechanical stability simultaneously. It is conducive to the recovery of the normal intervertebral disc activity of the injured endplate and reduction of the intervertebral disc degeneration [23]. What's more, the placement of screws in the injured vertebra is conducive to the formation of mass effect in the injured vertebra, thus promoting the reduction of the injured vertebra space after reduction. The screw placed in the injured vertebra can also play a direct prying effect, which can promptly restore the height of the anterior edge of the injured vertebra, thereby achieving an ideal reduction effect of the fracture vertebra [1]. Finally, the shortening of the longitudinal connecting rod can reduce the

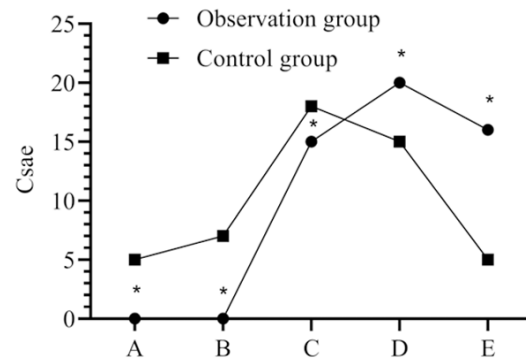


Figure 4. Comparison in the OG and the CG in the ASIA grading after the operations. After the operation, the patients classified in grades A, B, and C were reduced to 0, 0, and 15 in the OG, and in the CG, they were 5, 7, and 1. The patients in grades D and E were 20 and 16 in the OG, and 15 and 5 in the CG. * indicates $P<0.05$ compared with the CG.

stress load of the nail rod, decrease the possibility of internal fixation fracture, and avoid the loss of postoperative correction. The results of this study also showed that the composition ratios of the patients at grades A, B, and C in the OG were lower than they were in the CG, while the composition ratios of patients at grades D and E were higher than they were in the CG ($P<0.05$). This further proves the effectiveness of the posterior vertebral single pedicle screw reduction and fixation through the posterior approach, which can reduce the degree of spinal injury. The mechanism may be as follows: the single vertebra distraction operation can be performed after the screw placement of the injured vertebra; the short distraction distance and large longitudinal tension between the annulus fibrosus and the ligament can promote the reduction of the fracture block, and after the successful reduction of the fracture block, the degree of spinal injury can also be significantly reduced [24]. In addition, this operative method can also reduce the amount of screw placement needed, reduce medical costs, and significantly improve the stability of the fixation system, which can effectively prevent the secondary loss of postoperative vertebral correction and height, and reduce the failure rate of internal fixation.

In conclusion, compared with the traditional double-segment three-vertebra fixation through the injured vertebra, the posterior vertebral single pedicle screw reduction and fixation is more suitable for patients with traumatic b-type thoracolumbar fracture as it can promote

union, alleviate pain, and improve neurological function.

However, this study employed a small cohort. In the future, the sample size shall be further expanded for a more in-depth and explorative study.

Disclosure of conflict of interest

None.

Address correspondence to: Xueqian Chen, Department of Orthopedics, Beijing Tongzhou Integrative Medicine Hospital, No. 89, Chezhan Road, Tongzhou District, Beijing 101199, China. Tel: +86-18001319082; E-mail: pr8pvp@163.com

References

- [1] Li K, Zhang W, Liu D, Xu H, Geng W, Luo D and Ma J. Pedicle screw fixation combined with intermediate screw at the fracture level for treatment of thoracolumbar fractures: a meta-analysis. *Medicine (Baltimore)* 2016; 95: e4574.
- [2] Dobran M, Nasi D, Brunozzi D, di Somma L, Gladi M, Iacoangeli M and Scerrati M. Treatment of unstable thoracolumbar junction fractures: short-segment pedicle fixation with inclusion of the fracture level versus long-segment instrumentation. *Acta Neurochir (Wien)* 2016; 158: 1883-1889.
- [3] Zeng J, Gong Q, Liu H, Rong X and Ding C. Complete fracture-dislocation of the thoracolumbar spine without neurological deficit: a case report and review of the literature. *Medicine (Baltimore)* 2018; 97: e0050.
- [4] Chang W, Zhang D, Liu W, Lian X, Jiao Z and Chen W. Posterior paraspinal muscle versus post-middle approach for the treatment of thoracolumbar burst fractures: a randomized controlled trial. *Medicine (Baltimore)* 2018; 97: e11193.
- [5] Cao D, Zhang S, Yang F, Shen K and Tan Z. Hidden blood loss and its influencing factors after percutaneous kyphoplasty surgery: a retrospective study. *Medicine (Baltimore)* 2018; 97: e0435.
- [6] Cornelis I, Monticelli P and De Decker S. Postoperative symptomatic haematoma and pneumorrhachis in a dog with a thoracolumbar intervertebral disc extrusion. *Aust Vet J* 2016; 94: 467-469.
- [7] Passias PG, Soroceanu A, Smith J, Boniello A, Yang S, Scheer JK, Schwab F, Shaffrey C, Kim HJ, Protosaltis T, Mundis G, Gupta M, Klineberg E, Lafage V and Ames C; International Spine Study Group. Postoperative cervical deformity in 215 thoracolumbar patients with adult spinal deformity: prevalence, risk factors,

and impact on patient-reported outcome and satisfaction at 2-year follow-up. *Spine (Phila Pa 1976)* 2015; 40: 283-291.

- [8] Wang XL, Zhu XP, Ji DX, Wang J, Zhai RH, Li P and Yang XF. Beneficial effect of traditional Chinese medicine fumigation "Bone-healing Powder" in postoperative pain and recovery of neurological function of traumatic thoracolumbar spine fractures: a case-control study. *Medicine (Baltimore)* 2018; 97: e11983.
- [9] Baradaran A, Ebrahimzadeh MH, Birjandinejad A and Kachooei AR. Cross-cultural adaptation, validation, and reliability testing of the modified Oswestry disability questionnaire in Persian population with low back pain. *Asian Spine J* 2016; 10: 215-9.
- [10] van Hooff ML, Mannion AF, Staub LP, Ostelo RW and Fairbank JC. Determination of the Oswestry disability index score equivalent to a "satisfactory symptom state" in patients undergoing surgery for degenerative disorders of the lumbar spine-a spine tango registry-based study. *Spine J* 2016; 16: 1221-1230.
- [11] Newell N, Grant CA, Keenan BE, Izatt MT, Percy MJ and Adam CJ. Quantifying progressive anterior overgrowth in the thoracic vertebrae of adolescent idiopathic scoliosis patients: a sequential magnetic resonance imaging study. *Spine (Phila Pa 1976)* 2016; 41: E382-E387.
- [12] Runer A, Wierer G, Herbst E, Hepperger C, Herbert M, Gföller P, Hoser C and Fink C. There is no difference between quadriceps and hamstring tendon autografts in primary anterior cruciate ligament reconstruction: a 2-year patient-reported outcome study. *Knee Surg Sports Traumatol Arthrosc* 2018; 26: 605-614.
- [13] Martinez-Perez R, Paredes I, Cotrina J, Pandey S and Lagares A. F. 01 Prognostic factors in adults with spinal cord injury without radiological abnormalities (SCIWORA): MRI study. *Can J Neurol Sci* 2016; 43: S18-S19.
- [14] Ouchida J, Yukawa Y, Ito K, Katayama Y, Matsumoto T, Machino M, Inoue T, Tomita K and Kato F. Delayed magnetic resonance imaging in patients with cervical spinal cord injury without radiographic abnormality. *Spine (Phila Pa 1976)* 2016; 41: E981-E986.
- [15] Wood KB. Commentary of acute and hyperacute thoracolumbar corpectomy for traumatic burst fractures using a mini-open lateral approach. *Spine (Phila Pa 1976)* 2018; 43: E125.
- [16] Liu H, Qian BP, Qiu Y, Wang Y, Wang B, Yu Y and Zhu ZZ. Vertebral body or intervertebral disc wedging: which contributes more to thoracolumbar kyphosis in ankylosing spondylitis patients?: a retrospective study. *Medicine (Baltimore)* 2016; 95: e4855.
- [17] Zhang H and Li Q. Improved vacuum sealing drainage for treatment of surgical site infec-

- tion following posterior spinal internal fixation: a case report. *Medicine (Baltimore)* 2018; 97: e9952.
- [18] Liu J, Zhu LJ, Jiang EZ, Bao XG, Hu B, Niu DY and Xu GH. C1-C2 pedicle screw fixation for adolescent with os odontoideum associated atlantoaxial dislocation and a compound reduction technique for irreducible atlantoaxial dislocation. *Chin Med J (Engl)* 2019; 132: 1253-1256.
 - [19] Kim SB, Won Y, Sin LJ, Rhee JM, Lee SW and Lee GS. Unilateral spinous process noncovering hook type patient-specific drill template for thoracic pedicle screw fixation. *Spine (Phila Pa 1976)* 2017; 42: E1050-E1057.
 - [20] Di HX, Liu FY, Yang SD, Wang H, Yang DL and Ding WY. Short-segment fixation with a cement-augmented pedicle screw for Kummell disease. *Medicine (Baltimore)* 2017; 96: e8617.
 - [21] Wei XZ, Zhou XY, Yang YL, Xu XM, Li JF, Bai YS, Zhu XD, Li M and Wang F. Key vertebral pedicle screw strategy for the correction of flexible Lenke type 1 adolescent idiopathic scoliosis. *Spine (Phila Pa 1976)* 2017; 42: 1226-1232.
 - [22] Collinge CA and Crist BD. Combined percutaneous iliosacral screw fixation with sacroplasty using resorbable calcium phosphate cement for osteoporotic pelvic fractures requiring surgery. *J Orthop Trauma* 2016; 30: e217-e222.
 - [23] Orita S, Inage K, Sainoh T, Fujimoto K, Sato J, Shiga Y, Kanamoto H, Abe K, Yamauchi K, Aoki Y, Nakamura J, Matsuura Y, Suzuki T, Kubota G, Eguchi Y, Terakado A, Takahashi K and Ohtori S. Lower lumbar segmental arteries can intersect over the intervertebral disc in the oblique lateral interbody fusion approach with a risk for arterial injury: radiological analysis of lumbar segmental arteries by using magnetic resonance imaging. *Spine (Phila Pa 1976)* 2017; 42: 135-142.
 - [24] Sugawara T, Higashiyama N, Kaneyama S and Sumi M. Accurate and simple screw insertion procedure with patient-specific screw guide templates for posterior C1-C2 fixation. *Spine (Phila Pa 1976)* 2017; 42: E340-E346.