

## Original Article

# Arthroscopic surgery plus intra-articular sodium hyaluronate affects meniscus injury

Junqin Qiu\*, Jinglai Xue\*, Ren Lin, Wei Lin

Department of Orthopedics, Fuzhou Second Hospital Affiliated to Xiamen University, Fuzhou, Fujian Province, China. \*Equal contributors.

Received December 11, 2019; Accepted January 8, 2020; Epub April 15, 2020; Published April 30, 2020

**Abstract:** Objective: To investigate the clinical effects of arthroscopic surgery combined with intra-articular sodium hyaluronate injection for meniscus injury. Methods: A total of 130 patients with meniscus injury were assigned into two groups. The control group (n=65) underwent arthroscopic surgery, while the observation group (n=65) underwent arthroscopic surgery combined with intra-articular sodium hyaluronate injection. Results: After surgery, the ability of knee function, pain, and quality of life were observed. The Lysholm score of the observation group was significantly higher than that of the control group at 2, 3, 4, and 5 weeks after surgery (all  $P < 0.05$ ). The visual analogue scale score of the observation group was significantly lower than that of the control group at 4 and 8 weeks after surgery (both  $P < 0.05$ ). The total effective rate in the observation group was 98.46%, which was significantly higher than 89.23% in the control group ( $P < 0.05$ ). Additionally, the 5 scores in the Quality of Life Questionnaire-C30 were all significantly lower in the observation group than in the control group at 6 months after surgery (all  $P < 0.05$ ). Conclusion: Arthroscopic surgery and intra-articular sodium hyaluronate injection for patients with meniscus injury can effectively improve the knee function, relieve pain, elevate the efficacy, and benefit quality of life.

**Keywords:** Meniscus injury, arthroscopy, sodium hyaluronate injection, knee function, quality of life

## Introduction

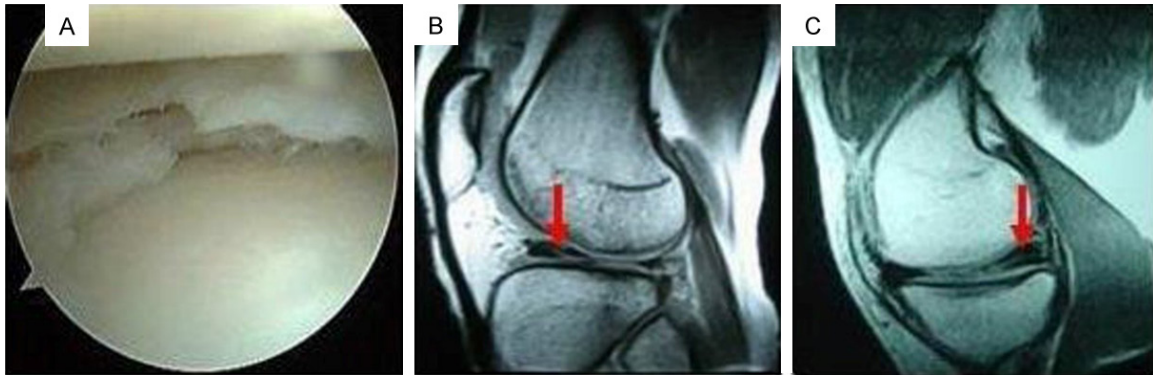
Meniscus injury, commonly seen in clinic, can be caused by trauma or joint degeneration [1-3]. Meniscus injury caused by severe trauma is usually accompanied by soft tissue injury in the knee such as the cruciate ligament and cartilage, which is very likely to cause swelling [4, 5]. Meniscus injury mainly leads to localized pain in the knee joint and affects the quality of life of the patient. At present, the general treatment for meniscus injury in clinic is meniscus resection [6-8]. However, simple meniscus resection does not retain the undamaged meniscus, but changes the stress distribution of the knee joint, and eventually leads to degeneration of the knee joint, which increases the incidence of osteoarthritis [9, 10]. In contrast, the preservation of the undamaged meniscus is conducive to postoperative recovery by improving the stability of the joint [11]. Arthroscopic surgery can preserve the undamaged meniscus, but the clinical efficacy is quite var-

ied. Intra-articular injection of sodium hyaluronate is a promising conservative treatment method [12-14]. However, sodium hyaluronate injection is currently only used to improve joint function in patients with no obvious meniscus injury. There is no previous study confirming the effect of sodium hyaluronate injection under arthroscopy. Therefore, this study included 130 patients with meniscus injury to explore the efficacy of the combination, hoping for better results than simple arthroscopic surgery.

## Materials and methods

### General data

A total of 130 patients with meniscus injury admitted to Fuzhou Second Hospital Affiliated to Xiamen University from January 2017 to February 2018 were enrolled in this study. A randomized digital table method was used for grouping, with 65 patients in each group. In the observation group, there were 39 males and 26 females, aged 32 to 76 years, with an



**Figure 1.** Meniscus injury in patients. A: Meniscus injury (under arthroscope); B: Lateral meniscus injury; C: Medial meniscus injury.

average age of ( $54.4 \pm 0.3$ ) years. In the control group, there were 37 males and 28 females, aged 33 to 76 years, with an average age of ( $54.7 \pm 0.5$ ) years. Informed consent was obtained from all participants in the study, and the Medical Ethics Committee of Fuzhou Second Hospital Affiliated with Xiamen University's ethics committee approved the study.

Patients were eligible if they were diagnosed with meniscus injury caused by trauma, which was in need of clearing of the joint cavity by arthroscopy and partial meniscectomy; patients who did not receive prior surgical treatment, patients without conservative treatment or drug therapy within two weeks; patients having ASA grade I-II; patients who were willing to receive surgery and drug injection; and patients who behaved favorably with compliance. Patients were excluded if they had coagulopathy or severe organ function impairment; patients who did not meet the inclusion criteria; or who were allergic to drugs injected.

#### Methods

The meniscus injury of all patients was observed, as shown in **Figure 1**. **Figure 1A** shows the meniscus injury under arthroscope. **Figure 1B** and **1C** are the internal and external meniscus injuries presented by Magnetic Resonance Imaging.

The control group was treated with arthroscopy alone. First, continuous epidural anesthesia was performed after the patient was instructed to be in a supine position. Second, the arthroscope was inserted from the anterolateral and anteromedial side of the knee with the help of

balloon tourniquet. Third, the synovial tissue, free body, etc. in the joint were cleared to clarify the meniscus injury. If the meniscus injury was small, the undamaged meniscus was retained; if the injury was large, the meniscus was completely removed. Lastly, the incision was sutured and pressure bandaged.

The observation group was treated with arthroscopic surgery combined with intra-articular injection of sodium hyaluronate. Before the end of the conventional arthroscopic surgery, 2 mL of sodium hyaluronate (Matsumoto Chemical, Japan) was administered to the knee (first injection), and the specification was 2 mL: 20 mg. After the first injection, each patient was given 2 mL of sodium hyaluronate each week for 8 weeks. The patient was notified to come to the hospital 1-2 days before each dose. After treatment, the patient was called at each follow-up time point to answer questionnaires, and was asked whether there were side effects such as joint stiffness or abnormal pain.

#### Outcome measures

The main outcome measures were knee function (Lysholm) and visual analogue scale (VAS) scores. The Lysholm score was evaluated before surgery and 2, 3, 4, and 5 weeks after surgery. Higher score indicates better knee function, with a total score of 100 points. VAS score was evaluated before surgery as well as 4 and 8 weeks after surgery. Higher score indicates more severe pain, with a total score of 10 points.

The secondary measures included quality of life and clinical efficacy. Five scores in the qual-

# Arthroscopic surgery plus sodium hyaluronate injection

**Table 1.** Comparison of general data

Group/item	Age (year)	Sex		Injured knee		Operation time (min)	Blood loss (mL)
		Male	Female	Left	Right		
Observation group	54.4±0.3	39	26	32	33	68.5±9.4	72.45±8.35
Control group	54.7±0.5	37	28	36	29	71.3±7.2	76.36±6.88
t value	5.674	4.867	5.236	6.474	7.357	5.579	7.168
P value	0.468	0.625	0.521	0.415	0.381	0.486	0.413

**Table 2.** Comparison of Lysholm scores ( $\bar{x} \pm sd$ )

Group	Cases	Lysholm score				
		Before surgery	2 weeks after surgery	3 weeks after surgery	4 weeks after surgery	5 weeks after surgery
Observation group	65	54.45±4.75	69.35±5.27 <sup>#</sup>	76.54±5.64 <sup>##,&amp;</sup>	83.38±5.37 <sup>###,Δ</sup>	90.57±3.69 <sup>###,▲</sup>
Control group	65	55.34±5.26	60.53±5.41 <sup>#</sup>	67.52±5.29 <sup>##,&amp;</sup>	74.56±5.34 <sup>###,Δ</sup>	80.25±5.69 <sup>###</sup>
P value		0.265	0.048	0.049	0.028	0.015

Compared with before surgery, <sup>#</sup>P<0.05, <sup>##</sup>P<0.01, <sup>###</sup>P<0.001; compared with 2 weeks after surgery, <sup>&</sup>P<0.05; compared with 3 weeks after surgery, <sup>Δ</sup>P<0.05; compared with 4 weeks after surgery, <sup>▲</sup>P<0.05.

ity of life questionnaire (QLQ)-c30 scale were observed 6 months after surgery, including: trouble with sleeping, tension, irritability, trouble doing strenuous activities, and fatigue. Lower score indicates better quality of life, with a total score of 20 points. The clinical efficacy was evaluated as follows. Markedly effective: normal knee joint function, no pain, and high quality of life; effective: basically normal knee joint function, no clear pain, and medium quality of life; ineffective: disordered knee joint function, severe pain, and poor quality of life. Total effective rate = (case of markedly effective + case of effective)/total number of cases \* 100%.

## Statistical analyses

SPSS 19.0 statistical software was used to process the data. The measurement data were presented as mean  $\pm$  standard deviation ( $\bar{x} \pm sd$ ), and compared by independent sample t test. Data at multiple time points were tested by repeated measurement analysis of variance combined with Bonferroni's post hoc. The counted data were presented as percentage, and compared by chi-square test. P<0.05 indicated a statistically significant difference.

## Results

### Comparison of general data

There were 39 males and 26 females in the observation group, with an average age of

(54.4±0.3) years old, while there were 37 males and 28 females in the control group, with an average age of (54.7±0.5) years old. There were no significant differences between the two groups in terms of age, sex, injury, operation time and intraoperative blood loss (all P>0.05). See **Table 1**.

### Comparison of Lysholm scores

There was no significant difference in preoperative Lysholm scores between the observation group and the control group (P>0.05), while the score was significantly higher in the observation group than in the control group at 2, 3, 4, and 5 weeks after surgery, with statistically significant differences (all P<0.05). See **Table 2** and **Figure 2**.

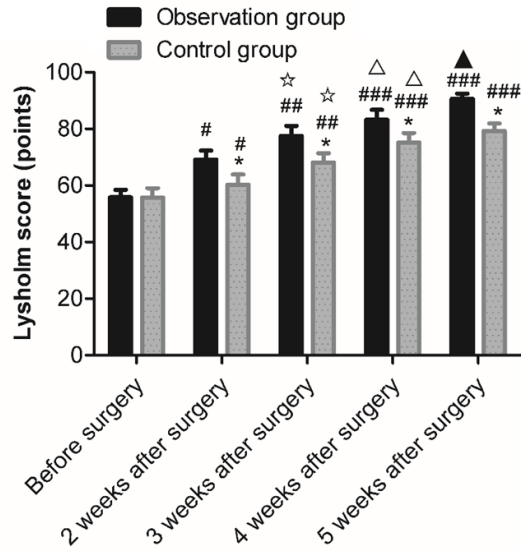
### Comparison of VAS scores

There was no significant difference in preoperative VAS scores between the observation group and the control group (P>0.05), while the score was significantly lower in the observation group than in the control group at 4, and 8 weeks after surgery, with statistically significant differences (both P<0.05). See **Table 3**.

### Comparison of efficacy

The total effective rate of the observation group (98.46%) was significantly higher than that of the control group (89.23%), with a statistically significant difference (P<0.05). See **Table 4**.

## Arthroscopic surgery plus sodium hyaluronate injection



**Figure 2.** Comparison of Lysholm scores. Compared with observation group \* $P < 0.05$ ; compared with before surgery, # $P < 0.05$ , ## $P < 0.01$ , ### $P < 0.001$ ; compared with 2 weeks after surgery, \* $P < 0.05$ ; compared with 3 weeks after surgery,  $\Delta P < 0.05$ ; compared with 4 weeks after surgery,  $\blacktriangle P < 0.05$ .

### Comparison of the 5 scores in the QLQ-c30 scale

The 5 scores in the QLQ-c30 scale were significantly lower in the observation group than in the control group at 6 months after operation, with statistically significant differences (all  $P < 0.05$ ). See **Table 5** and **Figure 3**.

### Discussion

This study investigated the value of arthroscopic surgery combined with sodium hyaluronate injection for the treatment of meniscus injury, and found that the above treatment can improve the knee function and pain in patients. In general, patients with meniscus injury have significant impairments in knee function and are suffering from varying degrees of pain [15, 16]. Therefore, evaluation of different treatment methods for meniscus injury can be carried out from the aspects of knee function and pain score after treatment. Study confirmed that arthroscopic surgery is better than traditional knee surgery in relieving pain and in accelerating postoperative recovery [17]. However, arthroscopic surgery may result in joint instability after surgery. Sodium hyaluronate injection, which plays a crucial role in the conservative treatment for knee injury, can improve joint sta-

bility [18, 19]. Sodium hyaluronate injection can only relieve symptoms but cannot cure the underlying injury. Therefore, the combination of the two is of great significance. Repeated measures analysis of variance in this study showed that the Lysholm scores of the two groups were different. To be specific, the scores were higher in the observation group than in the control group at 2, 3, 4, and 5 weeks after surgery. Moreover, the Lysholm score of the observation group showed time dependence: score at 3, 4, and 5 weeks after surgery were higher than that of the previous week, respectively; while the control group showed no significant difference in scores between 4 weeks and 5 weeks after surgery. It can be confirmed that after surgery, the knee joint function in the observation group was improved better and faster than that in the control group. Besides, the VAS scores of the observation group were significantly lower than those of the control group at 4 and 8 weeks after surgery, indicating that the degree of pain in the observation group was significantly lower than that of the control group. The reason could be the additional injection of sodium hyaluronate in the observation group. Sodium hyaluronate injection is a hyaluronic acid and a mucopolysaccharide. Therefore, injecting it into the joint cavity is conducive to the recovery of joint function.

The application of arthroscopic surgery combined with sodium hyaluronate injection can fully improve the treatment efficacy and the quality of life. The direct view of sodium hyaluronate injection under arthroscope in the observation group is better than indirect view, which may affect the injection into the lesions of the joint cavity, resulting in inferior efficacy [20, 21]. Injection of sodium hyaluronate into the joint cavity can supplement the endogenous hyaluronic acid deficiency in the joints, improve the nutrition of the joints, lubricate the joints, repair the damaged cartilage, improve the physical and chemical properties of the joints, expand the range of joint activity, and relieve pain. During the arthroscopic surgery, attention should be paid to avoid the narrowing of the joint space, so skilled surgeons are necessary. Compared with the control group, the treatment method in the observation group was safer and harmed less of the articular cartilage, showing a remarkable efficacy.

## Arthroscopic surgery plus sodium hyaluronate injection

**Table 3.** Comparison of VAS scores ( $\bar{x} \pm sd$ )

Group	Cases	VAS score		
		Before surgery	4 weeks after surgery	8 weeks after surgery
Observation group	65	8.65±0.77	5.33±0.85**	2.34±0.26***#
Control group	65	8.41±0.62	7.35±0.27*	5.84±0.37**
P value		0.525	0.029	0.036

Compared with before surgery, \*P<0.05, \*\*P<0.01, \*\*\*P<0.001; compared with 4 weeks after surgery, #P<0.05. VAS: visual analogue scale.

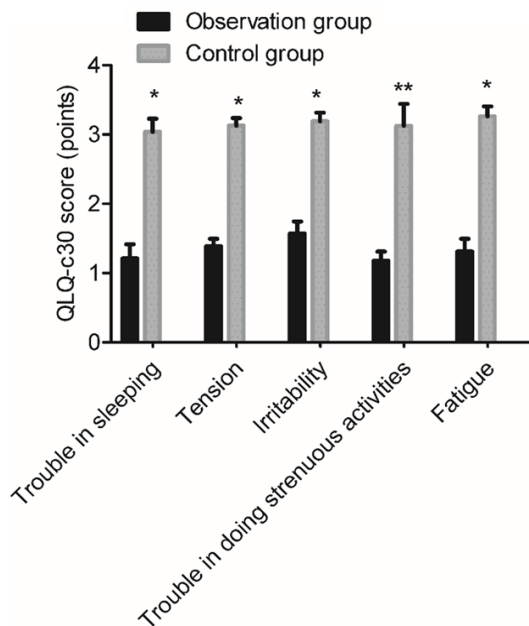
**Table 4.** Comparison of efficacy (n, %)

Group	Cases	Markedly effective	Effective	Ineffective	Effective rate
Observation group	65	58 (89.23)	6 (9.23)	1 (1.54)	64 (98.46)
Control group	65	55 (84.62)	3 (4.62)	7 (10.77)	58 (89.23)
$\chi^2$		0.609	1.074	4.795	4.795
P value		0.435	0.300	0.029	0.029

**Table 5.** Comparison of the 5 scores in the QLQ-c30 scale ( $\bar{x} \pm sd$ )

Group	Cases	QLQ-c30 score					Total score
		Trouble sleeping	Tension	Irritability	Trouble doing strenuous activities	Fatigue	
Observation group	65	1.25±0.32	1.38±0.15	1.54±0.24	1.13±0.19	1.34±0.25	5.30±0.90
Control group	65	3.05±0.24	3.12±0.16	3.21±0.17	3.08±0.38	3.17±0.24	12.46±1.19
T value		6.824	8.649	7.639	9.538	8.485	11.537
P value		0.037	0.012	0.024	0.002	0.016	0.000

Note: QLQ-c30: quality of life questionnaire-c30.



**Figure 3.** Comparison of the 5 scores in the QLQ-c30 scale. Compared with the control group, \*P<0.05, \*\*P<0.01.

The 8-week follow up in this study can only prove a short-term efficacy of the combination method than arthroscopic surgery alone. Further study is needed to investigate the long-term treatment effect, such as whether the efficacy is different after half a year. In summary, the combination of arthroscopic surgery and sodium hyaluronate injection for meniscus injury can effectively improve knee function, relieve pain, improve sleep quality and tension, and elevate the overall treatment efficacy.

### Disclosure of conflict of interest

None.

**Address correspondence to:** Wei Lin, Department of Orthopedics, Fuzhou Second Hospital Affiliated to Xiamen University, No. 47 Shangteng Road, Cangshan District, Fuzhou 350007, Fujian Province, China. Tel: +86-0591-22169106; Fax: +86-0591-22169106; E-mail: linwei77kk@163.com



References

- [1] Asai K, Nakase J, Oshima T, Shimozaki K, Toyooka K and Tsuchiya H. Lateral meniscus posterior root tear in anterior cruciate ligament injury can be detected using MRI-specific signs in combination but not individually. *Knee Surg Sports Traumatol Arthrosc* 2019; [Epub ahead of print].
- [2] Stanley LE, Kerr ZY, Dompier TP and Padua DA. Sex differences in the incidence of anterior cruciate ligament, medial collateral ligament, and meniscal injuries in collegiate and high school sports: 2009-2010 through 2013-2014. *Am J Sports Med* 2016; 44: 1565-1572.
- [3] Liu Y, Zhang J, Zhang S, Li R and Yue X. Concomitant ligamentous and meniscal injuries in floating knee. *Int J Clin Exp Med* 2015; 8: 1168-1172.
- [4] Mitchell JJ, Sjostrom R, Mansour AA, Irion B, Hotchkiss M, Terhune EB, Carry P, Stewart JR, Vidal AF and Rhodes JT. Incidence of meniscal injury and chondral pathology in anterior tibial spine fractures of children. *J Pediatr Orthop* 2015; 35: 130-135.
- [5] Mitchell J, Graham W, Best TM, Collins C, Currie DW, Comstock RD and Flanigan DC. Epidemiology of meniscal injuries in US high school athletes between 2007 and 2013. *Knee Surg Sports Traumatol Arthrosc* 2016; 24: 715-722.
- [6] Harato K, Niki Y, Kudo Y, Sakurai A, Nagura T, Hasegawa T, Masumoto K and Otani T. Effect of unstable meniscal injury on three-dimensional knee kinematics during gait in anterior cruciate ligament-deficient patients. *Knee* 2015; 22: 395-399.
- [7] McCready DJ and Ness MG. Systematic review of the prevalence, risk factors, diagnosis and management of meniscal injury in dogs: part 1. [corrected]. *J Small Anim Pract* 2016; 57: 59-66.
- [8] Dai H, Huang ZG, Chen ZJ and Liu JX. Diagnostic accuracy of ultrasonography in assessing meniscal injury: meta-analysis of prospective studies. *J Orthop Sci* 2015; 20: 675-681.
- [9] Bisson LJ, Phillips P, Matthews J, Zhou Z, Zhao J, Wind WM, Fineberg MS, Bernas GA, Rauh MA, Marzo JM and Kluczynski MA. Association between bone marrow lesions, chondral lesions, and pain in patients without radiographic evidence of degenerative joint disease who underwent arthroscopic partial meniscectomy. *Orthop J Sports Med* 2019; 7: 2325967119830381.
- [10] Abram SGF, Hopewell S, Monk AP, Bayliss LE, Beard DJ and Price AJ. Arthroscopic partial meniscectomy for meniscal tears of the knee: a systematic review and meta-analysis. *Br J Sports Med* 2019; [Epub ahead of print].
- [11] Leal MF, Arliani GG, Astur DC, Franciozi CE, Debieux P, Andreoli CV, Smith MC, Pochini Ade C, Eijnisman B and Cohen M. Comprehensive selection of reference genes for expression studies in meniscus injury using quantitative real-time PCR. *Gene* 2016; 584: 60-68.
- [12] Buckland J. Osteoarthritis: microRNA-mediated meniscal injury repair in rats. *Nat Rev Rheumatol* 2015; 11: 64.
- [13] Kloefkorn HE, Jacobs BY, Loye AM and Allen KD. Spatiotemporal gait compensations following medial collateral ligament and medial meniscus injury in the rat: correlating gait patterns to joint damage. *Arthritis Res Ther* 2015; 17: 287.
- [14] Singh A, Wei DT, Lin CTP, Liang S, Goyal S, Tan KA, Chin BZ and Krishna L. Concomitant meniscal injury in anterior cruciate ligament reconstruction does not lead to poorer short-term post-operative outcomes. *Knee Surg Sports Traumatol Arthrosc* 2018; 26: 1266-1272.
- [15] Rai MF and McNulty AL. Meniscus beyond mechanics: using biology to advance our understanding of meniscus injury and treatment. *Connect Tissue Res* 2017; 58: 221-224.
- [16] Astur DC, Xerez M, Rozas J, Debieux PV, Franciozi CE and Cohen M. Anterior cruciate ligament and meniscal injuries in sports: incidence, time of practice until injury, and limitations caused after trauma. *Rev Bras Ortop* 2016; 51: 652-656.
- [17] Karakasli A, Acar N, Basci O, Karaarslan A, Erduran M and Kaya E. Iatrogenic lateral meniscus anterior horn injury in different tibial tunnel placement techniques in ACL reconstruction surgery - a cadaveric study. *Acta Orthop Traumatol Turc* 2016; 50: 514-518.
- [18] Kocher MS, Tepolt FA and Vavken P. Meniscus transplantation in skeletally immature patients. *J Pediatr Orthop B* 2016; 25: 343-348.
- [19] Lin Z, Huang W, Ma L, Chen L, Huang Z, Zeng X, Xia H and Zhang Y. Kinematic features in patients with lateral discoid meniscus injury during walking. *Sci Rep* 2018; 8: 5053.
- [20] Fox AJ, Wanivenhaus F, Burge AJ, Warren RF and Rodeo SA. The human meniscus: a review of anatomy, function, injury, and advances in treatment. *Clin Anat* 2015; 28: 269-287.
- [21] Jiang D, Luo X, Ao Y, Gong X, Wang YJ, Wang HJ, Miao Y, Li N, Zhang JY and Yu JK. Risk of total/subtotal meniscectomy for respective medial and lateral meniscus injury: correlation with tear type, duration of complaint, age, gender and ACL rupture in 6034 Asian patients. *BMC Surg* 2017; 17: 127.