Int J Clin Exp Med 2021;14(2):947-953
www.ijcem.com /ISSN:1940-5901/IJCEM0123779

Original Article

The effect of minocycline on the IL-6, IL-1β, TNF-α, sICAM-1 and sVCAM-1 levels in the gingival crevicular fluid of chronic periodontitis patients

Shushu Wang[1*], Xinyi Xu[1*], Lingyan Shang[2], Jinhua Zhao[1]

[1]*Department of Stomatology, Changzhou TCM Hospital, Changzhou, Jiangsu, China;* [2]*Zhonglou District of Changzhou TCM Hospital, Changzhou, Jiangsu, China.* [*]*Equal contributors and co-first authors.*

Received October 9, 2020; Accepted November 24, 2020; Epub February 15, 2021; Published February 28, 2021

Abstract: Objective: This study aimed to investigate the effect of minocycline on the IL-6, IL-1β, TNF-α, sICAM-1, and sVCAM-1 levels in the gingival crevicular fluid (GCF) of patients with varying degrees of chronic periodontitis (CP). Method: A total of 85 patients with CP admitted to our hospital were recruited as the study cohort and randomly placed in a control group (n=42) or an experimental group (n=43). Both groups underwent routine treatment, and 3% hydrogen peroxide and 0.9% saline were used to flush their periodontal pockets. The patients in the experimental group were additionally treated with minocycline ointment. The changes in the IL-6, IL-1β, TNF-α, sICAM-1, and sVCAM-1 levels in the GCF were observed in the two groups. Results: After the minocycline intervention, the IL-6, IL-1β, TNF-α, sICAM-1 and sVCAM-1 levels in the GCF in the experimental group were significantly lower than they were in the control group ($P<0.05$). After minocycline intervention, the IL-6, IL-1β, TNF-α, sICAM-1 and sVCAM-1 levels in the GCF of the patients with different degrees of CP were significantly lower than they were before the intervention ($P<0.05$). Conclusion: Minocycline can reduce the inflammatory factor and adhesion factor levels in the GCF of patients with varying degrees of CP and shows positive therapeutic effects.

Keywords: Minocycline, chronic periodontitis, gingival fluid, inflammatory factors, adhesion factors

Introduction

Chronic periodontitis (CP) is a chronic infectious disease caused by dental plaque, genetic factors, defense mechanisms, and poor lifestyle habits [1]. Statistics show that about 35% of adults suffer from CP. Since the early symptoms are not obvious, many patients miss the best time for treatment due to negligence, and as the disease progresses, their periodontal conditions worsen, and about 15% will advance to moderate to severe chronic periodontitis [2]. CP is not just an oral disease. It is also closely associated with hypertension, diabetes, cardiovascular disease, kidney disease, and it increases the risk of developing other diseases as it progresses [3, 4]. The CP treatment period is long and is accompanied by loose teeth, a decreased chewing ability, gingival atrophy, acute swelling, and other symptoms [5]. Patients will experience anxiety and depression due to their long-term suffering. The higher the level of depression, the more severe the chronic periodontitis.

Gingival crevicular fluid (GCF) is a fluid that leaks from the epithelium of the sulcus and the combined epithelium into the gingival sulcus, which is minimal in healthy people, and its amount is positively correlated with the degree of inflammation in patients with CP [6]. The plaque index (PLI), probing depth (PD), clinical attachment loss (CAL), bleeding on probing (BOP), bleeding index (BI), and other indicators are non-objective. The conditions of patients with CP can be evaluated by measuring the biochemical parameters in the GCF. As the disease progresses, the composition and content of GCF change, so the measurement of GCF in patients with CP is a sensitive indicator of the degree of inflammation [7].

Minocycline is a kind of tetracycline that achieves antibacterial effects by binding to tRNA, and it is broad-spectrum, efficient, and long-lasting [8]. Due to its strong antibacterial activity and low side effects on human organs and the human nervous system, it has been widely used in CP treatment.

The aim of this study was to evaluate the clinical effect of minocycline in patients with CP by observing the changes in the content of the inflammatory factors IL-6, IL-1β, TNF-α and the adhesion factors sICAM-1 and sVCAM-1 in the GCF.

Materials and methods

General information

Eighty-five patients with CP who were diagnosed and treated in the Department of Dentistry of our hospital from May 2018 to May 2020 were enrolled as the study subjects, and all the patients met the diagnostic criteria for CP as determined by the 2017 World Workshop on the Classification of Periodontal and Peri-Implant Diseases and Conditions [9], including mild cases (20 patients), moderate cases (35 patients), and severe cases (30 patients).

Inclusion criteria: patients with at least 20 teeth, patients with a pocket depth >4 mm, and patients with no history of hypersensitivity to minocycline.

Exclusion criteria: patients with other acute or chronic infectious diseases, patients with diabetes mellitus, severe cardiovascular diseases, liver or kidney dysfunction, and patients who had undergone periodontal surgery or other antibiotic medication within one year prior to the start of this study.

The 85 subjects were divided into a control group (n=42, including 10 patients with mild, 16 patients with moderate, and 16 patients with severe CP) and an experimental group (n=43, including 10 patients with mild, 19 patients with moderate, and 14 patients with severe CP) using the random number table method. There were 25 males and 17 females in the control group, with an average age of (54.02±6.31) years, and there were 24 males and 19 females in the experimental group, with an average age of (53.79±6.09) years.

All the subjects voluntarily signed informed consent forms for their participation in this study. This study was reviewed and approved by the ethics committee of Changzhou TCM Hospital.

Methods

Intervention methods: The patients in both groups were given routine treatment and were followed up weekly with four visits.

The patients in the control group were given repeated rinses of their periodontal pockets using 3% hydrogen peroxide and 0.9% saline at the follow-up appointments.

After rinsing the periodontal pocket repeatedly with 3% hydrogen peroxide and 0.9% saline at each follow-up visit, the patients in the experimental group were instructed to dry the surface by blocking-up their saliva flows into the oral cavity. The patient's periodontal pockets were filled with minocycline ointment (Sunstar INC Japan, H20100244), with a slight overflow as appropriate. The patients were told to abstain from food and water for 2 hours.

GCF collection: The plaque was removed from the teeth without pulp or apical lesions. Their mouths were rinsed with water, their tooth surfaces were dried, and their gums were gently dried.

A 2 mm × 8 mm sterile paper strip was inserted into their gingival sulci or periodontal pockets, and the insertion was stopped when a slight resistance was encountered. After 30 s, the paper strip was retrieved and placed in a centrifuge tube for weighing, and the weight of the gingival fluid was obtained by calculating the difference in mass before and after the collection. After weighing, the paper strip was placed in a -70°C freezer. If there were blood stains on a paper strip, it was discarded for resampling.

Determination of the IL-6, IL-1β, TNF-α, sICAM-1 and sVCAM-1 levels: ELISA was used to determine the IL-6, IL-1β, TNF-α, sICAM-1, and sVCAM-1 levels.

The samples were equilibrated with all the items in the ELISA kit at room temperature and measured according to the instructions of the IL-6, IL-1β, TNF-α, sICAM-1, and sVCAM-1 ELISA kits (Shenzhen Jingmei Biotechnology Co.).

Outcome measurement

IL-6, IL-1β and TNF-α levels: IL-6 is a multifunctional inflammatory factor that can act on target cells and is associated with the immune,

Table 1. Comparison of the general clinical parameters ($\bar{x}$ ± s)/[n (%)]

Baseline data		Control group (n=42)	Experimental group (n=43)	t/X^2	P
Sex	Male	25	24	-0.333	0.795
	Female	17	19		
Average age (years)		54.02±6.31	53.79±6.09	0.186	0.853
Average weight (kg)		52.64±4.05	52.17±5.80	0.426	0.673
Average duration (years)		11.17±2.87	10.74±2.99	0.621	0.538

hematopoietic, and defensive functions. IL-6 regulates the production of proteins during the acute inflammatory phase, exacerbates the inflammatory response in patients with CP, and decreases the repair function of the periodontal tissue [10]. The higher the IL-6 level, the more severe the inflammatory response.

IL-1β is secreted by macrophages and endothelial cells and regulates the leukocyte polypeptides and activates the inflammatory responses. Patients with elevated IL-1β levels have an activated inflammatory response, and when the IL-1β level is greatly elevated, it promotes the hydrolysis of metalloproteinases and extracellular matrix proteases, further destroying periodontal collagen fibers and aggravating the inflammatory response, leading to a vicious cycle [11, 12].

TNF-α is a small molecular weight protein that regulates the cellular function and the inflammatory and immune responses. Elevated TNF-α levels in CP patients can inhibit alkaline phosphatase activity, activate osteoclast activity, increase alveolar bone resorption, and aggravate periodontal soft tissue damage [13].

The sICAM-1 and sVCAM-1 levels: sICAM-1 is produced by the *in situ* cleavage of ICAM-1 and modulates the adhesion response of the inflammatory factors to the microvascular endothelial cells. ICAM-1 is closely associated with the inflammatory response of the periodontal tissue, immune mechanisms, and tissue repair in patients with CP. When sICAM-1 is elevated, this indicates a high expression of ICAM-1, and the neutrophils in the lesion are activated, which in turn increases the inflammatory response [14].

VCAM-1 can bind to VLA-4 and accumulate at the infection sites, thereby amplifying the inflammatory response. When sVCAM-1 is elevated in patients, the inflammatory response is increased [15, 16].

Statistical analysis

The statistical analysis of the data was performed using SPSS 22.0 software. The measurement data were expressed in the form of mean ± standard deviation ($\bar{x}$ ± s), and t-tests were used to compare the differences between the groups. P<0.05 was considered a significant difference.

Results

Comparison of the differences in the baseline data in the two groups of patients

There were no significant differences in terms of the general data, such as gender, age, or disease duration between the two groups (P> 0.05), which were comparable (**Table 1**).

Comparison of the changes in the IL-6, IL-1β, and TNF-α levels

Before the intervention, there were no significant differences in the IL-6, IL-1β, or TNF-α levels in the two groups' GCF (P>0.05), but after intervention, there was a significant decrease in the IL-6, IL-1β, and TNF-α levels (P<0.05) (**Table 2**).

Comparison of the sICAM-1 and sVCAM-1 levels

Before intervention, there were no significant differences in the sICAM-1 and sVCAM-1 levels in the patients' gingival fluid in both groups (P>0.05). After the intervention, the sICAM-1 and sVCAM-1 levels in the gingival fluid of the patients in both groups showed significant decreases compared with the pre-intervention period levels, with sICAM-1 (10.35±1.68) and sVCAM-1 (16.87±2.45) in the gingival fluid of the control group, and sICAM-1 (8.74±0.93) and sVCAM-1 (11.50±1.46) in the gingival fluid of the experimental group, showing significant

Table 2. Comparison of inflammatory factors ($\bar{x} \pm s$)

Items	Control group (n=42)		Experimental group (n=43)	
	Pre-intervention	Post-intervention	Pre-intervention	Post-intervention
IL-6 (pg/mL)	114.23±11.95	91.26±7.09*,#	113.60±11.87	54.02±5.77*,#
IL-1β (ng/L)	241.02±22.98	196.48±18.33*,#	243.38±21.83	153.86±15.11*,#
TNF-α (mg/L)	4.33±1.28	3.12±0.92*,#	4.43±1.46	2.02±1.06*,#

Note: Compared with pre-intervention, *P<0.05. Compared with the control group, #P<0.05.

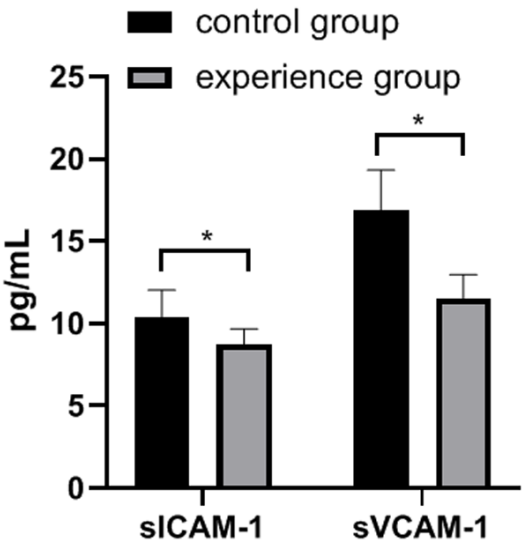

Figure 1. Changes in the sICAM-1 and sVCAM-1 after the intervention in both groups. *P<0.05.

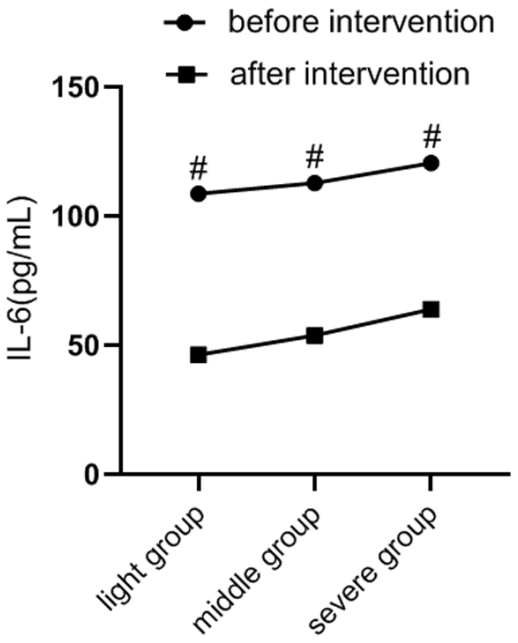

Figure 2. Changes in the IL-6 levels before and after the intervention in the experimental group. #P<0.05.

differences in the sICAM-1 and sVCAM-1 levels between the groups (P<0.05) (**Figure 1**).

Comparison of the changes in the IL-6, IL-1β, and TNF-α levels in the experimental group with varying degrees of CP

Before the intervention, the differences in the IL-6, IL-1β, and TNF-α levels among the patients with different degrees of chronic periodontitis in the experimental group were significant (P<0.05), and the IL-6, IL-1β, and TNF-α levels increased with the increasing severity of the periodontitis. After the intervention, these indicators in the mild, moderate, and severe groups decreased significantly (P<0.05) (**Figures 2**-**4**).

Comparison of changes in the sICAM-1 and sVCAM-1 levels in the experimental group with varying degrees of CP

Before intervention, the sICAM-1 and sVCAM-1 levels in the patients with different degrees of CP in the experimental group differed significantly (P<0.05), and these indicators increased as the periodontitis conditions worsened. After the intervention, the sICAM-1 and sVCAM-1 levels in the mild, moderate, and severe groups decreased significantly (P<0.05) (**Figure 5**).

Discussion

Due to unhealthy living habits, teeth are vulnerable to external stimuli, leading to an increased incidence of oral diseases, more than 80% of which are CP [17]. With the development of chronic inflammation, the body's ability to eliminate pathogenic bacteria decreases, leading to the formation of more plaque and plaque microorganisms, and the number of bacteria contained in the periodontal pockets of patients with CP has been reported to be approximately 10^8. The persistence of dental plaque triggers the release of the inflammatory factors and increases the inflammatory response

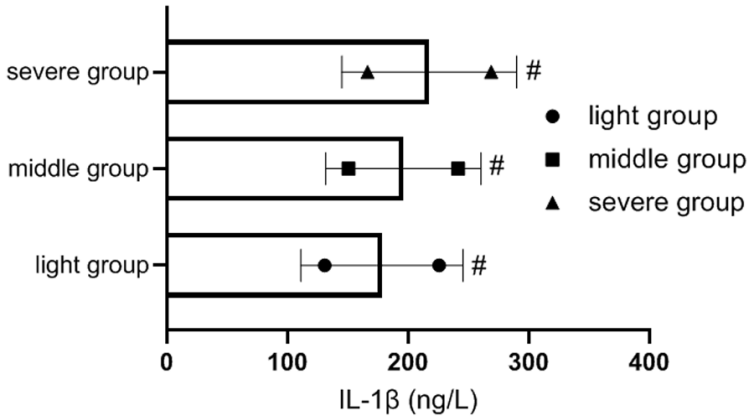

Figure 3. Changes in the IL-1β levels before and after the intervention in the experimental group. #P<0.05.

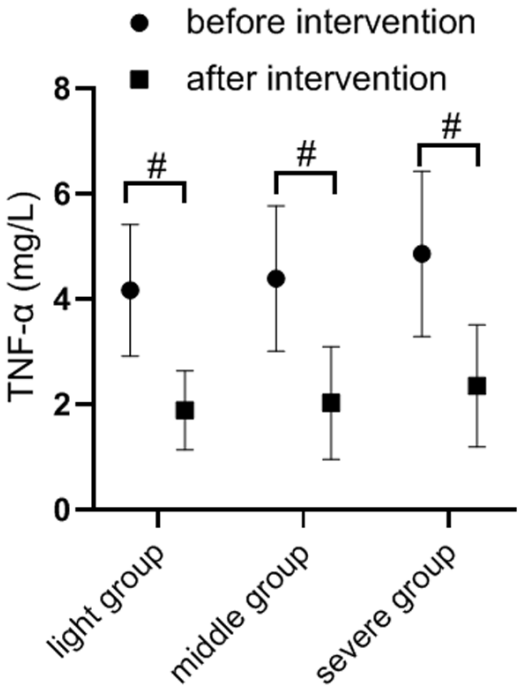

Figure 4. Changes in the TNF-α levels before and after the intervention in the experimental group. #*P*<0.05.

[18, 19]. Meanwhile, as the inflammatory factor levels increase, the risk of developing diseases such as heart disease and diabetes is also elevated.

The inflammatory factors work together with the adhesion factors to cause a persistent inflammatory response in the periodontal tissues. When a patient's IL-6, IL-1β, and TNF-α levels are increased, more inflammatory cells will accumulate at the site of the inflammation, thus contributing to the continuation of the inflammatory response [20-22]. Cell-to-cell adhesion is a prerequisite for immunity. sICAM-1 and sVCAM-1 work together to promote the adhesion of inflammatory cells such as monocytes and neutrophils to the periodontal tissues where inflammation occurs, thereby increasing the inflammatory response [23].

The main component of minocycline is dimethylamine tetracycline, which has an antibacterial effect by inhibiting the protein synthesis of periodontal pathogens. Minocycline ointment, when combined with water, forms a reticulated membrane, so the minocycline ointment is slowly released in the periodontal pocket, maintaining the desired concentration for a week and improving the therapeutic effect [24, 25].

The results of this study showed that minocycline can alleviate the disease condition by reducing the levels of the inflammatory factors IL-6, IL-1β, TNF-α and the adhesion factors sICAM-1 and sVCAM-1 in the GCF. We also found that minocycline can play a positive role in the treatment of patients with varying degrees of CP, but as the disease worsens, the IL-1β, TNF-α, and sICAM-1 and sVCAM-1 levels are still at high levels in moderate and severe patients, so minocycline intervention should be administered as early as possible to prevent disease progression.

Currently, mechanical therapy, such as removing plaque and the surrounding lesions, is commonly administered. Although it can achieve a certain therapeutic effect, it cannot deal with the deeper parts of the periodontal pockets, leading to a poor prognosis. In recent years, scholars have recommended the application of minocycline ointment in the adjuvant treatment of patients with CP, which, when denatured by water, can release its active ingredients slowly and maintain its effective concentration for a week, and it also has low side effects [26-28]. Lu et al. found that minocycline ointment assists subgingival scaling/root planing and can reduce PD, CAL, the gingival

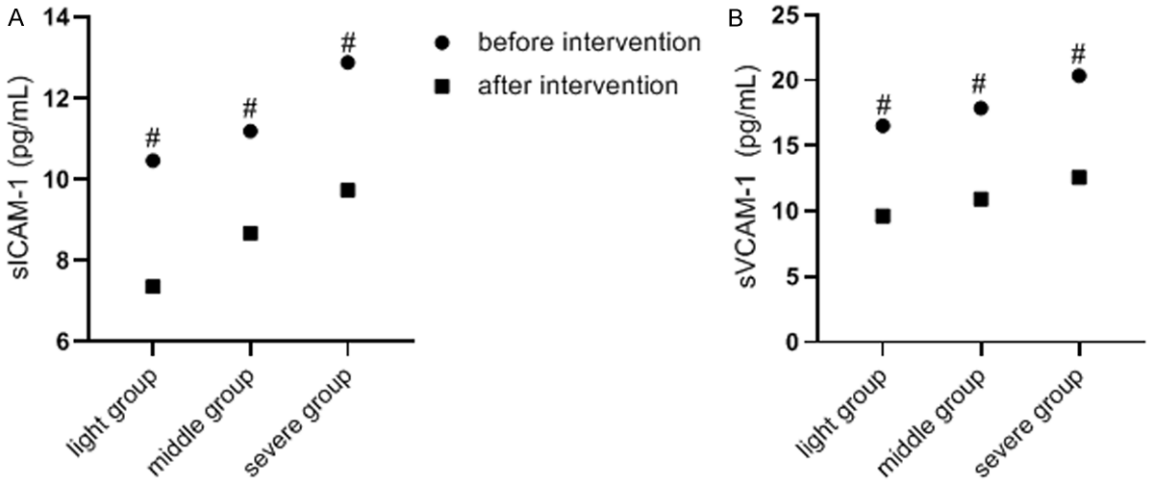

Figure 5. The sICAM-1 and sVCAM-1 levels before and after the intervention in the experimental group. #*P*<0.05.

index, and the interleukin-1β levels compared with scaling/root planing alone [29]. In the study of Basegmez et al., after 1, 3, and 6 months of intervention, the PLI, the sulci bleeding index, the PD and the relative attachment levels were measured, and gingival sulci samples were obtained for testing, demonstrating that minocycline showed clinical benefits in periodontal treatment and provided further improvement in the inflammatory mediators that promise to achieve host regulation [30].

In summary, minocycline can reduce the IL-6, IL-1β, TNF-α, sICAM-1, sVCAM-1 levels, thereby alleviating chronic periodontitis. The shortcomings of the present study are as follows: (1) The small sample size and the geographic location of the study made the results less generalizable. (2) Only three inflammatory factors and two adhesion factors were explored, so the results obtained were biased. In view of the above shortcomings, the next step is to carry out an in-depth study with a large sample size.

Disclosure of conflict of interest

None.

Address correspondence to: Jinhua Zhao, Department of Stomatology, Changzhou TCM Hospital, No. 25, Heping North Road, Tianning District, Changzhou, Jiangsu, China. Tel: +86-13585110979; E-mail: zhaojinhuaa@126.com

References

[1] Wellapuli N and Ekanayake L. Association between chronic periodontitis and oral health-related quality of life in Sri Lankan adults. Int Dent J 2016; 66: 337-343.

[2] Song JY, Kim HH, Cho EJ and Kim TY. The relationship between gastroesophageal reflux disease and chronic periodontitis. Gut Liver 2014; 8: 35-40.

[3] Arowojolu MO, Oladapo O, Opeodu OI and Nwhator SO. An evaluation of the possible relationship between chronic periodontitis and hypertension. J West Afr Coll Surg 2016; 6: 20-38.

[4] Sakalauskiene J, Kubilius R, Gleiznys A, Vitkauskiene A, Ivanauskiene E and Šaferis V. Relationship of clinical and microbiological variables in patients with type 1 diabetes mellitus and periodontitis. Med Sci Monit 2014; 20: 1871-1877.

[5] Ababneh KT, Al Shaar MB and Taani DQ. Depressive symptoms in relation to periodontal health in a Jordanian sample. Int J Dent Hyg 2010; 8: 16-21.

[6] Balli U, Ongoz Dede F, Bozkurt Dogan S, Gulsoy Z and Sertoglu E. Chemerin and interleukin-6 levels in obese individuals following periodontal treatment. Oral Dis 2016; 22: 673-680.

[7] Placzek M and Briscoe J. Sonic hedgehog in vertebrate neural tube development. Int J Dev Biol 2018; 62: 225-234.

[8] Wang W, Gu J, Shang J and Wang K. Correlation analysis on central lymph node metastasis in 276 patients with cN0 papillary thyroid carcinoma. Int J Clin Exp Pathol 2013; 6: 510-515.

[9] Tonetti MS, Greenwell H and Kornman KS. Staging and grading of periodontitis: framework and proposal of a new classification and case definition. J Periodontol 2018; 89 Suppl 1: S159-S172.

[10] Geisinger ML, Michalowicz BS, Hou W, Schoenfeld E, Gelato M, Engebretson SP, Reddy MS

and Hyman L. Systemic inflammatory biomarkers and their association with periodontal and diabetes-related factors in the diabetes and periodontal therapy trial, a randomized controlled trial. J Periodontol 2016; 87: 900-913.
[11] Roberts HM, Ling MR, Insall R, Kalna G, Spengler J, Grant MM and Chapple IL. Impaired neutrophil directional chemotactic accuracy in chronic periodontitis patients. J Clin Periodontol 2015; 42: 1-11.
[12] Algate K, Haynes DR, Bartold PM, Crotti TN and Cantley MD. The effects of tumour necrosis factor-α on bone cells involved in periodontal alveolar bone loss; osteoclasts, osteoblasts and osteocytes. J Periodontal Res 2016; 51: 549-566.
[13] Banu S, Jabir NR, Mohan R, Manjunath NC, Kamal MA, Kumar KR, Zaidi SK, Khan MS and Tabrez S. Correlation of Toll-like receptor 4, interleukin-18, transaminases, and uric acid in patients with chronic periodontitis and healthy adults. J Periodontol 2015; 86: 431-439.
[14] Erdemir EO, Hendek MK, Keceli HG and Apan TZ. Crevicular fluid levels of interleukin-8, interleukin-17 and soluble intercellular adhesion molecule-1 after regenerative periodontal therapy. Eur J Dent 2015; 9: 60-65.
[15] Wang L, Li XH and Ning WC. Evaluation of ICAM-1 and VCAM-1 gene polymorphisms in patients with periodontal disease. Med Sci Monit 2016; 22: 2386-2391.
[16] Turgut Çankaya Z, Bodur A, Taçoy G, Ergüder I, Aktuna D and Çengel A. The effect of periodontal therapy on neopterin and vascular cell adhesion molecule-1 levels in chronic periodontitis patients with and without acute myocardial infarction: a case-control study. J Appl Oral Sci 2018; 26: e20170199.
[17] Sima C, Aboodi GM, Lakschevitz FS, Sun C, Goldberg MB and Glogauer M. Nuclear factor erythroid 2-related factor 2 down-regulation in oral neutrophils is associated with periodontal oxidative damage and severe chronic periodontitis. Am J Pathol 2016; 186: 1417-1426.
[18] Dutzan N, Konkel JE, Greenwell-Wild T and Moutsopoulos NM. Characterization of the human immune cell network at the gingival barrier. Mucosal Immunol 2016; 9: 1163-1172.
[19] Ge X, Liu YF, Wong Y, Wu LZ, Tan L, Liu F and Wang XJ. Impact of nicotine on the interplay between human periodontal ligament cells and CD4+ T cells. Hum Exp Toxicol 2016; 35: 983-990.
[20] Meenawat A, Govila V, Goel S, Verma S, Punn K, Srivastava V and Dolas RS. Evaluation of the effect of nicotine and metabolites on the periodontal status and the mRNA expression of interleukin-1β in smokers with chronic periodontitis. J Indian Soc Periodontol 2015; 19: 381-387.
[21] Pandey V, Salam SA, Moda A, Agarwal P, Nath S and Pulikkotil SJ. Effect of the use of snuff on the levels of interleukin-1β and interleukin-8 in the gingival crevicular fluid of periodontitis patients. Dent Res J (Isfahan) 2015; 12: 461-468.
[22] Lütfioğlu M, Aydoğdu A, Sakallioğlu EE, Alaçam H and Pamuk F. Gingival crevicular fluid interleukin-8 and lipoxin A4 levels of smokers and nonsmokers with different periodontal status: a cross-sectional study. J Periodontal Res 2016; 51: 471-480.
[23] Joe BH, Borke JL, Keskintepe M, Hanes PJ, Mailhot JM and Singh BB. Interleukin-1beta regulation of adhesion molecules on human gingival and periodontal ligament fibroblasts. J Periodontol 2001; 72: 865-870.
[24] Abbas S, Mahendra J and Ari G. Minocycline ointment as a local drug delivery in the treatment of generalized chronic periodontitis - a clinical study. J Clin Diagn Res 2016; 10: Zc15-19.
[25] Soeroso Y, Akase T, Sunarto H, Kemal Y, Salim R, Octavia M, Viandita A, Setiawan J and Bachtiar BM. The risk reduction of recurrent periodontal pathogens of local application minocycline HCl 2% gel, used as an adjunct to scaling and root planing for chronic periodontitis treatment. Ther Clin Risk Manag 2017; 13: 307-314.
[26] Chackartchi T, Hamzani Y, Shapira L and Polak D. Effect of subgingival mechanical debridement and local delivery of chlorhexidine gluconate chip or minocycline hydrochloride microspheres in patients enrolled in supportive periodontal therapy: a retrospective analysis. Oral Health Prev Dent 2019; 17: 167-171.
[27] Jhinger N, Kapoor D and Jain R. Comparison of Periochip (chlorhexidine gluconate 2.5 mg) and Arestin (Minocycline hydrochloride 1 mg) in the management of chronic periodontitis. Indian J Dent 2015; 6: 20-26.
[28] Jain R, Mohamed F and Hemalatha M. Minocycline containing local drug delivery system in the management of chronic periodontitis: a randomized controlled trial. J Indian Soc Periodontol 2012; 16: 179-183.
[29] Lu HK and Chei CJ. Efficacy of subgingivally applied minocycline in the treatment of chronic periodontitis. J Periodontal Res 2005; 40: 20-27.
[30] Basegmez C, Berber L and Yalcin F. Clinical and biochemical efficacy of minocycline in nonsurgical periodontal therapy: a randomized controlled pilot study. J Clin Pharmacol 2011; 51: 915-922.