

Case Report

Efficacy of pingyangmycin injection for the treatment of cervical epidermoid cysts

Ling Zhang¹, Jing Zheng², Hua-Ming Mai¹, Ling Zhu¹, Lei Zhang¹, Jia-Wei Zheng^{*1}

¹Department of Oral and Maxillofacial Surgery, Ninth People's Hospital, College of Stomatology, Shanghai Jiao Tong University School of Medicine, Shanghai 200011, China; ²Laboratory of Molecular Neuropharmacology, School of Pharmacy East China University of Science and Technology 130 Meilong Road, Shanghai, 200237, P.R. China

Received July 24, 2012; accepted September 10, 2012; Epub November 18, 2012; Published January 1, 2013

Abstract: Epidermoid cysts are benign lesions commonly seen in the head and neck region. Here, we describe the case of an epidermoid cyst in a 20-year-old man with a history of trauma presenting with a complaint of mass in the right cervical region. Upon closer examination, a 3cm long scar was noticed within the swollen region of the right sub-mandibular area. MRI revealed a soft tissue mass involving the right neck and fine-needle aspiration biopsy showed that the content of the cyst was homogenous, confirming the diagnosis of epidermoid cyst. We used a pingyangmycin injection to manage the cyst with excellent short-term results, but the lesion reappeared after 3 months. The patient ultimately underwent surgical enucleation of the mass under general anesthesia.

Keywords: Pingyangmycin injection, epidermoid cyst

Introduction

Epidermoid cysts are benign developmental cystic malformations which represent 1.6% to 6.9% of all cysts in the head and neck area [1]. Within these regions, common sites include the floor of the mouth, cheeks and submandibular spaces. Epidermoid cysts consist of an epithelial-lined wall that may be partly keratinized, with no evidence of skin appendages [2]. They generally present with slow and progressive growth over a long period of time, and can be either congenital or acquired. The latter are typically associated with a history of trauma and are most likely the result of either accidental or iatrogenic inclusion of epithelial cells [3]. In general, epidermoid cysts appear as painless, asymptomatic masses, and are diagnosed in the second or third decade of life [4]. The traditional management option for these types of cysts is surgical therapy [5]. In the current report, we investigated the effectiveness of pingyangmycin injections for the treatment of a cervical epidermoid cyst in a young Chinese male.

Case presentation

A 20-year-old male patient presented with right

cervical swelling (**Figure 1**), which was initially small but had increased in size over the past 8 months. The young man had a history of trauma and on examination a 3cm long scar was noticed within the swollen region of the right sub-mandibular area. Fine-needle aspiration biopsy revealed the presence of a coffee-like cystic liquid, and magnetic resonance imaging (MRI) identified a soft tissue mass involving the right neck, 35mm×30mm in size. The mass had a low signal with T1-weighted and a high signal with T2-weighted enhancement (**Figure 2**). A diagnosis of epidermoid cyst was made based on clinical examination, as well as on aspiration and MRI findings. Complete excision of the lesion was proposed to the patient, but he rejected the suggestion due to concerns about a large surgical scar. An injection of pingyangmycin was suggested as an alternative therapy and performed with informed consent from the patient. The cystic liquid was first aspirated as much as possible with a syringe (**Figure 3**), after which 4ml of 2mg/ml pingyangmycin aqueous solution was injected directly into the cyst. Three weeks after the injection, the cystic mass had partially disappeared. Unfortunately, the mass reappeared 3 months later in the same region, at which point the patient underwent

Pingyangmycin for treatment of cervical epidermoid cysts

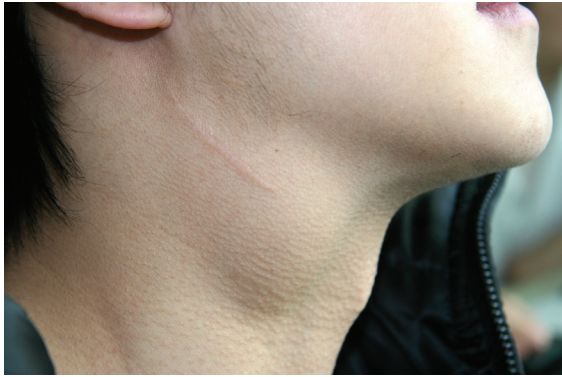

Figure 1. A 20 year-old man presented with submandibular swelling on the right side of the neck. A 3cm long scar was found on the skin within the swollen area.

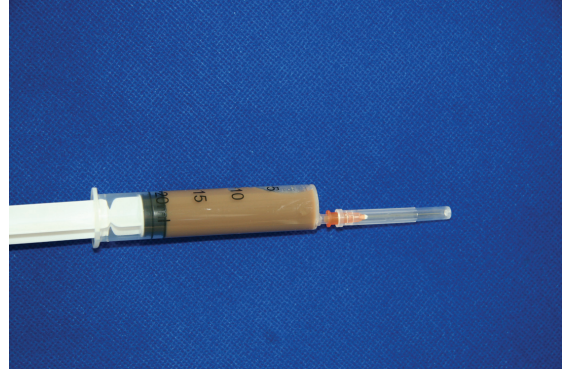


Figure 3. The cystic liquid was easily aspirated with a syringe.

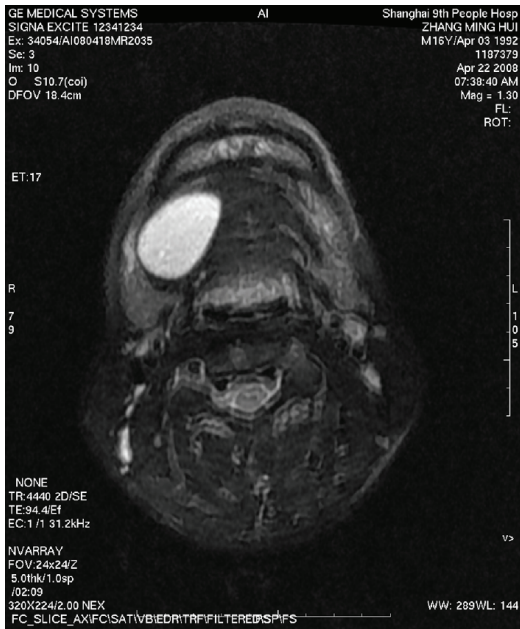

Figure 2. T2-weighted MRI scan showing a high 35mm×30 mm signal in the submandibular area.

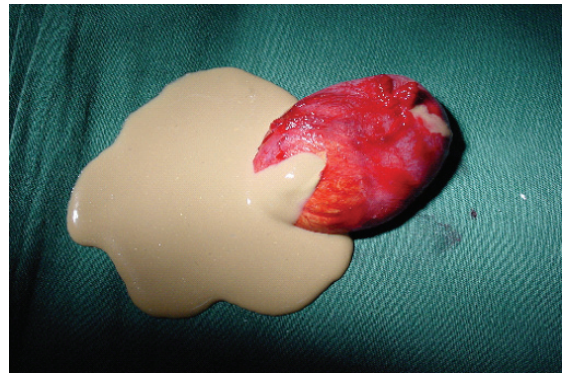

Figure 4. The mass contained a thick, greasy-looking substance.

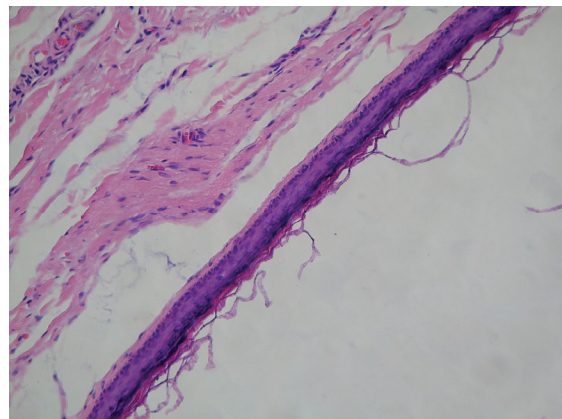


Figure 5. Keratinized stratified squamous epithelium and basophilic dot-like staining of the stratum granulosum was seen (HE ×200).

surgical excision under general anaesthesia. The mass contained a thick, greasy-looking substance (**Figure 4**) and histological examination revealed an acidophilic stratum corneum (**Figure 5**).

Discussion

To date, surgical enucleation has been the only effective therapy for the management of epidermoid cysts [6]. In the present case study, we

used a pingyangmycin injection to treat an epidermoid cyst, with good short-term results. Pin-

gyangmycin is an antibiotic compound that was isolated from a bacterial *Streptomyces* strain identified in soil from Pingyang County in the eastern Chinese province of Zhejiang. It is commonly used as an anti-cancer drug and has also been used as a sclerosant for the treatment of vascular anomalies, producing good results with minimal side effects [7]. Studies have shown that pingyangmycin is highly effective for the treatment of cyst-like lesions [8], particularly in the case of venous and lymphatic malformations [9]. Pingyangmycin can impair cell cycle progression and induce DNA degradation [10]. It can also cause damage to the cystic endothelium; after pingyangmycin administration, endothelial cells appear swollen, vacuolated and necrotic, with the cystic cavity narrowing and ultimately becoming completely occluded [11]. Unlike surgery, sclerotherapy is a simple, non-invasive procedure that can be performed without risk of injury to important adjacent structures. In the present case study, the short-term results of sclerotherapy with pingyangmycin were promising, but ultimately the cyst recurred. We propose two possible explanations for this recurrence: the first is that since epidermoid cysts consist of a thick, stratified squamous epithelial-lined wall that may be keratinized, the pingyangmycin solution was not strong enough to effectively destroy it. Another explanation is that multiple injections sessions may be necessary to achieve a curative effect, as opposed to the single injection that was used here. Therefore, the value of pingyangmycin injections for the treatment of epidermoid cysts remains to be determined.

Authors' contributions

ZL, ZJ, MH, ZL and ZL drafted the manuscript and designed the case report. All authors read and approved the final manuscript.

Acknowledgements

Written informed patient consent was obtained for publication.

Address correspondence to: Dr. Jia-Wei Zheng, Department of Oral and Maxillofacial Surgery, Ninth People's Hospital, College of Stomatology, Shanghai Jiao Tong University School of Medicine, Shanghai 200011, China. Tel: 0086-21 23271063; Fax: 0086-21 63121780; E-mail: davidzhengjw@sjtu.edu.cn

References

- [1] De Ponte FS, Brunelli A, Marchetti E, Bottini DJ. Sublingual epidermoid cyst. *J Craniofac Surg* 2002; 13: 308-310.
- [2] Fathke C, Wilson L, Shah K, Kim B, Hocking A, Moon R, Isik F. Wnt signaling induces epithelial differentiation during cutaneous wound healing. *BMC Cell Biol* 2006; 20: 114-117.
- [3] White AK, Jenkins HA, Coker NJ. Intradiploic epidermoid cyst of the sphenoid wing. *Arch Otolaryngol Head Neck Surg* 1987; 113: 995-999.
- [4] Shim WH, Jwa SW, Song M, Kim HS, Ko HC, Kim BS, Kim MB. Cutaneous metaplastic synovial cyst of the cheek generated by repetitive minor trauma. *Ann Dermatol* 2011; 23: 235-238.
- [5] Smirniotopoulos JG, Chiechi MV. Teratomas, dermoids, and epidermoids of the head and neck. *Radiographics* 1995; 15: 1437-1455.
- [6] Zuber TJ. Minimal Excision Technique for Epidermoid (Sebaceous) Cysts. *Am Fam Physician* 2002; 65: 1409-1412.
- [7] Boardman SJ, Cochrane LA, Roebuck D, Elliott MJ, Hartley BE. Multimodality Treatment of Pediatric Lymphatic Malformations of the Head and Neck Using Surgery and Sclerotherapy. *Arch Otolaryngol Head Neck Surg* 2010; 136: 270-276.
- [8] Mai HM, Zheng JW, Zhou Q, Yang XJ, Wang YA, Fan XD. Intralesional injection of pingyangmycin is a safe and effective treatment for microcystic lymphatic malformations in the tongue. *Phlebology* 2012. [Epub ahead of print]
- [9] Gao Q, Wang C, Wen Y. A study of the effects of pingyangmycin injection on the treatment of lymphangiomas in oral, maxillofacial and cervical regions. *Hua Xi Kou Qiang Yi Xue Za Zhi* 2002; 20: 184-186.
- [10] Gao QH, Zheng GJ, Wang CG, Zhou L, Wen YM, Wang CM, Hou SX. An experimental study on the preparation and drug sustained release characteristics of pingyangmycin albumin microspheres. *Hua Xi Kou Qiang Yi Xue Za Zhi* 2005; 23: 69-71.
- [11] Zheng JW, Yang XJ, Wang YA, He Y, Ye WM, Zhang ZY. Intralesional injection of Pingyangmycin for vascular malformations in oral and maxillofacial regions: an evaluation of 297 consecutive patients. *Oral Oncol* 2009; 45: 872-876.