

Review Article

A practical guide to treatment of infantile hemangiomas of the head and neck

Jia Wei Zheng¹, Ling Zhang¹, Qin Zhou¹, Hua Ming Mai², Yan An Wang¹, Xin Dong Fan³, Zhong Ping Qin⁴, Xu Kai Wang⁵, Yi Fang Zhao⁶

¹Department of Oral and Maxillofacial Surgery, Ninth People's Hospital, College of Stomatology, Shanghai Jiao Tong University School of Medicine, No. 639, Zhi Zao Ju Road, Shanghai 200011, China; ²Department of Oral and Maxillofacial Surgery, School of Stomatology, Guangxi Medical University, No. 10, Shuang Yong Road, Nanning 530021, Guangxi Province, China; ³Department of Radiology, Ninth People's Hospital, Shanghai Jiao Tong University School of Medicine, No. 639, Zhi Zao Ju Road, Shanghai 200011, China; ⁴Special Department of Hemangioma, Tumor Hospital of Linyi City, No. 6, Lingyuan East Street, Linyi 276001, Shandong Province, China; ⁵Department of Oral and Maxillofacial Surgery, School of Stomatology, China Medical University, No. 143, North Nanjing Road, Heping District, Shenyang 110002, Liaoning Province, China; ⁶Department of Oral and Maxillofacial Surgery, School of Stomatology, Wuhan University, No. 237, Luo Yu Road, Wuhan 430079, Hubei Province, China

Received September 11, 2013; Accepted October 22, 2013; Epub October 25, 2013; Published October 30, 2013

Abstract: Infantile hemangiomas are the most common benign vascular tumors in infancy and childhood. As hemangioma could regress spontaneously, it generally does not require treatment unless proliferation interferes with normal function or gives rise to risk of serious disfigurement and complications unlikely to resolve without treatment. Various methods for treating infant hemangiomas have been documented, including wait and see policy, laser therapy, drug therapy, sclerotherapy, radiotherapy, surgery and so on, but none of these therapies can be used for all hemangiomas. To obtain the best treatment outcomes, the treatment protocol should be individualized and comprehensive as well as sequential. Based on published literature and clinical experiences, we established a treatment guideline in order to provide criteria for the management of head and neck hemangiomas. This protocol will be renewed and updated to include and reflect any cutting-edge medical knowledge, and provide the newest treatment modalities which will benefit our patients.

Keywords: Hemangiomas, treatment, head and neck, sclerotherapy, drug therapy

Introduction

Hemangiomas are the most common benign tumor in infancy. Their prevalence has been estimated as 2%-3% in the neonates, 10% under age 1 year and up to 22%-30% in pre-term babies weighing less than 1000 g [1]. Hemangioma can be found in all regions of the body, but they occur most commonly in the head and neck region (60%), followed by the trunk (25%) and then the extremities (15%). Hemangiomas are more frequent in girls than boys, ranging from a 3:1 to 5:1 ratio. The etiology of hemangiomas remains unknown. It is reported that childbearing age, gestational hypertension and infant birth weight may be related to the formation of hemangioma [2-4]. Much of the previous confusion surrounding

vascular lesions was related to the classification systems used to categorize these lesions. In 1982, Mulliken and Glowacki [5] categorized vascular birthmarks into 2 main categories: hemangiomas and vascular malformations. Depending on the depth of the lesion, the simple clinical classification system by Waner and Suen [6] was used to note which hemangiomas were in either the superficial hemangioma (located in the papillary dermis), the deep-seated hemangioma (located in the reticular dermis or subcutaneous tissue), and the compound type (with both superficial and deep hemangioma characteristics).

Hemangioma is characterized by endothelial cell proliferation and the natural course can be divided into: rapid proliferating phase (0-1 yr),

involuting phase (1-5 yr) and the involuted phase (5-10 yr) [7]. With spontaneous regression of hemangiomas, the choice of treatment is still controversial. Through follow-up studies on 159 cases with involuting hemangiomas, Finn et al [8] discovered that 81% of cases could achieve “perfect” effect when regression occurred before 6 years. Thus, many physicians emphasize an approach of careful observation but not active treatment. These hemangiomas are usually not life-threatening or function-impairing, but various psychological problems will emerge due to disfigurement, such as negative self-image evaluation, lack of self-confidence and distress, etc. In fact, approximately 40%-50% of all hemangiomas resolve incompletely, leaving permanent changes in the skin, such as telangiectases, stippled scarring, anetoderma or epidermal atrophy, hypopigmentation and/or redundant skin with fibro-fatty residua etc. A few stubborn, problematic hemangiomas may result in serious disfigurement and dysfunction, and even become life-threatening. In order to not leave disfigurement and psychological sequelae, it is suggested that active treatment should be taken rather than observation. With the advances in modern technology, active treatments not only have definite therapeutic effects, but could also minimize the psychosocial distress caused by the lesions. Current treatment methods of head and neck hemangiomas mainly include drug therapy, laser therapy, and surgery. The treatment plan of hemangiomas should be individual and depend on the primary sites, extent, growing phase of the lesions and techniques available. There is no “gold standard” treatment applicable to all patients, and multidisciplinary management is often needed for best efficacy.

A treatment guideline for hemangiomas and vascular malformations of the head and neck was published in *Head and Neck* in 2009 [9]. The guideline provided guidance for the management of head and neck hemangiomas and vascular malformations. Based on published literature and clinical experiences, we established a treatment guideline to provide a protocol for the management of head and neck hemangiomas. This protocol will be reviewed and updated periodically to include and reflect cutting edge medical knowledge in order to provide the best treatment modalities which will benefit our patients.

Clinical and histopathological features

Hemangiomas may be present at birth, but most develop in the first few weeks after birth. It may manifest as a pale patch, easily neglected, and then grow rapidly. It finally appears as a port wine stain-like lesion. Hemangiomas feature a rapid proliferative phase (1-2 months after birth and 4-5 months after birth) followed by an involutive phase. The proliferation is usually during the first year of life, sometimes continuing to 18 months. If the growth rate of proliferative tumors is faster than that of infant development, then functional and cosmetic problems such as ulceration, nasal obstruction, vision problems and obvious airway obstruction would appear. The involutive phase generally begins around 18 months of age. The earliest sign of regression is the color of the lesion fading from a bright red to a dull red. Then, a gray-white hue develops at the center of the lesion and spreads to the periphery. The tumor is then becoming soft in texture followed by a reduction in the volume. Finally, obvious fibrous tissue and adipose tissue will gradually be deposited around blood vessels, along with the reduction in the number of lumen and the enlargement of the lumen diameter. The speed of change in involutive hemangiomas is unpredictable and considerably variable among individuals, but the involutive rate and degree are relatively consistent. Approximately 50% of hemangiomas will have completely resolved by age 5, with about 70% being completely resolved at age 7. Subsequent improvement may occur in the remaining lesions from age 10 to 12 years. Significant regression of midfacial hemangiomas usually occurs at 2 to 3 years old; otherwise, it cannot be resolved completely and will leave cosmetic problems.

The histologic appearance of hemangiomas fluctuates with the stage of the life cycle of the tumor and can be divided into the proliferative phase and the involutive phase. The proliferative hemangiomas show a proliferation of endothelial cells. The basal lamina is thickened and multilaminar underneath the endothelial cells forms syncytial masses with or without lumens. Light micrographic findings demonstrate a large number of vascular plexus consist of capillaries, venules and small veins. The proliferative endothelial cells are active with hypertrophy and a pale staining nucleus. The nuclei show occasional mitotic figures, and the num-

ber of mast cells is much higher than normal tissue. The involuting phase hemangioma demonstrates diminished cellularity with a flattening of the lining endothelial cells. As the endothelium flattens, there is a relative dilation of the vessels supplying the tumor and progressive deposition of perivascular, intralobular, and interlobular fibrous tissue. The basement cell membrane is still multilaminated and the number of mast cells gradually returns to normal. Complete involuted hemangioma has a “sponge-like” structure, with scattered thin-walled blood vessels lined with flat endothelial cells. The basement membranes remain multilaminated and the number of mast cells returns to normal amounts.

Diagnosis and treatment

In most instances, hemangiomas can be diagnosed based on history and physical examination. A hemangioma generally is not present at birth and grows rapidly in the first few weeks after birth. Superficial hemangiomas usually manifest as bright red macule or papule rashes with clear boundaries. In some cases, especially those with macule-like lesions, difficulties may exist in differentiating hemangiomas from port-wine stains. Patients should be observed for several days or weeks to see if the size has changed. The color of proliferative hemangiomas may deepen with time. The onset of involution is usually heralded by a change in color from bright red to dull purple, and finally in spotted pigment. Deep hemangiomas involve the deep dermis and subcutis, and the color of skin may depend on the depth of tumors as skin-colored to blue-violet nodules. Sometimes, deep hemangiomas may be difficult to distinguish from venous or lymphatic malformations, but accurate diagnosis can be made through a detailed history. If diagnosis is still uncertain, color Doppler ultrasonography and/or MRI may be used to aid in the diagnosis. Compound hemangiomas have both superficial and deep components, and therefore have features of both. Hemangiomas usually have an isointense or hypointense signal on T1 images and are enhanced on T2 imaging. Vascular flow voids and feeding vessel dilation are seen within and around the proliferative lesions on spin echo images. With involution, rich fibrofatty infiltration is demonstrated through high-intensity foci within the tumor on T1 weighted imaging [10-12].

Many treatment modalities are currently available for management of head and neck hemangiomas, including careful observation, drug therapy, laser therapy and surgery. Surgical excision of hemangiomas is no longer the treatment of first choice today, except for a few cases involving eyelid or huge scalp hemangiomas. Cryosurgery has rarely been used in the treatment of facial and cervical hemangiomas owing to its uncertain efficacy and possibility of scarring or pigmentation. Radioisotope therapy has good efficacy for superficial hemangiomas. However, it's often concurrent with skin atrophy, contracture, hyperpigmentation, hypopigmentation or hair loss etc. so care has to be taken during application on the face for aesthetic reasons.

Choice of treatment methods

The treatment of hemangiomas is dependent on the various stages of growth. The treatment principles of hemangiomas are summarized as follows [9]: (1) Small isolated or multiple skin lesions on the face found after birth should be treated as soon as possible in order to prevent its progress into the proliferative phase; (2) Proliferative hemangiomas should be treated step by step, including systematic drug therapy (oral propranolol, oral prednisone, topical use of imiquimod, subcutaneous injection of interferon α -2a or 2b) → laser therapy (argon laser, pulsed dye laser and Nd:YAG laser, semiconductor laser etc.) → sclerotherapy (intratumoral injection of steroids, pinyangmycin, interferon α). For deep or large hemangiomas, a comprehensive approach must be taken into consideration, e.g. drug therapy combined with laser therapy. (3) Close observation is indictable for involutive hemangiomas. Surgical excision should be taken for residual lesions, scar, hypertrophy, or pigmentation. (4) For residual lesions of involuted hemangiomas, surgical trimming or laser treatment is feasible. The treatment of hemangiomas should be considered cautiously and with consultation of the child's parents.

Wait and see

“Wait and see” is mainly indicated in involuting hemangiomas or small, stable hemangiomas in non-vital sites, without significant impacts on appearance and function. The growth of the lesions should be observed, recorded and pho-

Treatment guidelines of infantile hemangiomas

tographed in the follow-up period. Treatment should immediately be taken when the following occurs: (1) fast growth of hemangioma; (2) hemorrhage, infection or ulceration complicated with huge hemangioma; (3) functional problems, such as dysfunction of feeding, breathing, swallowing, hearing, vision, excretion or sports etc.; (4) it's associated with Kasabach-Merritt syndrome; (5) it's concurrent with high output congestive heart failure; (6) it involves facial vital structures, e.g. eyelids, nose, lips, auricle etc.

Cryotherapy

CO₂ rime and liquid nitrogen used to be applied in treatment of superficial hemangiomas with some effects in 1960s. Cellular damage during freezing is the product of strong lower temperatures condensing hemangiomas and tissue around tumors. Intra and extracellular ice crystals form immediately after cryotherapy, which mechanically breaks down the cellular membrane. Upon thawing, extracellular fluid shifts back into the intracellular space, causing cells to burst. Then the hemangioma disappears after the reparative process of the body. It is seldom utilized today due to complications of cold urticaria, cryoprecipitate fibrinogen and cryoglobulinemia etc. In addition, the extremely low temperature of liquid nitrogen easily leads to complications such as proliferative or atrophic scars, hyperpigmentation or hypopigmentation, milia, tissue contracture and so on [13]. Moderate cryosurgery (-32°C) has also been described recently to reduce the scarring and pigmentation, while the efficacy needs further study to be confirmed [14].

Laser therapy

Laser therapies treat hemangiomas by acting on intravascular oxyhemoglobin, resulting in vascular injury. There are several types of lasers available for management of hemangiomas, including argon laser, pulsed dye laser and Nd:YAG laser, etc [15]. Laser therapy is indictable for treatment of early, superficial hemangiomas or the superficial portion of the compound hemangiomas because of the limited penetration depth less than 5 mm, it is not suitable for management of deep-seated hemangiomas. If the lesions continue to enlarge during laser therapy, supplementary pharmacotherapy (propranolol, corticosteroids or inter-

feron α) should be considered. The advantage of laser therapy is the simplicity of use, which can be repeated at an interval of 2 to 4 weeks. The choice of laser therapy should be based on the location, size, and depth of the lesions.

Argon laser: The argon laser has a relatively short wavelength (488-514 nm), and is primarily used to treat various vascular birthmarks. It is characterized by an unselective thermal destruction of blood vessels to achieve curative effect. So it is easy to damage the adjacent normal tissues resulting in scarring and pigmentation etc. About 40% of infantile hemangiomas may be accompanied by hypertrophic scars after argon laser treatment, which has limited its use in clinical practice [16].

Flash lamp-pumped pulsed dye laser (FPDL): Flash lamp-pumped pulsed dye laser has a wavelength of 585 nm or 595 nm, and destroys the blood vessels selectively. It is the only laser that delivers photocoagulation of the targeted vessels while keeping the overlying skin intact. It is thus used to promote regression and inhibit endothelial cell proliferation of superficial hemangiomas, and can also accelerate the regression of involuting hemangiomas. FPDL is often applied with the following settings: pulse duration of 300-450 μ s, spot size of 2-10 mm, energy density of 3-10 J/cm². The laser beam is overlapping and the skin is protected through the cooling system. The energy needs to be decreased in some sensitive areas (e.g. infraorbital skin), as well as easily remodeled areas (e.g. neck and prothorax). Through adjusted wavelengths (585, 590, 595 or 600 nm), prolonged pulse duration (1.5~40 ms) with large spot size and energy of 5~5 J/cm², the depth of penetration is deeper and the damage remains within the blood vessels [15-17].

Immediately after radiation, the treated area turns off-white, with a surrounding erythematous flare, which resolves after 7 to 14 days. After treatment, the treated areas can be smeared with panthenol ointment. In case of blistering or crusting, the patients' parents are instructed to cleanse the area with povidone-iodine solution and prevent accidental injury. The patients are evaluated after 2 to 4 weeks, depending on the degree of response. Repeated treatment may be needed after the first session, often at a 4-week interval [18, 19]. FPDL is the first choice for laser treatment of heman-

Treatment guidelines of infantile hemangiomas

gioma with good efficacy and fewer side effects. The common side effects include atrophic scars, ulcerations, postoperative purpura and transient hyperpigmentation etc [20].

Neodymium:yttrium aluminum garnet (Nd:YAG) laser: Neodymium:yttrium aluminum garnet (Nd:YAG) laser is a kind of solid laser emitting a continuous or pulse type wave of infrared and invisible light with a wavelength of 1064 nm and a penetration depth of 4-6 mm. It can be utilized for deep-seated hemangiomas. Nd:YAG laser could promote the regression of giant hemangiomas through a non-selective thermal damage effect, which also increases the possibility of scar formation. So the possible complications and effect should be assessed before treatment [16].

Nd:YAG laser treatment is very painful and should be performed under local or general anesthesia. There is no clear standard in the operating parameters for continuous Nd:YAG laser treatment of hemangiomas. In general, short exposure time and low energy are for flat lesions, while longer exposure time and higher energy are for thick lesions. The regression extent should be followed up closely after treatment if continuous treatment is necessary.

One to four days after treatment, the lesion becomes swollen and will last 5 days. A blister, or sometimes a scab, may be present, but there is no necessity to incise the blister. The crust of the lesions fall off and the wound heals within 2 to 4 weeks posttreatment. Treatment can be repeated at an interval of every 5 to 8 weeks [16].

Compared with argon laser and FPD, Nd:YAG laser is more suitable for larger and up to 2 cm deep hemangiomas. Percutaneous interstitial irradiation can be used for deep hemangiomas to reduce skin damage and diminish lesions effectively [20]. Laser irradiation can be applied through an endoscopic catheter and fiber transmission for hemangiomas arising from the bronchial tree, gastrointestinal tract and bladder. The laser beam can penetrate into, and scatter within, the deep tissues as an ideal tool in photocoagulation and hemostasis. It can be applied repeatedly with minimal edema and bleeding [21, 22].

The KTP laser belongs to the group of solid state lasers. In fact, it is the 1064 nm Nd:YAG

modified by a crystal of potassium titanyl phosphate to produce a 532 nm wavelength. Since the wavelength is more similar to that of the hemoglobin absorption peak, the incidence of postoperative purpura decreases greatly. Compared with the long wavelength laser, the penetration of the KTP laser is weak. Thus, for deep lesions, a bare fiber can be applied directly into the hemangioma to avoid skin damage. However, epidermal melanin also can be targeted by a 532 nm laser, leading to pigmentation disturbances which will limit its clinical use in people with dark skin [15, 17].

CO₂ lasers play a role in the treatment of hemangiomas by removing of superficial blood vessels. It is rarely used today because of the high incidence of scar formation and poor effects [16].

Drug therapy

Pharmacotherapy is indicated for multiple hemangiomas, rapidly proliferative hemangiomas, and hemangiomas that are affecting vital organs or life threatening. Several drugs have been documented in the literatures including propranolol, corticosteroids, alpha-interferon, anti-cancer drugs (cyclophosphamide, vincristine, pinyangmycin), imiquimod, and etc. Induction of early involution and freedom from the side effects of steroid therapy seem encouraging for using propranolol as a first line treatment modality in the management of troublesome hemangiomas.

Oral corticosteroid: Oral corticosteroids have been used for more than 30 years. They used to be the first-line treatment for severe, multiple hemangiomas, potentially disfiguring hemangiomas or hemangiomas involving vital structures as well as for patients with congestive heart failure, consumptive coagulopathies, and thrombocytopenia prior to the serendipitous discovery and subsequent wide clinical application of propranolol. The initial oral dose of prednisone is 4 mg/kg per day for 7 days. If the tumors stop growing or become smaller, the same dose continues for 3 weeks. Conversely, the dose is increased to 5 mg/kg per day for 7 days, then is tapered down gradually and ceased after 4 to 8 weeks. The prescribed dosage of prednisone or prednisolone in China is 3 to 5 mg/kg every other day rather than per day; given as a single morning dose for 8 weeks. The

Treatment guidelines of infantile hemangiomas

dose is then gradually tapered to 1.5 to 2.5 mg/kg every other day at the 9th week, 10 mg every other day at the 10th week, 5 mg every other day at the 11th week, and discontinued at the 12th week. A second or third course of treatment may be initiated at intervals of 4 to 6 weeks when necessary [23]. Based on our clinical experience, oral prednisone, given on alternate days as a single morning dose, complies with the laws of the human adrenal gland secretion. This could reduce the adverse reactions and the inhibition of hypothalamic-pituitary-adrenal axis. The main side effects of systemic corticosteroids therapy are the Cushingoid face, disturbance of growth, and susceptibility to serious infections. Furthermore, complications also include appetite changes, behavior changes, polyuria, pilosity, thrush and gastrointestinal discomfort. Serious infections, bleeding and adrenal insufficiency were absent. With the increasing use of propranolol for problematic hemangiomas, oral corticosteroids are only reserved for propranolol-resistant or contraindicated candidates.

Intralesional injection of corticosteroids or bleomycin A5 (pingyangmycin in China): Intralesional injection of corticosteroids or pingyangmycin is adaptable to involuting phase hemangioma patients with poor response to oral drug therapy or laser therapy. The overall response rate of local administration is 94.5%. Locally administered corticosteroids have a similar response rate to systemic administration, but with fewer adverse effects [24].

For cutaneous superficial or mucosal hemangiomas, the concentration of pingyangmycin is 1.0 mg/ml and the maximum dose for one injection is 4 mg. For subcutaneous or deep hemangiomas, the concentration of Pingyangmycin is 1.5-2.0 mg/ml and the maximum dose for one injection is 8 mg. Generally, for a diameter of less than 1.5 cm, one injection is enough. Multiple injections (3-5 times) are needed at different sites and points for larger or more extensive lesions and the term of validity is 7-30 days after injection.

α -interferon (IFN- α): Interferon- α is used to treat rapidly growing, life-threatening hemangiomas which have failed to respond to systemic corticosteroids. It is usually used at a dosage of 3 million U/m², given subcutaneously per day

for more than 3 months. The response rate is varied between 80% and 90% [25, 26].

Compared with oral corticosteroid, IFN- α can be used for both proliferative and involutive hemangioma. However, due to the potential severe adverse effects, IFN- α administration should only be considered in patients with massive or life-threatening hemangiomas. The common complications include influenza-like symptoms of fever, somnolence, anorexia, diarrhea or constipation as well as neutropenia and a high level of aminotransferases. Although rare, neurotoxicity is still the main concern in the treatment of hemangiomas with interferon. Epilepsy, spastic diplegia and lower limb disability have been reported after interferon injection. If no clinical effect is noticed after 1 month of administration, interferon- α should be discontinued.

An intralesional injection of IFN- α is also available and the usual dosage is 1-3 million U/m², given intratumorally once a day for the first week; then once a week for 7 weeks. The advantages intralesional injection of IFN- α include a short course, reduced financial cost, good tolerance by patients and free of major complications [27].

Imiquimod: Imiquimod is an imidazole quinoline amines immunomodulatory drug, widely used in the treatment of genital herpes, basal cell carcinoma, squamous cell carcinoma in situ, actinic keratosis and lentigo maligna. Martinez et al [28] first attempted to apply imiquimod topically every other day in treating infantile hemangioma, and achieved ideal efficacy. Its mechanism of enhancing immunity may be through the production of a variety of cytokines, including interferon- α , IL-6 and TNF- α . Recently, Sunamura et al [29] found that the inhibiting tumor growth and anti-angiogenesis effect of IL-12 may play an important role in the imiquimod-induced regression of hemangiomas.

Many authors confirmed the efficacy of 5% imiquimod cream for the treatment of infantile hemangiomas in recent years, especially for small and moderate-sized lesions involving the non-conspicuous regions. It is applied topically once every other day, for a cycle of 3 to 5 months. The advantages are the ease of use, controllability, safety, and lack of local irritation [30, 31].

Treatment guidelines of infantile hemangiomas

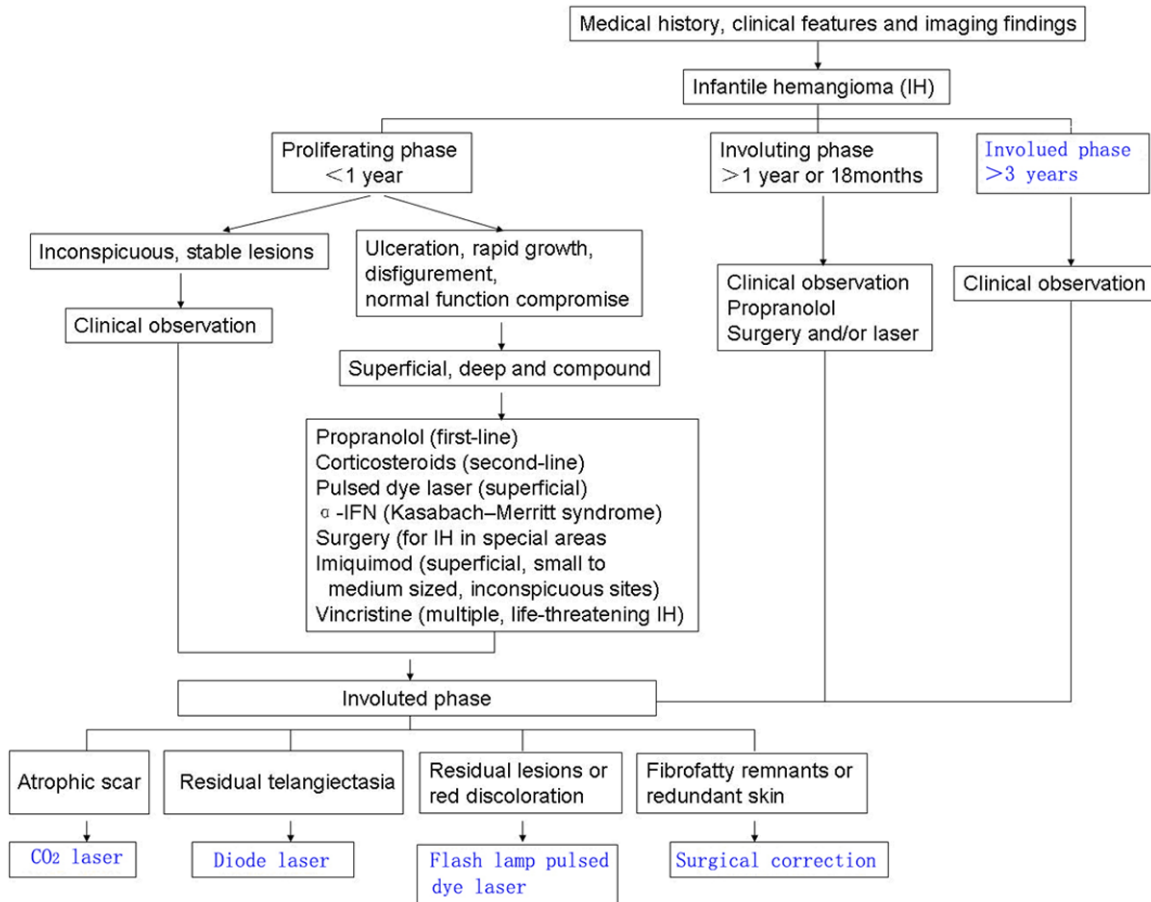


Figure 1. Treatment decision making algorithm for head and neck hemangiomas.

Propranolol: Léauté-Labrèze et al [32] accidentally found that propranolol can effectively control the proliferation of severe hemangioma and promote its regression, which was also confirmed subsequently by other physicians. Propranolol is a nonselective beta-blocker used in treating cardiac arrhythmias, angina and hypertension. The possible mechanisms for treatment of infantile hemangiomas are unclear. The most important advantages of oral propranolol over glucocorticoids and anti-cancer drugs are efficacy and safety, with fewer side effects and low cost. The side effects include: transient bradycardia, hypotension and gastrointestinal discomfort. Propranolol has replaced corticosteroids as first-line therapy for both proliferative and involutive hemangioma. The majority of patients responded within a week of initiating propranolol. No significant adverse effects were reported. A consensus has been reached concerning initiation and use of propranolol for infantile hemangioma

recently [33]. The suggested dosage is 2 mg/kg per day, divided into 2 to 3 doses; the mean treatment duration is 6-8 months; and the time to discontinue propranolol is 12 months of age unless complete resolution occurred earlier, and therapy was tapered off over the last month. Combined low-dose oral propranolol 1.5 mg/kg/day as first-line therapy and oral prednisolone 2 mg/kg/day might be useful in avoiding adverse effects of propranolol in young infants [34]. For facial segmental infantile hemangiomas, a combination of propranolol and pulsed dye laser displayed more rapid and complete clearance and required a lower cumulative propranolol dose to achieve near-complete clearance [35].

Other agents: Anti-cancer drugs (cyclophosphamide and vincristine) have also been used for the treatment of hemangiomas, but the indication should be controlled strictly because of the high toxicity [36, 37].

Treatment guidelines of infantile hemangiomas

Platelet derived growth factor (PDGF) can promote ulcer healing and is often used for ulcerated hemangiomas that are uncontrolled using steroids or laser therapy [38].

Radiation and radioisotope therapy

Radiation and radioisotope therapy uses the γ -ray produced by radioisotope to bombard the nuclei of the lesion area, terminate nucleoprotein synthesis leading to cell death and disintegration.

Radiation therapy is used in cases of serious life or function-threatening hemangiomas, such as those associated with congestive heart failure, acute respiratory distress, or platelet consumption (Kasabach-Merritt syndrome, KMS). The dose of radiation for each time is 2 Gy, and the total dose should be 10 Gy or less to avoid radiation-induced cancer [39]. Radioisotope therapy, such as strontium-90 (^{90}Sr), can be used for treatment of early, superficial proliferative hemangiomas. It is simple and can be implemented in a clinic or ward. Local scar formation or pigment abnormalities may be found after application therapy.

It must be stressed that due to the potential hazards to children and the unclear correlation with long-term tumorigenesis [40], radiotherapy and radioisotope therapy have been gradually replaced by other treatment modalities.

Surgical therapy

Surgical excision of hemangiomas is no longer the first choice treatment. But residual deformities after conservative, or laser, therapy can be corrected surgically in the involuting phase usually after 3.5 years old. The aim of surgery is to remove or re-contour the residual deformity, scar, hypertrophied tissues, hyperpigmentation, or fibrofatty tissues to improve cosmetics and function. The surgical indications for proliferating hemangioma are [9]: (1) hemangiomas located in the tip of nose and lip that do not respond well to other treatments, (2) hemangiomas in the eyelids that impair sight and aesthetics, (3) hemangiomas occurring on the forehead and scalp, and (4) repeated bleeding from the hemangiomas.

In summary, the treatment of hemangiomas should be individualized. Factors affecting the

decision to treat include: size, location, depth, growing stage, and trend of the lesion. A successful regime should be widely adaptable to various types and sizes of hemangiomas. Unfortunately, none of the currently available treatment modalities are refractory to standard therapy. For some patients, single method treatment may achieve perfect effects; while for extensive or multiple hemangiomas, combined treatment is often mandatory. The major principles of management are outlined as follows [41]: (1) preventing or treating life-or function-threatening complications; (2) preventing permanent disfigurement or face defects after hemangioma regression; (3) preventing or adequately treating ulceration to minimize scarring, infection, and pain; (4) minimizing psychosocial stress for patient and family; (5) avoiding over-treatment to lesions which could regress spontaneously with a good prognosis. A flowchart for the treatment of hemangiomas of the head and neck is illustrated in **Figure 1**.

Disclosure of conflict of interest

None.

Address correspondence to: Dr. Jia Wei Zheng, Department of Oral and Maxillofacial Surgery, Ninth People's Hospital, College of Stomatology, Shanghai Jiao Tong University School of Medicine, No. 639, Zhi Zao Ju Road, Shanghai 200011, China. Tel: +86 21 23271063; Fax: +86 21 63121780; E-mail: david-zhengjw@sjtu.edu.cn

References

- [1] Jacobs AH, Walton RG. The incidence of birthmarks in the neonate. *Pediatrics* 1976; 58: 218-222.
- [2] Pratt AG. Birthmarks in infants. *AMA Arch Derm Syphilol* 1953; 67: 302-305.
- [3] Amir J, Metzker A, Krikler R, Reisner SH. Strawberry hemangioma in preterm infants. *Pediatr Dermatol* 1986; 3: 331-332.
- [4] Holmdahl K. Cutaneous hemangiomas in premature and mature infants. *Acta Paediatr* 1955; 44: 370-379.
- [5] Mulliken JB, Glowacki J. Hemangiomas and vascular malformations in infants and children: a classification based on endothelial characteristics. *Plast Reconstr Surg* 1982; 69: 412-422.
- [6] Waner M, Suen JY. Management of congenital vascular lesions of the head and neck. *Oncology* 1995; 9: 989-994, 997.

Treatment guidelines of infantile hemangiomas

- [7] Tan ST, Velickovic M, Ruger BM, Davis PF. Cellular and extracellular markers of hemangioma. *Plast Reconstr Surg* 2000; 106: 529-538.
- [8] Finn MC, Glowacki J, Mulliken JB. Congenital vascular lesions: clinical application of a new classification. *J Pediatr Surg* 1983; 18: 894-900.
- [9] Zheng JW, Zhou Q, Yang XJ, Wang YA, Fan XD, Zhou GY, Zhang ZY, Suen JY. Treatment guideline for hemangiomas and vascular malformations of the head and neck. *Head Neck* 2010; 32: 1088-1098.
- [10] van Rijswijk CS, van der Linden E, van der Woude HJ, van Baalen JM, Bloem JL. Value of dynamic contrast-enhanced MR imaging in diagnosing and classifying peripheral vascular malformations. *AJR Am J Roentgenol* 2002; 178: 1181-1187.
- [11] Baker LL, Dillon WP, Hieshima GB, Dowd CF, Frieden IJ. Hemangiomas and vascular malformations of the head and neck: MR characterization. *AJNR Am J Neuroradiol* 1993; 14: 307-314.
- [12] Chooi WK, Woodhouse N, Coley SC, Griffiths PD. Pediatric head and neck lesions: assessment of vascularity by MR digital subtraction angiography. *AJNR Am J Neuroradiol* 2004; 25: 1251-1255.
- [13] Guidelines of care for cryosurgery. American Academy of Dermatology Committee on Guidelines of Care. *J Am Acad Dermatol* 1994; 31: 648-653.
- [14] Reischle S, Schuller-Petrovic S. Treatment of capillary hemangiomas of early childhood with a new method of cryosurgery. *J Am Acad Dermatol* 2000; 42: 809-813.
- [15] Tanzi EL, Lupton JR, Alster TS. Lasers in dermatology: four decades of progress. *J Am Acad Dermatol* 2003; 49: 1-31; quiz 31-34.
- [16] Al Buainian H, Verhaeghe E, Dierckxsens L, Naeyaert JM. Early treatment of hemangiomas with lasers. A review. *Dermatology* 2003; 206: 370-373.
- [17] Stier MF, Glick SA, Hirsch RJ. Laser treatment of pediatric vascular lesions: Port wine stains and hemangiomas. *J Am Acad Dermatol* 2008; 58: 261-285.
- [18] Witman PM, Wagner AM, Scherer K, Waner M, Frieden IJ. Complications following pulsed dye laser treatment of superficial hemangiomas. *Lasers Surg Med* 2006; 38: 116-123.
- [19] Levine VJ, Geronemus RG. Adverse effects associated with the 577- and 585-nanometer pulsed dye laser in the treatment of cutaneous vascular lesions: a study of 500 patients. *J Am Acad Dermatol* 1995; 32: 613-617.
- [20] Ulrich H, Bäumlner W, Hohenleutner U, Landthaler M. Neodymium-YAG Laser for hemangiomas and vascular malformations – long term results. *J Dtsch Dermatol Ges* 2005; 3: 436-440.
- [21] Cholewa D, Waldschmidt J. Laser treatment of hemangiomas of the larynx and trachea. *Lasers Surg Med* 1998; 23: 221-232.
- [22] Kato M, Chiba Y, Sakai K, Orikasa S. Endoscopic neodymium:yttrium aluminium garnet (Nd:YAG) laser irradiation of a bladder hemangioma associated with Klippel-Weber syndrome. *Int J Urol* 2000; 7: 145-148.
- [23] Frieden IJ, Haggstrom AN, Drolet BA, Mancini AJ, Friedlander SF, Boon L, Chamlin SL, Basella E, Garzon MC, Nopper AJ, Siegel DH, Mathes EW, Goddard DS, Bischoff J, North PE, Esterly NB. Infantile hemangiomas: current knowledge, future directions. Proceedings of a research workshop on infantile hemangiomas, April 7-9, 2005, Bethesda, Maryland, USA. *Pediatr Dermatol* 2005; 22: 383-406.
- [24] Chantharatanapiboon W. Intralesional corticosteroid therapy in hemangiomas: clinical outcome in 160 cases. *J Med Assoc Thai* 2008; 91: 90-96.
- [25] Greinwald JH Jr, Burke DK, Bonthius DJ, Bauman NM, Smith RJ. An update on the treatment of hemangiomas in children with interferon alfa-2a. *Arch Otolaryngol Head Neck Surg* 1999; 125: 21-27.
- [26] Bauman NM, Burke DK, Smith RJ. Treatment of massive or life-threatening hemangiomas with recombinant alpha(2a)-interferon. *Otolaryngol Head Neck Surg* 1997; 117: 99-110.
- [27] Kaselas C, Tsikopoulos G, Papouis G, Kaselas V. Intralesional administration of interferon A for the management of severe haemangiomas. *Pediatr Surg Int* 2007; 23: 215-218.
- [28] Martinez MI, Sanchez-Carpintero I, North PE, Mihm MC Jr. Infantile hemangioma: clinical resolution with 5% imiquimod cream. *Arch Dermatol* 2002; 138: 881-884; discussion 884.
- [29] Sunamura M, Sun L, Lozonschi L, Duda DG, Kodama T, Matsumoto G, Shimamura H, Takeida K, Kobari M, Hamada H, Matsuno S. The antiangiogenesis effect of interleukin 12 during early growth of human pancreatic cancer in SCID mice. *Pancreas* 2000; 20: 227-233.
- [30] Barry RB, Hughes BR, Cook LJ. Involution of infantile haemangiomas after imiquimod 5% cream. *Clin Exp Dermatol* 2008; 33: 446-449.
- [31] Ho NT, Lansang P, Pope E. Topical imiquimod in the treatment of infantile hemangiomas: a retrospective study. *J Am Acad Dermatol* 2007; 56: 63-68.
- [32] Léauté-Labrèze C, Dumas de la Roque E, Hubiche T, Boralevi F, Thambo JB, Taïeb A. Propranolol for severe hemangiomas of infancy. *N Engl J Med* 2008; 358: 2649-2651.
- [33] Drolet BA, Frommelt PC, Chamlin SL, Haggstrom A, Bauman NM, Chiu YE, Chun RH,

Treatment guidelines of infantile hemangiomas

- Garzon MC, Holland KE, Liberman L, MacLellan-Tobert S, Mancini AJ, Metry D, Puttgen KB, Seefeldt M, Sidbury R, Ward KM, Blei F, Basella E, Cassidy L, Darrow DH, Joachim S, Kwon EK, Martin K, Perkins J, Siegel DH, Boucek RJ, Frieden IJ. Initiation and use of propranolol for infantile hemangioma: report of a consensus conference. *Pediatrics* 2013; 131: 128-140.
- [34] Koay AC, Choo MM, Nathan AM, Omar A, Lim CT. Combined low-dose oral propranolol and oral prednisolone as first-line treatment in periocular infantile hemangiomas. *J Ocul Pharmacol Ther* 2011; 27: 309-311.
- [35] Reddy KK, Blei F, Brauer JA, Waner M, Anolik R, Bernstein L, Brightman L, Hale E, Karen J, Weiss E, Geronemus RG. Retrospective study of the treatment of infantile hemangiomas using a combination of propranolol and pulsed dye laser. *Dermatol Surg* 2013; 39: 923-933.
- [36] Pandey A, Gangopadhyay AN, Upadhyay VD. Evaluation and management of infantile hemangioma: an overview. *Ostomy Wound Manage* 2008; 54: 16-18, 20, 22-26, 28-29.
- [37] Fawcett SL, Grant I, Hall PN, Kelsall AW, Nicholson JC. Vincristine as a treatment for a large haemangioma threatening vital functions. *Br J Plast Surg* 2004; 57: 168-171.
- [38] Sugarman JL, Mauro TM, Frieden IJ. Treatment of an ulcerated hemangioma with recombinant platelet-derived growth factor. *Arch Dermatol* 2002; 138: 314-316.
- [39] Ogino I, Torikai K, Kobayasi S, Aida N, Hata M, Kigasawa H. Radiation therapy for life- or function-threatening infant hemangioma. *Radiology* 2001; 218: 834-839.
- [40] Lindberg S. Radiotherapy of childhood haemangiomas: from active treatment to radiation risk estimates. *Radiat Environ Biophys* 2001; 40: 179-189.
- [41] Frieden IJ, Eichenfield LF, Esterly NB, Geronemus R, Mallory SB. Guidelines of care for hemangiomas of infancy. American Academy of Dermatology Guidelines/Outcomes Committee. *J Am Acad Dermatol* 1997; 37: 631-637.