

Original Article

Orthodontic extrusion of horizontally impacted mandibular molars

Zhigui Ma, Chi Yang*, Shanyong Zhang*, Qianyang Xie, Yuqing Shen, Pei Shen

*Department of Oral Surgery, Shanghai Ninth People's Hospital affiliated to Shanghai Jiaotong University, School of Medicine, Shanghai Key Laboratory of Stomatology, Shanghai, P. R. China. *Equal contributors.*

Received August 9, 2014; Accepted September 15, 2014; Epub October 15, 2014; Published October 30, 2014

Abstract: Objective: To introduce and evaluate a novel approach in treating horizontally impacted mandibular second and third molars. Materials and methods: An orthodontic technique was applied for treatment of horizontally impacted mandibular second and third molars, which included a push-type spring for rotation first, and then a cantilever for extrusion. There were 8 mandibular third molars (M3s) and 2 second molars (M2s) in this study. Tooth mobility, extraction time, the inclination and parallelism of the impacted tooth, alveolar bone height of the adjacent tooth, and the relationship of impacted M3 and the inferior alveolar nerve (IAN) were evaluated. Results: Two horizontally impacted M2s could be upright in the arch and good occlusal relationships were obtained after treatment. All impacted M3s were successfully separated from the IAN, without any neurologic consequences. The average extraction time was 5 minutes. There was a significant change in the inclination and parallelism of the impacted tooth after treatment. A new bone apposition with the average height of 3.2 mm was noted distal to the adjacent tooth. Conclusions: This two-step orthodontic technique as presented here may be a safe and feasible alternative in management of severely horizontally impacted mandibular molars, which achieves a successful separation of M3s from the IAN and an excellent position for M2s.

Keywords: Two-step technique, orthodontic extrusion, impacted molar, CBCT

Introduction

Impaction involves abnormal tooth eruption caused by a physical obstacle in the eruption path or the abnormal position of the tooth [1]. The most commonly affected teeth are mandibular third molars (M3s). In 80% of cases, teeth in proximity to the inferior alveolar nerve (IAN) were significantly correlated with neurologic injuries following the removal of impacted lower M3s [2]. The majority of M3s are horizontally or mesioangular impaction and the horizontal impaction is located in a position which creates more frequent risk of neurosensory deficit [3, 4]. The prevalence of mandibular second molars (M2s) impaction has been reported in whites as 0.3%, whereas Fu et al. found a slight higher rate of 0.65% in the Taiwanese population [5, 6]. M2s are of great importance for the normal development of the dentition and coordination of the facial growth [7]. And

even if the disturbances do not occur frequently, it is necessary to develop an effective treatment modality for impacted lower molars.

To reduce the neurologic risks, an orthodontic technique to move the M3 away from the inferior alveolar nerve (IAN) could be adopted [8, 9]. Orthodontic repositioning is also needed for a horizontally impacted M2, in order to bring it into the occlusion [10]. It is a great challenge for clinicians to upright a horizontally impacted mandibular molar. The literature contains limited information regarding the management of such cases and no clear standard therapy has been established for how to treat impacted M2s. The aim of this paper is to describe our experience in the treatment of such a difficult problem with a 2-step approach and the treatment outcomes using this orthodontic technique were also analyzed.

Orthodontics for horizontally impacted molars

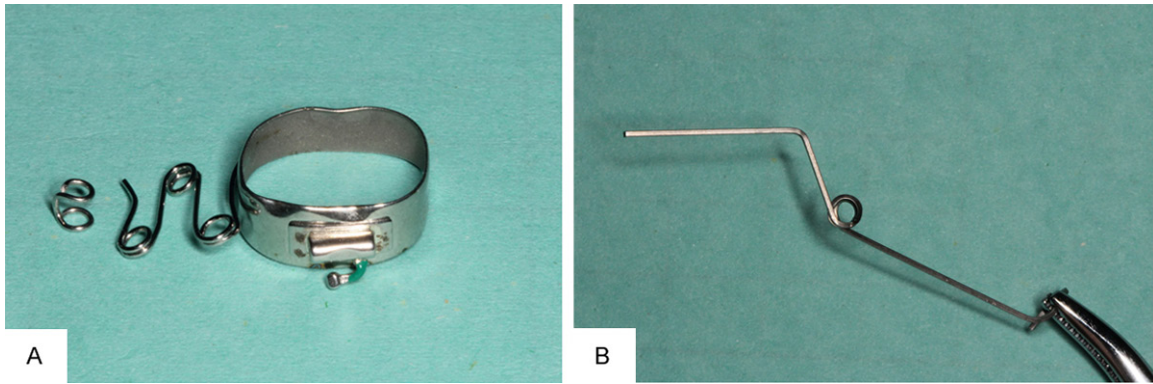


Figure 1. Preparation for push-type device. A: A 3-loop spring was welded to the molar band, with the end contacting the hook, to set the impacted molar distalization. B: Preparation for TMA cantilever. A 0.017 × 0.025 inch cantilever was made, to set the molar upward and backward.

Materials and methods

Patients

Patients were recruited from the Department of Oral Surgery, Shanghai Ninth People's Hospital, affiliated with Shanghai Jiao Tong University, School of Medicine (Shanghai, China).

Patients with the following characteristics were included in this study: (1) horizontally impacted mandibular molars, angle less than 30° was assigned a horizontal inclination, as described by Tay and Go (the inclination of impacted molars was determined by using the relationship of the long axis of the third molar to the occlusal plane on the panoramic radiograph); (2) the anatomical intimate relationship of the root of the M3 and the IAN; (3) impacted molars with bone impacted, in need of surgical exposure; (4) no periodontitis or pericoronitis; and (5) no history of trauma. Digital panoramic radiographs and cone-beam computed tomography (CBCT, J. Morita Mfg Corp, Kyoto, Japan) scans were taken before and after traction for each patient.

All the patients gave written, informed consent to participate in the study, which was approved by the ethics committee of the Ninth Hospital of Shanghai Jiaotong University.

Treatment phase

Phase 1: distal movement: An occlusal approach was recommended for a horizontally impacted tooth. The tissue should be removed

only on the distal surface, without exposure of the deep buccal surface.

A hook was bonded with a light-cured composite on the exposed surface. The hook, containing two parallel small circles with a vertical connection, was made with 0.016-inch stainless steel. One circle was bonded to the tooth and the other was used for force loading. The circle was 2 mm in diameter and the connection was 1.5 mm in length. The 3-loop spring made with 0.016-inch stainless steel was welded to the adjacent molar band, with the end contacting the hook, to set the impacted molar distalization (**Figure 1A**). The free end of the 3-loop spring was enlarged to 4 to 5 mm and generated a force of approximately 200 g backward and upward for the M2s and 250 g for the M3s [11]. With the impacted second molar progressively uprighting itself, the hook position could be adjusted appropriately to the treatment. The patients were scheduled for follow-up appointments four weeks later to control the movement of the impacted teeth.

Phase 2: occlusal eruption: The buccal tube bonded to the crown and was replaced as soon as possible when the buccal exposure was great enough. Anchorage was secured by the four teeth adjacent to the impacted molar with a 0.019 × 0.025 inch stainless steel wire [12]. A sectional titanium molybdenum alloy (TMA) cantilever, 0.017 × 0.025 inch, was inserted into the impacted molar buccal tube (**Figure 1B**). The free end of the cantilever was located at the oral vestibular sulcus, and then hooked onto the main arch wire to produce an active force of eruption. A force of 200 g was applied

Orthodontics for horizontally impacted molars

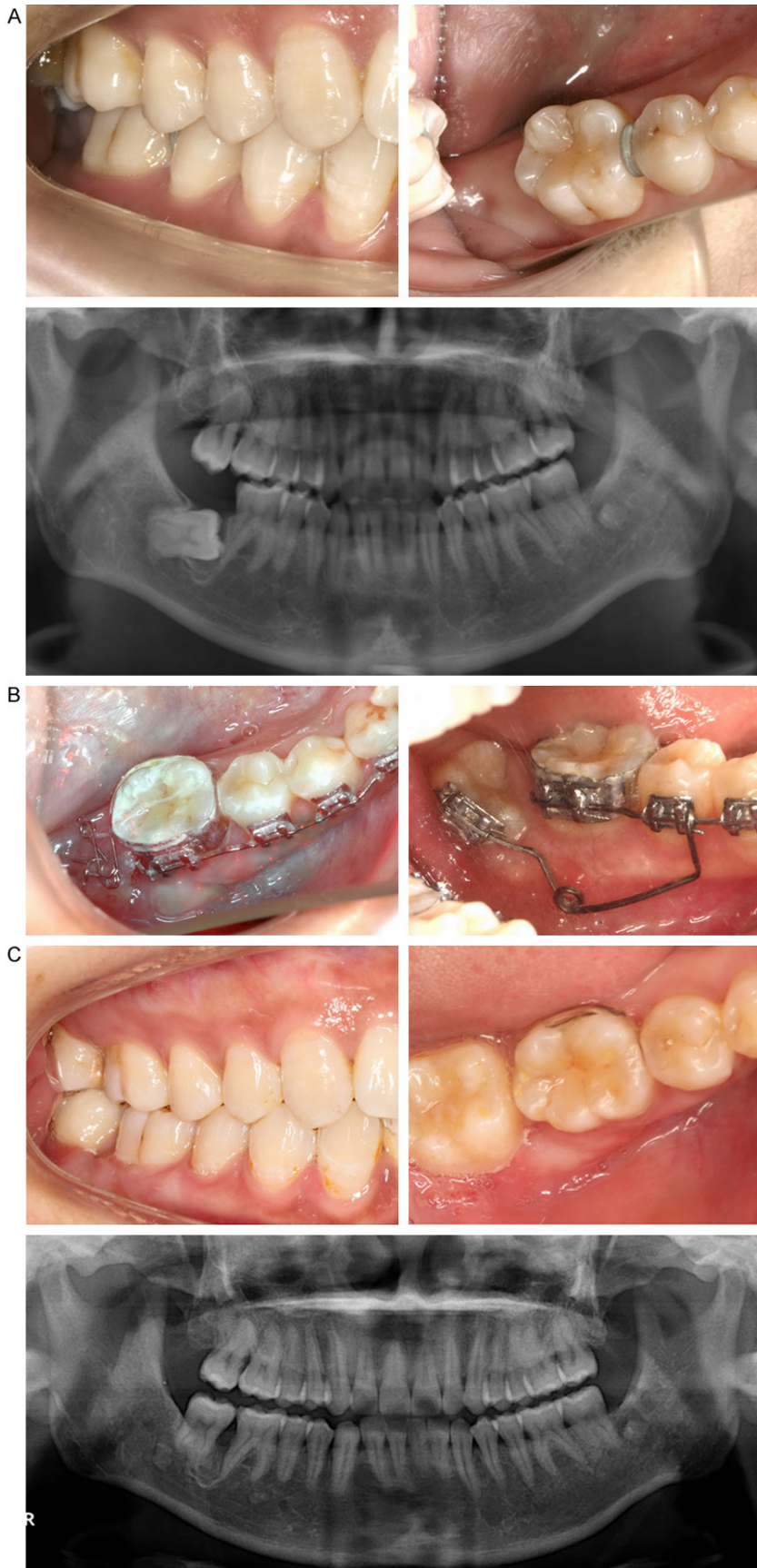

Figure 2. Treatment for horizontally impacted M2. A: Before treatment, a left mandibular M2 was severely horizontal impaction. B: During treatment, a two-step technique was used to set the M2 backward and upward. C: After treatment, the M2 was extruded and achieved a good occlusion with its root parallel to the adjacent tooth.

to the M3s and 150 g to the M2s.

Phase 3: precise adjustment for M2s or extraction for M3s: For an impacted M2, a successive finishing phase with a fixed appliance was applied to align the roots and close the remaining space. Extraction can proceed when the M3 roots are set apart from the IAN. Two of our clinical cases were presented (Figures 2, 3).

Clinical examination

For each patient, mobility of the impacted tooth was assessed after treatment. The criteria of tooth mobility was determined using Miller's mobility index: no movement distinguishable (0), first distinguishable sign of mobility (I), crown deviates within 1 mm of its normal position (II), mobility is easily noticeable and the tooth moves more than 1 mm in any direction (III).

M3 extraction time from gingival separation to removal from the socket was recorded, excluding anesthesia time.

Orthodontics for horizontally impacted molars

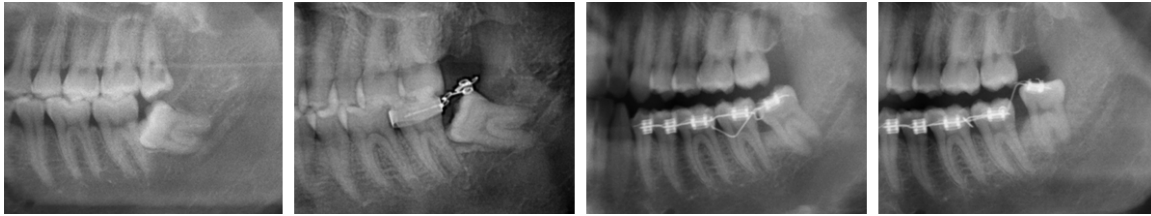


Figure 3. Orthodontic extrusion process. Panoramic radiograph shows treatment with a two-step technique to separate horizontally impacted M3 from the IAN.

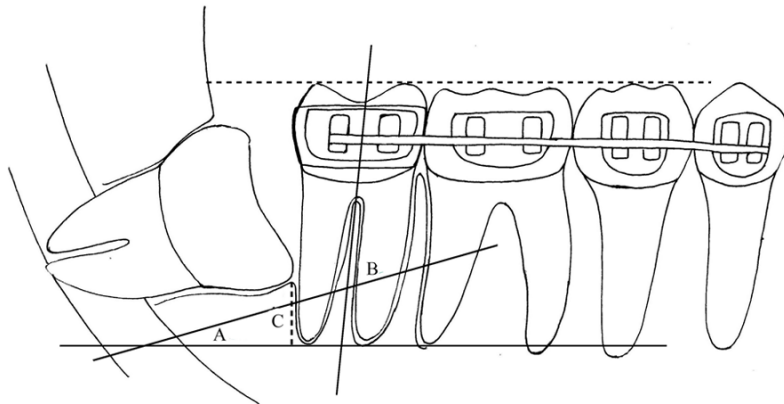


Figure 4. Schematic illustration of measurements. A and B: Angle of the inclination and parallelism of the horizontally impacted tooth, respectively. C: The alveolar bone height at distal aspect of the adjacent tooth.

Radiographic examination

To assess the alveolar bone height of the adjacent tooth, the largest sagittal imaging of the long axis was selected. The distance distal to the adjacent tooth between the alveolar crest and the root apex was performed with CBCT software, using a digital ruler accurate to 0.01 mm. The difference in distance before and after treatment was measured, which represented the new bone height of the adjacent tooth (**Figure 4**).

Using measurement software (E ruler, 1.1), the inclination of the impacted tooth, and the root parallelism between the impacted tooth and the adjacent molar, were measured on the digital panoramic radiographs. We selected the acute angle as the result (**Figure 4**).

The anatomic relationship of the M3 roots and the IAN was identified in all views of CBCT.

Statistical analysis

The paired t-test (SPSS statistics 17.0) was used to compare the difference of radiographic

measurements. *P* values smaller than 0.05 were considered statistically significant.

Results

Three males and 7 females with horizontally impacted molars were included. The patients' mean age was 26.5 years (range, 20 to 37 years). Eight were impacted M3s and the other 2 were M2s. There were 3 teeth with fused roots and 2 teeth with severely cured roots. Orthodontically-assisted treatment, with surgical

uncovering, was performed for all horizontally impacted teeth. The mean treatment period was 8.7 months. Two impacted M2s were upright in the arch and tight occlusion relationships were obtained after treatment. All impacted M3s were successfully extracted without any neurologic consequences. The average extraction time was 5 minutes (range, 3 to 7 minutes). The two impacted M2s showed no distinguishable luxation. I° of mobility was seen in 4 M3s and II° of mobility was seen in the other 4 (**Table 1**).

The average inclination was 21.43° before treatment, and the average change was 55.1° during treatment. The average angle of the impacted molar with adjacent tooth was 64.99° before treatment, and was 20.92° after treatment. There were significant changes in measurements of inclination and the parallelism ($p < 0.01$) (**Table 2**).

A significant difference in alveolar bone height distal to the adjacent tooth was observed between before and after treatment ($p < 0.01$). The average height of the new bone distal to the adjacent tooth was up to 3.2 mm (**Table 2**).

Orthodontics for horizontally impacted molars

Table 1. Clinical observation for 10 cases

No	Age	Sex	Position	Duration (mo)	Extraction time (min)	Mobility
1	22	Female	48	6	3	II
2	27	Female	48	7	6	I
3	31	Male	48	11	4	II
4	27	Female	37	7	-	-
5	28	Male	48	10	5	I
6	20	Female	38	7	7	I
7	25	Male	48	10	4	II
8	24	Female	38	8	6	I
9	23	Female	38	9	5	II
10	37	Female	47	12	-	-

Table 2. Radiographic changes of impacted molars during treatment

	Pre-treatment	Post-treatment	P
Inclination (°)	21.43 (4.49)	76.56 (7.57)	0.000
Parallelism (°)	64.99 (4.63)	20.92 (7.48)	0.000
Bone height (mm)	5.07 (1.28)	8.28 (1.17)	0.000

The values are given as mean (SD).

After traction, all of the M3s moved away from the IAN visualizing in three planes of CBCT.

Discussion

Horizontally impacted teeth often present a challenging problem for clinicians. It is difficult to bring a M2 into a normal occlusion or to extract a M3 that has an intimate relationship with the IAN. Modern dentistry often involves a multidisciplinary approach. Surgical exposure was performed first followed by a two-step technique. First, a push-type force, with a counter-clockwise rotation, was applied to upright a horizontally impacted molar. After enough surface exposure, an uprighting cantilever was then used to further extrude molars, so as to reposition impacted M2s or separating M3s from the IAN. The apex of the tooth may move downwards and closer to the IAN initially prior to the eruptive part of the orthodontic treatment moving it away from the IAN. However, the 2 steps couldn't be completely separated, as tooth distalization could accompany the occlusal extrusion. This two-step technique obeys the rule of tooth movement in the limited space. In this study, a statistically significant increase was found in the inclination and a significant decrease in the parallelism after treat-

ment. It was indicated that satisfactory molar uprighting was achieved via this technique.

Periodontal defects have been a frequent occurrence postoperatively at the distal aspect of the adjacent molar after the removal of impacted M3s. Kugelberg et al demonstrated that 44.4% of the study sample, aged 26 years or older, had infrabony defects exceeding 4 mm following M3 extraction [13, 14]. Briguglio et al reported conventional extractions of the impacted third molars often resulted in infrabony periodontal defects on the distal surface of the adjacent teeth [15]. In this study, it is worth noting that new bone apposition was detected after orthodontic extrusion, with the average height of 3.2 mm distal to the adjacent tooth. The present results show that this technique could be effective in treating bone defects of the adjacent tooth, avoiding the subsequent requirement of reconstructive substitutes [16]. However, the stability of increased distal bone needs further study.

Different treatment options are discussed in the literature. Landi et al presented coronectomy technique allowing spontaneous mesial migration of the impacted M3 by sectioning the portion of the M3 crown as a way to reduce neurological complication [17]. However, a further sectioning for a greater migration or double surgical procedures may be required. Use of a titanium miniscrew or miniplate for absolute anchorage during orthodontic uprighting has also been introduced [18, 19]. There are also a few limitations, namely, the requirement of a complex surgical procedure, the relatively high cost, and secondary operation for removing devices. When the molar is deeply impacted, orthodontic treatment could be particularly complex due to the difficulty of placing the conventional devices for molar uprighting. In our experience, the application of a two-step technique may overcome this problem easily. In contrast to a buccal surgical approach, the occlusal approach to exposure of horizontally impacted tooth is recommended in our study, which may contribute to less alveolar bone removal and minimally invasive surgery.

This technique could make it possible to move the impacted molars with different root morphology. We effectively luxated the M3s,

enabling M3 extraction with no fracture of the root fragment. Park et al also reported that one case with a curved lingual root close to the IAN was extracted successfully underwent orthodontic traction [18]. If the orthodontic force had not been used, severely curved roots might have been fractured, needing a higher risky operation to remove it from the proximity of the IAN. Additionally, this 2-step technique could be considered efficient for M3 extraction with the mean operative time of 5 minutes, much shorter than that of the conventional extraction.

Nevertheless, this modality remains several adverse effects because it takes quite a long period and the orthodontic appliance is very uncomfortable for the patient. Additionally, this procedure may need the patient compliance and be more expensive than simple M3 extraction. Moreover, the presence of horizontally impacted lower second molars is unusual and only two of horizontally impacted M2s were included in this study. Further research with more cases to verify the efficacy of this treatment protocol will be necessary in the future.

Conclusions

The management of horizontally impacted molars is an orthodontic challenge and this 2-step approach is considered a feasible alternative. The application of this novel technique could be effective in achieving a successful separation of M3s from the IAN and an excellent position for M2s. Further study in a large sample is needed to verify the efficacy of this new treatment protocol.

Disclosure of conflict of interest

None.

Address correspondence to: Zhigui Ma, Department of Oral Surgery, Shanghai Ninth People's Hospital Affiliated to Shanghai Jiaotong University, School of Medicine, Shanghai Key Laboratory of Stomatology, Shanghai, P. R. China. E-mail: mazhigui2007@126.com

References

- [1] Raghoobar GM, Boering G, Vissink A, Stegenga B. Eruption disturbances of permanent molars: a review. *J Oral Pathol Med* 1991; 20: 159-166.
- [2] Robert RC, Bacchetti P, Pogrel MA. Frequency of trigeminal nerve injuries following third mo-

- lar removal. *J Oral Maxillofac Surg* 2005; 63: 732-735.
- [3] Tay AB, Go WS. Effect of exposed inferior alveolar neurovascular bundle during surgical removal of impacted lower third molars. *J Oral Maxillofac Surg* 2004; 62: 592-600.
- [4] Valmaseda-Castellón E, Berini-Aytés L, Gay-Escoda C. Inferior alveolar nerve damage after lower third molar surgical extraction: a prospective study of 1117 surgical extractions. *Oral Surg Oral Med Oral Pathol Oral Radiol Endod* 2001; 92: 377-383.
- [5] Vedtofte H, Andreasen JO, Kjaer I. Arrested eruption of the permanent lower second molar. *Eur J Orthod* 1999; 21: 31-40.
- [6] Fu PS, Wang JC, Wu YM, Huang TK, Chen WC, Tseng YC, Tseng CH, Hung CC. Impacted mandibular second molars. *Angle Orthod* 2012; 82: 670-675.
- [7] Proffit WR. Equilibrium theory revisited: factors influencing position of the teeth. *Angle Orthod* 1978; 48: 175-186.
- [8] Miloro M, DaBell J. Radiographic proximity of the mandibular third molar to the inferior alveolar canal. *Oral Surg Oral Med Oral Pathol Oral Radiol Endod* 2005; 100: 545-549.
- [9] Alessandri Bonetti G, Bendandi M, Laino L, Checchi V, Checchi L. Orthodontic extraction: riskless extraction of impacted lower third molars close to the mandibular canal. *J Oral Maxillofac Surg* 2007; 65: 2580-2586.
- [10] Giancotti A, Arcuri C, Barlattani A. Treatment of ectopic mandibular second molar with titanium miniscrews. *Am J Orthod Dentofacial Orthop* 2004; 126: 113-117.
- [11] Ma ZG, Xie QY, Yang C, Xu GZ, Cai XY, Li JY. An orthodontic technique for minimally invasive extraction of impacted lower third molar. *J Oral Maxillofac Surg* 2013; 71: 1309-1317.
- [12] Majourau A, Norton LA. Uprighting impacted second molars with segmented springs. *Am J Orthod Dentofacial Orthop* 1995; 107: 235-238.
- [13] Kugelberg CF. Periodontal healing two and four years after impacted lower third molar surgery. A comparative retrospective study. *Int J Oral Maxillofac Surg* 1990; 19: 341-345.
- [14] Kugelberg CF, Ahlström U, Ericson S, Hugoson A, Kvint S. Periodontal healing after impacted lower third molar surgery in adolescents and adults. A prospective study. *Int J Oral Maxillofac Surg* 1991; 20: 18-24.
- [15] Briguglio F, Zenobio EG, Isola G, Briguglio R, Briguglio E, Farronato D, Shibli JA. Complications in surgical removal of impacted mandibular third molars in relation to flap design: clinical and statistical evaluations. *Quintessence Int* 2011; 42: 445-453.
- [16] Dodson TB. Management of mandibular third molar extraction sites to prevent periodontal

Orthodontics for horizontally impacted molars

- defects. *J Oral Maxillofac Surg* 2004; 62: 1213-1224.
- [17] Landi L, Manicone PF, Piccinelli S, Raia A, Raia R. A novel surgical approach to impacted mandibular third molars to reduce the risk of paresthesia: a case series. *J Oral Maxillofac Surg* 2010; 68: 969-974.
- [18] Park W, Park JS, Kim YM, Yu HS, Kim KD. Orthodontic extrusion of the lower third molar with an orthodontic mini implant. *Oral Surg Oral Med Oral Pathol Oral Radiol Endod* 2010; 110: e1-e6.
- [19] Tseng YC, Chen CM, Chang HP. Use of a mini-plate for skeletal anchorage in the treatment of a severely impacted mandibular second molar. *Br J Oral Maxillofac Surg* 2008; 46: 406-407.