

## Original Article

# Clinical experiences of NBI laryngoscope in diagnosis of laryngeal lesions

Xinmeng Qi<sup>1</sup>, Dan Yu<sup>1</sup>, Xue Zhao<sup>1</sup>, Chunshun Jin<sup>1</sup>, Changling Sun<sup>2</sup>, Xueshibojie Liu<sup>1</sup>, Jinzhang Cheng<sup>1</sup>, Dejun Zhang<sup>1</sup>

<sup>1</sup>Department of Otolaryngology Head and Neck Surgery, The Second Hospital, Jilin University, 218 Ziqiang Street, Changchun 130041, Jilin Province, China; <sup>2</sup>Department of Otorhinolaryngology Head and Neck Surgery, Wuxi Fourth People's Hospital, Affiliated Hospital of Jiangnan University, Wuxi 214000, Jiangsu Province, China

Received August 12, 2014; Accepted September 20, 2014; Epub October 15, 2014; Published October 30, 2014

**Abstract:** Endoscopy is essential for the diagnosis and treatment of cancers derived from the larynx. However, a laryngoscope with conventional white light (CWL) has technical limitations in detecting small or superficial lesions on the mucosa. Narrow band imaging especially combined with magnifying endoscopy (ME) is useful for the detection of superficial squamous cell carcinoma (SCC) within the oropharynx, hypopharynx, and oral cavity. A total of 3675 patients who have come to the outpatient clinic and complained of inspiratory stridor, dyspnea, phonation problems or foreign body sensation, were enrolled in this study. We describe the glottic conditions of the patients. All 3675 patients underwent laryngoscopy equipped with conventional white light (CWL) and NBI system. 1149 patients received a biopsy process. And 1153 lesions were classified into different groups according to their histopathological results. Among all the 1149 patients, 346 patients (312 males, 34 females; mean age 62.2±10.5 years) were suspected of having a total of 347 precancerous or cancerous (T1 or T2 without lymphnode involvement) lesions of the larynx under the CWL. Thus, we expected to attain a complete vision of what laryngeal lesions look like under the NBI view of a laryngoscope. The aim was to develop a complete description list of each laryngeal conditions (e.g. polyps, papilloma, leukoplakia, etc.), which can serve as a criteria for further laryngoscopic examinations and diagnosis.

**Keywords:** Narrow band imaging, diagnosis, endoscopy, laryngeal lesion

## Introduction

The larynx serves as the organ of phonation and as airway. It keeps the foodway and airway separate during food ingestion. Certain laryngeal disorders including inspiratory stridor, dyspnea, phonation problem (e.g. hoarseness), and eating difficulties, which may occur separately or in combination, may drive patients to a doctor. At present, indirect laryngoscopy is widely used for the assessment of laryngeal lesions, although direct laryngoscopy under general anesthesia with biopsy remains to be the gold standard. Flexible fiber scope allows a thorough observation of the larynx, even under difficult conditions of the anatomy or with regard to gagreflex [1]. Furthermore, an electronic videoscope system with a small charge-coupled device (CCD) chip, built into the tip of the flexible endoscope, can provide high quality color images on the color video monitor [2]. These high quality color images are helpful to

determine an optimal treatment of laryngeal lesions, which do get a visual difference comparing to normal anatomy. However, the intraepithelial lesions may be false-negatively diagnosed over these diagnostic strategies. Narrow band imaging (NBI) is a novel endoscopic technique enhances the diagnostic sensitivity of endoscopes for characterizing tissues by using narrow-bandwidth filters in a sequential red, green and blue illumination system. This filter cuts all wavelengths in illumination except two narrow wavelengths. One of these wavelengths is of 415 nm which corresponds to the peak absorption spectrum of hemoglobin to emphasize the image of capillary vessels on surface mucosa [3]. Superficial lesions are identified by changes in the color tone and irregularity of surface mucosa during endoscopic examinations. NBI has proved to be a useful screening tool in both the upper and the lower gastrointestinal tracts and the lower aerodigestive system [4-6]. Since endoscopic observation of superficial

**Table 1.** Precancerous and cancerous demographics (n=346)

Gender, no (%)	
Male	312 (90.2)
Female	34 (9.8)
Age, mean±SD, yr	62.2±10.5
Range, yr	33-87
Pathology, no (%) (n=347)	
Leukoplakia	105 (30.3)
Erythroplakia	21 (6.1)
Pachydermia	53 (15.3)
Malignant	168 (48.4)

SD=standard deviation.

**Table 2.** Lesions and diagnosis demographics (n=1153)

Diagnosis of Laryngeal Lesions, no (%)	
Polyp	692 (60.0)
Cyst & Mucocele	76 (6.6)
Papilloma	37 (3.2)
Leukoplakia	105 (9.1)
Erythroplakia	21 (1.8)
Pachydermia	53 (4.6)
Malignant	168 (14.6)

laryngeal carcinoma is similar to those of superficial esophageal carcinoma, it has become apparent that observation of the epithelial microvessels is useful in the diagnosis of laryngeal carcinoma as well as other laryngeal lesions [7, 8].

## Patients and methods

### Subjects and procedure

This study was conducted between January 2012 and October 2013 at the Department of otolaryngology, the second hospital of Jilin University (Changchun Jilin, China). Prior to performing endoscopic examinations, the surface of the patient's nasal cavity and oropharynx was anesthetized with a 4% lidocaine hydrochloride spray. The patient was examined in a seated position. The insertion tube was introduced through the wider nasal passage of each individual, and the examiner conducted an endoscopic examination while observing the live images on the color video monitor. The images were obtained by an assistant seating

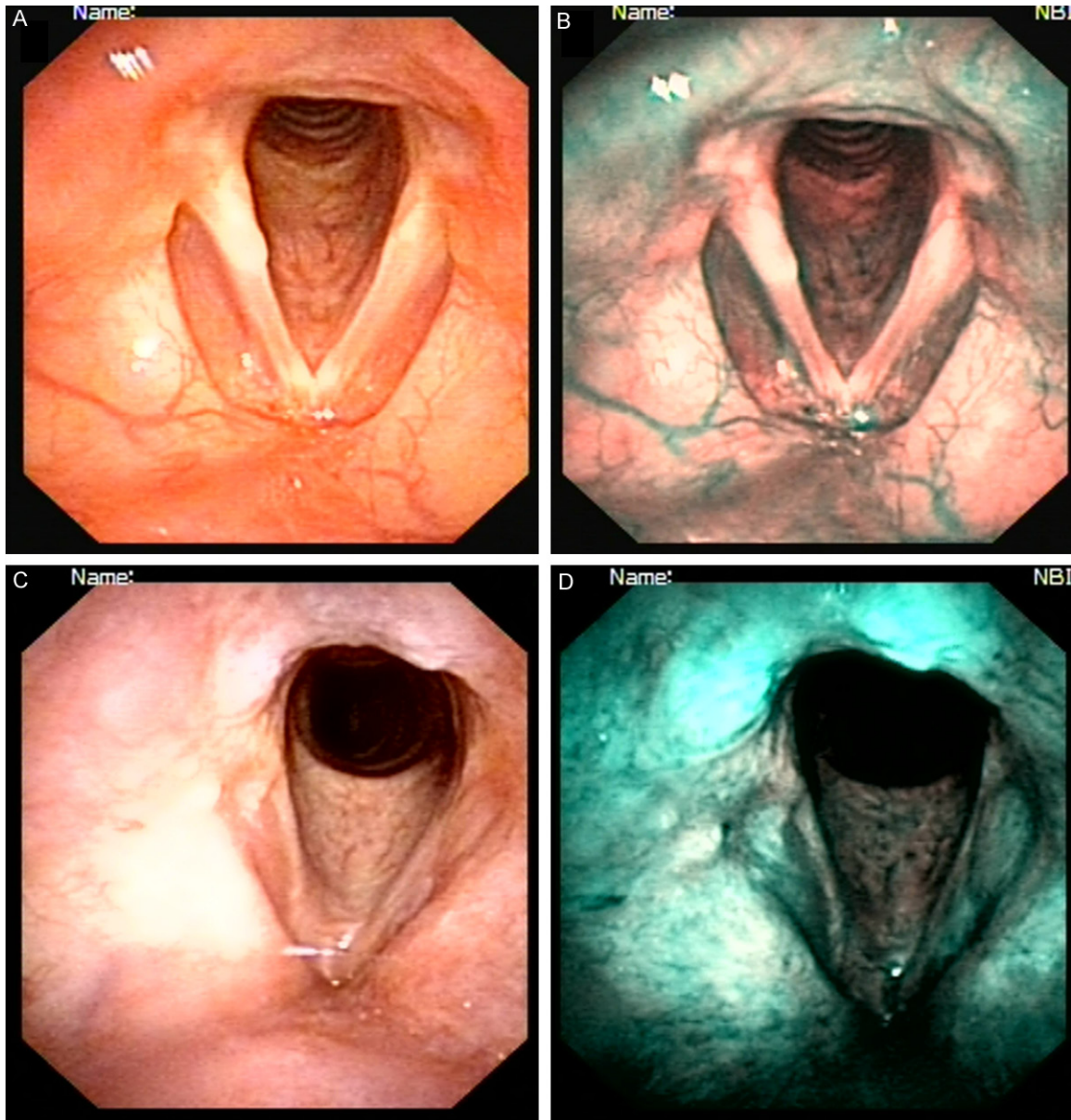
beside the monitor using a computer which shares the same live images with the color video monitor. For those who have visual lesions in their larynx, a biopsy process or an operation followed by a biopsy process was then undergone.

Written informed consent was obtained from each patient before laryngoscopy or biopsy. The biopsy specimens were fixed with 10% formalin for 24 h and submitted for histopathological examination.

A total of 3675 patients (2092 males, 1583 females; mean age 50.2±19.5) who have come to the outpatient clinic and complained of either inspiratory stridor, dyspnea, phonation problems or foreign body sensation, were enrolled in this study. We describe the glottic conditions of the patients. All 3675 patients underwent laryngoscopy equipped with conventional white light (CWL) and NBI system. 46 patients were postoperative, post-irradiated or receiving periodic examinations. 1149 patients underwent a biopsy process. And 1153 lesions were classified into different groups according to their histopathological results. Among all the 1149 patients, 346 patients (312 males, 34 females; mean age 62.2±10.5 years) were suspected of having a total of 347 precancerous or cancerous (T1 or T2 without lymphnode involvement) lesions of the larynx under the CWL. The demographics of precancerous and cancerous lesions are summarized in **Table 1**. Laryngoscopy using NBI system was performed on the same area observed by conventional white-light view. The diagnostic criteria of malignant lesions, including both SCC and carcinoma in situ (CIS), by NBI view was the presence of demarcated brownish area with scattered brown spots in the lesion [9].

### Equipment

The NBI system used for this study is based on modification of the spectral features with optical color separation filter narrowing a bandwidth of the spectral transmittance. The filter is placed in the optical system of the illumination. The filter cuts all wavelengths in illumination except two narrow wavelengths. The central wavelengths of each band are 415 and 540 nm. The image is reproduced in the processor with the information from two bands' illumina-



**Figure 1.** A. Conventional white-light image of a normal larynx; B. NBI image of the same site as A. Mucosa of a normal vocal fold was light brown; C, D. Conventional white-light and NBI image of the larynx of a postoperative patient. The patient was a 54-year-old male, and complaint of hoarseness for about 2 months when he come to our outpatient clinic. Under CWL laryngoscope, a not smooth tumor was observed in the right vocal fold, and an edematous swelling in the corresponding position in the left glottis; C, D. are images of him one year after the operation. The mucosa of larynx seems smooth and no abnormal microvessels were observed.

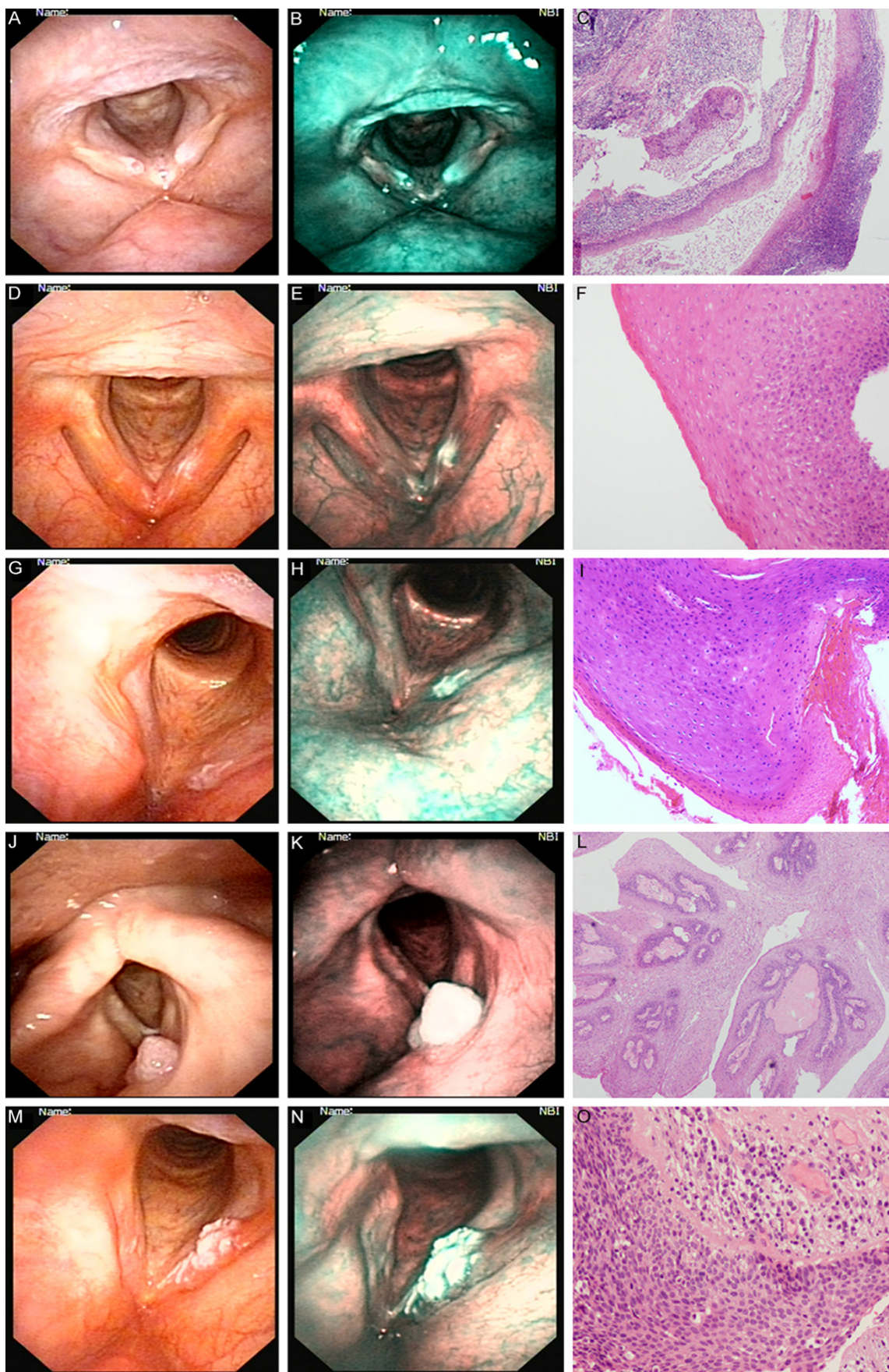
tion. The wavelength of 415 nm provides most information of capillaries within the superficial mucosa and structures on the mucosa.

This system is equipped with the ENF-TYPE VT2 video rhinolaryngoscope (Olympus Medical Systems Corp., Tokyo, Japan), the light source (CLV-S40Pro, Olympus Medical Systems Corp., Tokyo, Japan), and the video system center

(OTV-S7Pro, Olympus Medical Systems Corp., Tokyo, Japan). The light source has the optical filter (NBI filter) for NBI. When its observation mode is NBI, the NBI filter is inserted into the optical axis of the light source. The button on the control section of scope allows switching between the conventional view and the NBI view. Switching between the CWL and the NBI mode is achieved by pressing a button on the



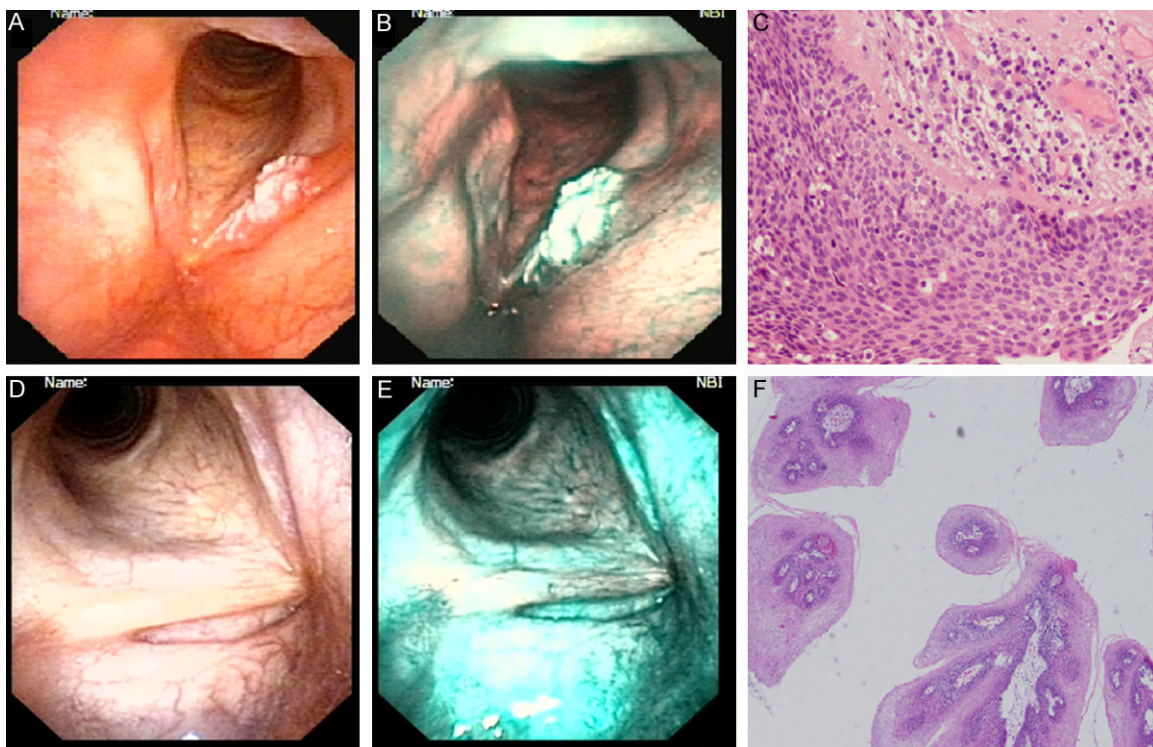
## NBI laryngoscope in diagnosis of laryngeal lesions





## NBI laryngoscope in diagnosis of laryngeal lesions

**Figure 2.** A. Conventional white-light image of the larynx. Cyst of the right vocal fold and laryngeal polyp of the left vocal fold; B. NBI mode of the same site as A. Cyst appeared as light white with an transparent little vesicle in the center. Polyp showed a color of light green; C. Histopathological evaluation of the biopsy specimen of cyst in the right vocal fold and polyp in the left. Hematoxylin and eosin staining with a magnification of  $\times 10$ ; D. Conventional white-light image of the larynx. Leukoplakia of bilateral vocal fold. Erythroplakia are seen in the supraglottic region of right ventricular band; E. Typical figures of leukoplakia are shown. Erythroplakia demonstrated as well-distributed dark brown lesions on NBI view; F. Low power magnification of the biopsied specimen. The lesion showed minimal cell size variation and was diagnosed as low-grade dysplasia; G, H. The CWL and NBI image of a larynx. Pachydermia on bilateral vocal fold. On NBI view, it appears as light white color; I. Low power magnification of the biopsied specimen. The lesion showed abnormal cell size variation and diagnosed as high-grade dysplasia; J. Conventional white light of a larynx. Papilloma is seen in the supraglottic region; K. NBI image of the same site as J. Papilloma appears as quite delicate green, which is much lighter than that of polyps; L. Histopathological evaluation of the biopsy specimen of papilloma in the supraglottic region. Hematoxylin and eosin staining with a magnification of  $\times 10$ ; M. Conventional white-light image of the larynx. The left glottic region is displayed slightly reddish; N. NBI view of the same site as M; O. Histology of that endoscopically biopsied superficial carcinoma specimen demonstrating squamous cell carcinoma in situ with keratinization (HE; original magnification  $\times 40$ ).



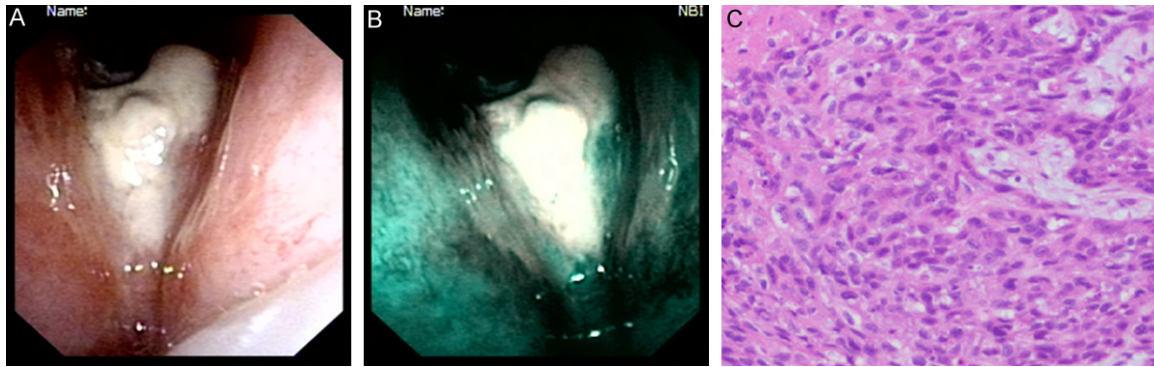
**Figure 3.** A. CWL image of the larynx showing tumor on the left vocal fold with keratin covering the mucosa; B. NBI view of the same site as A; C. Histology of that endoscopically biopsied superficial carcinoma specimen demonstrating squamous cell carcinoma in situ with keratinization (HE; original magnification  $\times 40$ ); D. CWL version of laryngoscope of the larynx; E. NBI displays white region in almost the whole length of the left vocal fold; F. Low power magnification of the biopsied specimen. The lesion showed cancer nests were composed of small round cancer cells.

light source or on the control section of scope less than a second during the procedure.

### Results

All patients well tolerated the electronic video-endoscopic examinations and developed no complications related to the use of laryngoscope. The quality of video-endoscope images obtained from the larynx was excellent and those images

were recorded by digital video recorder. No special techniques were required to perform endoscopic examination with NBI system, which could be carried out by pushing a fingertip control switch. The electroendoscope with NBI system could be handled as easily as standard laryngopharyngoscope. The average time needed for a patient's individual conventional white light and NBI endoscopy sequence was approximately 1 minute.



**Figure 4.** A. CWL image of the larynx showing necrosis and pseudomembrane in the glottic region; B. NBI view of the same site as A, showing a brown region in the right vocal fold; C. Histology of that endoscopically biopsied superficial carcinoma specimen demonstrating squamous cell carcinoma in situ (HE; original magnification  $\times 40$ ).

All 3675 patients were assigned to primary laryngoscopy equipped with conventional white light (CWL) followed by that with NBI system. 1149 patients underwent a biopsy process, and 1153 lesions were classified into different groups according to their histopathological results. Distinctive descriptions of each laryngeal lesion were concluded. Of those undergoing biopsy processes, 692 were pathologically confirmed as polyp. 74 were cyst and mucocele. 37 lesions were proved to be papilloma. The histopathological results of 179 were pre-malignant lesions, consisting of leukoplakia, erythroplakia and pachydermia, the data of which was respectively 105, 21 and 53. 168 were classified as malignant. **Table 2** shows the demographic characteristics of patients and their diagnosis.

On NBI view, mucosa of the normal vocal fold was light brown, which were slightly lighter than that of supraglottic regions. Intraepithelial vessels on NBI view displayed blue-green, which were in striking contrast to the surrounding mucosa, which was the distinguishing features of NBI view and hardly obtained by conventional white-light view. Polyps demonstrated a color of light green. Cysts and mucocele appeared as light white. Leukoplakia was shown as a white color and hyperplastic epithelial lesions appeared as a slightly brownish color. Erythroplakia appeared as well-distributed dark brown lesions on NBI view. Pachydermia displayed light white with a quite different shape from that of cysts and mucocele. Papilloma was shown as quite delicate green, which were much lighter than that of polyps. Abnormal sub-mucosal microvessel changes visualized in

laryngeal carcinoma lesions were shown as typical scattered dark brownish spots. Representative CWL and NBI images are shown in **Figures 1** and **2**. 168 lesions histopathologically proved to be malignant (129 SCC and 39 CIS). However, 166 lesions were classified as malignant by NBI view on the basis of abnormal intraepithelial microvascular changes.

There were two false-negative interpretations made by NBI view. The two false-negative cases were both seen in adult laryngeal SCC cases. The abnormal microvascular changes were masked by thick keratin layer completely covering the underlying malignant lesions (**Figure 3**).

The following case well demonstrates one of the advantages of NBI endoscopy for the diagnosis of superficial cancer of the larynx.

A 65-year-old male had hoarseness for about 2 months. He admitted to the local clinic and received laryngoscope with CWL. The local doctor conducted biopsy procedure under general anesthesia for three times, but did not get a positive result. Then the patient came to our outpatient clinic where he received endoscopy under both CWL and NBI view. Under CWL mode, reddening of the right vocal fold was observed, and abnormal microvascular changes were evident on NBI view. Under CWL endoscopy, necrosis and pseudomembrane was seen in the glottic region. The local doctor conducted biopsy procedure under general anesthesia for three times, but did not get a positive result. Then the patient came to our outpatient clinic where he received endoscopy under both CWL and NBI view. Under CWL mode, reddening of

the right vocal fold was differentiation between squamous carcinoma covered by a thick keratin layer and papilloma lesions, as was seen in the two false-negative cases. The presence of observed and abnormal microvascular changes was evident on NBI view. Histopathological evaluation of biopsy specimens revealed SCC in situ (**Figure 4**).

### Discussion

On NBI view, mucosa of the vocal fold displayed a slightly lighter brownish color than that of supraglottic and subglottic regions because of scanty submucosal vessels, which displayed dark green. The reason that cysts and mucoceles appeared as light white may be interpreted by the shape of the lesions. One of the limitations of the NBI system without magnification system is the differentiation between squamous carcinoma covered by a thick keratin layer and papilloma lesions, as was seen in the two false-negative cases.

Symptoms such as phonation problems or foreign body sense may drive a patient to a clinic when the glottic lesion is in situ or at least at an early stage of carcinoma, but early carcinoma located in the supraglottic and subglottic region is uncommon. This is probably due to that the latter patients are often asymptomatic until the tumor reaches a significant size presenting with airway problems [10, 11].

Furthermore, NBI seems to be helpful in dealing with the resection margin during surgery [12], for example, one may confirm the margin of a malignant lesion under CWL, but on NBI view, the image of submucosal vessel near the edging area may be abnormal, which may present a wider incision field. Those with apparent lesions, for example, leukoplakia, papilloma or pachydermia, may also benefit from NBI due to the fact that NBI shows the most suitable spot to receive biopsy, as was seen in the case with necrosis tissue above. Moreover, NBI is a non-invasive technique that can be carried out in the outpatient clinic [13] by pushing a fingertip control switch, without using special techniques, without drug application. NBI endoscopy is such a simple, convenient, and reliable tool, and adds additional value to detect local recurrence in the early phase. It may serve as an ideal tool in posttreatment surveillance in a patient with laryngeal lesion. Since laryngeal

squamous cell carcinoma is one of the most common malignant neoplasms of the head and neck [14] and the prognosis of early malignant disease of the larynx is favorable, it is important for otolaryngologists to have a clear understanding of the clinical features of the premalignant and early malignant changes in the larynx [15]. A majority of malignant neoplasms are of SCC in origin and have almost the same morphology in the upper aerodigestive tract including the head and neck and esophagus. Although direct laryngoscopy under general anesthesia with biopsy remains to be the gold standard for diagnosing larynx cancer, it is invasive, and it is not feasible to repeat this procedure at every follow-up visit. NBI endoscopy seems to be a very promising diagnostic tool in the diagnosis of laryngeal malignant disease.

### Conclusion

Endoscopic tools for examination of the upper aerodigestive tract have undergone significant developments in recent years. Despite of the drawbacks of this promising examination approach, the advent of NBI seems to be a breakthrough in the field of assessing laryngeal cancer.

### Disclosure of conflict of interest

None.

**Address correspondence to:** Dan Yu or Chunshun Jin, Department of Otolaryngology Head and Neck Surgery, The Second Hospital, Jilin University, 218 Ziqiang Street, Changchun 130041, Jilin Province, China. E-mail: yudan19792003@163.com (DY); luoyulou@163.com (CSJ)

### References

- [1] Katada C, Tanabe S, Koizumi W, Higuchi K, Sasaki T, Azuma M, Katada N, Masaki T, Nakayama M, Okamoto M and Muto M. Narrow band imaging for detecting superficial squamous cell carcinoma of the head and neck in patients with esophageal squamous cell carcinoma. *Endoscopy* 2010; 42: 185-190.
- [2] Kawaida M, Fukuda H and Kohno N. Observations of laryngeal lesions with a rhinolarynx electronic videoendoscope system and digital image processing. *Ann Otol Rhinol Laryngol* 1998; 107: 855-859.
- [3] Watanabe A, Taniguchi M, Tsujie H, Hosokawa M, Fujita M and Sasaki S. The value of narrow band imaging for early detection of laryngeal cancer. *Eur Arch Otorhinolaryngol* 2009; 266: 1017-1023.



- [4] Muto M, Horimatsu T, Ezoe Y, Hori K, Yukawa Y, Morita S, Miyamoto S and Chiba T. Narrow-band imaging of the gastrointestinal tract. *J Gastroenterol* 2009; 44: 13-25.
- [5] van den Broek FJ, Reitsma JB, Curvers WL, Fockens P and Dekker E. Systematic review of narrow-band imaging for the detection and differentiation of neoplastic and nonneoplastic lesions in the colon (with videos). *Gastrointest Endosc* 2009; 69: 124-135.
- [6] Hayashi T, Muto M, Hayashi R, Minashi K, Yano T, Kishimoto S and Ebihara S. Usefulness of narrow-band imaging for detecting the primary tumor site in patients with primary unknown cervical lymph node metastasis. *Jpn J Clin Oncol* 2010; 40: 537-541.
- [7] Nonaka K, Nishimura M and Kita H. Role of narrow band imaging in endoscopic submucosal dissection. *World J Gastrointest Endosc* 2012; 4: 387-397.
- [8] Yoshimura N, Goda K, Tajiri H, Yoshida Y, Kato T, Seino Y, Ikegami M and Urashima M. Diagnostic utility of narrow-band imaging endoscopy for pharyngeal superficial carcinoma. *World J Gastroenterol* 2011; 17: 4999-5006.
- [9] Muto M, Minashi K, Yano T, Saito Y, Oda I, Nonaka S, Omori T, Sugiyura H, Goda K, Kaise M, Inoue H, Ishikawa H, Ochiai A, Shimoda T, Watanabe H, Tajiri H and Saito D. Early detection of superficial squamous cell carcinoma in the head and neck region and esophagus by narrow band imaging: a multicenter randomized controlled trial. *J Clin Oncol* 2010; 28: 1566-1572.
- [10] Kumamoto T, Sentani K, Oka S, Tanaka S and Yasui W. Clinicopathological features of minute pharyngeal lesions diagnosed by narrow-band imaging endoscopy and biopsy. *World J Gastroenterol* 2012; 18: 6468-6474; discussion 6473.
- [11] Piazza C, Dessouky O, Peretti G, Cocco D, De Benedetto L and Nicolai P. Narrow-band imaging: a new tool for evaluation of head and neck squamous cell carcinomas. Review of the literature. *Acta Otorhinolaryngol Ital* 2008; 28: 49-54.
- [12] Matsuba H, Katada C, Masaki T, Nakayama M, Okamoto T, Hanaoka N, Tanabe S, Koizumi W, Okamoto M and Muto M. Diagnosis of the extent of advanced oropharyngeal and hypopharyngeal cancers by narrow band imaging with magnifying endoscopy. *Laryngoscope* 2011; 121: 753-759.
- [13] Watanabe A, Tsujie H, Taniguchi M, Hosokawa M, Fujita M and Sasaki S. Laryngoscopic detection of pharyngeal carcinoma in situ with narrowband imaging. *Laryngoscope* 2006; 116: 650-654.
- [14] Burduk PK. Association between infection of virulence cagA gene *Helicobacter pylori* and laryngeal squamous cell carcinoma. *Med Sci Monit* 2013; 19: 584-591.
- [15] Marioni G, Marchese-Ragona R, Cartei G, Marchese F and Staffieri A. Current opinion in diagnosis and treatment of laryngeal carcinoma. *Cancer Treat Rev* 2006; 32: 504-515.