

## Case Report

# Cyclic thrombocytopenia related to menstrual cycle: a case report and literature review

Guoshu Chen<sup>1\*</sup>, Li Chen<sup>1\*</sup>, Xiaohua Qin<sup>1\*</sup>, Xiaoling Xie<sup>1</sup>, Guowei Li<sup>1</sup>, Bing Xu<sup>2</sup>

<sup>1</sup>Department of Hematology, Huizhou Municipal Central Hospital, 41, Eling Road North, Huizhou 516001, PR China;

<sup>2</sup>Department of Hematology, Nanfang Hospital, Southern Medical University, Guangzhou 510515, PR China. \*Equal contributors.

Received August 20, 2014; Accepted September 20, 2014; Epub October 15, 2014; Published October 30, 2014

**Abstract:** Cyclic thrombocytopenia (CTP) is rarely seen and characterized by periodic fluctuations in platelet counts. In some cases, it occurs in phase with menstrual cycle. A 40-year-old female, presented firstly on June 30, 2012, with a 40-day history of appearance of purpuric skin rash and bruising, was readmitted on Aug 14, when she noted bruise on her lips. The platelet count was  $24 \times 10^9/L$  on June 30,  $32 \times 10^9/L$  on Aug 14, while it was  $161 \times 10^9/L$  on July 1,  $110 \times 10^9/L$  on Aug 16. Physical examination show skin purpuric spots and bruise over the limbs and trunk. Liver, spleen, lymph nodes were not enlarged. Antinuclear antibody and rheumatoid factor (RF) were positive. Results of immune complex levels, serum complements, Hp antibody and Thrombopoietin (TPO) were all within normal ranges. Bone marrow aspiration and biopsy shown there was no change in megakaryocyte number. Fluorescence-activated cell sorter (FACS) performed normal. JAK2-V617F gene mutational and platelet-associated antibodies were not detected. We observed the patient over two complete cycles, and continued investigating her blood counts for six months follow up. During the entire process, her menstrual was regular without heavy blood loss and prolonged period. Her hemoglobin and white cell counts remained normal without cyclic change. Even if the patient was not on any therapy designed to increase the platelet count, her platelet level was back to normal. Follow up to December, 2012; her platelet count continued to fluctuation,  $20 \times 10^9/L$ - $40 \times 10^9/L$  in the middle of menstrual cycle while  $105 \times 10^9/L$ - $197 \times 10^9/L$  at the menses.

**Keywords:** Cyclic thrombocytopenia, menstrual cycle, antinuclear antibody

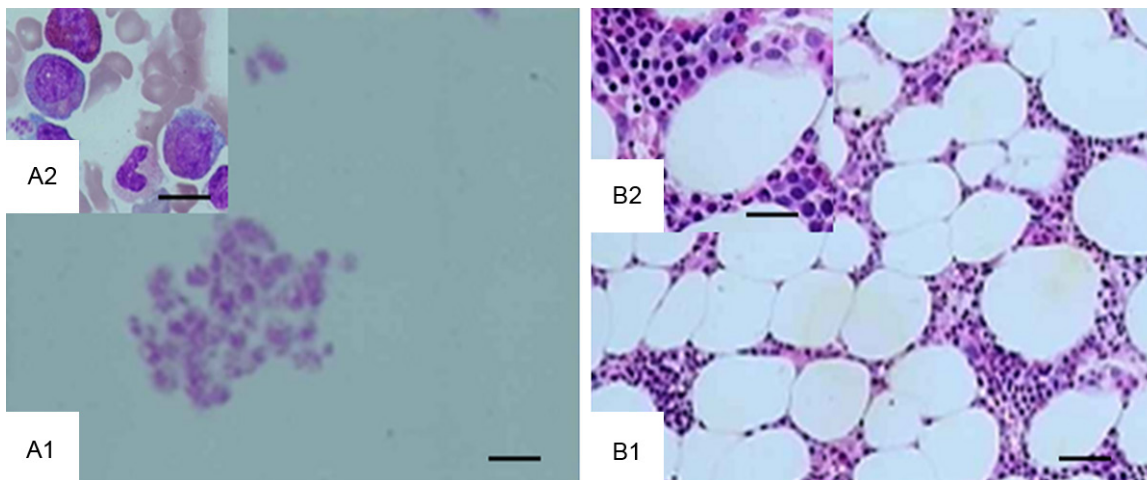
### Introduction

Cyclic thrombocytopenia (CTP) is a rare disease characterized by periodic fluctuations in platelet counts [1]. In women, this phenomenon often occurs in synchrony with menstrual cycle [2-6]. With similar clinical features to idiopathic thrombocytopenia (ITP), CTP is usually first diagnosed and treated as ITP with lack of response [2, 7, 8]. We recently encountered a CTP patient related to menstruation with multiple autoantibodies. We indicated that the platelet fluctuation, which correlated with her menstrual cycles and mediated by autoantibodies, might be vital to the pathogenesis of such condition.

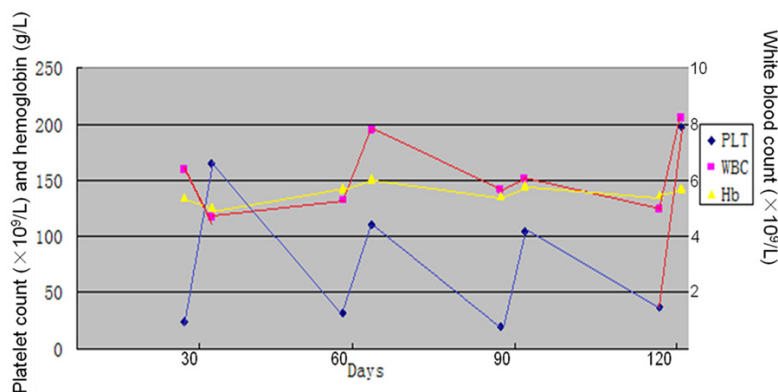
### Case report

A 40-year-old married female patient, delivered a boy eight years ago by normal labor, first pre-

sented with a 40-day history of appearance of purpuric skin rash and bruising, on June 30, 2012. She was readmitted to our hospital on Aug 14, 2012, when she noted bruise on her lips. The platelet count was  $24 \times 10^9/L$  on June 30,  $32 \times 10^9/L$  on Aug 14, while it was  $161 \times 10^9/L$  on July 1,  $110 \times 10^9/L$  on Aug 16. Her physical examination showed skin purpuric spots and bruise over the limbs and trunk, but there was no evidence of blood loss from any other site. Liver, spleen, lymph nodes were not enlarged. Antinuclear antibody test and rheumatoid factor (RF) were positive. Quantitative immunoglobulin determinations showed elevated IgG levels (17 g/L). Results of repeated examinations of immune complex levels, serum complements C3, C4, Hp antibody and thrombopoietin (TPO) test were all within normal ranges. Bone marrow aspiration and biopsy shown there was no change observed in megakaryocyte number and fluorescence-activated cell sorter (FACS)



**Figure 1.** Bone marrow aspiration and biopsy shown there was no change observed in megakaryocyte number. (A: bone marrow aspiration. B: bone marrow biopsy. A1, B1: 100x. B2: 400x. A2: 1000x).



**Figure 2.** The relationship between platelet, white blood cell counts and hemoglobin levels over a 120-day period. Platelet counts periodic fluctuated in synchrony with menstrual cycle, but the hemoglobin levels and white blood cell counts remain normal without cyclic changes.

performed normal (**Figure 1**). JAK2-V617F gene mutational testing was negative and platelet-associated antibodies were not detected. We initially observed the patient over two complete cycles, and then continued measuring her blood counts for six months (**Figure 2**). During the entire process, her menstrual was regular without heavy blood loss and prolonged period. The patient was not on any therapy designed to increase the platelet count, however, her platelet level was back to normal line on the next two days, and her hemoglobin and white cell counts remained normal without cyclic change. Reports of follow-up till December 2012 showed that her platelet count continued to fluctuate, and it was  $20 \times 10^9/L$ - $40 \times 10^9/L$  in the middle of two menstrual cycles, while it was

$105 \times 10^9/L$ - $197 \times 10^9/L$  in menses.

### Discussion

CTP is rarely seen, most cases of CTP seem to be idiopathic, while some are secondary to myelodysplastic, lymphoproliferative diseases and rheumatology. Although the cause of CTP remains unclear, there are several mechanisms documented for the pathogenesis of CTP [2-4, 8-12], including autoimmune platelet destruction, megakaryocytic hypoplasia, and hormonal factors.

Typically, the highest platelet levels occur between two menstrual cycles, rather than at the time of menstruation [11, 13], although in some females the pattern is opposite [5, 11]. In our case, the platelet counts fell at the middle cycle of menses and peaked at the menses. Serum TPO test was normal. There was no change of megakaryocyte numbers in bone marrow specimen. JAK2-V617F mutation and platelet-associated antibodies were not detectable. There was no significant clinical evidence of an underlying auto-immune disorder, but her antinuclear antibodies were persistently detectable, which indicated that some underlying abnormalities might be due to the immune system and needed to be further researched.

## Thrombocytopenia and menstrual cycle

On reviewing the literature, we found that it was a long time to diagnosis CTP from the onset, few cases was fitted to the right diagnosis and most CTP cases received ITP treatment without good reaction. There are no standard regimens for CTP. Treatment should be guided by etiology and disease severity, and sometimes not necessary in mild cases. CTP appears to be less responsive to conventional therapies used for ITP [7, 8]. For example, patients often fail to respond to corticosteroids, splenectomy and IVIG [2, 4, 7, 8]. Estrogen and progesterone can be used, but not very effective [14]. There are some individual cases reported by successfully using CsA, 6-MP, TPO, helicobacter pylori eradication and danazol [7, 15-19]. In this case, the patient has never experienced severe blood loss or life-threatening hemorrhage that would require red cell or platelet transfusions, and her hemoglobin and white cell counts have remained normal without cyclic change through the whole course, so she did not receive any therapy designed to increase platelet count, such as corticosteroids, CsA, TPO or danazol, and her platelet counts returned to normal level spontaneously.

In conclusion, this case reveals that CTP is a heterogeneity disease that should be differentiated from ITP, and there is no special therapy for CTP, treatment should be guided by etiology and disease severity. Though our information can not be taken as direct evidence for a defect of immune-regulation, the indicated disorder of immune system in our patient was very impressive. We will continue to investigate and apply new ways to explore it.

### Disclosure of conflict of interest

None.

**Address correspondence to:** Dr. Xu Bing, Department of Hematology, Nanfang Hospital, Southern Medical University, Guangzhou 510515, PR China. Tel: +86 (0) -20-616-416-15; Fax: +86 (0) -20-872-807-61; E-mail: xubingzhangjian@126.com

### References

- [1] Minot GR. Purpura hemorrhagica and lymphocytosis: acute type and intermittent menstrual type. *Am J Med Sci* 1936; 2: 445.
- [2] Cohen T, Cooney DP. Cyclic thrombocytopenia. Case report and review of literature. *Scand J Haematol* 1974; 12: 9-17.

- [3] Pepper H, Liebowitz D, Lindsay S. Cyclical thrombocytopenic purpura related to the menstrual cycle. *AMA Arch Pathol* 1956; 61: 1.
- [4] Lewis ML. Cyclic thrombocytopenia. A thrombopoietin deficiency? *J Clin Pathol* 1974; 27: 242-246.
- [5] Skoog WA, Lawrence JS, Adams WS. A metabolic study of a patient with idiopathic cyclical thrombocytopenic purpura. *Blood* 1957; 12: 844-856.
- [6] Brey O, Garner EPR, Wells D. Cyclic thrombocytopenia associated with multiple autoantibodies. *Br Med J* 1969; 3: 397-398.
- [7] Bose P, Hussein KK, Terrell DR, Berger D, Rice L, George JN. Successful treatment of cyclic thrombocytopenia with thrombopoietin-mimetic agents: a report of two patients. *Am J Hematol* 2009; 84: 459-461.
- [8] Go RS. Idiopathic cyclic thrombocytopenia. *Blood Rev* 2005; 19: 53-59.
- [9] Engstrom K, Lundquist A, Soderstrom N. Periodic thrombocytopenia or tidal platelet dysgenesis in a man. *Scand J Haematol* 1966; 3: 290-294.
- [10] Wasastjerna C. Cyclic thrombocytopenia of acute type. *Scand J Haematol* 1967; 4: 380-384.
- [11] Kuyama J, Take H, Matsumoto S, Nakajima T, Sugase T, Hata A, Hanada M, Nakagawa K. Synchronous fluctuation of interleukin-6 and platelet count in cyclic thrombocytopenia and thrombocytosis. *Intern Med* 1995; 34: 636-639.
- [12] Yujiri T, Tanaka Y, Tanaka M, Tanizawa Y. Fluctuations in thrombopoietin, immature platelet fraction, and glyocalicin levels in a patient with cyclic thrombocytopenia. *Int J Hematol* 2009; 90: 429-430.
- [13] Tomer A, Schreiber AD, McMillan R, Cines DB, Burstein SA, Thiessen AR, Harker LA. Menstrual cyclic thrombocytopenia. *Br J Haematol* 1989; 71: 519-524.
- [14] Helleberg C, Taaning E, Hansen PB. Cyclic thrombocytopenia successfully treated with low dose hormonal contraception. *Am J Hematol* 1995; 48: 62-63.
- [15] Fogarty PF, Stetler-Stevenson M, Pereira A, Dunbar CE. Large granular lymphocytic proliferation-associated cyclic thrombocytopenia. *Am J Hematol* 2005; 79: 334-336.
- [16] Asaumi N, Niiya K, Yoshida C, Shibakura M, Niiya M, Tanimoto M. Complete remission of cyclic thrombocytopenia after Helicobacter pylori eradication. *Blood Coagul Fibrinolysis* 2004; 15: 439-440.
- [17] Dan K, Inokuchi K, An E, Nomura T. Cell-mediated cyclic thrombocytopenia treated with azathioprine. *Br J Haematol* 1991; 77: 365-370.

## Thrombocytopenia and menstrual cycle

- [18] Rocha R, Horstman L, Ahn YS, Mylvaganam R, Harrington WJ. Danazol therapy for cyclic thrombocytopenia. *Am J Hematol* 1991; 36: 140-143.
- [19] Rice L, Nichol JL, McMillan R, Roskos LK, Bacile M. Cyclic immune thrombocytopenia responsive to thrombopoietic growth factor therapy. *Am J Hematol* 2001; 68: 210-214.