

Case Report

Role of PET/CT in the diagnosis, staging, and follow-up of a nasal-type natural killer T-cell lymphoma in the larynx: a case report and literature review

Min-Li Zhou¹, Kui Zhao², Shui-Hong Zhou¹, Qin-Ying Wang¹, Zhou-Jun Zheng³, Zhong-Jie Lu⁴

Departments of ¹Otolaryngology, ²PET/CT Centre, ³Pathology, ⁴Radiotherapy, The First Affiliated Hospital, College of Medicine, Zhejiang University, 310003, China

Received August 30, 2014; Accepted October 23, 2014; Epub November 15, 2014; Published November 30, 2014

Abstract: Background: Nasal-type natural killer T-cell lymphoma involving the larynx is uncommon. Our search revealed only 12 cases reported previously in the English-language literature. Case report: We report a case of laryngeal NKTCL. In December 2011, the patient was diagnosed with nasal-type NKTCL and FDG PET/CT showed the lesions were confined to the nasal cavity (stage I). At 1 year after radiotherapy, the patient presented with hoarseness and FDG PET/CT revealed high FDG uptake in the subglottic region and left cervical lymph nodes. A biopsy of the subglottis confirmed NKTCL (stage II). He then received chemotherapy and 14 months after the completion of chemotherapy, FDG PET/CT showed no evidence of recurrence or metastasis. Conclusions: PET/CT has better sensitivity than other conventional methods and may play an important role in the diagnosis, staging, and follow-up of nasal-type natural killer T-cell lymphoma.

Keywords: Natural killer T-cell lymphoma, larynx, PET/CT, follow-up

Introduction

Nasal-type natural killer T-cell lymphoma (NKTCL) is a rare entity and is always localized in the upper aerodigestive tract [1]. However, NKTCL involving the larynx is uncommon. To our knowledge, this is only the thirteenth case ever reported in the English-language literature [2-9].

Because of the limited number of cases, the diagnosis and treatment of laryngeal NKTCL are unclear. [¹⁸F] 2-fluoro-2-deoxy-d-glucose (¹⁸F-FDG) positron emission tomography/computed tomography (PET/CT) imaging has been used widely for the diagnosis, preoperative staging, restaging, prognosis prediction, and detection of unknown primary tumors [10]. However, the role of ¹⁸F-FDG PET/CT in NKTCL is limited due to the rarity of this entity and there are few reports about ¹⁸F-FDG PET/CT in NKTCL. Indeed, we have found no report about ¹⁸F-FDG PET/CT in laryngeal NKTCL.

Here, we report a case of laryngeal NKTCL. In December 2011, the patient was diagnosed

with nasal-type NKTCL and FDG PET/CT showed that the lesions were confined to the nasal cavity (stage I). At 1 year after radiotherapy, the patient presented with hoarseness and FDG PET/CT revealed high FDG uptake in the subglottic region and left cervical lymph nodes. A biopsy of the subglottis confirmed NKTCL (stage II).

Case report

On December 2, 2011, a 59-year-old male presented with a 1-year history of bilateral nasal obstruction and 2-month history of rhinorrhea with bleeding. His past medical history included a drainage operation for a hepatic abscess 20 years earlier, seasonal dermatitis for 10 years, excision of a vocal polyp 5 years earlier, and right lobe resection of the thyroid gland for a thyroid nodule 3 years earlier. He had a long history of smoking, 20 cigarettes per day for 40 years, and then gave up smoking 2 years ago. Nasal endoscopy showed a mass in the right nasal cavity and the other anatomical structures were obstructive and unclear. The third of multiple biopsies revealed extranodal NK/T-cell

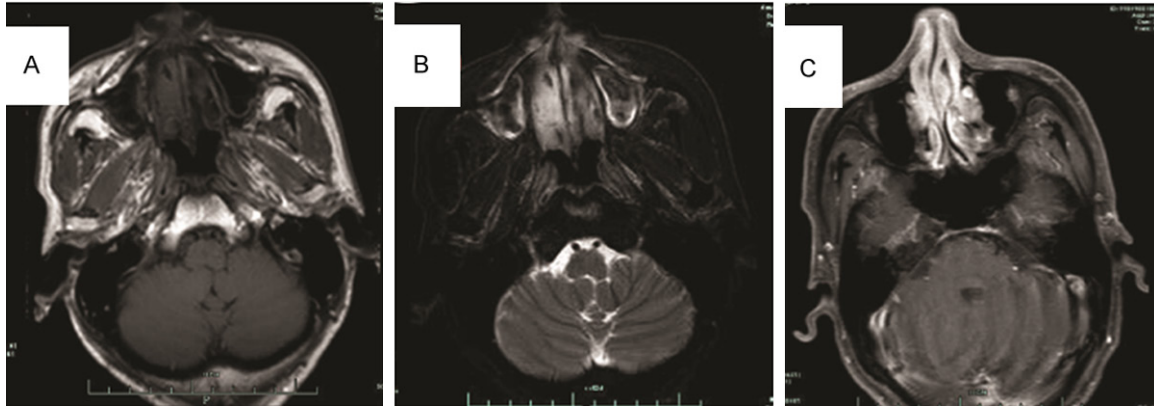


Figure 1. Magnetic resonance imaging (MRI) showed hyperplasia of the bilateral inferior turbinate and that there was no lesion in the nasal cavity. The T1-weighted signals were isointense (A), the T2-weighted signals were hyperintense, mixed with dotted hypointense (B) and the contrast-enhanced T1-weighted MRI images showed moderate enhancement (C).

lymphoma (nasal type). Magnetic resonance imaging (MRI) showed hyperplasia of the bilateral inferior turbinate, but there was no lesion in the nasal cavity (**Figure 1**). FDG PET/CT showed high FDG uptake only in the right nasal cavity; other parts revealed no increased uptake (**Figure 2**). According to Ann Arbor stage, the patient was in stage I. Thus, the patient received radiotherapy. The total dose was 5014 cGy in 218-cGy fractions delivered over 25 days.

During follow-up, the patient suffered from persistent dry throat. Then, 3 months later, he had persistent irregular hoarseness and bilateral nasal obstruction. At 1 year after the radiotherapy, he had hemoptysis occasionally when he coughed. On January 10, 2013, a video strobolaryngoscope showed that the subglottic area had bleeding and local mucosal edema. MRI of the larynx revealed no abnormality in the larynx. The patient refused to undergo a biopsy of the larynx. On April 23, 2013, FDG PET/CT revealed FDG high uptake in subglottic regions and left cervical lymph nodes (**Figure 3**). The patient was admitted to our department on May 2, 2013, and strobolaryngoscope examination showed a neoplasm with a rough surface below the anterior commissure of the vocal cords. The bilateral vocal cords were smooth and motor function was normal (**Figure 4**). MRI of the larynx showed that the walls of the glottis and subglottis were thickened, showing hyperintensity on T2-weighted imaging. Contrast-enhanced T1-weighted MRI images

demonstrated pronounced enhancement but no enlarged cervical lymph nodes (**Figure 5**). Subsequently, a biopsy was performed by suspension laryngoscopy under general anesthesia. The frozen section indicated hyperplastic lymphoid tissue. Postoperative pathological results revealed that the lesion was composed of diffuse, moderate lymphoid cells, and necrotic tissue. Immunohistochemical results demonstrated that tumor cells were positive for CD56, CD2, CD3, CD5, EBER, and granzyme B, and negative for CD21, CD7, CD10, CD20, and Bcl-6. The Ki67 index was 40%. These results confirmed the tumor to be a laryngeal NK/T-cell lymphoma (nasal type; **Figure 6**).

The patient was referred to the hematology department and received three cycles of the SMILE chemotherapy regimen (methotrexate 3.5 g, intravenously (i.v.), day 1; ifosfamide 2.0 g, i.v., days 2-4; vepeside 150 mg, i.v., days 2-4; dexamethasone (DXM) 40 mg, i.v., days 2-4; L-asparaginase (L-ASP) 3750 U, i.v., day 8). The patient was treated every 4 weeks for three cycles total. However, he then refused further SMILE chemotherapy because of the side-effects, and his chemotherapy regimen was changed to CHOP + L-ASP (cyclophosphamide 1.2 g, i.v., day 1; vincristine 4 mg, i.v., day 1; doxorubicin 120 mg, i.v., day 1; DXM 15 mg, i.v., days 1-2; prednisone 100 mg, i.v., days 3-5; L-ASP 3750 U, i.v., day 5). At 14 months after the completion of chemotherapy, a further FDG PET/CT examination found no evidence of recurrence or metastasis (**Figure 7**).

The diagnostic role of PET/CT

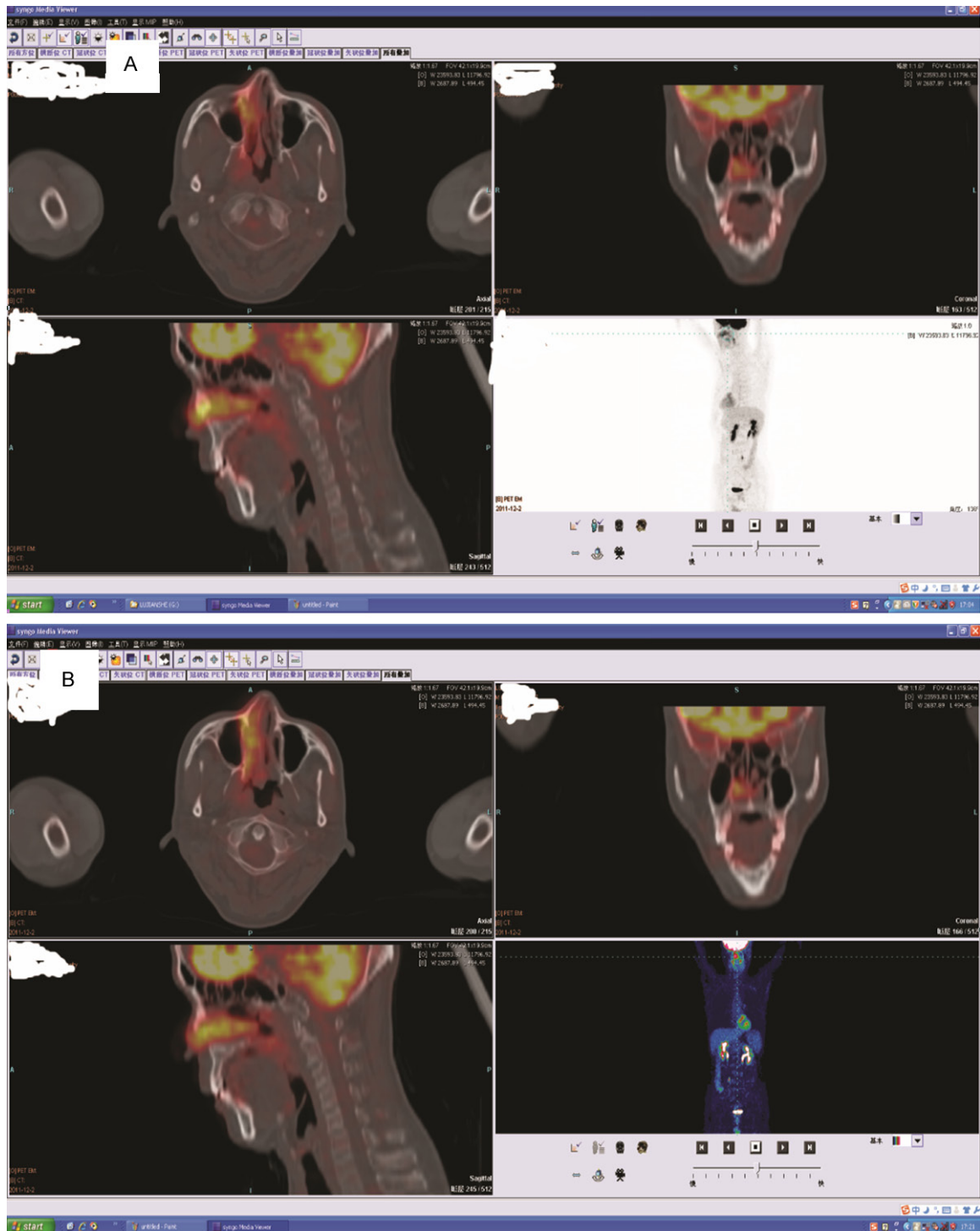


Figure 2. FDG PET/CT showed high FDG uptake only in the right nasal cavity; other parts revealed no increased FDG uptake. Local images of FDG PET/CT, CT and fused PET/CT images demonstrated increased FDG uptake in the right nasal cavity.

Discussion

The nasal type of NK/T-cell lymphoma rarely involves in the larynx. To our knowledge, there are only 13 cases (including this one) of NKTCL

involving the larynx in the English-language literature (**Table 1**). Among them, there were eight males and three females (data about gender were not available for two patients). The male-to-female ratio was thus 8:3. The mean

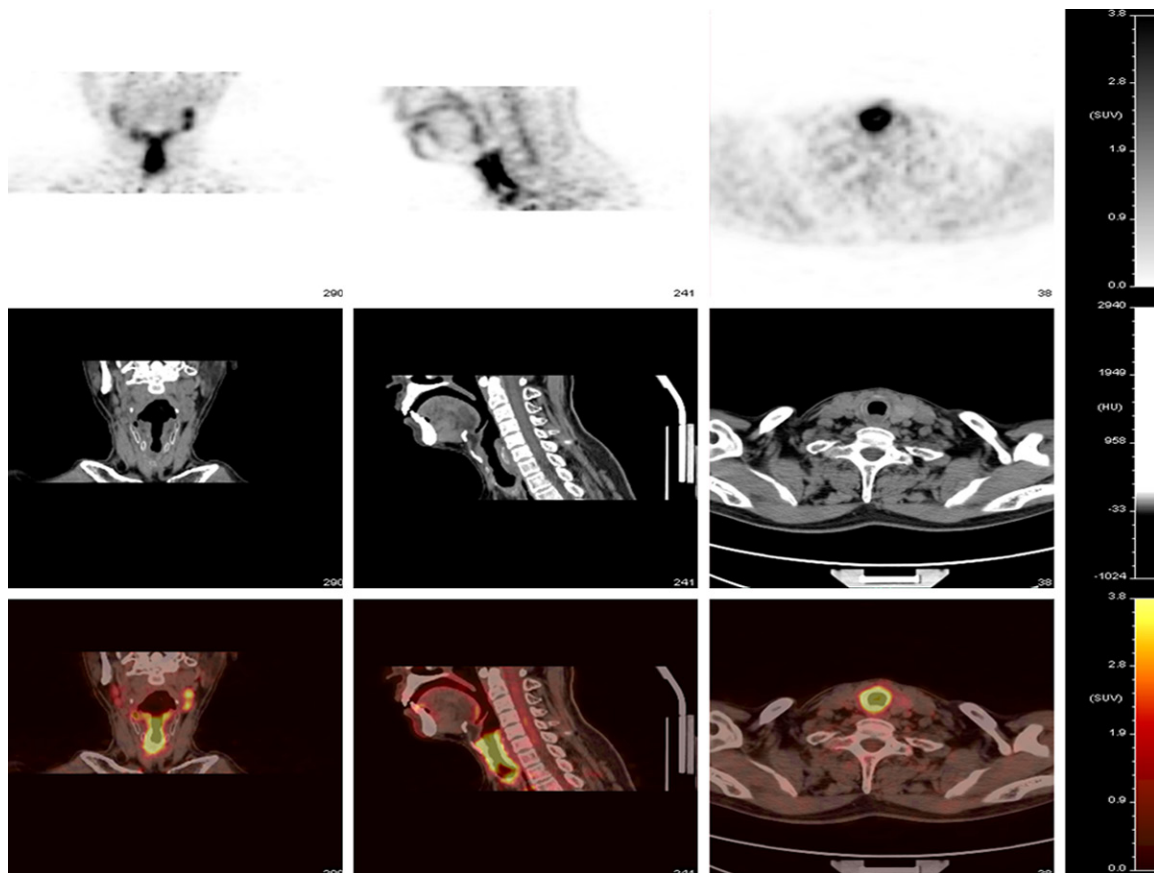


Figure 3. FDG PET/CT showed high FDG uptake only in the subglottic regions and left cervical lymph nodes; other parts revealed no increased FDG uptake. Local images of FDG PET/CT, CT and fused PET/CT images demonstrated increased FDG uptake in the larynx.

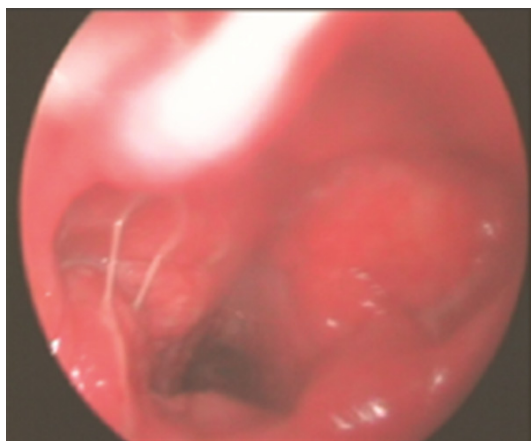


Figure 4. Strobolaryngoscope showed a neoplasm with a rough surface below the anterior commissure of vocal cords.

age was 52.4 years (34-77 years; data were not available for two patients). The primary site was in the larynx in nine patients, and one primary

site was in the skin and disease developed in the larynx at 5 months [9] (data were not available for two patients). In the present case, the lesions were located in the nasal cavity initially and received radiotherapy. However, lesions were found in the subglottic region 1 year after radiotherapy. In nine recorded sites in the larynx, six cases occurred mainly in the supraglottic region, two in the subglottic region, and one in the glottis.

As above, the diagnosis and evaluation of pre-treatment stages are difficult due to the rarity of laryngeal NKTCL. In the 11 recorded cases, hoarseness was the most common symptom, followed by sore throat; only one was accompanied by fever. Some patients underwent multiple biopsies, including our case. Thus, judgment of the lesions is important. Routine work-up including CT and MRI may provide information about the appearance and invasion extent of the lesions [7]. The success of biopsies may

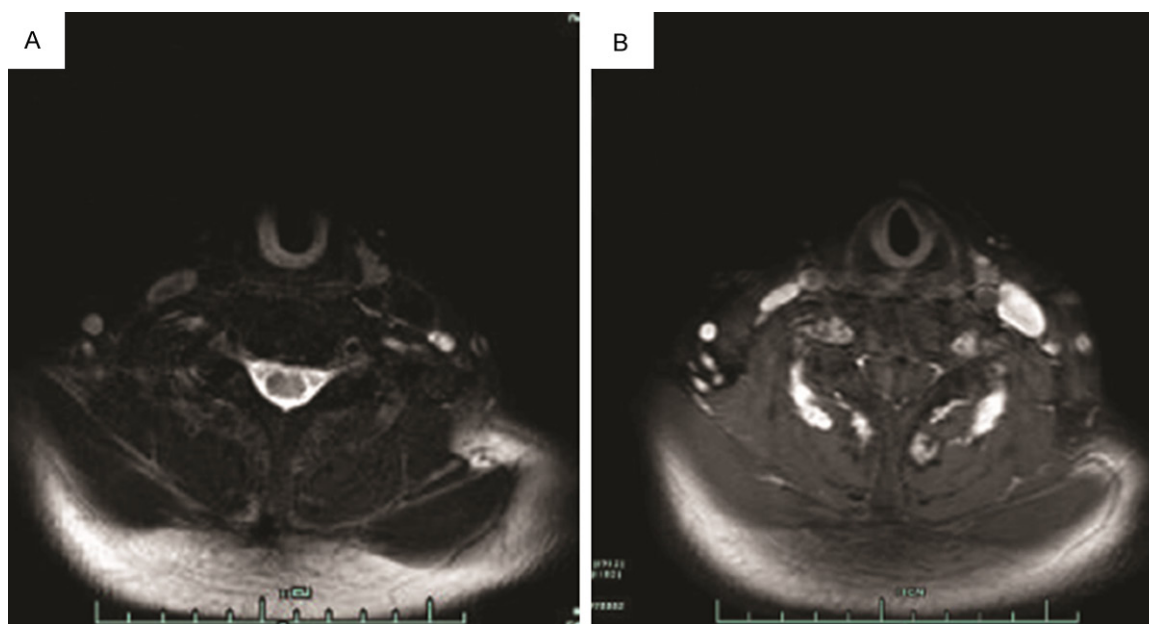


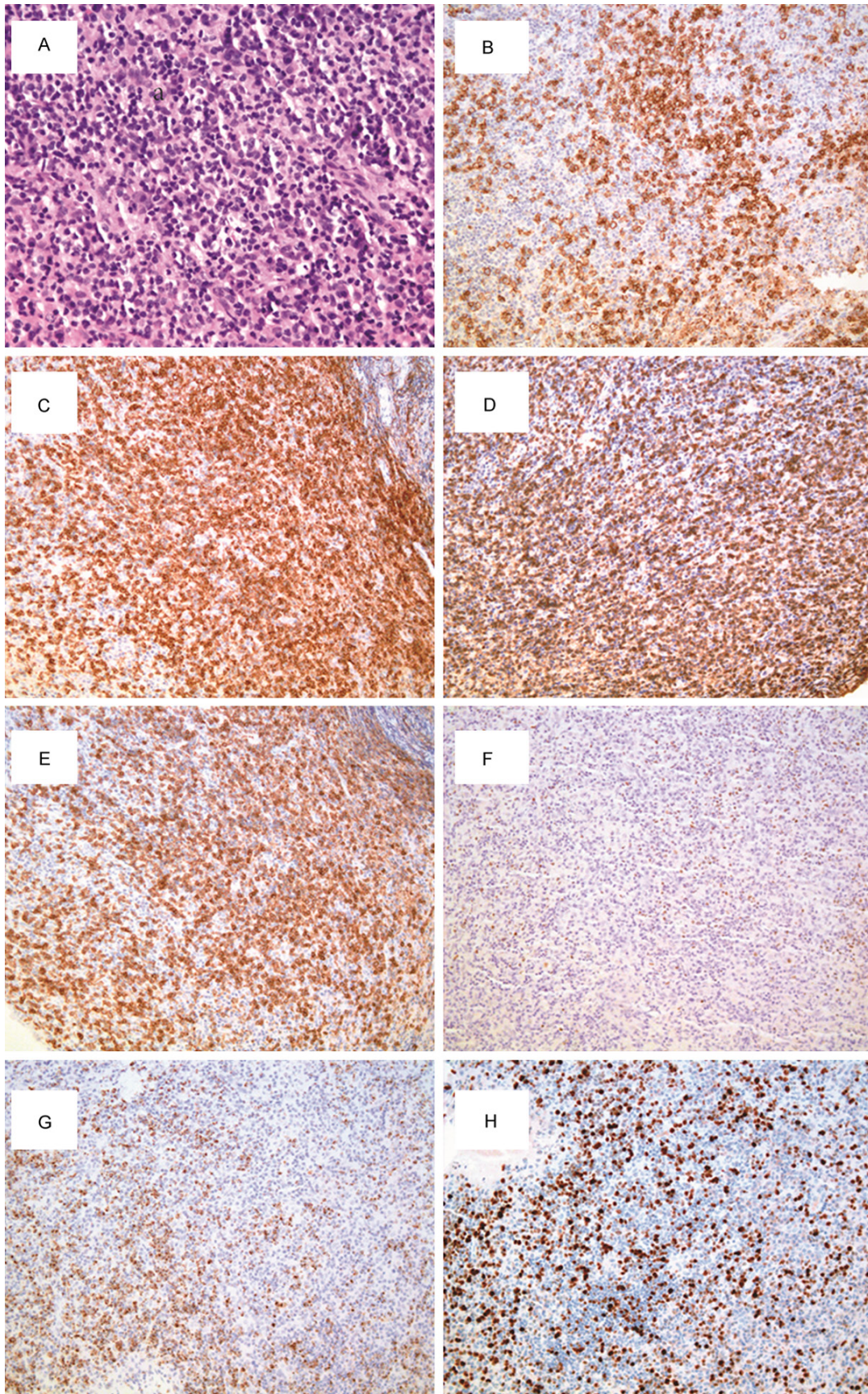
Figure 5. MRI of the larynx showed that the walls of the glottis and subglottis were thickened, showing hyperintensity on T2-weighted images (A). Contrast-enhanced T1-weighted MRI images demonstrated pronounced enhancement and no enlarged cervical lymph node (B).

be increased according to CT and/or MRI findings. However, these routine workups may not be sufficient. Today, PET/CT is not only used as a diagnostic tool but also as a method for staging, restaging, and assessing the response to therapy of various types of lymphoma [11]. PET/CT is widely used in oncology; however, published experience and recommendations on the role of ^{18}F -FDG PET in extranodal natural killer T-cell lymphoma (ENKTL) are limited [12]. As has been reported, NKTCL is intensely FDG-hypermetabolic and high FDG uptake was closely associated with local tumor invasion, contributing to unfavorable treatment and survival outcomes in patients with NKTCL [13]. According to Moon et al., PET/CT scans had better sensitivity than conventional staging methods (CSMs) for the detection of malignant lesions, and PET/CT findings altered the original staging category and treatment planning in some cases [14]. MacDonald et al. reported three cases; PET/CT changed the stage and target volume requiring treatment in two patients. The third patient was unable to tolerate an MRI, but could undergo PET/CT, which improved the accuracy of the target volume [15]. In a prospective study, Khong et al. found an early mid-treatment ^{18}F -FDG PET scan after two or three cycles of chemotherapy to be useful in the prediction of SMILE therapy response in ENKTL

patients and found Deauville score was only predictor of overall survival in ENKTL [16].

In the present case, PET/CT played an important role in the diagnosis, staging, and follow-up. The patient first presented with a nasal obstruction and rhinorrhea with bleeding. At that time, FDG PET/CT showed the lesions were confined to the nasal cavity. Thus, he was diagnosed in stage I, according to the Ann Arbor staging scheme. During follow-up, the patient had dry throat, hoarseness, nasal obstruction, and hemoptysis occasionally when he coughed. A video strobolaryngoscope exam showed subglottic-area bleeding and local mucosal edema, but MRI was apparently normal. The patient refused to undergo a biopsy of the larynx at first. Then, after PET/CT examination, which revealed FDG high uptake in subglottic regions and left cervical lymph nodes, he agreed to the biopsy. The biopsy of the subglottis confirmed NKTCL (stage II). At 14 months after the completion of all therapies, FDG PET/CT found no evidence of recurrence or metastasis.

In conclusion, nasal-type natural killer T-cell lymphoma involving the larynx is rare. PET/CT may be useful in the diagnosis, staging, and follow-up of nasal-type natural killer T-cell lymphoma.



The diagnostic role of PET/CT

Figure 6. Pathological results revealed that the lesion was composed of diffuse, moderate lymphoid cells, and necrotic tissue (A) (hematoxylin and eosin; magnification, $\times 400$). Immunohistochemical results demonstrated that the tumor cells were positive for CD56 (B), CD2 (C), CD3 (D), CD5 (E), EBER (F), granzyme B (G) and Ki67 (H) (magnification $\times 200$, EnVision staining).

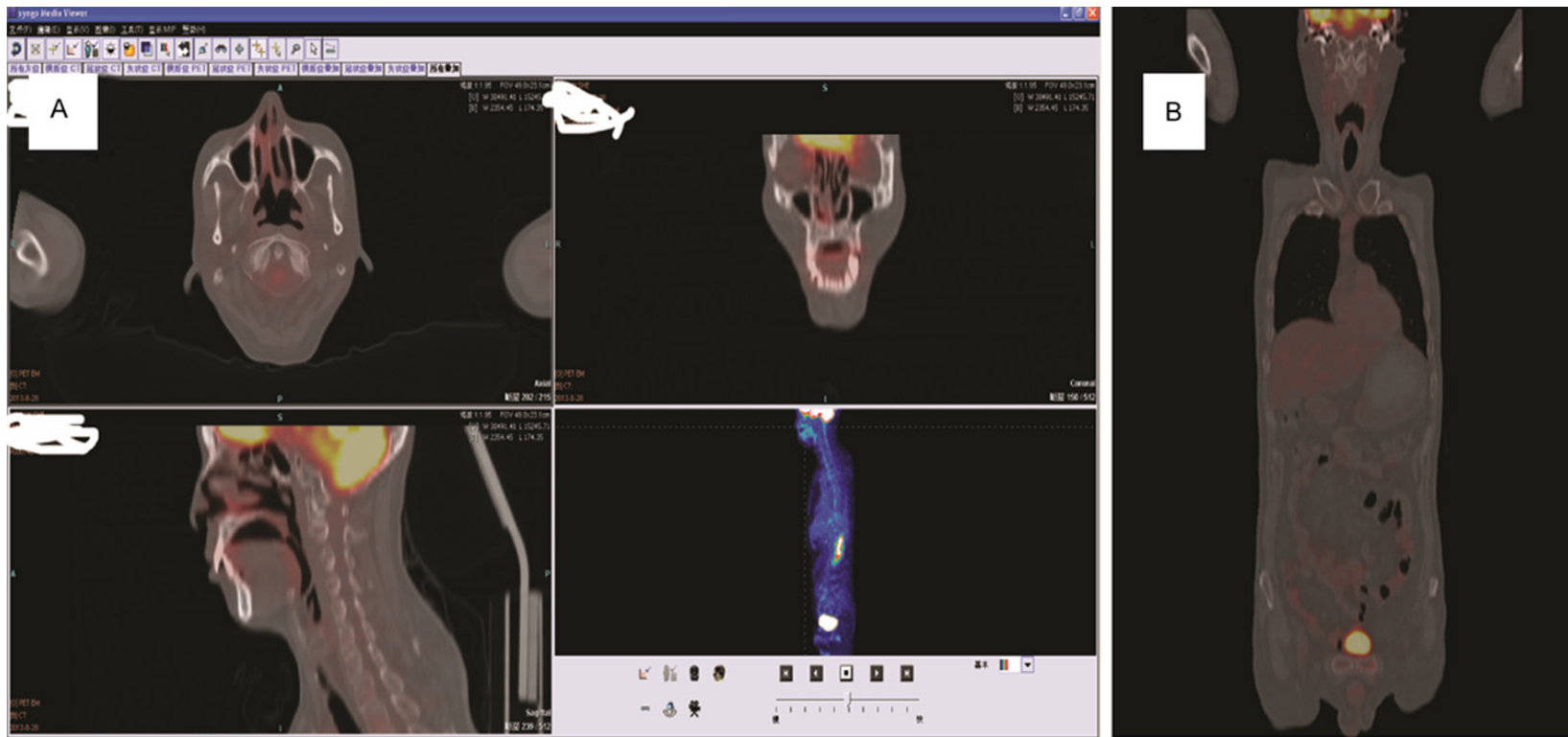


Figure 7. At 14 months after the completion of chemotherapy, FDG PET/CT showed no evidence of recurrence or metastasis. Local images of FDG PET/CT, CT and fused PET/CT images demonstrated no increased FDG uptake in the right nasal cavity (A) or larynx, or in whole-body images (B).

Table 1. The nasal type of NK/T-cell lymphoma

Ref	Pt	Sex/ age	site	symptom	Treatment	Recur- rence	Metastasis	Follow-up
Present case	1	M/59	first occurred in nasal cavity, 17 months later, involving in larynx	nasal obstruction, hoarseness	radiotherapy in nasal cavity, chemotherapy in larynx	No	No	NED, 32 months
Liu 2014	2	NA	NA	NA	NA	NA	NA	NA
Liu 2014	3	NA	NA	NA	NA	NA	NA	NA
Cikojević 2012	4	M/77	supraglottic region	swallowing difficulty, cough, and a foreign-body sensation in his throat	chemotherapy + radiotherapy	No	No	NED, 12 months
Uri 2012	5	M/45	glottis	sore throat, pain on the right side of the neck, hoarseness, and otalgia	CHOP + 60 Gy radiotherapy	No	No	NED, 24 months
Tardío 2008	6	M/34	supraglottic region	lump in the throat, mild sore throat	chemotherapy	No	No	DOD, 6 months
Monobe 2008	7	M/73	supraglottic region	hoarseness, fever	CHOP	No	systemic progressed	DOD, 1.5 months
King 2004	8	F/45	supraglottic region	Sore throat	NA	No	No	NED, 36 months
King 2004	9	F/36	supraglottic region	hoarseness	NA	NA	colonic lymphoma	Died at 2 months
King 2004	10	M/40	supraglottic region	hoarseness	NA	NA	NA	lost to follow-up
Mok 2001	11	F/44	subglottic region	sore throat, hoarseness, and weight loss	CHOP	No	involving in naso-pharynx, skin	DOD, 8 months
Chan 1997	12	M/56	larynx	NA	chemotherapy + radiotherapy	No	relapsed in terminal ileum, mesenteric lymph nodes at 2yr	NA
Chan 1997	13	M/67	Skin, developed disease in larynx at 5 months	NA	Nil	NA	NA	NA

NA: not available, NED: no evidence of disease, DOD: died of disease.

Acknowledgements

This research was supported by the National Natural Science Foundation of China (grant nos. 81172562 and 81372903).

Disclosure of conflict of interest

None.

Address correspondence to: Dr. Shui-Hong Zhou, Department of Otolaryngology, The First Affiliated Hospital, College of Medicine, Zhejiang University, 310003, China. Tel: 86-571-87236894; Fax: 86-571-87236895; E-mail: zhouyunchou@163.com

References

- [1] Turker B, Uz B, Isik M, Bektaş O, Demiroğlu H, Sayinalp N, Uner A, Özcebe Oİ. Nasal Natural Killer/T-cell Lymphoma with Skin, Eye, and Peroneal Nerve Involvement. *Turk J Haematol* 2012; 29: 413-419.
- [2] Liu QF, Wang WH, Wang SL, Liu YP, Huang WT, Lu N, Zhou LQ, Ouyang H, Jin J, Li YX. Immunophenotypic and clinical differences between the nasal and extranasal subtypes of upper aerodigestive tract natural killer/T-cell lymphoma. *Int J Radiat Oncol Biol Phys* 2014; 88: 806-813.
- [3] Cikojevic D, Gluncic I, Pesutic-Pisac V, Klancnik M and Colovic Z. Primary laryngeal NK/T-cell non-Hodgkin lymphoma: a case report. *Ear Nose Throat J* 2012; 9: E10-12.
- [4] Uri N, Schindler Y, Quitt M, Valkovsky O and Barzilai G. Primary NK/T-cell lymphoma of the larynx. *Ear Nose Throat J* 2012; 91: 206-207.
- [5] Tardio JC, Moreno A, Perez C, Hernandez-Rivas JA and Lopez-Carreira M. Primary laryngeal T/NK-cell lymphoma, nasal-type: an unusual location for an aggressive subtype of extranodal lymphoma. *Eur Arch Otorhinolaryngol* 2008; 265: 705-708.
- [6] Monobe H, Nakashima M and Tominaga K. Primary laryngeal natural killer/T-cell lymphoma—report of a rare case. *Head Neck* 2008; 30: 1527-1530.
- [7] King AD, Yuen EH, Lei KI, Ahuja AT and Van Hasselt A. Non-Hodgkin lymphoma of the larynx: CT and MR imaging findings. *AJNR Am J Neuroradiol* 2004; 25: 12-15.
- [8] Mok JS, Pak MW, Chan KF, Chow J and Hasselt CA. Unusual T- and T/NK- cell non-Hodgkin's lymphoma of the larynx: a diagnostic chal-

- lenge for clinicians and pathologists. *Head Neck* 2001; 23: 625-628.
- [9] Chan JK, Sin VC, Wong KF, Ng CS, Tsang WY, Chan CH, Cheung MM, Lau WH. Nonnasal lymphoma expressing the natural killer cell marker CD56: a clinicopathologic study of 49 cases of an uncommon aggressive neoplasm. *Blood* 1997; 89: 4501-4513.
- [10] Zhao K, Luo XM, Zhou SH, Liu JH, Yan SX, Lu ZJ, Yang SY, Lin LL and Dong MJ. ¹⁸F-fluorodeoxyglucose positron emission tomography/computed tomography as an effective diagnostic workup in cervical metastasis of carcinoma from an unknown primary tumor. *Cancer Biother Radiopharm* 2012; 27: 685-693.
- [11] Fang J, Luo XM, Yao HT, Zhou SH, Ruan LX and Yan SX. Expression of glucose transporter-1, hypoxia-inducible factor-1alpha, phosphatidylinositol 3-kinase and protein kinase B (Akt) in relation to [(18)F] fluorodeoxyglucose uptake in nasopharyngeal diffuse large B-cell lymphoma: a case report and literature review. *J Int Med Res* 2010; 38: 2160-2168.
- [12] Karantanis D, Subramaniam RM, Peller PJ, Lowe VJ, Durski JM, Collins DA, Georgiou E, Ansell SM, Wiseman GA. The value of [(18)F] fluorodeoxyglucose positron emission tomography/computed tomography in extranodal natural killer/T-cell lymphoma. *Clin Lymphoma Myeloma* 2008; 8: 94-99.
- [13] Suh C, Kang YK, Roh JL, Kim MR, Kim JS, Huh J, Lee JH, Jang YJ, Lee BJ. Prognostic value of tumor 18F-FDG uptake in patients with untreated extranodal natural killer/T-cell lymphomas of the head and neck. *J Nucl Med* 2008; 49: 1783-1789.
- [14] Moon SH, Cho SK, Kim WS, Kim SJ, Chan Ahn Y, Choe YS, Lee KH, Kim BT, Choi JY. The role of 18F-FDG PET/CT for initial staging of nasal type natural killer/T-cell lymphoma: a comparison with conventional staging methods. *J Nucl Med* 2013; 54: 1039-1044.
- [15] MacDonald SL, Mulroy L, Wilke DR and Burrell S. PET/CT aids the staging of and radiotherapy planning for early-stage extranodal natural killer/T-cell lymphoma, nasal type: a case series. *Radiat Oncol* 2011; 6: 182.
- [16] Khong PL, Huang B, Phin Lee EY, Sum Chan WK and Kwong YL. Midtreatment 18F-FDG PET/CT Scan for Early Response Assessment of SMILE Therapy in Natural Killer/T-Cell Lymphoma: A Prospective Study from a Single Center. *J Nucl Med* 2014; 55: 911-916.