

Original Article

Reconstruction of attached soft tissue around dental implants by acellular dermal matrix grafts and resin splint

Changying Liu¹, Yucheng Su², Baosheng Tan¹, Pan Ma¹, Gaoyi Wu³, Jun Li¹, Wei Geng¹

¹Department of Dental Implantology Centre, School of Stomatology, Capital Medical University, Beijing 100050, China; ²Department of Dental Implantology of Peking Union Medical College Hospital, Beijing 100032, China; ³Department of Stomatology, Jinan General Military Hospital, Jinan 250031, China

Received October 2, 2014; Accepted November 13, 2014; Epub December 15, 2014; Published December 30, 2014

Abstract: Objectives: The purpose of this study was to recommend a new method using acellular dermal matrix graft and resin splint to reconstruct the attached soft tissue around dental implants in patients with maxillofacial defects. Materials and methods: Total 8 patients (3 male and 5 female patients) diagnosed with maxillofacial defects and dentition defects caused by tumors, fractures or edentulous jaw, were selected for this study. Dental implants were routinely implanted at the edentulous area. Acellular dermal matrix heterografts and resin splint were used to increase the attached soft tissue. The width of attached gingiva in the labial or buccal surface at edentulous area was measured before surgical procedures and after the completion of superstructures. Paired t-test was applied to assess the change of quantitative variables. All tests were 2-tailed, and $P < 0.05$ was considered statistically significant. Results: The dense connective tissue around implants could be reconstructed one month after the completion of surgical procedures, and the epithelial cuff around the implant neck established very well. The width of attached gingival tissue in the patients increased significantly from a mean of 0.61 ± 0.75 mm to 6.25 ± 1.04 mm. The patients were fully satisfied with the esthetic and functional results achieved. Conclusions: The acellular dermal matrix graft could be used to increase the attached gingiva around dental implants in these patients with maxillofacial defects. The resin splint could facilitate the healing of graft.

Keywords: Peri-implant attached soft tissue, implant, acellular dermal matrix, resin splint, maxillofacial defect, soft

tissue reconstruction

Introduction

Dental implantation allowing stabilization of prosthesis in terms of function and aesthetics is now considered to be a routine procedure with high success rates in patients with maxillofacial defect. The reconstruction of maxillofacial defects can be achieved by reconstructive surgical techniques, such as vascularized free bone flaps, and guided bone regeneration (GBR). However, the lack of keratinized soft tissue in the peri-implant area is still one of the biggest challenges in these cases [1]. It has been well documented in the literature that keratinized tissue around dental implants helps to maintain patient comfort, facilitating impression taking by the restorative dentist as well as helping to maintain oral hygiene [2, 3]. To incr-

ease keratinized tissue around teeth and dental implants, several techniques have been proposed in the literature [4]. Soft tissue ridge augmentation using autogenous palatal grafts has been thoroughly documented in the management of residual ridge defects [5, 6]. However, the autogenous gingival graft procedure requires an additional surgical wound, and the amount of graft is limited because of the donor site.

Recently, an acellular dermal matrix (ADM) allograft was approved as a substitute for autogenous grafts [7, 8]. The acellular dermal matrix allograft is processed from human or mammal donor skin, and prepared by removing the epidermis and cellular components of the skin [9]. ADM allografts have been used in dentistry for the correction of gingival recession [10, 11] and

Peri-implant soft tissue reconstruction

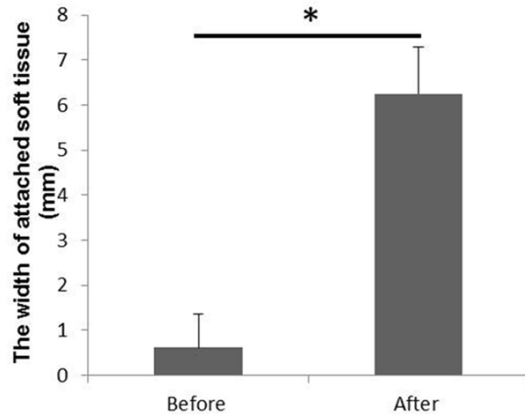


Figure 1. The measurement of the width of attached soft tissue in the labial or buccal surface at edentulous area. Values are expressed as mean \pm SD. *: Paired t-test ($P < 0.05$, $t = -11.656$).

guided bone regeneration [12, 13]. Fetal bovine acellular dermal xenografts have also been used with tissue expansion in staged breast reconstruction and in treatment of burns [14, 15]. Thus far, there have been few reports of keratinized gingival tissue reconstruction using fetal bovine acellular dermal matrix (FBADM) grafts. However, how to fix the graft to facilitate the wound healing still disturbs clinic dentists.

Eight patients were presented in this study. They were diagnosed with maxillofacial defects and dentition defects lack of attached gingiva and keratinized soft tissue. Heterogeneous acellular dermal matrix grafts and resin splint were used to reconstruct and increase the attached soft tissue at the peri-implant region in these cases. The width of attached gingival tissue in the patients increased significantly and the patients were fully satisfied with the aesthetic and functional results achieved. This article will introduce this method to reconstruct the attached soft tissue around dental implants.

Materials and methods

The protocol of the study was approved by the ethical committee of the Capital Medical University.

Total 8 patients (3 male and 5 female patients) were selected for this study, aged between 22 to 60 years (mean age 39.5 ± 13.19 years) from the Department of Dental Implantology Centre of Beijing Stomatological Hospital.

Case inclusion criteria: (1) Patients diagnosed with maxillofacial bone defects and dentition defects caused by tumors, fractures or edentulous jaw. (2) Patients with less than 2.0 mm thickness of keratinized tissue on the buccal surface and vestibulum depression at the edentulous area. (3) Patients voluntarily agreed to have dental implant treatment. (4) Patients agreed and accepted two-stage operation with heterogeneous ADM graft. (5) Patients consented to all the surgical procedures prior to treatment.

Case exclusion criteria: (1) Uncooperative patients were excluded. (2) Patients with poor general condition were not approved to undergo surgical procedures.

First, bone defects were reconstructed and dental implants (Straumann, Swiss; or BEGO, German) were routinely implanted at the edentulous area according to different cases. Following a healing period of six months, the osseointegration was achieved well between implants and bone. Two-stage operation was then prepared.

Operative and surgical procedure

Surgical procedures: After 0.12% chlorhexidine solution mouth rinse and routine sterilization, Primacaine (4% Articaine with 1:100,000 epinephrine) local anesthetic was injected. A crestal incision was made with a No.15 surgical blade at the alveolar ridge. According to vestibuloplasty, vertical incisions were made on either side of the horizontal incision which would further facilitate to remove the mucosal tissue. Then partial thickness flap was thoroughly raised on the periosteal bed to the base of vestibulum. After the implants were exposed, impression was immediately taken. Meanwhile the resin splint was prepared by another dentist. The patients then received acellular dermal matrix heterograft (Heal-all®, Zhenghai Biotechnology Co., Ltd., Yantai, China) according to the range of the defect. The size of the ADM grafts needed to be 2 to 3 mm larger than the defects. The graft previously rehydrated in sterile saline for 5 minutes was firmly placed on the periosteal bed and secured to the periosteum and surrounding connective tissue by absorbable sutures (**Figures 2B, 2C, 7B, 7C**). Two layers of iodoform gauze were placed on the surface of graft. Both graft and iodoform gauze

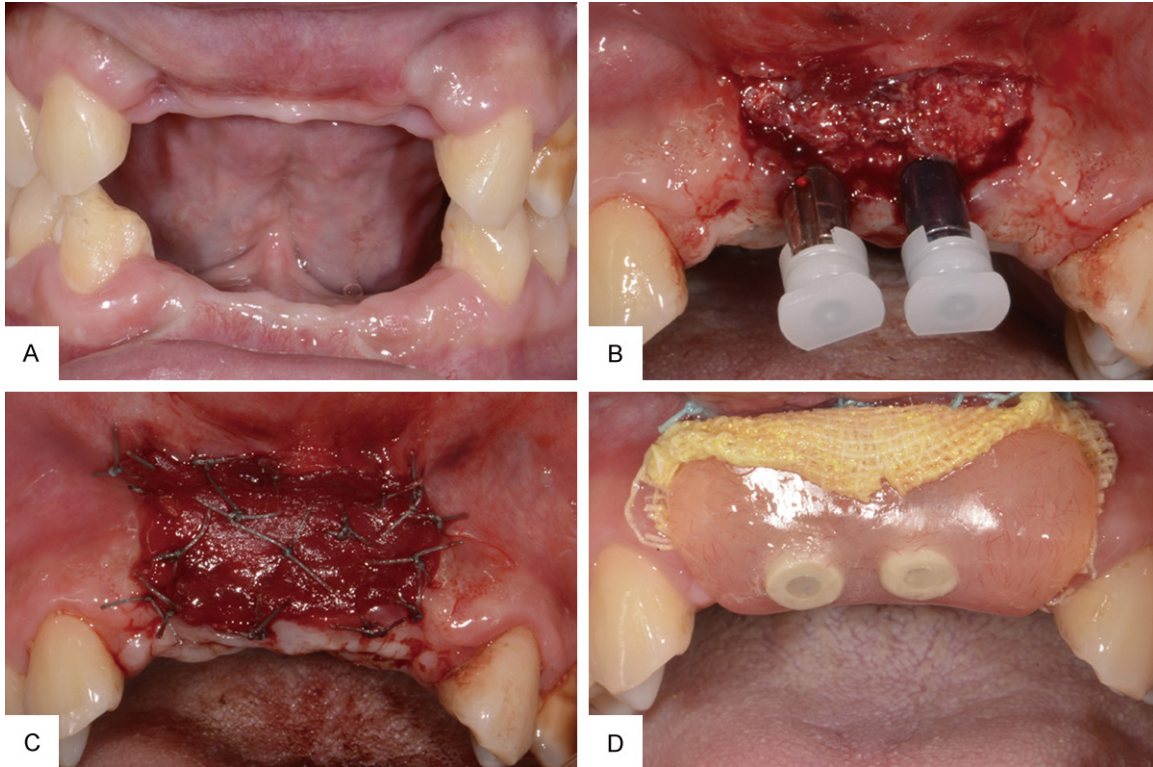


Figure 2. A. Patient was missing two maxillary central, two maxillary lateral, four mandibular incisors and mandibular left canine with residual ridges resorption at the edentulous area. No keratinized gingival tissue could be found in the labial or buccal surfaces of residual ridges and the vestibulum disappeared at the edentulous area. B. A crestal incision was made and partial thickness flap was thoroughly raised on the periosteal bed and impression was taken immediately. C. The acellular dermal matrix graft was firmly placed on the periosteal bed and secured to the periosteum by absorbable sutures. D. The graft and iodoform gauze were stabilized with the prepared resin splint.

were stabilized by the prepared resin splint (**Figures 2D, 7D**). Then the resin splint was screwed to the implants.

Preparation of resin splint: Plaster model was casted in the impression taken during the surgery. Two or three temporary abutments were ground to an appropriate height and screwed to the dental implants on the plaster model. A layer of wax (about 2 mm thickness) was coated uniformly in the area of defect to make space for ADM graft. A piece of resin (GC, Japan) was coated at the defect region on the model and adjusted to 2-3 mm in thickness. In addition, the size of the resin should be adjusted according to the range of the defect in order to cover the entire mucosa defect. Then the resin was gently pressed to integrate with temporary abutments tightly. At last, the resin splint was solidified by light-cure. After abutment was unscrewed, the resin splint was separated from the model (**Figure 3**). The resin splint was then finalized by polish and sterilization and ready for next procedure.

Postoperative instructions: Azithromycin and Ibuprofen were prescribed to prevent post-operative complications. The healing was uneventful. Patients were seen and the iodoform gauze was changed per triduum in the first week (**Figures 4A, 7E, 7F**), then once a week for follow-up to monitor healing (**Figure 7G**) and plaque control. Three weeks after the second surgical procedure, the resin splint and remaining sutures were removed, and the grafted area was carefully cleaned with 0.12% chlorhexidine solution. Then healing abutments were screwed to the implants (**Figures 4B, 7H**). Three to four weeks after the resin splint were removed, impression was taken and prosthesis was delivered.

Measurement methods

The width of attached gingiva in the labial or buccal surface at edentulous area was measured before the surgical procedures and after the completion of superstructures. The dista-

Peri-implant soft tissue reconstruction

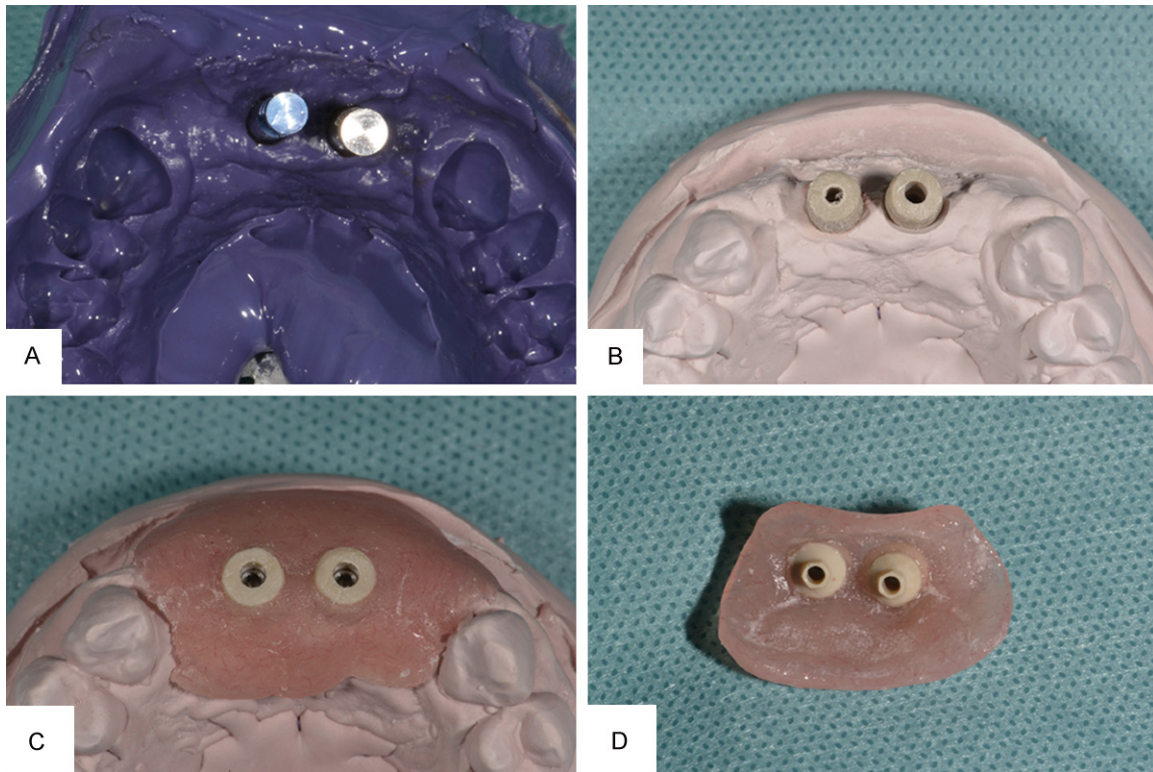


Figure 3. A. Impression was taken. B. Custom-designed abutments were used. C. The resin splint was manufactured. D. The resin splint.

Table 1. The characteristics of patients

| Patient No | Age (ys) | Sex | Recipient sites (FDI) | Defect region (FDI) | Causes of maxillofacial defects | Dental implant system | Follow-up after implants placement (months) |
|------------|----------|-----|-----------------------|---------------------|---------------------------------|-----------------------|---|
| 1 | 30 | M | 11, 21, 31, 33, 42 | 12-22; 42-33 | fracture | BEGO | 13 |
| 2 | 22 | F | 32, 41, 42, 43, 44 | 45-32 | epulis | Straumann | 48 |
| 3 | 47 | F | 32, 34, 35, 43 | 43-36 | ameloblastoma | Straumann | 24 |
| 4 | 43 | M | 11, 12, 14, 21, 22 | 14-22 | fracture | Straumann | 36 |
| 5 | 52 | F | 33, 43 | 47-37 | edentulous jaw | BEGO | 24 |
| 6 | 27 | M | 31, 32, 33, 42 | 43-33 | fracture | Straumann | 30 |
| 7 | 60 | F | 33, 43 | 47-37 | edentulous jaw | Straumann | 30 |
| 8 | 35 | F | 32, 41, 42, 45 | 32-45 | ameloblastoma | Straumann | 19 |

nance was measured from alveolar ridge crest to mucogingival junction before the surgical procedure. The distances were recorded zero in 3 patients with no attached tissue at the edentulous area. After the completion of superstructures, the distance was measured from the epithelial cuff around the implant neck to mucogingival junction. The measurements were recorded at 3 locations around each implant.

Statistical methods

Paired t-test was applied to assess the change of quantitative variables. All tests were 2-tailed,

and $P < 0.05$ was considered statistically significant.

Results

There were 8 patients (3 male and 5 female patients), aged between 22 to 60 years (mean age 39.5 ± 13.19 years) who received acellular dermal matrix heterograft (Table 1). The soft tissue healing was uneventful. None of the patients had postoperative complications except mild pain and/or swelling. The dense connective tissue around implants was reconstructed one month after the completion of surgical procedures, and the epithelial cuff around the im-

Peri-implant soft tissue reconstruction

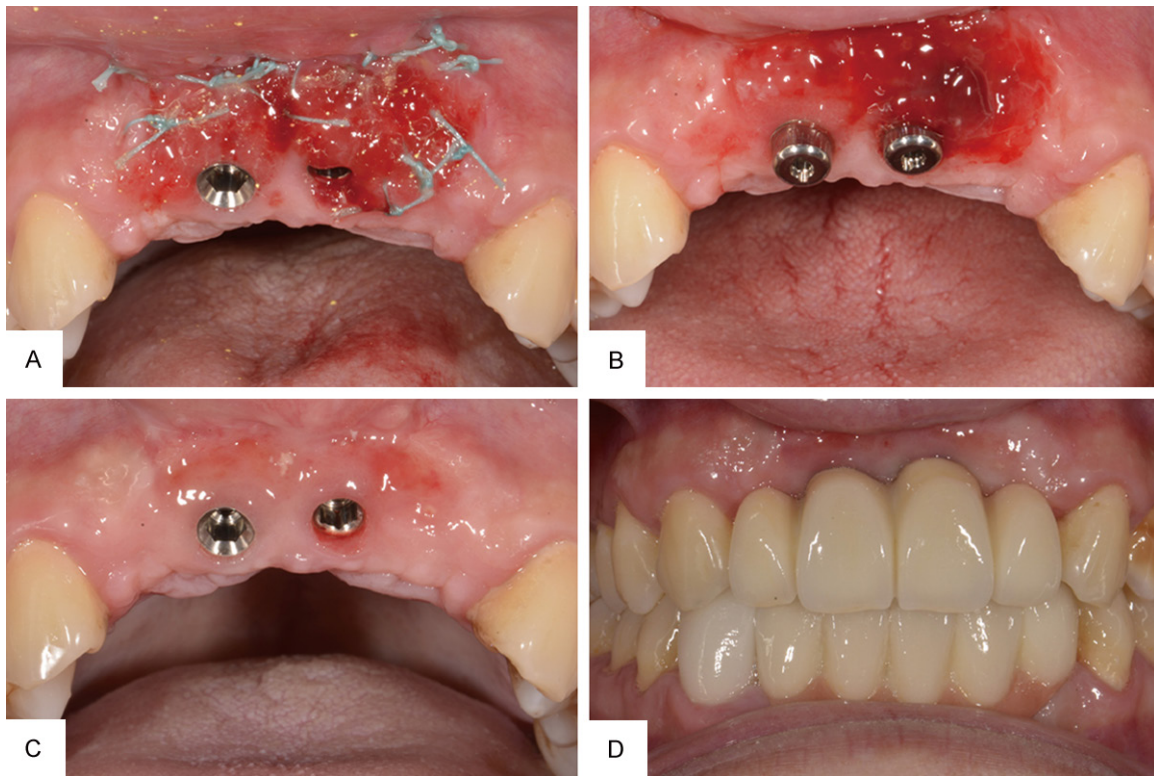


Figure 4. A. Well healing graft at one week follow-up. B. New vascularization could be found following a healing period of three weeks. Healing abutments were screwed to the implants. C. The dense connective tissue around implants could be found and the vestibular depth notably increased. Epithelial cuff around implant neck established well. D. Completed superstructure.

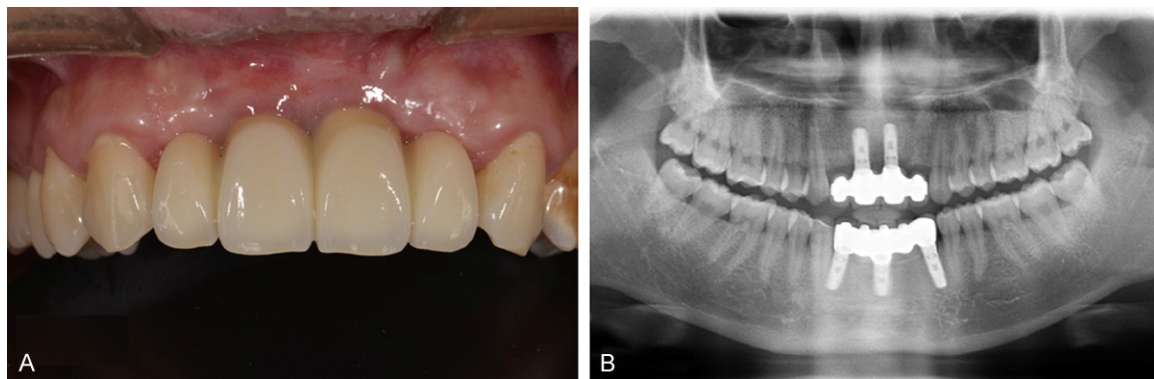


Figure 5. A. Thirteen months after implants placement. B. Thirteen months after implants placement, panoramic radiographs revealed good osseointegration with no bone resorption around implants.

plant neck established very well. The width of attached gingival tissue in the patients increased significantly from a mean of 0.61 ± 0.75 mm to 6.25 ± 1.04 mm (**Figure 1**).

Cases descriptions and results

Two cases were introduced in this study, including different attached soft tissue defects in the maxilla and mandible.

Case 1: A 30-year-old male patient with anterior teeth loss and alveolar bone defects caused by maxillofacial trauma was referred to Department of Dental Implantology Centre of Beijing Stomatological Hospital on October 2012, after 3 months period of wound healing. Clinical examinations revealed two maxillary central incisors, two maxillary lateral incisors and four mandibular incisors and mandibular left canine

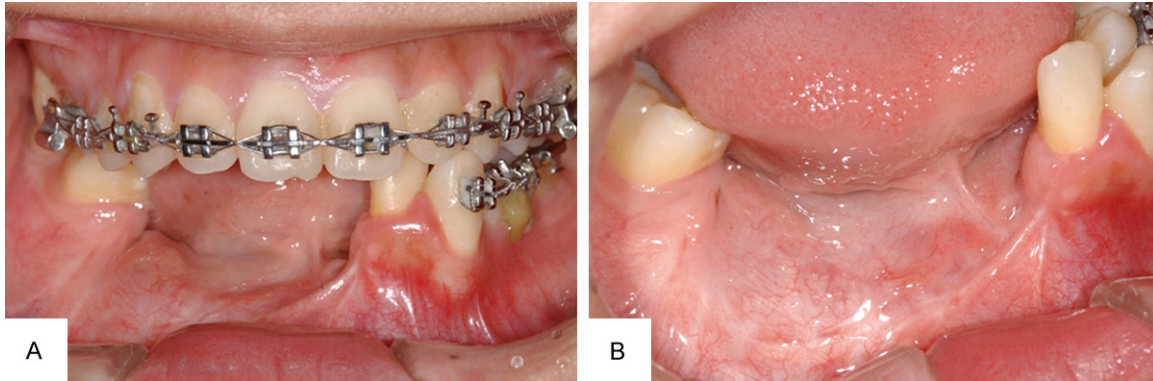


Figure 6. A. Symphysis and part of the right-side body of the mandible defect was found from mandibular left central incisor to mandibular right second premolar. Brackets were bonded on the residual teeth in maxillary and mandibular. The occlusal relationship was desirable, and orthodontic treatment procedure was going to the retention phase. B. No keratinized gingival tissue could be found on the surfaces of residual ridges and the vestibulum disappeared at the edentulous area.

missing and residual ridges resorption at the edentulous area. No attached gingival tissue could be found in the labial or buccal surfaces of residual ridges and the vestibulum disappeared at the edentulous area in the maxilla (**Figure 2A**). A multidisciplinary treatment approach was planned including guided bone regeneration, dental implants insertion and attached soft tissue reconstruction with acellular dermal matrix graft. Five dental implants were routinely implanted with two implants placed in the site of maxillary central incisors. The acellular dermal matrix graft was firmly placed on the periosteal bed and secured to the periosteum by absorbable sutures (**Figure 2B, 2C**). The graft and iodoform gauze were stabilized with the prepared resin splint (**Figure 2D**). One week follow-up the graft healed well, and new vascularization could be found following a healing period of three weeks. One month later, the dense connective tissue around implants could be observed. The vestibular depth notably increased and the epithelial cuff around the implant neck established very well (**Figure 4C**). At last, the superstructures were completed (**Figure 4D**). The patients were fully satisfied with the esthetic and functional results achieved (**Figure 5**).

Case 2: A 22-year-old female patient, diagnosed with epulis in the right side of mandible by Department of oral and maxillofacial surgery in 2005, with two mandibular central incisors and two mandibular lateral incisor, mandibular right canine and mandibular right premolars extracted, received a square mandibulectomy. Six months later, the patient received removable partial denture. The patient was referred to Department of Dental Implantology in May of 2008. Clinical and radiographic examinations revealed symphysis and part of the right-side body of the mandible defect from mandibular left lateral incisor to mandibular right second premolar (**Figure 6**), and the height of the alveolar bone at the edentulous area was 5 mm lower than adjacent alveolar bone (**Figure 9A**). No attached gingival tissue could be found on the surfaces of residual ridges and the vestibulum disappeared at the edentulous area. A multidisciplinary treatment approach including Sandwich bone grafting with free iliac crest bone (**Figure 9B**), rehabilitation of the dentition with dental implant supported fixed restoration, and attached soft tissue reconstruction with acellular dermal matrix graft were planned. Three months after surgical procedure, the dense connective tissue around implants was noticed and the vestibular depth was significantly increased. The epithelial cuff around the implant neck was established very well (**Figure 8D**). In one year follow-up, clinical examination (**Figure 10A**) and panoramic radiographs revealed bone graft healed well with good osseointegration. There was no bone resorption around implants (**Figure 10B**).

Discussion

Long-term stability of the dental implant not only depends on the osseointegration between implant and bone, but also depends on the soft tissue condition around the dental implant.

Peri-implant soft tissue reconstruction

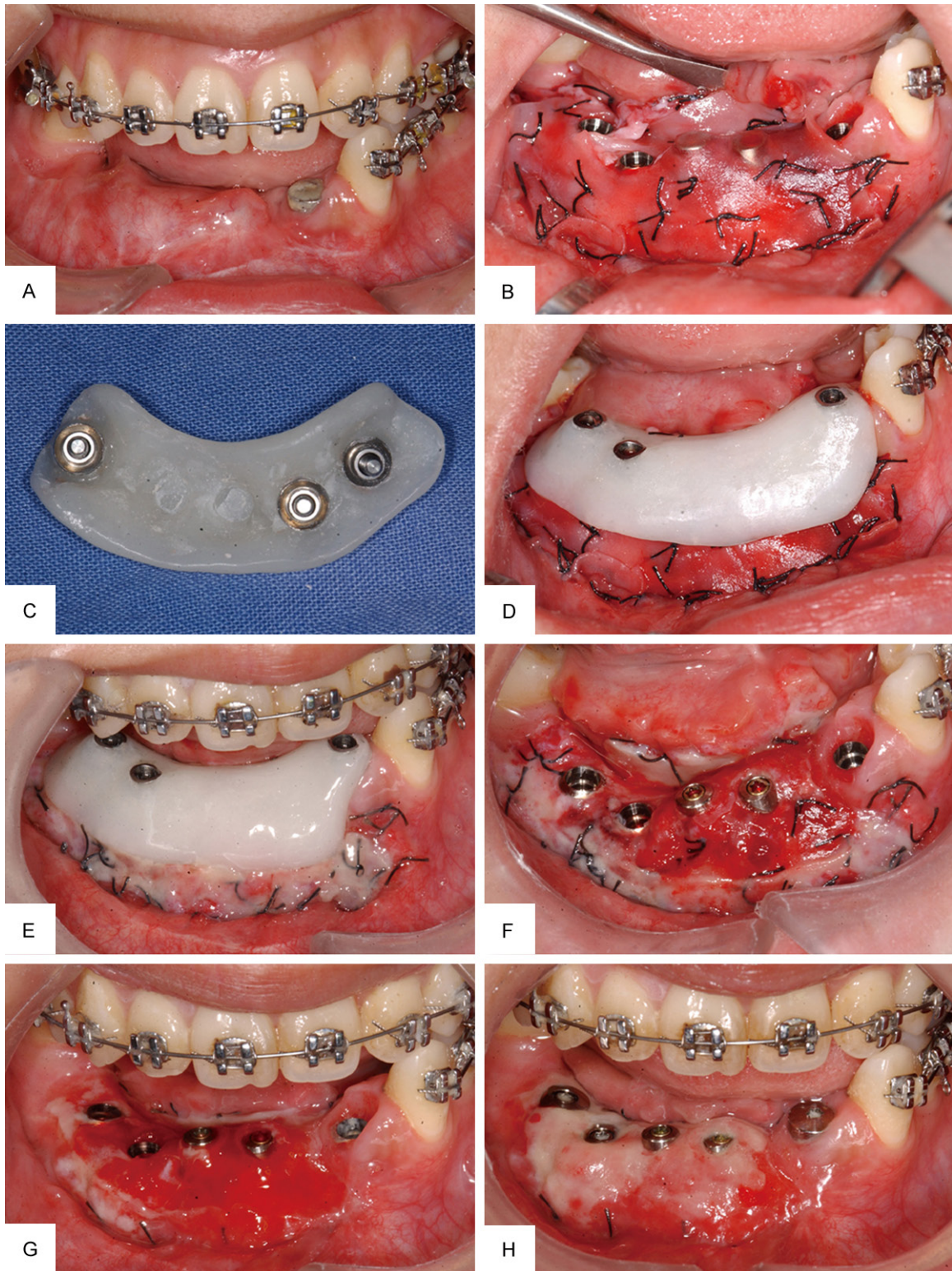


Figure 7. A. Five endosseous dental implants were placed into the mandible. B. Acellular dermal matrix graft was firmly placed on the periosteal bed and secured to the periosteum by absorbable sutures. C. The resin splint was manufactured. D. The graft was stabilized with the prepared resin splint. E. One week after the surgical procedure, oral hygiene was well maintained. F. One week follow-up the graft was healing well. G. New vascularization could be found following a healing period of two weeks. H. New dense connective tissue around implants could be found at three weeks follow-up.

Peri-implant soft tissue reconstruction

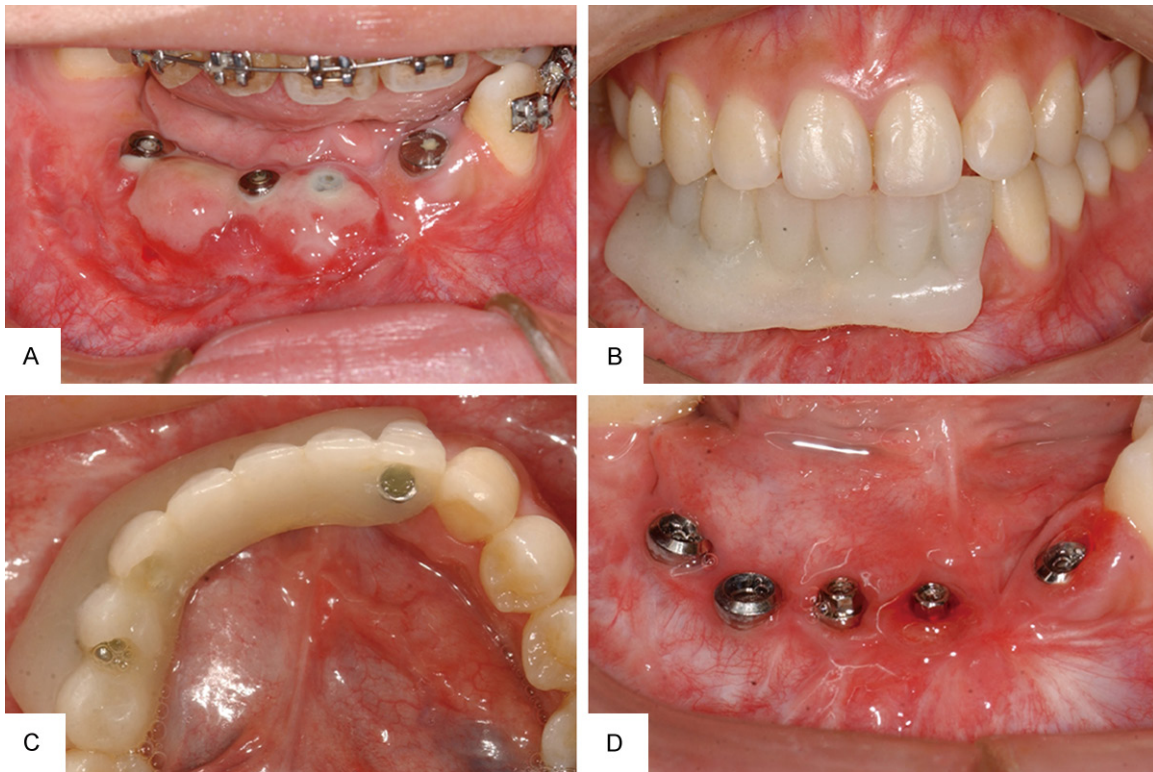


Figure 8. A. One month later, dense connective tissue around implants could be found and the vestibular depth notably increased. B. New transition denture was manufactured to maintain the vestibular depth, and to keep the edentulous space. C. The new transition denture was screwed to the implants. D. The 3-month follow-up postprocedure, the epithelial cuff around implant neck was well established.

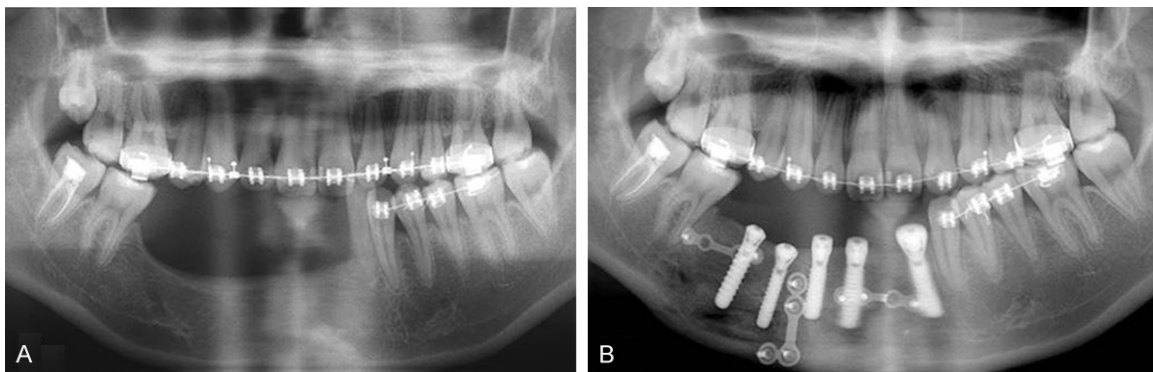


Figure 9. A. Panoramic radiographs revealed the height of the alveolar bone at the edentulous area was 5 mm lower than adjacent alveolar bone. B. Panoramic radiographs revealed good osseointegration between implants and bone before two stage operation.

Tooth loss accompanied by attached gingival tissue defect, especially in these cases caused by maxillofacial tumors, maxillofacial fracture or edentulous jaw, presents a significant clinical problem. Free gingival grafts, autogenous palatal grafts and subepithelial connective tissue grafts could be used to increase the width of keratinized tissue. Han et al have shown the

use of free soft tissue grafts to augment keratinized gingiva before or following the restoration of an implant [16]. However, the autogenous graft procedure requires an additional surgical wound that may cause certain degree of discomfort and increase the risk of postoperative complications such as pain and hemorrhage, and the amount of graft is limited be-

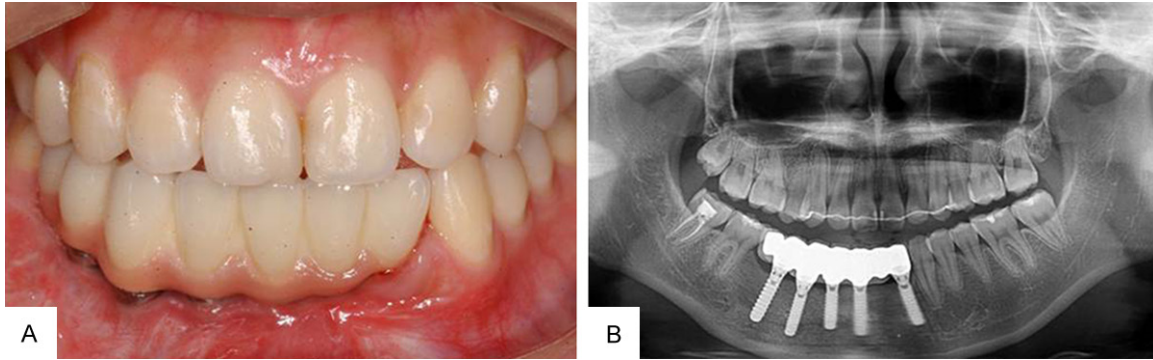


Figure 10. A. One year follow-up after the superstructure was completed. B. One year follow-up after the superstructure was completed, panoramic radiographs revealed bone graft healed well, with good osseointegration. There was no bone resorption around implant.

cause of the donor site especially when the range of the keratinized tissue defect is large.

In an effort to avoid second surgical site for harvesting the autogenous tissue graft from the palate, to reduce potential morbidity, and to treat a wider array of defects, different biomaterials such as acellular dermal matrix (ADM) graft have been tried. The acellular dermal matrix graft is processed from human [1, 7, 8] or mammal [14, 15] donor skin. All epidermal and dermal cells are removed from donated tissue. ADM retains all of the critical features for tissue regeneration, including tissue structure and biochemistry. It is comprised of a structurally integrated basement membrane complex and extracellular matrix in which collagen bundles and elastic fibers are the main components. ADM is an acellular dermal matrix designed to serve as a biologic scaffold for normal tissue remodeling. ADM contains both the structure and the biochemical information to direct normal revascularization and cell repopulation because blood vessels, collagens, proteoglycans, and elastin are preserved. This extracellular matrix contains the blood vessel channels that serve as conduits for revascularization; collagens, proteoglycans, and elastin provide structure and information for cell repopulation [7, 17]. The ADM graft which is rich in collagen has been increasingly suggested in both medicine and dentistry for plastic and reconstructive surgery applications. ADM graft has been used for a variety of purposes including correction of gingival recession [10, 11, 18] and guided bone regeneration [12, 13]. Koudale found that the use of ADMA eliminated the need for the palatal donor site thus represented a less invasive

surgery for treating multiple gingival recessions [19]. Meanwhile ADM allograft (i.e. AlloDerm®) has been used to increase the width of keratinized tissue around dental implant [1]. It has been shown that the acellular dermal matrix allograft could be applied as a grafting material to increase the width of peri-implant keratinized mucosa. This procedure appears to have some benefits for oral hygiene [8].

Comparing to the autogenous tissue, ADM graft is easy to obtain, and the amount of graft is unlimited. Acellular dermal matrix heterograft (Heal-all®, Zhenghai Biotechnology Co., Ltd., Yantai, China) was used in this study. It is processed from bovine donor skin. The ADM graft is rich in type-I and type-III collagen and it can maintain its ultrastructural acellular matrix integrity without provoking inflammatory response in host tissues and immunologic rejection due to low immunogenicity. In addition to type I collagen, the primary collagen of human skin, fetal bovine ADM is rich in type III collagen. Type III collagen plays a critical role in the cellular activities during tissue formation and regeneration in the early phases of wound healing [20]. Endress [14] had used fetal bovine acellular dermal xenograft with tissue expansion for staged breast reconstruction. Their study found that fetal bovine ADM significantly reduced wound drainage time.

In this study, the soft tissue healing was uneventful, and no patients had postoperative complications except mild pain and/or swelling. One month after surgical procedure, the width of attached tissue increased significantly, and the epithelial cuff around the implant neck established very well. At six months and long te-

rm follow-up, the width of attached tissue reconstructed by ADM had a little shrinkage, but peri-implant tissue health was achieved and maintained during the follow-up period. The size of ADM graft we selected was bigger than the range of defect.

Traditionally, the autogenous palatal grafts were stabilized with thick package of iodoform gauze and sutured to periosteum and surrounding connective tissue. In this study, a resin splint was manufactured using temporary abutments to fix the graft and iodoform gauze. The splint with thin layer of iodoform gauze facilitated dressing changes and monitoring of graft healing. The resin splint was fitting to the defect reduced wound drainage time and facilitated the graft healing. Interim or transition dentures at the splint can also be manufactured to lessen the time without denture (**Figure 8B**). This treatment was also used in the patient with edentulous jaw. The vestibular depth could be notably increased in these patients. In addition, the splint size is small enough to minimize foreign body sensation in the patient's oral cavity. In this study, oral hygiene procedures can be facilitated by the splint. Finally, all the patients were fully satisfied with the aesthetic and functional results achieved.

In conclusion, the acellular dermal matrix graft could be used to increase the attached gingiva around dental implants in patients with maxillofacial defects. And the resin splint screwed to dental implants facilitated the healing of graft. The patients were fully satisfied with the esthetic and functional results achieved.

Acknowledgements

This work was supported by grants from the National Natural Science Foundation of China (81371115 to J.L.) and the Capital Medical Development Foundation of China (2009-3143 to W.G.) and Beijing Capital Medical University Fund for basic and clinical medicine research (13JL83 to P.M.).

Disclosure of conflict of interest

None.

Address correspondence to: Dr. Wei Geng or Dr. Jun Li, Department of Dental Implantology Centre, School of Stomatology, Capital Medical University,

Beijing 100050, China. Tel: 86-10-57099170; Fax: 86-10-57099170; E-mail: gengwei717@aliyun.com (WG); lijun3021@aliyun.com (JL)

References

- [1] Buyukozedemir Askin S, Aksu AE, Calis M, Tulunoglu I, Safak T, Tozum TF. Multidisciplinary treatment of an extensive mandibular ameloblastoma with free iliac crest bone flap, dental implants and acellular dermal matrix graft. *J Oral Implantol* 2013; [Epub ahead of print].
- [2] Mehta P, Lim LP. The width of the attached gingiva—much ado about nothing? *J Dent* 2010; 38: 517-525.
- [3] Krygier G, Glick PL, Versman KJ, Dahlin CJ, Cochran DL. To minimize complications, is it essential that implant abutments be surrounded by keratinized tissue? *Int J Oral Maxillofac Implants* 1997; 12: 127.
- [4] Fu JH, Su CY, Wang HL. Esthetic soft tissue management for teeth and implants. *J Evid Based Dent Pract* 2012; 12: 129-142.
- [5] Esposito M, Maghaireh H, Grusovin MG, Ziouanas I, Worthington HV. Soft tissue management for dental implants: what are the most effective techniques? A Cochrane systematic review. *Eur J Oral Implantol* 2012; 5: 221-238.
- [6] Scharf DR, Tarnow DP. Modified roll technique for localized alveolar ridge augmentation. *Int J Periodontics Restorative Dent* 1992; 12: 415-425.
- [7] Al-Hamdan KS. Esthetic soft tissue ridge augmentation around dental implant: Case report. *Saudi Dent J* 2011; 23: 205-209.
- [8] Park JB. Increasing the width of keratinized mucosa around endosseous implant using acellular dermal matrix allograft. *Implant Dent* 2006; 15: 275-281.
- [9] Bottino MC, Jose MV, Thomas V, Dean DR, Janowski GM. Freeze-dried acellular dermal matrix graft: effects of rehydration on physical, chemical, and mechanical properties. *Dent Mater* 2009; 25: 1109-1115.
- [10] Wei PC, Laurell L, Geivelis M, Lingen MW, Maddalozzo D. Acellular dermal matrix allografts to achieve increased attached gingiva. Part 1. A clinical study. *J Periodontol* 2000; 71: 1297-1305.
- [11] Wei PC, Laurell L, Lingen MW, Geivelis M. Acellular dermal matrix allografts to achieve increased attached gingiva. Part 2. A histological comparative study. *J Periodontol* 2002; 73: 257-265.
- [12] Griffin TJ, Cheung WS, Hirayama H. Hard and soft tissue augmentation in implant therapy using acellular dermal matrix. *Int J Periodontics Restorative Dent* 2004; 24: 352-361.

Peri-implant soft tissue reconstruction

- [13] Fowler EB, Breault LG, Rebitski G. Ridge preservation utilizing an acellular dermal allograft and demineralized freeze-dried bone allograft: Part I. A report of 2 cases. *J Periodontol* 2000; 71: 1353-1359.
- [14] Endress R, Choi MS, Lee GK. Use of fetal bovine acellular dermal xenograft with tissue expansion for staged breast reconstruction. *Ann Plast Surg* 2012; 68: 338-341.
- [15] Han YF, Han YQ, Pan YG, Chen YL, Chai JK. Transplantation of microencapsulated cells expressing VEGF improves angiogenesis in implanted xenogeneic acellular dermis on wound. *Transplant Proc* 2010; 42: 1935-1943.
- [16] Han TJ, Klekkevold PR, Takei HH. Strip gingival autograft used to correct mucogingival problems around implants. *Int J Periodontics Restorative Dent* 1995; 15: 404-411.
- [17] Eppley BL. Experimental assessment of the revascularization of acellular human dermis for soft-tissue augmentation. *Plast Reconstr Surg* 2001; 107: 757-762.
- [18] Felipe ME, Andrade PF, Grisi MF, Souza SL, Taba M, Palioto DB, Novaes AB. Comparison of two surgical procedures for use of the acellular dermal matrix graft in the treatment of gingival recession: a randomized controlled clinical study. *J Periodontol* 2007; 78: 1209-1217.
- [19] Koudale SB, Charde PA, Bhongade ML. A comparative clinical evaluation of acellular dermal matrix allograft and sub-epithelial connective tissue graft for the treatment of multiple gingival recessions. *J Indian Soc Periodontol* 2012; 16: 411-416.
- [20] Volk SW, Wang Y, Mauldin EA, Liechty KW, Adams SL. Diminished type III collagen promotes myofibroblast differentiation and increases scar deposition in cutaneous wound healing. *Cells Tissues Organs* 2011; 194: 25-37.