

Original Article

A novel visual sputum suctioning system is useful for endotracheal suctioning in a dog model

Xun Liu^{1*}, Huisheng Deng^{1*}, Ziyang Huang¹, Bingbing Yan¹, Jingjing Lv¹, Jinxing Wu²

¹Department of Geriatrics, The First Affiliated Hospital of Chongqing Medical University, Chongqing 400016, P.R. China; ²Department of Respiratory Medicine, The First Affiliated Hospital of Chongqing Medical University, 400016, P.R. China. *Equal contributors.

Received November 6, 2014; Accepted November 8, 2014; Epub December 15, 2014; Published December 30, 2014

Abstract: Objective: This study is to test the effectiveness of fiber-optic-guided endotracheal suction catheter (visual sputum suctioning system or VSSS) in dog models. Methods: Dog sputum models were established by administering dimethoate emulsifiable. Twenty-seven intubated dogs were equally randomized into three groups of conventional suctioning (CS) group, VSSS with no supplemental oxygen (VSSS) group and VSSS with 100% oxygen (VSSS/O₂) group. The suctioning efficiency, vital signs and tracheal wall injury were assessed. Results: The VSSS/O₂ (8.6 ± 0.7g) and VSSS groups (8.5 ± 0.9 g) collected significantly more sputum than the CS group (5.9 ± 0.8 g) ($P < 0.05$ for VSSS/O₂ group versus CS group; $P < 0.05$ for VSSS group versus CS group). Immediately after suctioning, the arterial partial pressure of oxygen (P_{aO_2}) of VSSS/O₂ group was significantly higher than that of the VSSS group or the CS group (both $P < 0.05$), and 5 min after suction the P_{aO_2} , the mean arterial pressure (MAP) and heart rate (HR) in all groups returned to the baseline ($p = 0.54$, $P = 0.67$, $P^2 = 0.11$, respectively). Moreover, in the VSSS/O₂ and VSSS groups all the three variables were higher than the CS group at 5 min after suctioning ($P < 0.01$, $P = 0.03$; $P = 0.02$, $P < 0.01$; $P = 0.02$, $P = 0.01$ respectively). Conclusions: Visual sputum suctioning system collected more sputum and caused less tracheal mucosa damage than conventional suctioning.

Keywords: Suctioning, sputum, endotracheal tube, intubation, dogs

Introduction

In clinical practice of respiratory medicine, suctioning may be used to clear the airway of fluids such as blood, saliva, vomit, or other secretions so that a patient may breathe [1]. It is also used to prevent growth of microorganisms, which can lead to lung infections. According to the American Association for Respiratory Care Clinical Practice Guideline [2] on suctioning, the suction catheter should not exceed the tip of the endotracheal tube, because such deep suctioning will lead to tracheal mucosa damage. Meanwhile, some studies have found that it is not good to exceed the tip of the endotracheal tube when suctioning. However, these studies might have failed to find good sputum-retrieval thus the suction catheter was blindly inserted and manipulated into the airway but without optical guidance. In actual practice, endotracheal suctioning is frequently performed in the ICU for clearing bronchial secretions in intubated and ventilated patients with

severe disease and many clinicians insert the suction catheter beyond the tip of the endotracheal tube.

Fiber-optic technology is widely used in diagnosis and therapy, including intubation, bronchoalveolar lavage, biopsy and suctioning [3-13]. However, fiber-optic bronchoscopy is too complicated and time-consuming for suctioning, and its efficiency depends substantially on the experience of the practitioners [14]. To provide visual guidance, maximize suctioning efficiency and minimize the risk of mucosa damage during performing suctioning by non-physician clinicians, we developed a fiber-optic-guided endotracheal suctioning system (which was also called the visual sputum suctioning system or VSSS) [15]. The VSSS catheter has the same outer diameter as the commonly used fiber-optic bronchoscope (5 mm), and has three channels: one (inner diameter 1.5 mm) houses the fiber-optic cable, another (inner diameter 2.5 mm) delivers the suction, and the third




Figure 1. Features of the visual sputum suctioning system (VSSS) for sputum suction. A. Fiber-optic cable (outer diameter 0.8 mm). B. Triple-lumen catheter (outer diameter 5.0 mm). I: Fiber-optic cable channel (inner diameter 1.50 mm). II: Suction channel (inner diameter 2.50 mm). III: Insufflation channel (inner diameter 1.0 mm).

(inner diameter 1.0 mm) insufflates oxygen to minimize hypoxia and lung-volume loss.

The incidence of suctioning complications increases with the increasing frequency of suctioning, as a result, researches on minimizing complications have focused on improving the efficiency (amount of secretions collected per suctioning) and reducing the frequency of suctioning [16-18]. Our previous in vitro testing of the VSSS had concerned its suctioning efficiency. In the present study, the sputum model [19] was established by administering dimethoate emulsifiable in dogs. The dog model was designed not only to develop clinical disease model with complex pathology but also to ensure adequate sputum for suctioning. The efficiency and safety of the VSSS system was analyzed.

Materials and methods

The suctioning system

The VSSS (**Figure 1**) included an optical fiber (FVS-001MI, Blade, Beijing, China, outer diam-

eter 0.8 mm, resolution 6,000 pixels) in a triple-lumen catheter (outer diameter 5 mm) and a computer processor and monitor. The commercially available conventional suctioning system tested in this study had only a single-lumen catheter (14 Fr, part-number of suction catheter: YZB/hu 2620-66-2010, Jiangsu Yongning Medical Devices, Yangzhou, Jiangsu, China).

Animals and model preparation

A total of 27 healthy pastoral dogs, with the body mass of 20-25 kg, were included in this study. They were provided by the Animal Laboratory of Chongqing Medical University. The dogs were kept in standard condition with free access to water and food. The agreement in the experimental animal ethics committee was approved by the First Affiliated Hospital of Chongqing Medical University. The dogs were anesthetized with intraperitoneal injection of 3% pentobarbital (30 mg/kg) and maintained with additional pentobarbital as needed. After anesthesia, 40% emulsifiable dimethoate (Dacheng Pesticide Co., Zibo, Shandong, China)

Visual sputum suctioning test in dogs

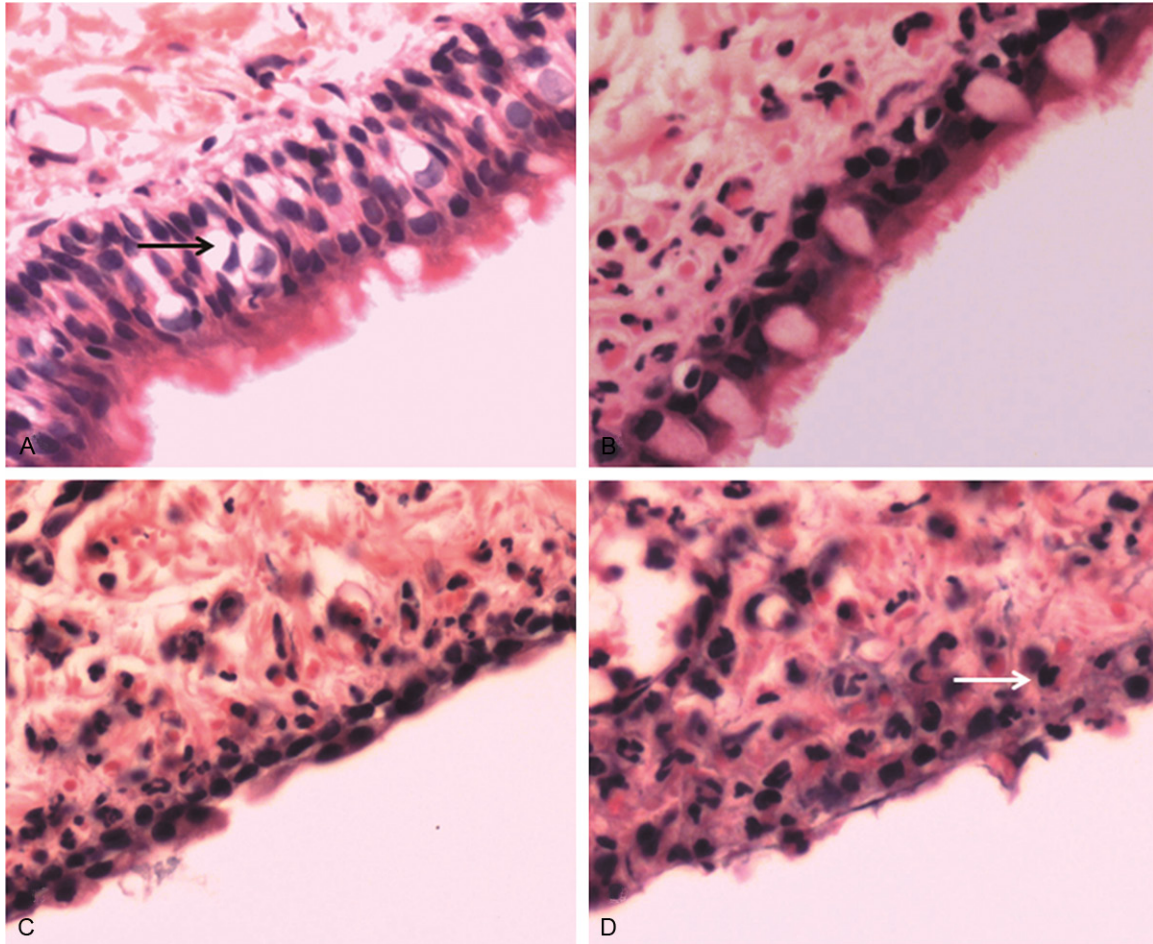


Figure 2. Morphology of tracheal mucosa. After five suctioning passes, the trachea was randomly taken from the lower airway of trachea beneath the endotracheal tube. HE staining was performed to analyze the morphology of tracheal mucosa. Representative HE staining results were shown ($\times 400$). A. Normal tracheal mucosa. The black arrow indicated goblet cell. B. Slight damage. C. Moderate damage. D. Severe damage. The white arrow indicated inflammatory cell.

was administrated (10 mg/kg) via a gastric tube. Each dog was orally intubated with an endotracheal tube (inner diameter 9 mm, Mallinckrodt/Covidien, Mansfield, Massachusetts, USA). An arterial catheter was placed in the femoral artery for arterial blood samples collection. A heparin with the dose of 250 IU/kg was administered to the catheter for anticoagulation.

Suctioning procedures

The 27 dogs were randomly divided equally into three groups and named as conventional suctioning (CS) group, VSSS with no supplemental oxygen (VSSS) group and VSSS with insufflation of 100% oxygen (VSSS/O₂) group. Thirty minutes after intragastric administration of dimethoate, the suctioning catheter was inserted into the endotracheal tube and suction (150

mm Hg) was applied for 10 s in each suctioning pass. Five suctioning passes were performed in each dog. The suctioned secretions were collected with a sputum trap (YZB/hu 2620-66-2011, Jiangsu Yongning Medical Devices, Yangzhou, China) and weighed with a calibrated scale (MP5002, Laboratory Electronic Balance, Sunny Hengping Scientific Instrument Co., Ltd, Shanghai, China). The amount of the sputum retrieved partially depended on the clinician's technique [20], so three inexperienced physicians were enrolled in this study. All the physicians were blind to the purpose of this study. The wet weight of the collected secretions was measured.

Detection of vital signs

The arterial blood gases (GEM Premier 3000, Instrumentation Laboratory/Werfen Group,

Visual sputum suctioning test in dogs

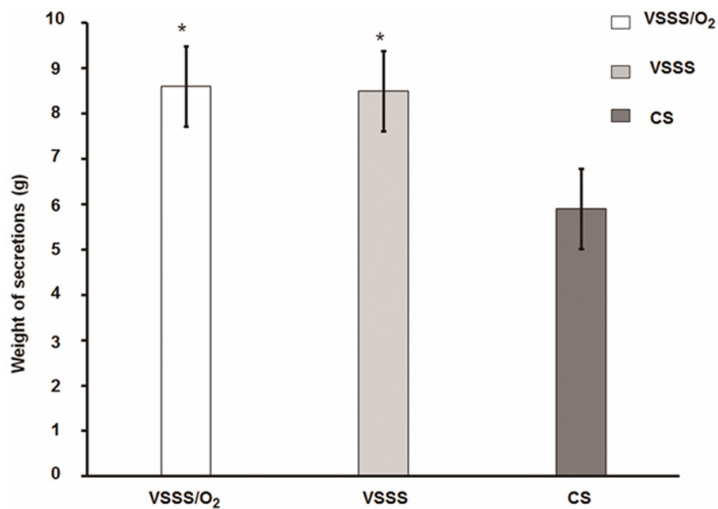


Figure 3. Weight of secretions suctioned. The collected secretions were collected with a sputum trap and weighed with a calibrated scale. The wet weight of the collected secretions was measured. Compared with CS group, * $P < 0.05$.

Barcelona, Spain), the heart rate (HR) (UT4000B, electrocardiogram monitor, Goldway Co., Shenzhen, Guangdong, China) and the mean arterial pressure (MAP) were measured. The HR, the MAP and the arterial partial pressure of oxygen (P_{aO_2}) were recorded before (baseline), immediately after, 3 min after and 5 min after each suction [21].

Mucosa damage examination

After five suctioning passes, the dogs were killed with an overdose of pentobarbital followed by careful removal of the trachea without touching the mucosa. Three samples were randomly taken from the lower airway of trachea beneath the endotracheal tube and sliced into sections for pathology grading (**Figure 2**). The grading basis and the criteria were indicated below [22]. Normal tracheal mucosa, covered by pseudostratified ciliated columnar epithelium with interspersed goblet cells and supported by an underlying basement membrane and lamina propria was defined as grade-1. Slight damage with preservation of a two-to-four-cell thickness was considered as grade-2. Moderate damage, with preservation of one flattened cell thickness was named as grade-3. Severe damage, with ulceration characterized by loss of mucosa and infiltration of inflammatory cells to the underlying tissue was grade-4. Ulceration with necrosis, characterized by blue staining of

necrotic at base of ulcer was taken as grade-5.

Statistical analysis

All data were analyzed by SPSS10.0 software (SPSS Inc, Chicago, IL, USA). The nonparametric *t*-test was used for normally distributed data, and the nonparametric Wilcoxon-Mann-Whitney rank test was used for other data. Repeated-measures analysis of variance at four time points (before suctioning, immediately after suctioning, 3 min after suctioning, and 5 min after suctioning) was used to analyze the differences in P_{aO_2} , HR and MAP. $P < 0.05$ was considered as statistically significant.

Results

The amount of sputum collected by VSSS is more than that by CS

To compare the efficiency between the suctioning systems, the amount of the sputum collected was recorded and the differences between different groups were analyzed. As shown in **Figure 3**, the amount of sputum in the VSSS/O₂, VSSS and CS groups was 8.6 ± 0.7 g, 8.5 ± 0.9 g and 5.9 ± 0.8 g, respectively. VSSS/O₂ and VSSS groups collected significantly more sputum than the CS group ($P < 0.01$ for VSSS/O₂ versus CS, $P < 0.01$ for VSSS CS), however, there was no significant difference between VSSS/O₂ group and VSSS group ($P = 0.81$ for VSSS/O₂ versus VSSS). These results indicate that VSSS is better than CS in collecting sputum.

The vital signs of VSSS are better than those of CS

To determine the cardiorespiratory function, the HR, the MAP and the P_{aO_2} were measured and analyzed. Compared to the baseline, as shown in **Table 1** and **Figure 4**, the HR and the MAP were significantly higher immediately after suctioning in all the three groups while the P_{aO_2} did not decrease greatly. In all the three groups, the HR, the MAP and the P_{aO_2} totally returned to the baseline at 5 min after suctioning. The P_{aO_2}

Visual sputum suctioning test in dogs

Table 1. P_{aO_2} , heart rate and mean arterial pressure before and after suctioning (mean \pm SD)

	VSSS/ O_2	VSSS	CS	<i>p</i> for VSSS/ O_2 vs VSSS	<i>p</i> for VSSS/ O_2 vs Convention	<i>p</i> for VSSS vs Convention
P_{aO_2} (mm Hg)						
Before suctioning	79 \pm 4	81 \pm 4	81 \pm 4	0.16	0.32	0.66
Immediately after suctioning	94 \pm 2†	80 \pm 4	79 \pm 5	< 0.01*	< 0.01*	0.51
3 min after suctioning	90 \pm 4†	85 \pm 4†	82 \pm 7	0.06	< 0.01*	0.17
5 min after suctioning	84 \pm 3†	84 \pm 3†	80 \pm 2	0.67	< 0.01*	< 0.01*
Heart rate (beats/min)						
Before suctioning	135 \pm 7	134 \pm 8	136 \pm 9	0.93	0.62	0.55
Immediately after suctioning	138 \pm 6†	139 \pm 8†	143 \pm 8†	0.90	0.19	0.23
3 min after suctioning	135 \pm 7	136 \pm 8	141 \pm 9†	0.91	0.16:	0.20
5 min after suctioning	131 \pm 5†	130 \pm 8†	139 \pm 8	0.78	0.04*	0.02*
Mean arterial pressure (mm Hg)						
Before suctioning	108 \pm 9	106 \pm 6	108 \pm 10	0.75	0.89	0.63
Immediately after suctioning	113 \pm 6†	112 \pm 7†	115 \pm 9†	0.79	0.58	0.40
3 min after suctioning	107 \pm 4	106 \pm 6	113 \pm 8	0.72	0.08	0.03*
5 min after suctioning	101 \pm 6†	100 \pm 5†	109 \pm 8	0.86	0.01*	0.01*

Note: P_{aO_2} = arterial partial pressure of oxygen; VSSS/ O_2 = visual sputum suctioning system with 100% oxygen; VSSS = visual sputum suctioning system without supplemental oxygen; CS = conventional suction; *, $P < 0.05$, tests of between subject effects at the same time point; †, $P < 0.05$, tests of within subject effects; vs. time point before suctioning in the same group.

at 5 min after suctioning in VSSS/ O_2 and VSSS groups was higher than that of the CS group, however there was no difference between VSSS/ O_2 and VSSS groups. The mean HR at 5 min after suctioning in VSSS/ O_2 and VSSS groups was lower than that of the CS group. The MAP at 5 min after suctioning in VSSS/ O_2 and VSSS group was lower than that of the CS group. Collectively, these results indicate that compared to CS, VSSS is helpful to maintain blood pressure and the blood gases no matter with or without oxygen therapy.

VSSS causes less mucosa damage

To identify the potential adverse effect of suctioning by VSSS and CS, pathological examination was performed. The grading criteria were described in materials and methods. None of the trachea tissue samples had grade-5 damage. The CS group had numerous grade-3 to grade-4 damage while the damage of VSSS and VSSS/ O_2 groups was less serious. The differences in mucosa damage were significant between the CS group and the VSSS and VSSS/ O_2 groups (all $P < 0.05$ via Wilcoxon-Mann-Whitney rank test, **Figure 5**). These results suggest that VSSS is better than CS in protecting trachea mucosa. Images from the visual spu-

tum suctioning system (VSSS) in dogs were shown in **Figure 6**.

Discussion

Conventional endotracheal suctioning, with a single-lumen suction catheter can cause severe complications, such as iatrogenic infection, mucosa damage, increased heart rate, increased arterial pressure and decreased P_{aO_2} [20, 23-34]. Closed suctioning systems decrease the risk of iatrogenic infection and hypoxemia, however, it is less efficient than the open suctioning systems in removing secretions [23, 25, 32-34]. The suction lumen of VSSS catheter is narrower than that of the CS catheter, therefore the sputum collected per second by VSSS catheter is less than that of the CS catheter. However, from previous in vitro test [15], we found that the ability of visualizing the airway made it possible for targeting sputum, which, compensated the smaller lumen and made the suctioning procedure more efficiently. The insufflation flow out of the suction catheter tip can push secretions away from the suction catheter tip. We suppose that we might increase the suctioning efficiency (amount of secretions collected) by separating the insufflating oxygen channel from suction channel

Visual sputum suctioning test in dogs

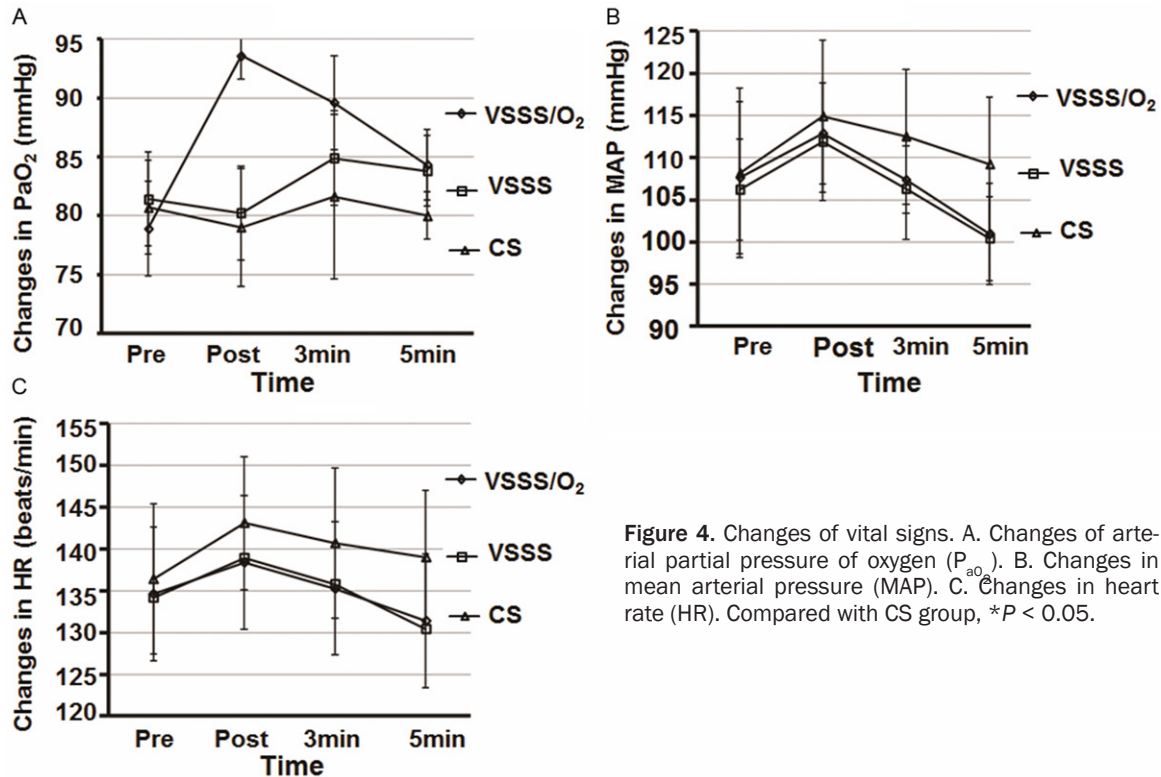


Figure 4. Changes of vital signs. A. Changes of arterial partial pressure of oxygen (P_{aO_2}). B. Changes in mean arterial pressure (MAP). C. Changes in heart rate (HR). Compared with CS group, $*P < 0.05$.

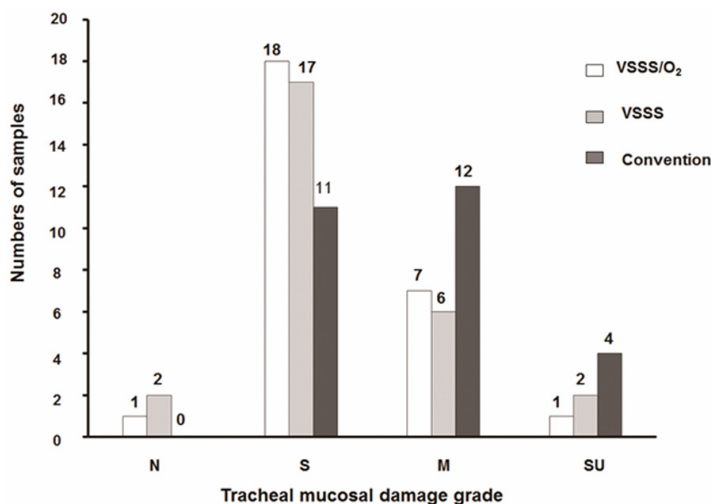


Figure 5. Tracheal mucosa damage. N: Normal tracheal mucosa; S: Slight damage; M: Moderate damage; SU: Severe damage, ulceration. Compared with CS group, $*P < 0.05$.

and adding holes in the insufflating oxygen channel. We added two elliptical holes (3 mm long by 2.5 mm wide, 6 mm apart) in the oxygen channel (8 mm and 18 mm) from the tip of the VSSS catheter. This released some of the insufflated oxygen and thus decreased the insufflation flow at the VSSS catheter tip. So the sputum was less pushed away by the insufflation flow.

Suctioning-induced hypoxia can be decreased by insufflation (100% oxygen during suctioning) [20]. However, Benditt et al [35] found that a high fraction of inspired oxygen could damage several organ systems. Moreover, the high insufflation flow can push secretions away from the suction catheter even deep into the lung [33, 34], thus, decreasing the suctioning efficiency. In a systematic review of suctioning in adult patients, Overend et al [36] found that hyperoxygenation helped to maintain oxygenation during suctioning, and the American Association for Respiratory Care's Suctioning Guideline suggests administering 100% oxygen before and after suctioning in adult patients [2]. The

toxicity of high-oxygen concentration depends on the both oxygen concentration and the duration of administration. Thus, we consider that the toxicity risk of brief hyperoxygenation is relatively low and the benefit of minimizing hypoxia worth the risk.

Unlike some previous studies [20, 35], we found that the P_{aO_2} of the VSSS/ O_2 group was

Visual sputum suctioning test in dogs

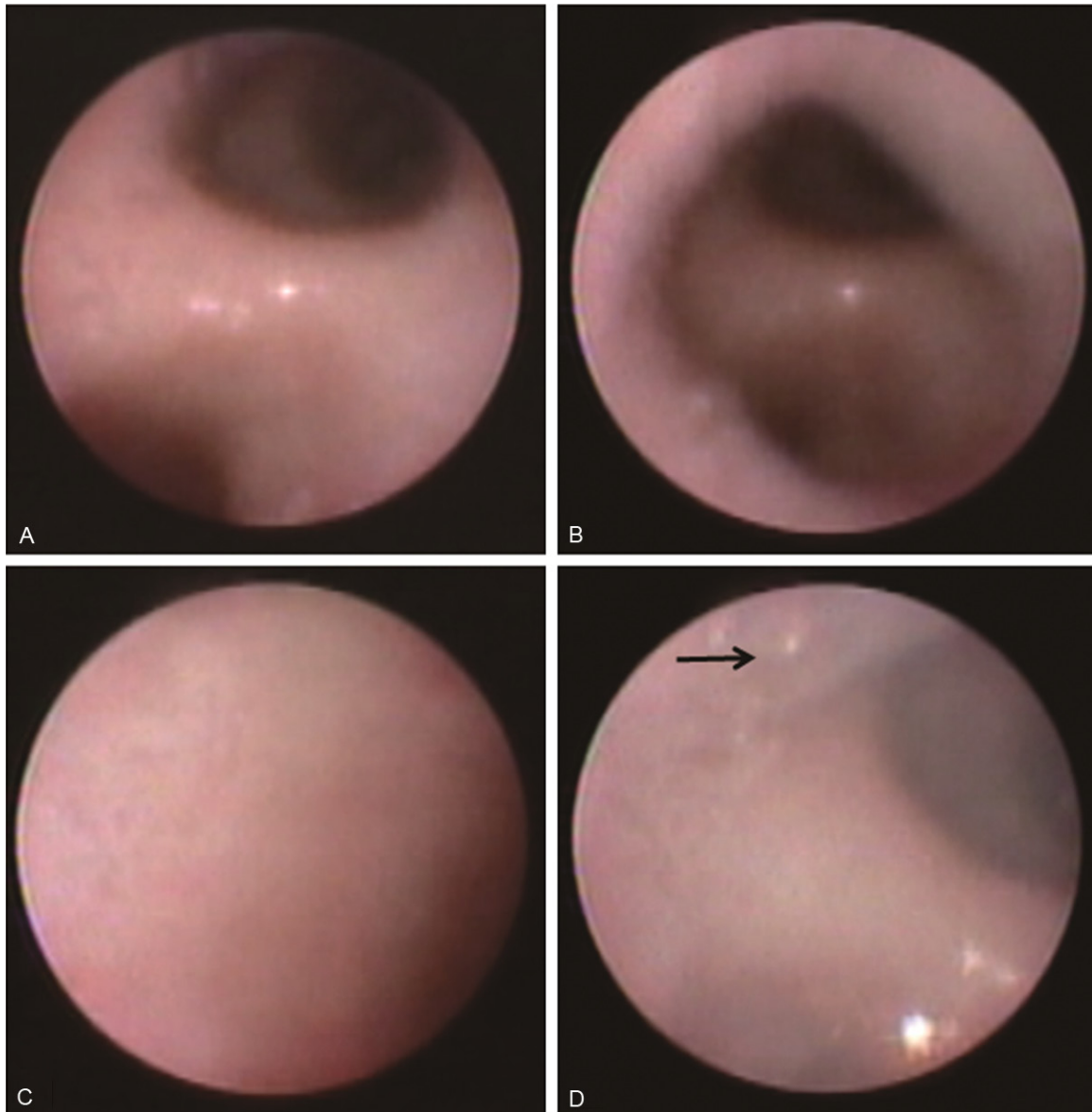


Figure 6. Images from the visual sputum suctioning system (VSSS) in dogs. A. Carina. B. Right bronchus. C. Trachea wall. D. Sputum in the trachea. The black arrow indicated the sputum in the trachea.

significantly increased once the suction was carried while the P_{aO_2} of the VSSS and the CS groups declined immediately after suction. This might be due to the dogs' low basic P_{aO_2} level, which is in poisoning condition and causes hypoxia. And we administered continuously 100% oxygen for only 10 seconds, which was within the safe levels recommended in the literature [35]. Therefore, the finding demonstrated that the new VSSS was useful in an emergency, at least partially useful.

It is reported [30] that acute hypoxemia during suction will affect HR and impair hemodynamic

stability. This might be associated with discomfort and increased oxygen consumption, which may further stimulate the sympathetic system. The P_{aO_2} , HR and MAP levels in both the VSSS/ O_2 and VSSS groups were significantly different from these of the CS group 5 min after suctioning, although the differences between VSSS and CS group was not significant immediately after suction. This might be explained by the merits of short time period and efficacy of the new system. Removing amounts of secretions in a short time could significantly alleviate obstruction of the airway and increase ventilation.

It is clear from earlier animal model studies that trauma to the tracheobronchial mucosa is a potential adverse effect of suctioning. Human data reporting the damage to bronchia, however, are scarce. Bronchial hemorrhage was observed in 3.3% of the patients those undergoing endotracheal suctioning [30], which, was lower than the incidence in our animal study. It might be partly due to the airway spasms, mucosa congestion and edema caused by organophosphorus poisoning. However, the results still showed that the new VSSS cause less damage to the tracheobronchial mucosa than the CS.

Although the resolution of the optical fiber of VSSS was lower than that of a fiber-optic bronchoscope, the VSSS provided adequately clear imaging for guiding suctioning. The clinical procedure of VSSS was similar in complexity and time-consumption compared with CS. Therefore, respiratory therapists can competently perform suctioning with VSSS. The routine cleaning and disinfection procedure for VSSS is the same as that for a flexible bronchoscope (the fiber-optic cable is soaked in glutaraldehyde).

The above results of this study showed that VSSS was better than the CS, however there were some limitations. Firstly, our study did not detect blood in recovered secretions and the iatrogenic infection of suction, as a result, the evaluation of long-term influence was limited. Secondly, the viscoelastic and surface properties of the secretions were limited. In the case of organophosphate poisoning, large amount of foamy sputum was often seen. However, these results could not be directly extrapolated to the cases with viscous sputum. In addition, the outer diameter of the VSSS catheter is 5 mm, which is wider than a CS catheter. We plan to test a narrower, two-lumen VSSS catheter (no insufflation lumen), which might offer advantages for some patients such as those with small-diameter endotracheal tubes.

In conclusion, using the dog model, our findings showed that VSSS efficiently removed the airway secretions and avoided complications commonly occurred in the conventional endotracheal suctioning.

Acknowledgements

This work was supported by the Chongqing Science and Technology Commission (Grant

No. CSTC2009AB5218). We want to thank the support from the National Key Clinical Specialty Discipline Construction Program of China.

Disclosure of conflict of interest

None.

Address correspondence to: Jinxing Wu, Department of Respiratory Medicine, The First Affiliated Hospital of Chongqing Medical University, NO. 1, Youyi Road, Chongqing 400016, P. R. China. Tel: 86-23-89012-962; Fax: 86-23-89012962; E-mail: lauade@sohu.com

References

- [1] Allen GS, Coates NE. Pulmonary contusion: A collective review. *Am Surg* 1996; 62: 895-900.
- [2] American Association for Respiratory Care. AARC Clinical Practice Guidelines. Endotracheal suctioning of mechanically ventilated patients with artificial airways 2010. *Respir Care* 2010; 55: 758-764.
- [3] Gasparini S. It is time for patients to undergo bronchoscopy without discomfort. *The Eur Respir J* 2011; 38: 507-509.
- [4] Midulla F, de Blic J, Barbato A, Bush A, Eber E, Kotecha S. Flexible endoscopy of paediatric airways. *Eur Respir J* 2003; 22: 698-708.
- [5] Gruson D, Hilbert G, Valentino R, Vargas F, Chene G, Bebear C, Allery A, Pigneux A, Gbikpi-Benissan G, Cardinaud JP. Utility of fiberoptic bronchoscopy in neutropenic patients admitted to the intensive care unit with pulmonary infiltrates. *Crit Care Med* 2000; 28: 2224-2230.
- [6] British Thoracic Society Bronchoscopy Guidelines Committee, a Subcommittee of Standards of Care Committee of British Thoracic Society. British Thoracic Society guidelines on diagnostic flexible bronchoscopy. *Thorax* 2001; 56 Suppl 1: i1-21.
- [7] Nishino T, Tagaito Y, Isono S. Cough and other reflexes on irritation of airway mucosa in man. *Pulm Pharmacol* 1996; 9: 285-292.
- [8] Lindgren S, Odenstedt H, Erlandsson K, Grivans C, Lundin S, Stenqvist O. Bronchoscopic suctioning may cause lung collapse: a lung model and clinical evaluation. *Acta anaesthesiol Scand* 2008; 52: 209-218.
- [9] Ovassapian A. The flexible bronchoscope. A tool for anesthesiologists. *Clin Chest Med* 2001; 22: 281-299.
- [10] Sackner MA, Landa JF, Greeneltch N, Robinson MJ. Pathogenesis and prevention of tracheobronchial damage with suction procedures. *Chest* 1973; 64: 284-290.

Visual sputum suctioning test in dogs

- [11] Kovnat DM. Controlled suction during flexible fiberoptic bronchoscopy. *Chest* 1975; 68: 125-126.
- [12] Cracco C, Fartoukh M, Prodanovic H, Azoulay E, Chenivresse C, Lorut C, Beduneau G, Bui HN, Taille C, Brochard L, Demoule A, Maitre B. Safety of performing fiberoptic bronchoscopy in critically ill hypoxemic patients with acute respiratory failure. *Int Care Med* 2013; 39: 45-52.
- [13] Chastre J, Fagon JY. Ventilator-associated pneumonia. *Am J Respir Crit Care Med* 2002; 165: 867-903.
- [14] Smyth CM, Stead RJ. Survey of flexible fibreoptic bronchoscopy in the United Kingdom. *Eur Respir J* 2002; 19: 458-463.
- [15] Lv J, Wu J, Guo R, Liu X, Yan B, Deng H. Laboratory test of a visual sputum suctioning system. *Respir Care* 2013; 58: 1637-1642.
- [16] Plum F, Dunning MF. Technics for minimizing trauma to the tracheobronchial tree after tracheotomy. *N Engl J Med* 1956; 254: 193-200.
- [17] Link WJ, Spaeth EE, Wahle WM, Penny W, Glover JL. The influence of suction catheter tip design on tracheobronchial trauma and fluid aspiration efficiency. *Anesth Analg* 1976; 55: 290-297.
- [18] Moore T. Suctioning techniques for the removal of respiratory secretions. *Nurs Stand* 2003; 18: 47-53.
- [19] Leiman BC, Katz J, Stanley TH, Butler BD. Removal of tracheal secretions in anesthetized dogs: balloon catheters versus suction. *Anesth Analg* 1987; 66: 529-532.
- [20] Oh H, Seo W. A meta-analysis of the effects of various interventions in preventing endotracheal suction-induced hypoxemia. *J Clin Nur* 2003; 12: 912-924.
- [21] Jongerden IP, Kesecioglu J, Speelberg B, Buiting AG, Leverstein-van Hall MA, Bonten MJ. Changes in heart rate, mean arterial pressure, and oxygen saturation after open and closed endotracheal suctioning: a prospective observational study. *J Crit Care* 2012; 27: 647-654.
- [22] Czarnik RE, Stone KS, Everhart CC Jr, Preusser BA. Differential effects of continuous versus intermittent suction on tracheal tissue. *Heart Lung* 1991; 20: 144-151.
- [23] Lasocki S, Lu Q, Sartorius A, Fouillat D, Remerand F, Rouby JJ. Open and closed-circuit endotracheal suctioning in acute lung injury: efficiency and effects on gas exchange. *Anesthesiology* 2006; 104: 39-47.
- [24] Shah S, Fung K, Brim S, Rubin BK. An in vitro evaluation of the effectiveness of endotracheal suction catheters. *Chest* 2005; 128: 3699-3704.
- [25] Blackwood B, Webb CH. Closed tracheal suctioning systems and infection control in the intensive care unit. *J Hospital Infect* 1998; 39: 315-321.
- [26] Morrow BM, Futter MJ, Argent AC. Endotracheal suctioning: from principles to practice. *Int Care Med* 2004; 30: 1167-1174.
- [27] AARC clinical practice guideline. Endotracheal suctioning of mechanically ventilated adults and children with artificial airways. American Association for Respiratory Care. *Respir Care* 1993; 38: 500-504.
- [28] Bourgault AM, Brown CA, Hains SM, Parlow JL. Effects of endotracheal tube suctioning on arterial oxygen tension and heart rate variability. *Biol Res Nurs* 2006; 7: 268-278.
- [29] Berman IR, Stahl WM. Prevention of hypoxic complications during endotracheal suctioning. *Surgery* 1968; 63: 586-587.
- [30] Demir F, Dramali A. Requirement for 100% oxygen before and after closed suction. *J Adv Nurs* 2005; 51: 245-251.
- [31] Mary A. Effectiveness of standard endotracheal suctioning technique on patients with mechanical ventilators. *Nurs J India* 2005; 96: 109.
- [32] Lindgren S, Almgren B, Högman M, Lethvall S, Houlitz E, Lundin S, Stenqvist O. Effectiveness and side effects of closed and open suctioning: an experimental evaluation. *Int Care Med* 2004; 30: 1630-1637.
- [33] Pedersen CM, Rosendahl-Nielsen M, Hjerminde J, Egerod I. Endotracheal suctioning of the adult intubated patient—what is the evidence? *Intensive Crit Care Nurs* 2009; 25: 21-30.
- [34] Copnell B, Tingay DG, Kiraly NJ, Sourial M, Gordon MJ, Mills JF, Morley CJ, Dargaville PA. A comparison of the effectiveness of open and closed endotracheal suction. *Intensive Care Med* 2007; 33: 1655-1662.
- [35] Benditt JO. Adverse effects of low-flow oxygen therapy. *Respir Care* 2000; 45: 54-61.
- [36] Overend TJ, Anderson CM, Brooks D, Cicutto L, Keim M, McAuslan D, Nonoyama M. Updating the evidence-base for suctioning adult patients: a systematic review. *Can Respir J* 2009; 16: e6-17.