

## Original Article

# Classification and surgical management for the axis fracture complicated with adjacent segment instability

Lei Wang<sup>1</sup>, Chao Liu<sup>2</sup>, Qing-Hua Zhao<sup>1</sup>, Ji-Wei Tian<sup>1</sup>

<sup>1</sup>Department of Orthopedics, First People's Hospital Affiliated to Shanghai Jiaotong University, No. 100, Haining Road, Shanghai 200080, China; <sup>2</sup>Shanghai Jiao Tong University School of Medicine, No. 227, South Chongqing Road, Shanghai 200025, China

Received January 11, 2014; Accepted February 17, 2014; Epub March 15, 2014; Published March 30, 2014

**Abstract:** This study was to classify the axis fracture complicated with adjacent segment instability and to explore its significance to surgical management. 42 patients (25 males and 17 females) with axis fractures with an average age of 44.14 years (range, 23 to 65) who received surgery between January 2006 and June 2012 were analyzed retrospectively. Results suggest that all patients underwent surgery safely without spinal cord injury, cerebrospinal fluid leakage or vertebral artery injury. The average follow up was 18 months (12-48 months). There was significant difference ( $t = 2.339$ ,  $P = 0.011$ ) in JOA score between pre-operation ( $13.10 \pm 4.51$ ) and post-operation time points ( $15.24 \pm 3.86$ ). 1-2 degree improvement of neurofunction was achieved in all except 1 Frankel B. After operation, all patients were immobilized in a hard collar for 3 months. Fusion was achieved in all cases (mean 4.5 months). X-ray showed no malposition of the screws. No instrument failure was noted during follow up. Thus, axis fracture complicated with adjacent segment instability should be treated individually based on the fracture type and adjacent segment instability. Our classification can be used to guide the surgical management.

**Keywords:** Axis fractures, adjacent section, instability, operative methods

## Introduction

Currently, axis fracture is clinically classified into odontoid fracture, hangman fractures and axis vertebral fracture. The treatment focuses on axis fractures, and if its adjacent segments atlantoaxial joint or C2/3 instability is not dealt with accordingly, it may cause potential danger on spinal cord and even affect the prognosis. The aim of this study was to come up with the classification for axis fracture complicated with adjacent segment instability by analyzing the axis fracture and its adjacent atlantoaxial joint and C2/3 joint stability, in which, C1/2/3 segment was taken as a whole for study, further understanding the functional significance of axis in the upper and lower cervical axial connection and providing the basis for selection of clinical treatment strategies.

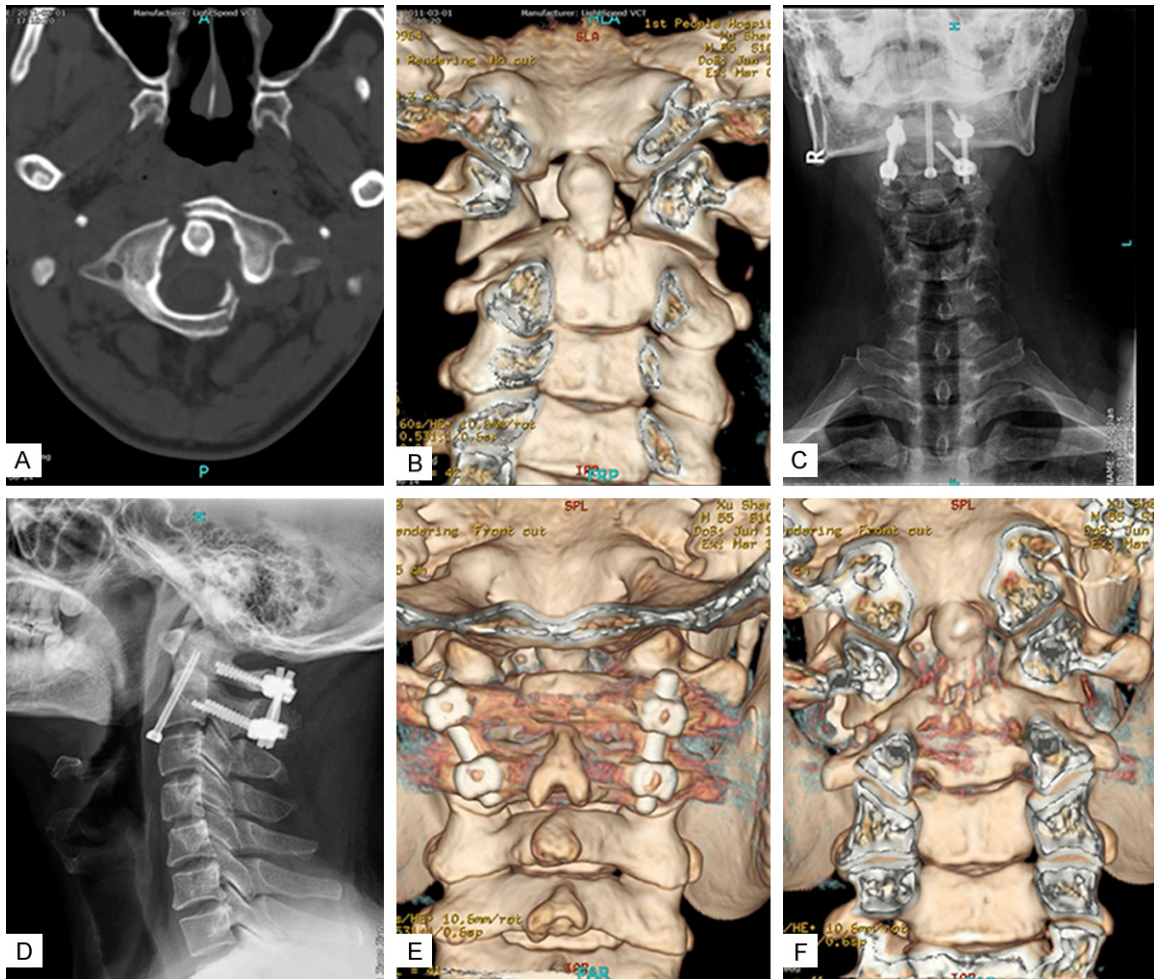
## Materials and methods

### General information

42 patients (mean age: 44.14 (23-65) years) who were preliminary diagnosed as axis frac-

ture were admitted to our hospital from January 2006 to June 2012, including 25 males and 17 females. All patients in this group just had simple trauma, and the upper cervical spine deformities and degenerative diseases were excluded. The causes of injury included traffic injuries in 18 patients, fall injury in 15 patients, combat injuries in 7 patients and the others in 2 patients. Clinical symptoms included occipital pain in 42 cases (100%), limited neck activity in 42 cases (100%), torticollis with limited neck activity in 13 cases (30.95%), neurological symptoms including upper limbs numbness and weakness as well as lower limbs activity limitation in 9 cases (21.4%). In all 42 patients, 9 cases (21.4%) were complicated with spinal cord injury, among them, Frankel scales were as follow: 1 grade A, 2 grade B, 3 grade C, and 3 grade D; 4 cases were complicated with traumatic brain injury, 2 cases mandibular fractures, 8 cases limb fractures, 1 case pneumothorax, 2 cases lower cervical spine fracture and 2 cases thoracolumbar fractures.

## Treatment of axis fracture



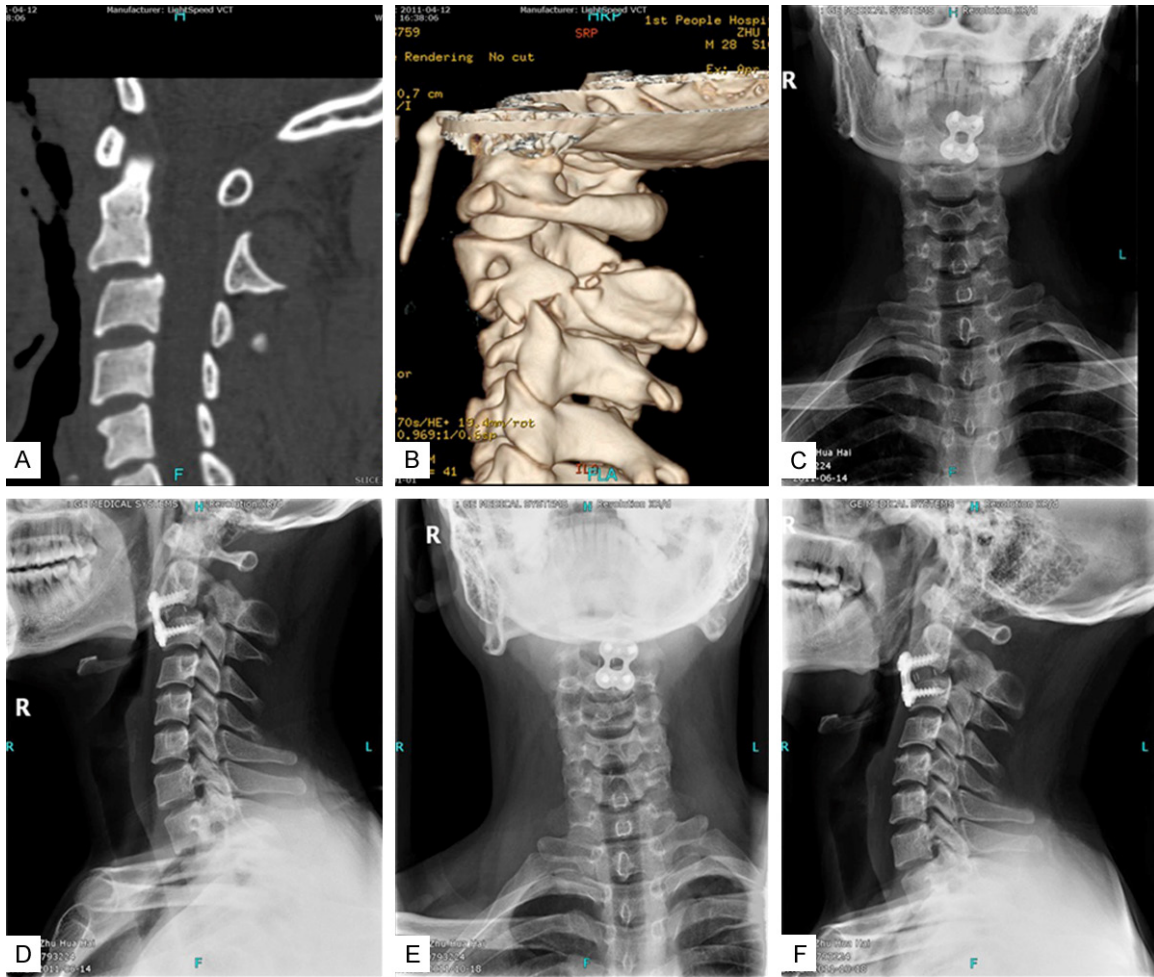
**Figure 1.** Type A: A 34-year-old male patient with pain at neck and occiput limitation of neck movement with loss of strength in both arms after a car accident. A, B: CT scan and 3D-CT showed axis odontoid fracture combined with C1 fracture before operation. C, D: Cervical X-ray scan showed anterior odontoid annulated screws with posterior atlantoaxial pedicle screw fixation after operation. There was fracture line in Odontoid. E, F: 3D-CT showed anterior odontoid annulated screws with posterior atlantoaxial pedicle screw fixation at 6 month after operation. Odontoid fracture healing and fusion occurred in C1/2.

### *Injury classification*

All patients underwent imaging tests, including X-ray, CT, MRI, etc. Because patients involved upper cervical fracture, dynamic cervical radiographs cannot be performed before surgery. The inclusion criteria for adjacent segmental instability were: axis fracture combined with C1/2 instability, such as atlantoaxial dislocation/subluxation and transverse ligament rupture or atlas fracture; axis fractures combined with C2/3 instability, such as C2/3 dislocation, C2/3 intervertebral disc injury and those combined with C3 vertebral fractures. Classification was performed based on the axis fracture combined with adjacent segment instability: 1) type

A: axis fracture combined with C1/2 instability in 20 cases, including type II odontoid fracture of the axis combined with atlantoaxial dislocation in 13 cases and axis fracture (II type/III odontoid fractures, vertebral body fracture, Hangman fracture) combined with axis fracture in 7 cases; type B: axis fracture combined with C2/3 instability in 14 cases, including vertebral body fractures combined with C2/3 dislocation in 7 cases, type II Hangman fracture combined with C2/3 intervertebral disc injury in 5 cases and axis fracture combined with C3 fracture in 2 cases; type C: axis fracture combined with C1/2 and C2/3 instability in 8 cases, including odontoid fracture combined with Hangman fracture in 5 cases, Hangman fracture com-

## Treatment of axis fracture



**Figure 2.** Type B: A 30-year-old female with neck pain with myasthenia of limbs after a high falling injury. A, B: CT and 3D-CT scan showed axis Hangman fractures combined with C2-3 dislocation. C, D: X ray scan showed C2-3 discectomy and fusion, and anterior cervical plate fixation after operation. E, F: Cervical X ray showed C2-3 discectomy and fusion, and anterior cervical plate fixation at 6 month after operation and the fracture was healing.

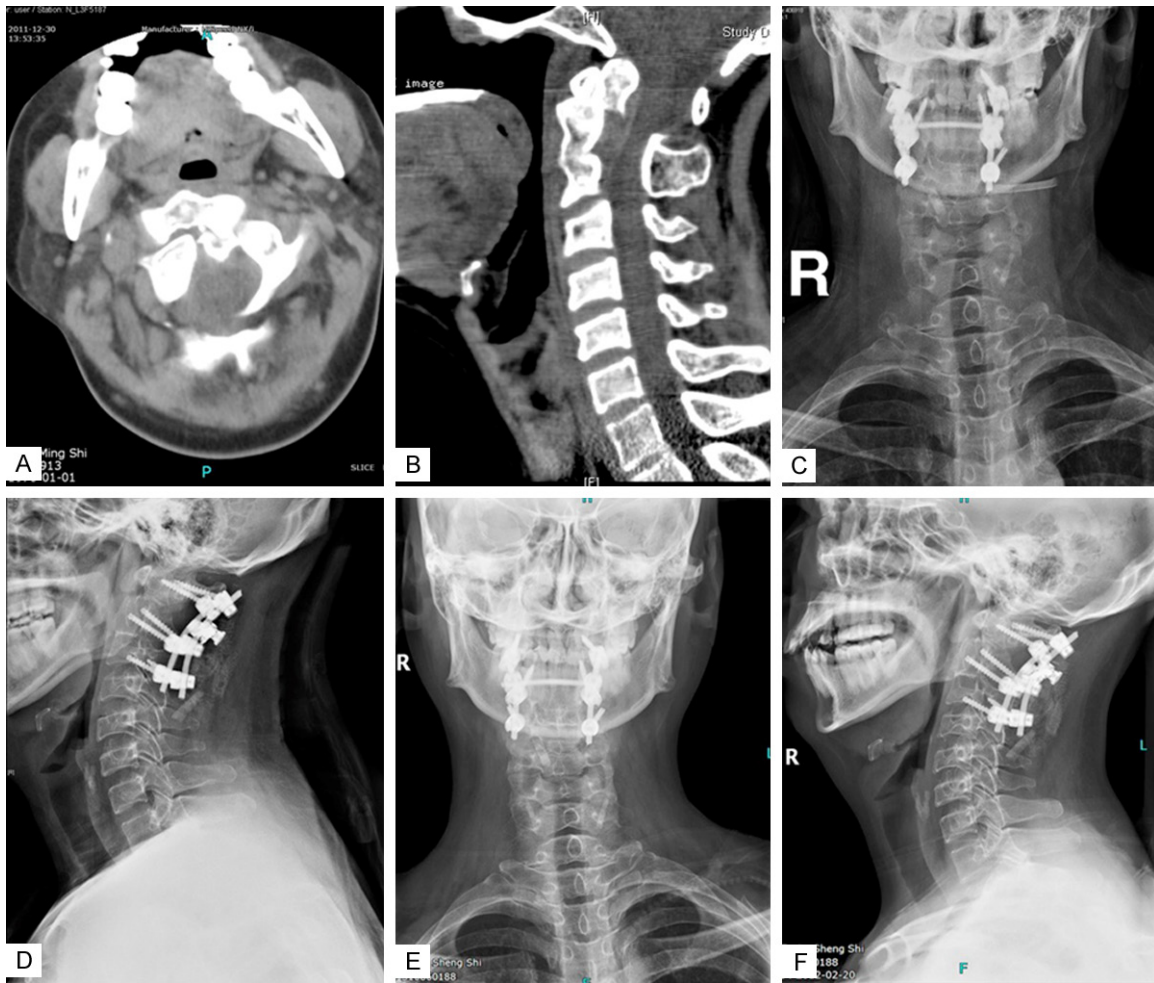
combined with atlantoaxial and C2-3 instability in 2 cases, and type II odontoid fractures combined with atlantoaxial instability and C2/3 disc injury in 1 case.

### *Selection of surgical procedures*

For patients with nerve compression symptoms, surgical decompression and fixation should generally be given as soon as possible if appropriate. 9 patients in this group had nerve compression symptoms, among them, 8 cases underwent surgery at 2-7 days (average 3.5 days) after injury, 1 case with severe nerve damage underwent surgery after skull traction for 2 weeks in ICU; as for the patients without nerve compression symptoms; they should be given the surgery after first receiving a skull

traction for 1 to 2 weeks and then a reexamination by X ray which showed a poor restoration. Axis joint should be fixed while atlantoaxial joint and/or C2-3 joint should also be stabilized according to the type of fracture and atlantoaxial joints and C2-3 stability. The patients in this group: type A: For type II odontoid fractures with atlantoaxial dislocation, posterior atlantoaxial pedicle screw fixation plus screw fixation for odontoid fracture were used (**Figure 1**), if odontoid screw was difficult to imbed, posterior fixation with posterior bone graft fusion would be simply performed. Posterior atlantoaxial pedicle screw fixation could be used for axis fracture combined with atlas fracture; if atlas screws were difficult to implant, occipital cervical fusion could be used; in this group, 10 cases underwent odontoid screw + posterior

## Treatment of axis fracture



**Figure 3.** Type C: A 43-year-old male with neck pain with paralysis of the lower extremities after a traffic accident. A, B: CT scan showed axis odontoid fractures combined with C1-2 and C2-3 dislocation. C, D: Cervical X ray showed Posterior C1-2 cervical pedicle screw and C3 lateral mass screws fixation after operation. E, F: Cervical X ray showed Posterior C1-2 cervical pedicle screw and C3 lateral mass screws fixation at 1 year after operation. The bone was in fusion.

atlantoaxial fixation, and 8 cases underwent posterior atlantoaxial fixation, and 2 cases underwent occipital cervical fusion. Type B: anterior C2/3 discectomy, intervertebral fusion, and anterior cervical plate fixation could be applied for treatment of axis fracture with C2/3 intervertebral disc injury (**Figure 2**). Posterior pedicle screw/lateral mass screws fixation could be applied for treatment of C2 and C3 fractures. In this group, 12 cases underwent anterior cervical CAGE placement + plate fixation, and 2 cases underwent posterior C2 and C3 fixation. Type C: posterior C1-C3 pedicle screw/lateral mass screws (**Figure 3**) or anterior-posterior surgery could be applied. If atlantoaxial vertebral pedicle screw were difficult to implant, occipital cervical fusion for fixation

could be used; in this group, 5 cases underwent C1-C3 fixation, and 2 cases underwent anterior-posterior surgery, and 1 case underwent occipital cervical fusion. In 7 axis fracture patients combined with atlas fracture, 1 patient had a transverse ligament rupture by preoperative MRI and underwent an atlantoaxial posterior interbody fusion; and 4 patients didn't show a transverse ligament rupture by preoperative MRI and underwent posterior atlantoaxial pedicle screw fixation and didn't receive bone graft fusion; and the other 2 patients could not receive atlas pedicle screw fixation due to atlas splintered fracture and underwent occipital cervical fusion; and the remaining patients underwent anterior interbody and/or posterior interbody fusion. Drainage tube was placed for

**Table 1.** The frankel scale for spinal function before surgery and after 6 months follow-up

Pre-operation	Cases	Post-operation				
		A	B	C	D	E
A	1		1			
B	2		1	1		
C	3				2	1
D	3					3

24 to 48 hours after surgery, and antibiotics were used for 1 to 3 days. Sutures were removed at 12 to 14 days after surgery, and cervical collar was worn for 3 months. It was necessary to conduct regular follow-up after surgery.

#### *Efficacy evaluation*

Imaging evaluation standards of bone healing: Cervical spine X-ray results showed that vertebral fracture line had presented bridge-like connection by bone trabecula. Criteria for inter-transversal fusion: lateral cervical spine X-ray for hyperextension and hyperflexion showed that intervertebral angle on fused segments varied < 2 degrees or the range of motion of interspinous process on fused segments was less than 2 mm. If the pseudarthrosis formation couldn't be identified or excluded, cervical spine CT scan should be applied to observe the fusion. The JOA score was adopted for Clinical efficacy assessment, and patients' clinical symptoms, signs and sphincter function 3 months before and after surgery were evaluated.

#### *Statistical analysis*

SPSS 10.0 software package was used for statistical analysis, and paired t test was used as the statistical method, and the difference with  $P < 0.05$  was considered significant.

#### **Results**

No vertebral artery or nerve damage was found during the surgery. 3 patients had postoperative cerebrospinal fluid leakage and did not merge headaches and dizziness. The wound healed after removal of the drainage tube and tightly suturing. 1 patient exhibited a wound with fat liquefaction at 6 days after the surgery, which healed 2 weeks after dressing change. These patients were followed up for 12 to 48 months with an average of 15 months. X-ray

results showed a good fracture healing 6 to 9 months after the surgery (**Figures 1-3**), and osseous fusion was observed in all the patients with bone graft fusion 3 to 6 months (mean 4.5 months) after the surgery. Cervical sequence was good, and lateral cervical spine X-ray for stretch and flexion showed that cervical vertebra was stable without loosening internal fixation, prolapse and fracture. For 4 patients who did not undergo bone graft fusion, it was found that atlantoaxial fracture healed during the follow-up visit, and internal fixations were removed 6 to 12 months (mean: 9 months) after the surgery. JOA score was 2~17 ( $15.24 \pm 3.86$ ) 3 months after the surgery, and the difference was statistically significant when compared with the preoperative score ( $t = 2.339$ ,  $P = 0.011$ ). In 9 patients with spinal cord damage, preoperative Frankel grades were as follows: 1 grade A, 2 grade B, 3 grade C and 4 grade D; 1 patient at grade B did not recover 6 months after the surgery, and 1 grade A was transferred into B, and 1 grade B was transferred into C, and 2 grade C were transferred into D, and 1 grade C was transferred into E, and 3 grade D were transferred into E (**Table 1**).

#### **Discussion**

##### *Diagnosis and initial classification for axis fracture combined with adjacent segmental instability*

Axis fractures were classified into odontoid fractures, vertebral pedicle fractures and vertebral fractures. Odontoid fracture was classified into three types [1] in accordance with Anderson'Alonzo classification. Vertebral pedicle fracture of the axis was known as Hangman fracture (also known as traumatic spondylolisthesis of the axis). Levine and Edwards classified the fracture into three types [2]. The vertebral body fractures of the axis were also classified into three types [3]. Previous studies showed that odontoid fracture could cause atlantoaxial instability [4]; The odontoid fractures combined with Hangman fractures may also result in co-existence of C2/3 instability [5], however, C1/2/3 was not studied as a whole. With high-energy injury increase such as traffic injury and fall injury, a variety of mechanisms would be involved, and the differences in violence orientation, size and time also caused fracture at more than two parts including odontoid fractures, vertebral pedicle fractures and

vertebral fractures, which may be accompanied by atlas and C3 fractures or C2/3 intervertebral disc injury. All these may result in axis fractures accompanied by adjacent segments instability, thus causing a potential risk on spinal cord and also inducing missed diagnosis, misdiagnosis and secondary damage. Imaging examination has a crucial role in the early diagnosis of axis fracture with adjacent segment instability. Clear lateral and open situation of cervical spine X-ray can identify axis fracture type and shifting, but most of patients are impossible to receive a standard X-ray examination of the upper cervical spine in the early stage because they have some associated injuries, and 5 patients in this group had severe traumatic brain injury and pneumothorax and didn't receive X-ray examination in the early stage. The patients who have a cervical spine injury suggested by conventional radiological examination or clinical manifestations and are very difficult to be diagnosed based on the conventional radiological examination, CT scans, 3D reconstruction and MRI should be performed as required [6, 7]. Lateral cervical radiographs for flexion/extension were suitable for old injury and were not used routinely because a satisfactory image for the neck muscle spasms cannot be obtained and may aggravate the existing injury in the early stage; it should also be done under the special guardianship if necessary. In this study, 47 axis fracture combined with adjacent vertebral segmental instability patients who had complete medical records were analyzed, and the classification was initially proposed on the basis of fracture type demonstrated by imaging, instability of atlantoaxial joint or C2/3: type A: axis fracture with C1/2 instability in 21 patients, type B: axis fracture with C2/3 instability in 17 patients, type C: axis fracture with C1/2 and C2/3 instability in 9 patients.

### *Surgical strategy and selection of methods*

If axis fracture involves the adjacent segment instability and even dislocation, it can easily lead to high cervical spinal cord injury and vertebro-basilar artery insufficiency, thus resulting in quadriplegia and even life-threatening condition. The principle for the surgery is that axis fracture type should be considered and the adjacent instable segments should be fixed to restore the stability between C1/2/3. Personalized surgical method should be select-

ed for each patient, thus achieving an effective fixation and preserve the movement phase of the spine as much as possible [8].

*Type A: axis fracture complicated with atlantoaxial joint instability:* In the axis fracture, the more common types are type II odontoid fracture, which has a higher non-healing rate. Ochoa et al reported that the non-healing rate of non-surgical treatment for such fracture was as high as 35%-85% [9], therefore, surgery treatment is more common for most of these patients at present. Anterior cannulated screw fixation is widely used in clinic because it has less trauma and less bleeding, and is conducive to fracture healing and doesn't lead to loss of atlantoaxial rotation function. Then, type II odontoid fractures are often complicated with atlas transverse ligament injury, atlantoaxial instability and even atlantoaxial dislocation; and simply fixed odontoid regardless of atlantoaxial joint stability may further aggravate the postoperative instability. Therefore, it is necessary to pay attention to atlantoaxial joint stability for type II odontoid fracture; the patients with transverse ligament or atlantoaxial dislocation by preoperative CT or MRI should undergo posterior atlantoaxial reduction and fixation. For the patients with type II odontoid fracture complicated with atlantoaxial joint instability, posterior atlantoaxial fixation is the first choice, and odontoid screw fixation can also be combined; if preoperative MRI results do not prompt the transverse ligament rupture and incomplete atlantoaxial joint dislocation, intertransversal fusion can not be performed, and internal fixation could be removed until fracture healing after the surgery, and atlantoaxial active function should be properly preserved. For the patients who have severe atlantoaxial dislocation and even are combined with comminuted atlas fracture, it is difficult to perform posterior atlantoaxial fixation, therefore, occipital cervical fusion can be applied. In 8 cases with axis fracture and axis fracture of this group, preoperative MRI results suggested that no significant transverse ligament rupture was observed, among them, 7 patients underwent posterior atlantoaxial pedicle screw fixation and did not undergo bone graft fusion; 1 patient with comminuted axis fracture could not undergo atlas pedicle screw fixation, but underwent occipital cervical fusion; all internal fixation was removed 6 months to 1 year after the surgery. Therefore, as for the patients with A-type injury,

axis fracture is considered while atlantoaxial joint should also be stabilized.

*Type B: axis fracture complicated with C2/3 joint instability:* Axis fracture complicated with C2/3 joint instability is mainly caused by severe vertebral body fracture and/or Hangman fracture. Since Levine-Edwards type II and type II A Hangman fractures belong to unstable fracture [2] the conservative treatment or simple epistropheus fixation are likely to result in secondary aggravation of C2/3 joint instability, spinal cord compression etc., therefore, such fractures are usually combined with C2/3 intervertebral disc injury and/or anterior-posterior longitudinal ligament damage and even C2/3 dislocation, For therapy of such fractures, some methods can be selected such as anterior discectomy, bone graft fusion, plate osteosynthesis as well as posterior vertebral pedicle or lateral mass screw fixation. Anterior approach should be first considered when intervertebral disc injury or C2/3 joint instability exist because it can not only remove damaged disc directly, relieve the oppression of the spinal cord, restore normal spinal sequence and reconstruct C2/3 stability, but also has a lower risk to damage spinal cord and aorta [10]. Posterior surgery can be chosen when spinal cord is compressed by the posterior. Anterior approach could not restore dislocated facet joint for type III Hangman fracture and could not correct kyphosis to reach the anatomical reduction for C2/3 severe dislocation, therefore, we can choose the anterior-posterior approach which fully can relieve the oppression and stabilize C2/3 joint.

*Type C: axis fracture complicated with atlantoaxial joint and C2/3 joint instability:* Axis fracture complicated with atlantoaxial joint and C2/3 joint instability is the most complicated type, whose therapy not only needs to stabilize atlantoaxial and C2/3 joints and relieve the oppression of the spinal cord when neurologic symptoms exist, but also consider physiological function of the upper cervical vertebra. Xie et al. [11] reported that C2/3 anterior plate decompression and fusion with bone graft fusion plus odontoid screws fixation were used to treat unstable Hangman fracture complicated with odontoid fracture. However, for such patients combined with transverse ligament injury, atlantoaxial joint dislocation and other atlantoaxial joint instability, odontoid screws

fixation cannot be used to stabilize atlantoaxial joint and even make an effect on C1-3 stability after surgery. Our presented patients mostly received posterior C1-3 fixation, which provides a good immediate stability and easy reduction, and allows placing bone grafts in the posterior joint on both sides, is independent of integrity of C1-3 posterior structure and has high fusion rates. Horn et al. found that C1-3 screw fixation of lateral mass provides better effects of immobilization, anti-fatigue and anti-subsidence for unstable upper cervical vertebra [12]. But this approach needs a greater surgical technology and video equipment for monitoring, thus causing a higher risk for vertebral artery injury. Moreover, screw placement is difficult sometimes. In these cases, occipitocervical fusion can be applied in order to relieve the oppression, fix fractured vertebral body and stabilize C1-3.

Therefore, as for patients with axis fracture and adjacent segment instability, we should give consideration to both axis fracture and its adjacent segment instability to determine the fracture type and judge damage of atlantoaxial joint and C2/3 joint stability. According to different classifications, the corresponding treatment can be given to achieve good curative effect.

### Conclusion

Axis fracture complicated with adjacent segment instability should be treated individually based on the fracture type and adjacent segment instability. Our classification can be used to guide the surgical management.

### Disclosure of conflict of interest

None.

**Address correspondence to:** Dr. Lei Wang, Department of Orthopedics, First People's Hospital Affiliated to Shanghai Jiaotong University, No. 100, Haining Road, Shanghai 200080, China. E-mail: wanglewlwl@163.com

### References

- [1] Harrop JS, Hart R and Anderson PA. Optimal treatment for odontoid fractures in the elderly. *Spine* 2010; 35: S219-S227.
- [2] Rayes M, Mittal M, Rengachary SS and Mittal S. Hangman's fracture: a historical and biomechanical perspective: Historical vignette. *J Neurosurg Spine* 2011; 14: 198-208.

## Treatment of axis fracture

- [3] Koller H, Acosta F, Forstner R, Zenner J, Resch H, Tauber M, Lederer S, Auffarth A and Hitzl W. C2-fractures: part II. A morphometrical analysis of computerized atlantoaxial motion, anatomical alignment and related clinical outcomes. *Eur Spine J* 2009; 18: 1135-1153.
- [4] Mimatsu K, Katoh F, Kawakami N and Nakagami W. Atlantoaxial fusion with posterior double wire fixation. *Spine* 1992; 17: 1409-1413.
- [5] Bristol R, Henn JS and Dickman CA. Pars screw fixation of a hangman's fracture: technical case report. *Neurosurgery* 2005; 56: E204.
- [6] Pratt H, Davies E and King L. Traumatic injuries of the c1/c2 complex: computed tomographic imaging appearances. *Curr Probl Diagn Radiol* 2008; 37: 26-38.
- [7] Jia LS. Basic concepts of diagnosis and treatment of occipital cervical injuries. *Chinese Journal of Trauma* 2007; 23: 3-5.
- [8] Tan MS and Zhang GB. Thoughts on therapies and surgical indications for atlantoaxial instability. *Chinese Journal of Spine and Spinal Cord* 2006; 16: 330-331.
- [9] Ochoa G. Surgical management of odontoid fractures. *Injury* 2005; 36: S54-S64.
- [10] Tuite GF, Papadopoulos SM and Sonntag VK. Caspar plate fixation for the treatment of complex hangman's fractures. *Neurosurgery* 1992; 30: 761-764.
- [11] Xie N, Khoo LT, Yuan W, Ye XJ, Chen DY, Xiao JR and Ni B. Combined Anterior C2-C3 Fusion and C2 Pedicle Screw Fixation for the Treatment of Unstable Hangman's Fracture: A Contrast to Anterior Approach Only. *Spine* 2010; 35: 613-619.
- [12] Horn EM, Hott JS, Porter RW, Theodore N, Papadopoulos SM and Sonntag VK. Atlantoaxial stabilization with the use of C1-3 lateral mass screw fixation: technical note. *J Neurosurg Spine* 2006; 5: 172-177.