

Original Article

Exploratory study of oral mucosal colonization of human gastric *Helicobacter pylori* in mice

Xueqin Wan¹, Dongsheng Tang¹, Xiaohuan Zhang², Hongming Li¹, Zhixin Cui¹, Sijuan Hu³, Ming Huang¹

¹Department of Pathogenic Microbiology, Foshan University, Foshan, Guangdong, 528000, China; ²Guanghua School of Stomatology, Sun Yat-Sen University, Guangzhou, Guangdong, 510000, China; ³Department of Gastroenterology, Xijing Hospital, Xi'an, 710032, China

Received January 27, 2014; Accepted February 11, 2014; Epub March 15, 2014; Published March 30, 2014

Abstract: In this study, human gastric *Helicobacter pylori* (Hp) was closely attached to the pre-treated mouse buccal mucosa by using artificial oral film to induce the growth and colonization of Hp on the buccal mucosa in mice. Sixty BALB/c mice were divided into three groups, in which Hp biofilm colonization was detected in three mice in Hp film group (Hp mesh biofilm accumulation under an optical microscope; Hp accumulated colonization under an electron microscope). There were no Hp biofilms detected in Hp smear group or the control group with black film. In this study, human gastric Hp was first used to artificially induce the growth and colonization of Hp on the buccal mucosa in mice. The mouse model of oral infection with Hp was initially established, providing animal experimental evidences for oral conditions of growth and colonization of Hp on the buccal mucosa in mice, and providing a workable animal modeling method for further research of joint infection of Hp on the mouth and stomach, as well as the relationship between oral Hp and gastric Hp.

Keywords: *Helicobacter pylori*, oral colonization, mouse model

Introduction

Helicobacter pylori (Hp) were a primary prevention target of gastric cancer. The difficulty of Hp prevention lied in the eradication of Hp recurrence [1]. Since the first successful isolation and culture of Hp from the dental plaques in patients with gastritis by Krajden et al [2] in 1989, some scholars began to raise the oral cavity as another important gathering place of Hp, which was the major cause of gastric Hp recurrence. There were more and more reports on the correlation between gastric Hp and oral Hp [3], for example, there was a molecular homology between gastric Hp and oral Hp; [4] and the treatment of dental plaques could significantly reduce the recurrence rate of gastric Hp [5, 6]. In recent years, the hypothesis that the recurrence of gastric Hp was mainly caused by its gathering in the oral cavity has been increasingly concerned [3-7].

However, other scholars believed that oral Hp was not the source of gastric Hp, but the pass-

er-by on its way back into the oral cavity [3]. Factions debated [8], and the two parts were mostly based on clinical data other than animal experimental evidences strictly implemented according to Koch's postulates. The animal models were mostly those infected with gastric Hp in the gastric area other than those infected with gastric Hp in the oral cavity, or other than those secondarily infected with oral Hp in the gastric area, which leading to in vivo study of joint infection of oral Hp and gastric Hp.

This article reported a new exploratory animal experimental method by attaching human gastric Hp on mouse oral mucosa to induce the growth and colonization of Hp on the oral mucosa by using artificial oral film. This study provided animal experimental evidences for oral conditions of growth and colonization of Hp on the buccal mucosa in mice, and provided a workable animal modeling method for further research of joint infection of Hp on the mouth and stomach, as well as the relationship between oral Hp and gastric Hp.



Figure 1. Isolation and culture of *Helicobacter pylori* with the candle jar method.




Figure 2. *Helicobacter pylori* cultures and colonies.

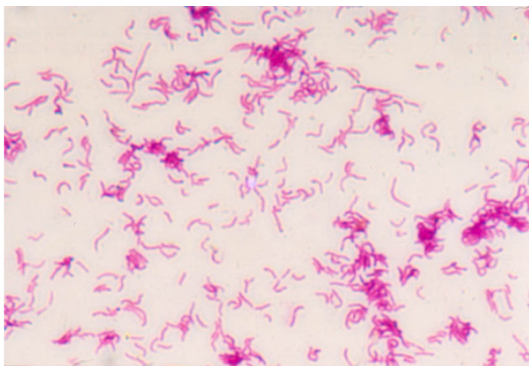


Figure 3. Oil endoscopy of gram stained-*Helicobacter pylori*.

Materials and methods

Source, identification and culture of strains

The endoscopic biopsy specimens of clinical patients with gastritis (taken from the Gastroendoscopy Room of the Third Affiliated Hospital of Guangzhou Medical College, with patients' informed consent) that showed positive by C14-urea breath test were inoculated on the Brandt selective medium containing 7.5% sterile rabbit blood prepared within one week, and cultured at 37°C for 5-7 days under the micro-aerobic conditions provided by the candle jar method. Based on the colony morphology, gram stained bacterial morphology, urease, oxidase and catalase tests, it was identified as Hp [9]. The pure cultures of Hp were then extracted.

Animals and anesthesia

There were a total of sixty SPF-level BALB/c male mice in three groups, weighed from 22 g to 25 g, $n = 20$. They were provided by the Guangdong Medical Laboratory Animal Center. According to the provisions of Animal Safety and Management and Animal Welfare and Ethics, mice were anesthetized with enflurane in all of the irritation experiments. Specifically, mice were first intraperitoneally ($0.8 \text{ ml}\cdot\text{kg}^{-1}$) or subcutaneously ($1.5 \text{ ml}\cdot\text{kg}^{-1}$) injected with enflurane, and then underwent the following experimental operations after the reduction of avoidance reflex.

Pre-treatment of mouse oral cavity

The buccal mucosa was in a relatively larger area and less affected by oral motions, with strong compliance of operations, so that chemical method was used to induce the formation of erosive lesions on the buccal mucosa of mouse oral cavity. Specifically, a sterile cotton swab dipped with 3% hydrochloric acid alcohol was smeared on the buccal mucosa of mice. The local lesions were observed until the emergence of exudation or erosion of mucosal inflammation.

Hp colonization of the oral mucosa in mice

The mouse oral Hp film was made to promote long-term adhesion of Hp on the oral mucosal

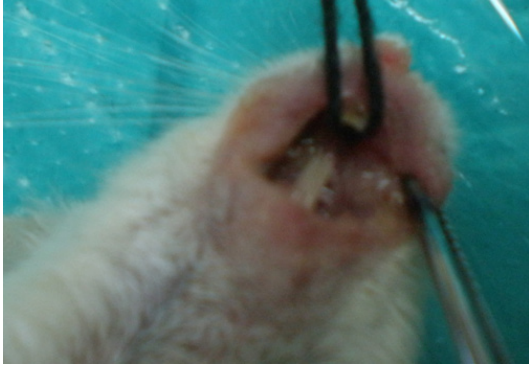

Figure 4. Hp colonization in mouse buccal mucosa (positive).

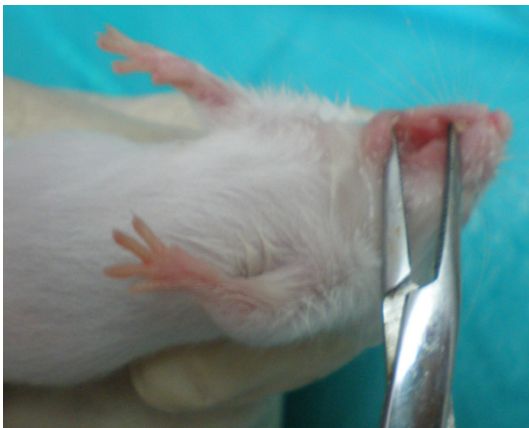


Figure 5. Hp colonization in mouse buccal mucosa (negative).

surface, prolong the residence time of Hp in the oral mucosa or lesions, and induce Hp colonization. The film standards included long time of adhesion, no mucosal irritation, good compliance, and no interference with mouse activities and diets. The film material was film-forming polyvinyl alcohol (PVA) and binder sodium carboxymethyl cellulose (CMC-Na) $[C_6H_7O_2(OH)_x(OCH_2COONa)_y]_n$, both of which were commonly used dental film materials [10].

Preparation of blank film

The ratio of polyvinyl alcohol film (PVA) and sodium carboxymethyl cellulose (CMC-Na) was 5:5, with a total of 50 g, which were soaked in appropriate amount of water and dissolved by heating. 10 mL of glycerol was added, followed by stirring, coating the film, drying, and opening the film. The film was cut into 1 cm × 1 cm

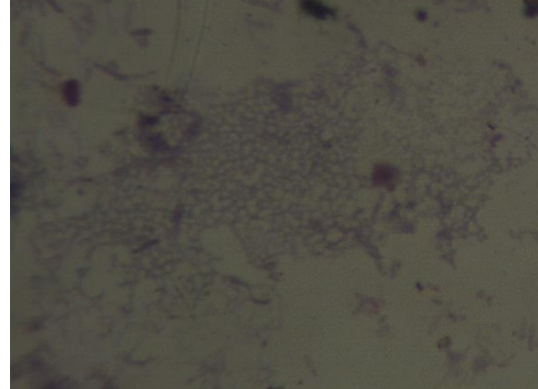


Figure 6. Mesh Hp biofilm by oil microscopy of gram stained-mouse oral mucosal surface.

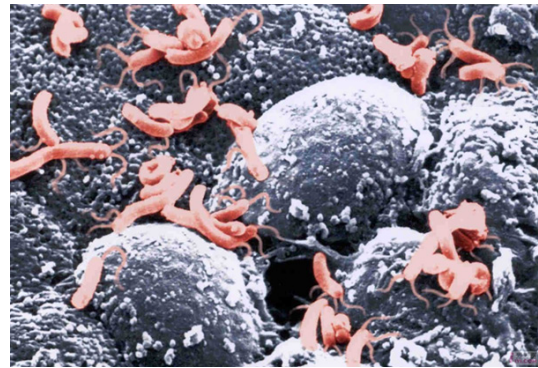


Figure 7. Hp colonization under an electron microscope.

blocks. They could be attached on the buccal mucosa for 4-10 h [11, 12].

Preparation and usage of Hp film

Two or three Hp colonies were taken from the in fresh cultures and directly smeared on the inside of the blank film. The inner side was quickly attached on the lesions of mouse erosion, which was tightened by pushing for half a minute. The Hp colonization testing as made after one week.

Hp biofilm detection

Oil microscopy: The mucus was taken from the lesion with a sterile swab and its smear underwent gram staining and oil microscopy, followed by photographing. **Electron microscopy:** The diseased mice were directly sent to the Electron Microscopy Room of Southern Medical University to get photos.

Results

Isolation, culture and identification of human gastric Hp and acquirement of Hp pure cultures

H. pylori was successfully isolated from the endoscopic biopsy specimens of clinical patients with gastritis and cultured with candle jar method (**Figure 1**). *H. pylori* inoculated on the Brandt selective medium was hoary, semitransparent and rough microcolony (**Figure 2**). Gram stained and oil immersion lens were used to detect *H. pylori*. Typical gram stained bacterial morphology of *H. pylori* showed gram-negative bacterium with seagull shaped, S shape or arc-shaped (**Figure 3**). Bacterium with positive urease, oxidase and catalase tests was identified as *Hp*.

Artificial induction of oral colonization of Hp in mice

Hp film group: Twenty mice were pre-treated on the oral mucosa of mice with the chemical method. After the occurrence of the exudation of slight inflammation, the oral film smeared with human gastric *Hp* pure cultures was attached on the exudation site. The growth condition of *Hp* biofilm was detected after 7 days. Results: Six of twenty mice were died after chemical treatment of the oral cavity; six were died within three days after being attached with the film; three of eight surviving mice were detected with biofilms. The results of mice were shown in **Figures 4 and 5**.

Hp swearing group: *Hp* pure cultures were directly smeared on the pre-treated oral mucosa of twenty mice for a total of continuous five days, once a day. Results: Seven of twenty mice were survived until the end of experiment, but no mice were detected with *Hp* biofilms.

Control group with blank film: Twenty mice were attached on the pre-treated oral mucosa of mice with blank films without *Hp*. Results: Nine mice were still alive at the end of the experiment, but no mice were detected with *Hp* biofilms.

Microscopy of biofilm on mouse oral mucosa

The findings of oil microscopy of two mice with positive *Hp* biofilms showed that *Hp* was woven into a mesh and *Hp* was bent to an O-like type.

The findings of electron microscopy showed that *Hp* was stacked together showing a screw shape (**Figures 6, 7**).

Discussion

In 1983, Warren and Marshall [13] isolated *Hp* from patients with chronic active gastritis through the gastric biopsy. Since then, *Hp* has been confirmed by a large number of studies to be a major pathogenic factor of chronic gastritis and peptic ulcer, and an important pathogenic factor of gastric cancer and gastric mucosa-associated lymphoid tissue lymphoma. In 1989, Krajden et al [2] first isolated and cultured *H. pylori* from the dental plaques in patients with gastritis, and speculated that oral cavity might be another gathering place of *H. pylori* in the human body. Since then, the research of oral *H. pylori* has become a hot. In 1993, Ferguson et al [14] first cultured one case of *H. pylori* with viability from nine cases of saliva in patients with gastritis. Since then, a large number of literatures have reported the existence of *H. pylori* in the oral cavity, as well as its relationship with gastric *H. pylori*. Interestingly, there were two different views on the source of oral *H. pylori*. In one view, oral *H. pylori* believed to be derived from the gastric area; oral *H. pylori* were easier systematically eradicated than gastric *H. pylori*; oral *H. pylori* might be just the temporary retention of *H. pylori* on the way back into the oral cavity [3]. In another view, the oral cavity was believed to be the source of gastric *H. pylori*; oral *H. pylori* were more difficult to be systematically eradicated than gastric *H. pylori*; oral *H. pylori* might be used as normal flora in the oral cavity and became the sources of infected and re-infected with gastric *H. pylori* [15].

Whether *Hp* first occurred in the stomach, or was first colonized in the oral cavity? Whether *Hp* detected in the oral cavity was that back into the oral cavity by gastric *Hp*, or *Hp* was first colonized in the oral cavity, infected the stomach, and induced the colonization of gastric *Hp*? And whether oral *Hp* was the origin of gastric *Hp* recurrence? So far these problems were still pended [3-8, 14-19]. It has been reported that *Hp* on the gastric mucosa in part of the patients with gastrosis might still relapse after eradication therapy, which might be caused by residual *Hp* repeated entering into the stomach

and re-colonization on the gastric mucosa. Therefore, oral Hp was probably to be a potential factor of gastric reinfection [16, 17]. There were also literatures believed that oral Hp might be caused by the shift of gastric bacteria due to gastroesophageal reflux [18, 19].

All of the data collected from the literatures were derived from specimens of clinical patients. There were no data from animal experiments of oral Hp that followed Koch's postulates. Therefore, first of all, gastric Hp was isolated and cultured with the gastric biopsy specimens from clinical informed patients. Second, the pure cultures of gastric Hp were used to infect the buccal mucosa by artificial inducing method. Finally, the formation and colonization of Hp biofilm were successfully detected on the buccal mucosa of mice. The bacterial biofilms referred to that the bacteria were bound and adhered to the receptors on the epithelial cell surface, and secreted extracellular polysaccharide polymers. The bacteria were adherent to each other in a very fine manner, so that the membrane was formed. It could play barrier and space-occupying protective effects, contribute to the formation and stability of the micro-environment within the biofilm. This was a necessary step of long-term colonization of bacteria. The significance of this study lied in that the oral cavity was proved to be suitable for the growth and colonization of Hp by animal experiments, and thus it was speculated to be the gathering place of oral Hp. The significance also lied in that certain conditions were necessary to be provided in the artificial induction of Hp colonization in the mouse oral cavity, namely, the oral mucosal injury and micro-aerobic microenvironment existed in the oral cavity. It was speculated that the damaged mucosa might provide nutrients essential for the growth of Hp, and the micro-aerobic micro-environment was required for the growth of Hp.

One of the keys to the success of this study was the use of a strain derived from human Hp. They were derived from the pure Hp cultures obtained by in vitro isolation and culture of clinical gastric biopsy specimens by the candle jar method. This method was simple and mature, especially for laboratories with poor conditions. Considering the study of mouse model of oral Hp was innovative, this study referred to the experimental study of mouse model of gastric Hp that was relatively mature. Currently, rela-

tively stable animal models of gastric Hp at home and abroad [20-23], were accomplished by long-term domestication of Hp strains. Continuous in vivo infections could alter the metabolic activity of Hp and enhance the vitality of Hp colonization. This study showed that all of the used Hp strains were the first generation of in vitro cultures of fresh gastric mucosa for the Hp biofilm-positive mice. It was hypothesized that this kind of Hp bacteria had strong vitality and colonization ability due to its long-term in vivo domestication in the human stomach. The study found that after several passages in vitro, Hp would appear variations in the bacterial morphology and flagella, thereby affecting the ability of Hp colonization in the oral cavity of mice. By screening the Hp strains, we found that the internal environment could enhance the vitality of Hp infection. We speculated that Hp with low in vitro motility, if with the opportunity to take the lead infection in the oral cavity, would be acclimated and enhanced its vitality in the oral environment, and thus had the opportunity of entering into the stomach with foods. After the neutralization of gastric acid with foods, Hp was better able to maintain the vitality, followed by infection and colonization in the gastric mucosa, resulting in gastric infection or recurrence of Hp.

The second key issue addressed in this study was the exploration of Hp colonization conditions in the mouse oral cavity. Hp was a kind of micro-aerobic bacterium with higher nutritional requirement. The basic conditions for its in vivo colonization included blood nutrients, low oxygen pressure or low Eh, pH 6-8. It was an indisputable fact that Hp was colonized in the stomach. However, it was still controversial whether Hp was colonized in the oral cavity. Comparing the micro-environment of stomach and the oral cavity, Hp colonization in the oral cavity was critical to create a micro-oxygen environment or reduce Eh. Different parts of the human oral cavity were differently affected by the local O₂ exposure, aerobic and facultative anaerobic mixed infections, and pathological changes of tissues, orthodontic and restorative treatment and other factors. The partial pressure of oxygen or Eh had been largely changed [24]. The normal buccal fold (0.3% O₂) and periodontal pocket (-50 mV) were sufficient to cause the growth of anaerobic bacteria. There were a lot of plaques, debris, calculus, food debris and inflammatory exudates in the periodontal pockets of patients. These substances provided the

suitable temperature, humidity, pH and nutrition environment for Hp colonization in the oral cavity. The depth of the periodontal pocket provided a good micro-ecological environment and protective function for the survival of Hp, and offered the potential of Hp gathering [25]. In this study, the mouse oral mucosa was pre-treated to be with the nutritional conditions of Hp growth. The microhabitat of mouse buccal mucosa was changed by using the artificial film. A microaerophilic environment suitable for Hp growth was created. Consequently, the Hp bio-film was successfully artificially induced on the buccal mucosa in mice. However, only part of mice in the experimental group and the control group completed the entire process of the experiment due to their small bodies, great difficulties in the operations, and their limited tolerance. However, the number of death in three groups was similar, indicating that the death of mice during the experiment was not directly related to the infection with Hp. In this study, the oral microhabitats laws and characteristics of onset and completion of Hp colonization were explored after establishing the animal model of Hp infection in the oral cavity; the successful establishment of mouse model of oral mucosa of Hp colonization provided an animal model for the study of human oral Hp, laid an experimental basis for further establishment of the joint infection of oral Hp and gastric Hp, and provided a new research idea for further in vivo of reveal the relationship between oral Hp and gastric Hp.

Acknowledgements

The study was supported by Scientific Fund of Foshan University & National and Provincial College Innovation Projects (201311847016, 1184713047); Science and Technology Program & Natural Science Foundation of Guangdong Province (2010B031600150, 09111526000-04).

Disclosure of conflict of interest

None.

Address correspondence to: Dongsheng Tang, Medical School, Foshan University, Foshan, Guangdong, 528000, China. E-mail: tangdsh@163.com

References

[1] Wan XQ, Li HM and Bai Y. Advances in phage therapy of *Helicobacter pylori* infection. World

Chinese Journal of Digestology 2009; 17: 3623-3626.

[2] Krajden S, Fuksa M, Anderson J, Kempston J, Boccia A, Petrea C, Babida C, Karmali M and Penner JL. Examination of human stomach biopsies, saliva, and dental plaque for *Campylobacter pylori*. J Clin Microbiol 1989; 27: 1397-1398.

[3] Zou QH and Li RQ. *Helicobacter pylori* in the oral cavity and gastric mucosa: a meta-analysis. J Oral Pathol Med 2011; 40: 317-324.

[4] Wang ZJ. *Helicobacter pylori* in oral effect of gastritis. Sichuan Med J 2012; 33: 2048-2050.

[5] Hou HL, Meng HX, Hu WJ and Wang JW. The relationship between *Helicobacter pylori* in oral cavity and the Hp infection in stomach. Chin J Stomatol 2003; 38: 327-329.

[6] Wu ZP, Wu XR and Ji F. The affect of oral *Helicobacter Pylori* infection on the radical rate of gastric *Helicobacter Pylori*. Beijing Med J 2012; 34: 765-767.

[7] Liu P, Yue J, Han S, Deng T, Fu C, Zhu G and Chen D. A cross-sectional survey of dental caries, oral hygiene, and *Helicobacter pylori* infection in adults. Asia Pac J Public Health 2013; 25: 49S-56S.

[8] Al-Ahmad A, Kurschner A, Weckesser S, Wittmer A, Rauberger H, Jakob T, Hellwig E, Kist M and Waidner B. Is *Helicobacter pylori* resident or transient in the human oral cavity? J Med Microbiol 2012; 61: 1146-1152.

[9] Wan XQ, Zhou PZ, Ma F, Li WKL, Tan SY and Qi J. Candle jar fractional cultivation and cryopreservation of *Helicobacter pylori*. J Foshan University (Natural Science Edition) 2011; 29: 82-85.

[10] Li D, Wang J and Hou HM. Progress of Buccal Mucosa Drug Delivery System. Chin J Pharmaceuticals 2009; 40: 303-307.

[11] Wu WT, Xu HN and He M. Development of Laminated adhesive Eilms of Unidirectional Release of Metronidazole Applicable (original on page) to Mucous Membrane in Oral Cavity. Chin J Hospital Pharmacy 1991; 11: 8-47.

[12] Zhang SN, Tang RY, Zhang YM, Wang CF and Wu ZA. Galla Chinensis sustained-release film experimental study on the treatment of oral ulcer. J Clin Stomatol 2011; 27: 83-84.

[13] Unidentified curved bacilli on gastric epithelium in active chronic gastritis. Lancet 1983; 1: 1273-1275.

[14] Ferguson DA Jr, Li C, Patel NR, Mayberry WR, Chi DS and Thomas E. Isolation of *Helicobacter pylori* from saliva. J Clin Microbiol 1993; 31: 2802-2804.

[15] Bago I, Bago J, Plecko V, Aurer A, Majstorovic K and Budimir A. The effectiveness of systemic eradication therapy against oral *Helicobacter pylori*. J Oral Pathol Med 2011; 40: 428-432.

Oral mucosal colonization of *Helicobacter pylori*

- [16] Miyabayashi H, Furihata K, Shimizu T, Ueno I and Akamatsu T. Influence of oral *Helicobacter pylori* on the success of eradication therapy against gastric *Helicobacter pylori*. *Helicobacter* 2000; 5: 30-37.
- [17] Yang HT. [Nested-polymerase chain reaction in detection of *Helicobacter pylori* in human dental plaque]. *Zhonghua Yi Xue Za Zhi* 1993; 73: 750-752, 774.
- [18] Zaman C, Osaki T, Hanawa T, Yonezawa H, Kurata S and Kamiya S. Analysis of the microbial ecology between *Helicobacter pylori* and the gastric microbiota of Mongolian gerbils. *J Med Microbiol* 2014; 63: 129-137.
- [19] Madinier IM, Fosse TM and Monteil RA. Oral carriage of *Helicobacter pylori*: a review. *J Periodontol* 1997; 68: 2-6.
- [20] Benoit SL, Miller EF and Maier RJ. *Helicobacter pylori* stores nickel to aid its host colonization. *Infect Immun* 2013; 81: 580-584.
- [21] Guo G, Liu KY, Xie QH, Zhang WJ and Zou QM. Establishment of a BALB/c mouse model infected steadily with *H pylori* through serial passages in vivo. *World Chinese Journal of Digestology* 2007; 15: 1338-1341.
- [22] Lebwohl B, Blaser MJ, Ludvigsson JF, Green PH, Rundle A, Sonnenberg A and Genta RM. Decreased Risk of Celiac Disease in Patients With *Helicobacter pylori* Colonization. *Am J Epidemiol* 2013; 178: 1721-1730.
- [23] Kronsteiner B, Bassaganya-Riera J, Philipson C, Viladomiu M, Carbo A, Pedragosa M, Vento S and Hontecillas R. *Helicobacter pylori* infection in a pig model is dominated by Th1 and cytotoxic CD8+ T cell responses. *Infect Immun* 2013; 81: 3803-3813.
- [24] Wichelhaus A, Brauchli L, Song Q, Adler G and Bode G. Prevalence of *Helicobacter pylori* in the adolescent oral cavity: dependence on orthodontic therapy, oral flora and hygiene. *J Orofac Orthop* 2011; 72: 187-195.
- [25] Chen J, He XY, Wu LL and CHE TJ. The correlation between oral colonization of *Helicobacter pylori* and gastrointestinal disease. *Hua Xi Kou Qiang Yi Xue Za Zhi* 2011; 29: 351-354.