

Original Article

Hybrid PET/MR imaging in two sarcoma patients – clinical benefits and implications for future trials

Sasan Partovi^{1*}, Andres A Kohan^{1*}, Lisa Zipp², Peter Faulhaber¹, Christos Kosmas¹, Pablo R Ros¹, Mark R Robbin¹

¹Department of Radiology, University Hospitals Seidman Cancer Center, University Hospitals Case Medical Center, Case Western Reserve University, Cleveland, Ohio; ²Department of Pediatrics, Rainbow Babies and Children's Hospital, University Hospitals Case Medical Center, Cleveland, Ohio. *Equal contributors.

Received February 3, 2014; Accepted February 18, 2014; Epub March 15, 2014; Published March 30, 2014

Abstract: PET/MRI is an evolving hybrid imaging modality which combines the inherent strengths of MRIs soft-tissue and contrast resolution and PETs functional metabolic capabilities. Bone and soft-tissue sarcoma are a relatively rare tumor entity, relying on MRI for local staging and often on PET/CT for lymph node involvement and metastatic spread evaluation. The purpose of this article is to demonstrate the successful use of PET/MRI in two sarcoma patients. We also use these patients as a starting point to discuss how PET/MRI might be of value in sarcoma. Among its potential benefits are: superior TNM staging than either modality alone, decreased radiation dose, more sensitive and specific follow-up and better assessment of treatment response. These potentials need to be investigated in future PET/MRI soft-tissue sarcoma trials.

Keywords: PET/MRI, PET/CT, FDG, sarcoma, molecular hybrid imaging

Introduction

Sarcomas are a rare group of tumors, comprising less than 1% of all newly diagnosed cancers and accounting for 2% of all cancer related deaths with a 5 year survival rate of 60% [1-3]. While MRI is the mainstay for sarcoma imaging [4, 5], other imaging technologies, such as CT and PET/CT, also play important roles in the management of this disease. For staging purposes, MR has high sensitivity for tumor detection and local staging. In post-treatment patients MR with Gadolinium is often helpful to differentiate between residual or recurrent tumor from postoperative or treatment induced changes [6]. Prior to surgery a CT of the thorax delivers valuable information with regard to lung metastases. PET/CT is of importance in high-grade cases for lymph node assessment and diagnosis of metastatic spread, including lung metastasis [7-9].

PET/MRI was recently introduced in the clinical arena as an evolving hybrid imaging modality mainly applied in oncologic patients. This technique leverages the inherent strengths of MRI,

with its high soft-tissue and contrast resolution and multiparametric sequences, with those of PET which can track tumor metabolism with high sensitivity. Clinical experience with PET/MRI is still limited and mainly includes neuroradiology applications [10-12]. Recently PET/MRI was also evaluated for tumors in the chest and abdomen with promising results [13, 14].

A current major challenge of this hybrid imaging modality is attenuation correction. The need of a reliable MR based attenuation correction map for accurate standardized uptake values (SUVs) measurements is critical. The commercially available techniques are based on segmentation and classification of different types of tissue [15, 16]. The three segment model (air, soft tissue and lung) uses a T1 weighted multi-station spoiled gradient echo sequence [17] and has been proven to be accurate when compared to a transmission based approach and to CT attenuation correction [18-20]. The four segment model (air, soft tissue, fat and lung) uses a T1 weighted 2-point Dixon sequence that generates in-phase, out-of-

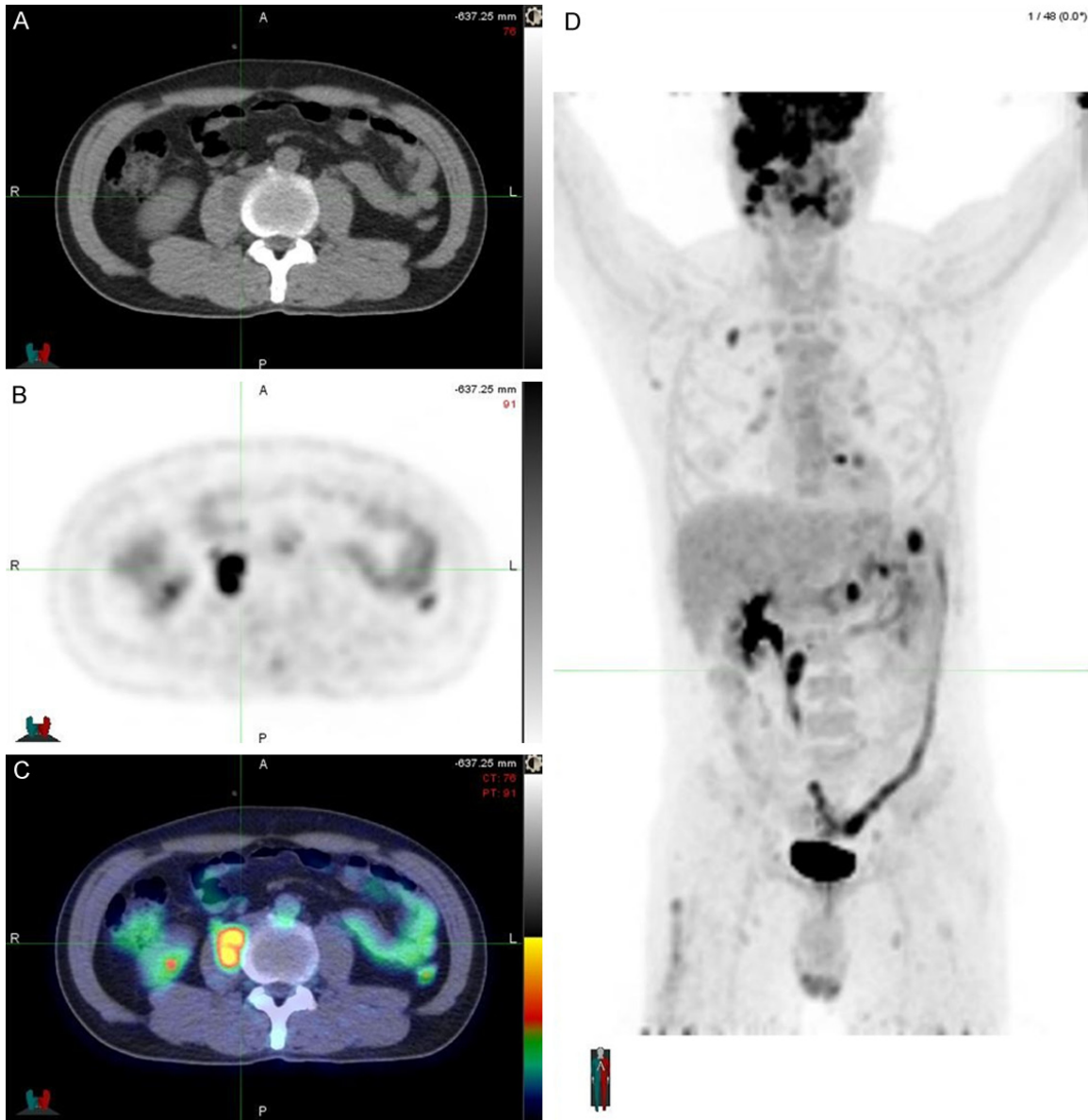


Figure 1. Initial PET/CT done during radiation therapy shows spread of the disease beyond the primary tumor. Increased uptakes are noticeable in the head, upper right lung, upper left abdominal quadrant and right psoas (D). Uptake in the descending colon was interpreted as physiologic. Axial CT (A), PET (B) and fusion (C) images show in more detail the lesion described in the psoas, which is slightly noticeable in the CT image (A) as a less hypodense structure inside the psoas and presents homogeneous FDG uptake in the PET image (B).

phase, water and fat only images applying different echo times [21]. Nonetheless with current attenuation correction techniques cortical bone cannot be reliably detected, leading to errors of up to 18% in quantitative approaches using MR based attenuation correction [22].

Despite the aforementioned challenges, PET/MRI has potential benefits in oncology applications in which high soft-tissue contrast is required or in which frequent follow-up studies

in a young patient population without major irradiation exposure have to be conducted [5]. Even before the introduction of PET/MRI systems the valuable approach of combining functional PET information with the anatomical detail of MRI has been discussed [23]. The purpose of this technical report is to show our experience using PET/MRI in two patients with sarcoma and discuss the potential clinical value of PET/MRI in this population for future trials.

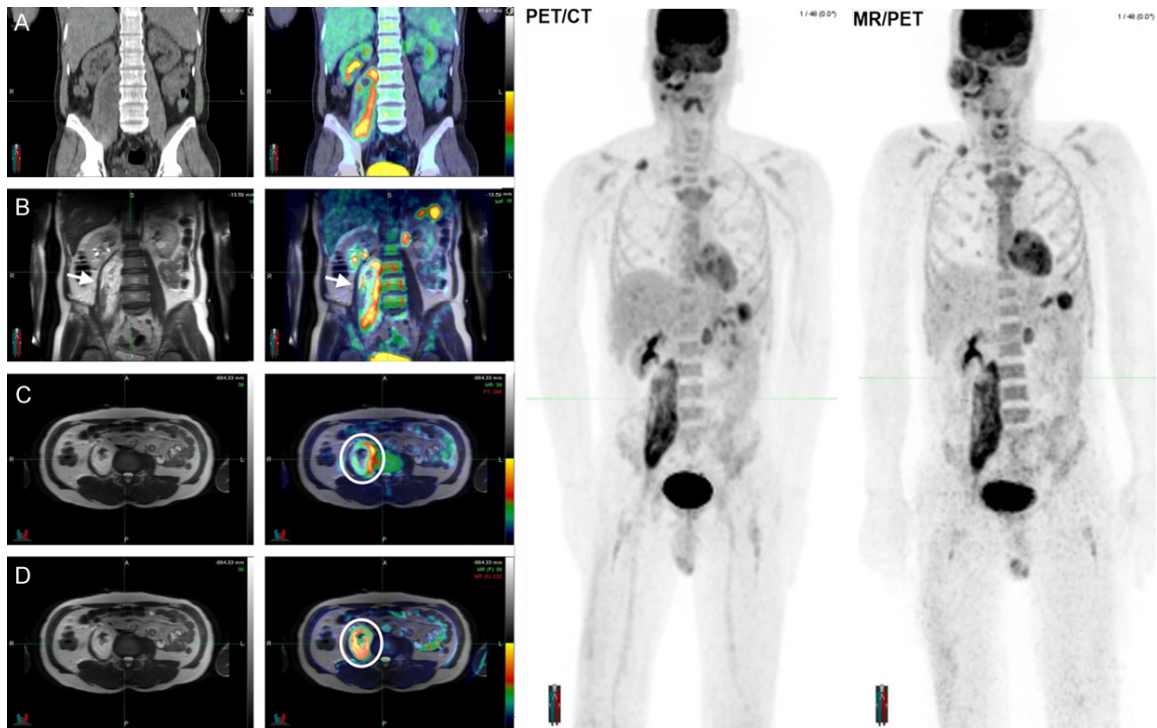


Figure 2. Coronal CT reconstruction (A) and coronal T2w (B) fused with their corresponding PET in the contiguous image (row A and B), reveals the higher soft-tissue resolution of MRI, allowing the identification of healthy muscle (arrow) that is displaced by the heterogeneous tumor. Axial T2w (C and D) fused with the corresponding PET (row C) and the DWI (row D) show the discrepant findings described in the text. Direct comparison of the PET MIPs shows the successful performance of PET/MRI and the MR based attenuation correction map.

Both patients were enrolled in HIPAA compliant studies which were approved by the local IRB committee. The patients gave written informed consent prior to enrollment.

Patient #1

A 49-year old male patient complaining of facial swelling and dysphagia underwent surgery four months prior to the PET/MRI for initial treatment and staging purposes of a maxillary sinus mass. During surgery it was observed that the tumor extended into the maxillary sinus infiltrating the roof. As the intraoperative biopsy could not establish a clear diagnosis, a maxillectomy was initially performed. After pathological confirmation of the tumor etiology (spindle cell maxillary sinus sarcoma) a revision maxillectomy as well as orbital exenteration and ethmoidectomy followed by free flap reconstruction was performed to pursue the surgical treatment.

Because of tumor recurrence shortly after surgery adjuvant radiotherapy was initiated (exter-

nal beam radiation, total dose of 70.2 Gy). After 5 treatments of 10 Gy, the patient noticed swelling in the right maxillary sinus flap, thus an MRI of the area was requested. Findings in the MR suspicious for recurrence and spread to adjacent lymph nodes prompted a treatment plan change increasing the dose to the recurrent tumor and extending the field caudally to cover the involved lymph nodes. Due to the recurrence and apparent progression of the disease the patient was referred to our department for PET/CT, which showed further disease progression with multiple lymph node involvement and various FDG avid lesions in the lung and abdomen concerning for metastatic spread (**Figure 1**), including a lesion in the right psoas. Consequently concurrent chemotherapy (2 cycles of ifosfamide) was indicated. After the second cycle of chemotherapy, and almost 2 months after initiation of the radiotherapy, a CT of the abdomen and pelvis showed a large heterogeneous mass in the right psoas measuring 6.3×4.3 in axial dimension and 15 cm cranio-caudally. Because of the inability to determine

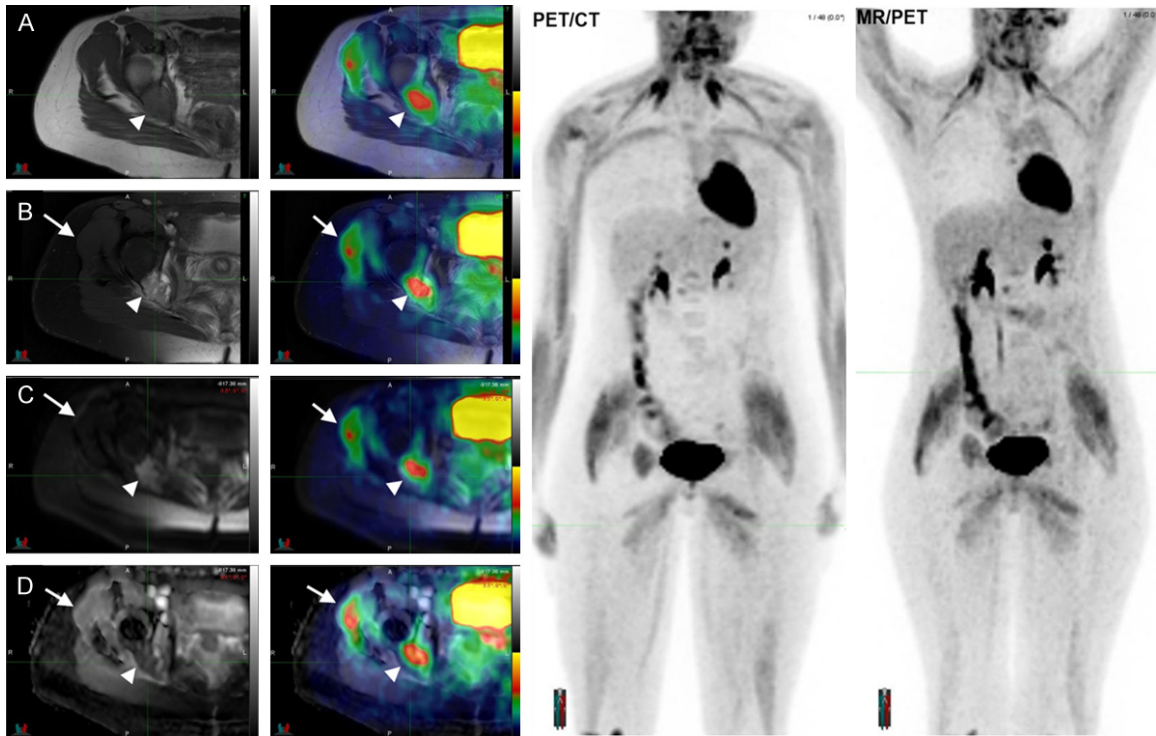


Figure 3. Axial T2w (A), STIR (B), DWI (C) and ADC (D) and the fusion of these images with the corresponding PET shows integration of the PETs functional capabilities with MRIs local assessment of the recurrence (arrow heads). Notice the peri-articular muscle uptake (arrows) which can be discarded as physiological due to the normal appearance of that area in STIR, DWI and ADC images (arrows). Direct comparison of PET MIPs allows recertification of the successful performance of the MR based attenuation correction map.

whether the mass was a hematoma or retro-peritoneal metastasis, PET/CT followed by PET/MRI was performed (**Figures 2, 3**). The studies were conducted after finalization of the head and neck radiation therapy. The findings in the PET images of the PET/MRI matched those found in the PET/CT (**Figure 3**) with similar SUV values. Nonetheless better characterization of the lesion was feasible due to MRIs superior tissue resolution and use of DWI (**Figure 2**), allowing thus the diagnosis of a heterogeneous mass with central necrosis, as opposed to a hematoma. These findings were somewhat concordant to those of the PET/CT although more conclusive. Also, mismatch of the area of restriction in DWI and the area of FDG uptake was evident. Meanwhile, between the first PET/CT and the second PET/CT + PET/MRI lesions seen in the head showed reduced FDG uptake, while the other described lesions, except the enlarging psoas mass, demonstrated no interval change. The FDG uptake of the head and neck lesions in the first PET/CT could be closely related to inflammatory changes due to the

radiation therapy. Detection of these findings was crucial as it led to a new chemotherapeutic treatment with cisplatin and adriamycin. The patient is currently undergoing chemotherapy and awaiting new control studies after finishing treatment.

Patient #2

A 19 year old female patient initially presented three years prior to the PET/MRI due to a mass like lesion in the upper right thigh. An MRI of the area showed a subcutaneous soft tissue mass with defined borders that did not invade the adjacent muscular compartment. This enhancing solid soft-tissue mass underwent an excisional biopsy demonstrating a high grade soft tissue sarcoma. Due to the histological findings the patient underwent wide re-excision of the previous biopsy site.

Two years after the initial diagnosis a pulmonary lesion suspicious for recurrence was detected on follow up studies prompting a diagnostic thoracoscopy with left upper lobectomy.

When pathology confirmed it as recurrence the patient underwent 6 cycles of chemotherapy (ifosfamide and doxorubicin).

Six months after finishing the chemotherapy the patient was referred to our department for follow up with MRI and PET/CT suggesting enrollment in the double scan protocol (PET/CT and PET/MRI). After giving consent, the patient was injected F18-FDG on the PET/MRI examination table and MRI of the thigh was performed during the radiotracer uptake phase. At 62 minutes after FDG injection the PET from the PET/MRI was acquired. Once the PET acquisition was finalized the patient was taken to the PET/CT and the examination was performed 99 minutes after injection. The MRI of the thigh and the PET/CT were read as separate studies and the PET/MRI was analyzed in light of those findings. While the MRI showed a bone marrow replacing lesion in the right ischium/posterior acetabulum that seemed to break through the cortical bone extending into the surrounding soft tissue; the PET/CT showed an FDG avid soft tissue lesion in the same region and two more FDG avid foci in relation to lytic lesions in L1 and L2. Analysis of the PET/MRI (**Figure 3**) allowed successful identification of all the described findings while providing a direct and reliable comparison of MRIs multiparametric sequence (DWI) and the FDG uptake as evidenced in the PET.

Discussion

The MR component of the PET/MRI was useful in patient #1 to accurately diagnose the enlarging right psoas mass. MR demonstrated a right sided psoas mass with central necrosis which may have represented a hematoma, possible abscess or neoplasm. The PET exam showed high peripheral SUVs, these findings combined with the MR images were most consistent with metastatic malignancy. Based on these findings the multidisciplinary board decided to restart a chemotherapy regimen. Patient #1 demonstrates how PET/MRI can provide in a single exam, anatomic and functional information that impacts treatment decisions. Furthermore both patients show that PET/MRI is a valuable technique as a potential one stop approach.

Prognosis and treatment decisions of sarcoma need accurate staging. The T staging using PET/MRI equals that of an MR only approach

while adding simultaneous N and M staging from the PET component. Furthermore, new PET tracers like ^{11}C -choline demonstrated promising results for N staging of sarcoma [24] which used concurrently with sequences, such as STIR and DWI should allow for more accurate and precise assessment of lymph node involvement. In terms of M staging PET/MRI might gain a substantial role for liver, bone and brain lesions [25], thanks to the MR component, while still maintaining the other areas where PET is beneficial. Research to understand whether MRI multiparametric imaging capabilities combined with the metabolic PET information can better detect and characterize necrosis and viable solid tumor component is needed as evidenced in our patients: In patient #1 DWI findings weren't completely concordant with FDG findings. This differentiation between tumor and necrosis is of interest, in particular for re-staging purposes after radiation therapy or chemotherapy and for prognosis [26, 27]. With regard to prognosis SUVs derived from the PET component are of interest as higher values are associated with lower survival [28].

Another area where PET/MRI shows promise is in therapy response assessment. Therapy of sarcoma implicates a complex multidisciplinary approach including surgery, chemotherapy and/or radiation therapy and most recently molecular therapeutics [29]. It is important to find the optimal therapy regimen and to assess therapy response reliably towards an individualized oncologic approach. In current sarcoma imaging therapy response evaluation is reflected in the RECIST criteria [30]. The RECIST criteria are mainly based on tumor size changes but some molecular therapy strategies have anti-cancer effects without reducing the actual tumor size but inducing alterations in the tumor microenvironment [31]. In a recently published manuscript treatment changes were induced in 21 out of 23 patients based on PET/CT results. Those changes included pivotal decisions like referring patients to chemotherapy instead of the originally planned surgery [32]. Diffusion weighted sequences and SUV values over time in PET positive lesions have been shown to be useful for treatment response assessment in this patient population [33-35]. The correlation between FDG-PET and diffusion weighted MRI for therapy response as shown in previous studies [36, 37] has a high sensitivity. The combination of PET/MRI information should help

assess treatment response more accurately by combining different surrogate markers and multiparametric imaging sequences.

Among the different multiparametric sequences currently available and under research the ones that show promise in tumor response assessment are: DWI with ADC maps, DCE, BOLD and MR spectroscopy. For example, DWI can help assess cell density based on how freely water molecules can move within the tissue, and helps to distinguish viable tumor from fibrosis or necrosis. At the same time, the quantitatively derived ADC values from this sequence have implications for predicting response to chemotherapy [38, 39]. Dynamic contrast enhanced imaging may help assess vascular density by analyzing the contrast enhancement pattern, while research is being done to evaluate if it can show early treatment response to anti-angiogenic treatment. Also, the contrast wash-out pattern gives information about leakage of the microvessels. On the other hand, BOLD sequences can help determine areas of tumor hypoxia which in turn may facilitate radiation therapy planning [40, 41]. Finally MR spectroscopy may be useful for assessing the local spread and tumor microenvironment as it is already done in brain tumor imaging [42, 43].

To summarize the hypotheses derived from two sarcoma patients PET/MRI is of interest for primary diagnosis and staging as the PET component can complement the MR derived information and vice versa. For distant metastases and adenopathy detection the MR may complement the essential molecular information derived from PET. Finally functional imaging with advanced MR sequences (e.g. DWI) and depiction of metabolism with PET may prove highly valuable for treatment assessment.

Low dose oncologic imaging has gained tremendous interest in recent years, in particular in the pediatric population. The highly interesting study of Pearce and colleagues revealed a positive correlation of radiation dose from CT scans with leukemia and with brain tumors. The authors concluded that cumulative CT doses of 50 mGy could almost triple the risk for leukemia and cumulative CT doses of 60 mGy could triple brain tumor risks [44]. Meanwhile, pediatric cancer patients need an average of 3.2 PET/CT exams [45]. The frequent follow-up with PET/CT implies a significant radiation bur-

den. Hence PET/MRI is of interest in follow-up of children and young adults who would have had received otherwise a PET/CT. In an initial case description PET/CT has been replaced by PET/MRI in a young woman with aggressive fibromatosis. This patient needed frequent follow-up studies after administration of imatinib therapy. PET/MRI was performed to avoid exposure to a high radiation dose over time [46]. The benefit of PET/MRI to reduce radiation doses has been discussed in a recently published article applying PET/MRI in pediatric oncology patients [47]. The authors estimated that the PET/MRI radiation dose, which was around 4.6 mSv, equals 20% of the dose of PET/CT [47, 48]. It can be thus concluded that PET/MRI is beneficial for the pediatric and young adult sarcoma population with the goal to decrease the cumulative radiation dose.

One of the major limitations is that we were not able to correlate the discordant findings from PET/MRI with histopathological features, as surgical treatment was discarded for patient #1 due to the extent and spread of the disease. A further limitation is that we present only two patients. To investigate the findings and hypotheses larger clinical studies are warranted in the near future.

Conclusion

PET/MRI has recently entered the clinical arena and potential applications of this hybrid imaging technology are currently being investigated. As shown in these two patients, PET/MRI might be of value for tumor characterization in sarcoma patients. Besides better TNM staging, in vivo imaging of cancer metabolism and microenvironment with PET/MRI might also be of value in soft-tissue sarcoma with regard to a more reliable treatment response evaluation. MR and PET as standalone imaging modalities have already been proven to be beneficial in these patients. The hybrid imaging modality PET/MRI needs to be further explored in sarcoma patients with the goals of improving staging, response to therapy evaluation and decreasing cumulative radiation dose.

Disclosure of conflict of interest

The PET/MRI system was funded by a State of Ohio Third Frontier Grant. Clinical PET/MRI studies in the institution are funded by grants from Philips Healthcare.

Address correspondence to: Dr. Mark R Robbin, Department of Radiology, University Hospitals Seidman Cancer Center, University Hospitals Case Medical Center, Case Western Reserve University, 11100 Euclid Avenue, Cleveland, OH 44106. Tel: 2168441000; Fax: 2168445922; E-mail: mark.robbin@uhhospitals.org

References

- [1] Storm HH. Survival of adult patients with cancer of soft tissues or bone in Europe. EURO-CARE Working Group. *Eur J Cancer* 1998; 34: 2212-2217.
- [2] Buck AK, Herrmann K, Büschenfelde CM, Juweid ME, Bischoff M, Glatting G, Weirich G, Möller P, Wester HJ, Scheidhauer K, Dechow T, Peschel C, Schwaiger M, Reske SN. Imaging bone and soft tissue tumors with the proliferation marker [18F]fluorodeoxythymidine. *Clin Cancer Res* 2008; 14: 2970-2977.
- [3] Been LB, Suurmeijer AJ, Elsinga PH, Jager PL, Van Ginkel RJ, Hoekstra HJ. 18F-fluorodeoxythymidine PET for evaluating the response to hyperthermic isolated limb perfusion for locally advanced soft-tissue sarcomas. *J Nucl Med* 2007; 48: 367-372.
- [4] Hogendoorn PC; ESMO/EUROBONET Working Group, Athanasou N, Bielack S, De Alava E, Dei Tos AP, Ferrari S, Gelderblom H, Grimer R, Hall KS, Hassan B, Hogendoorn PC, Jurgens H, Paulussen M, Rozeman L, Taminiau AH, Whelan J, Vanel D. Bone sarcomas: ESMO Clinical Practice Guidelines for diagnosis, treatment and follow-up. *Ann Oncol* 2010; 21 Suppl 5: v204-213.
- [5] Casali PG, Blay JY. Soft tissue sarcomas: ESMO Clinical Practice Guidelines for diagnosis, treatment and follow-up. *Ann Oncol* 2010; 21 Suppl 5: v198-203.
- [6] Clark MA, Fisher C, Judson I, Thomas JM. Soft-tissue sarcomas in adults. *N Engl J Med* 2005; 353: 701-711.
- [7] Tateishi U, Yamaguchi U, Seki K, Terauchi T, Arai Y, Kim EE. Bone and soft-tissue sarcoma: preoperative staging with fluorine 18 fluorodeoxyglucose PET/CT and conventional imaging. *Radiology* 2007; 245: 839-847.
- [8] Tateishi U, Hosono A, Makimoto A, Sakurada A, Terauchi T, Arai Y, Imai Y, Kim EE. Accuracy of 18F fluorodeoxyglucose positron emission tomography/computed tomography in staging of pediatric sarcomas. *J Pediatr Hematol Oncol* 2007; 29: 608-612.
- [9] Völker T, Denecke T, Steffen I, Misch D, Schönberger S, Plotkin M, Ruf J, Furth C, Stöver B, Hautzel H, Henze G, Amthauer H. Positron emission tomography for staging of pediatric sarcoma patients: results of a prospective multicenter trial. *J Clin Oncol* 2007; 25: 5435-5441.
- [10] Schwenzer NF, Stegger L, Bisdas S, Schraml C, Kolb A, Boss A, Müller M, Reimold M, Erneemann U, Claussen CD, Pfannenbergl C, Schmidt H. Simultaneous PET/MR imaging in a human brain PET/MR system in 50 patients—current state of image quality. *Eur J Radiol* 2012; 81: 3472-3478.
- [11] Boss A, Stegger L, Bisdas S, Kolb A, Schwenzer N, Pfister M, Claussen CD, Pichler BJ, Pfannenbergl C. Feasibility of simultaneous PET/MR imaging in the head and upper neck area. *Eur Radiol* 2011; 21: 1439-1446.
- [12] Boss A, Bisdas S, Kolb A, Hofmann M, Erneemann U, Claussen CD, Pfannenbergl C, Pichler BJ, Reimold M, Stegger L. Hybrid PET/MRI of intracranial masses: initial experiences and comparison to PET/CT. *J Nucl Med* 2010; 51: 1198-1205.
- [13] Drzezga A, Souvatzoglou M, Eiber M, Beer AJ, Fürst S, Martinez-Möller A, Nekolla SG, Ziegler S, Ganter C, Rummeny EJ, Schwaiger M. First clinical experience with integrated whole-body PET/MR: comparison to PET/CT in patients with oncologic diagnoses. *J Nucl Med* 2012; 53: 845-855.
- [14] Schwenzer NF, Schraml C, Müller M, Brendle C, Sauter A, Spengler W, Pfannenbergl AC, Claussen CD, Schmidt H. Pulmonary lesion assessment: comparison of whole-body hybrid MR/PET and PET/CT imaging—pilot study. *Radiology* 2012; 264: 551-558.
- [15] Keereman V, Mollet P, Berker Y, Schulz V, Vandenberghe S. Challenges and current methods for attenuation correction in PET/MR. *MAGMA* 2013; 26: 81-98.
- [16] Hofmann M, Pichler B, Scholkopf B, Beyer T. Towards quantitative PET/MRI: a review of MR-based attenuation correction techniques. *Eur J Nucl Med Mol Imaging* 2009; 36 Suppl 1: S93-104.
- [17] Schulz V, Torres-Espallardo I, Renisch S, Hu Z, Ojha N, Börnert P, Perkuhn M, Niendorf T, Schäfer WM, Brockmann H, Krohn T, Buhl A, Günther RW, Mottaghy FM, Krombach GA. Automatic, three-segment, MR-based attenuation correction for whole-body PET/MR data. *Eur J Nucl Med Mol Imaging* 2011; 38: 138-152.
- [18] Kershah S, Partovi S, Traughber BJ, Muzic RF Jr, Schluchter MD, O'Donnell JK, Faulhaber P. Comparison of SUV Measurements in Normal Structures between PET/CT and PET/MRI. *Mol Imaging Biol* 2013 Dec; 15: 776-85.
- [19] Schramm G, Langner J, Hofheinz F, Petr J, Beuthien-Baumann B, Platzek I, Steinbach J, Kotzerke J, van den Hoff J. Quantitative accu-

- racy of attenuation correction in the Philips Ingenuity TF whole-body PET/MR system: a direct comparison with transmission-based attenuation correction. *MAGMA* 2013; 26: 115-126.
- [20] Partovi SLZ, Thomas S, O'Donnell JK, Faulhaber P. Quantitative and qualitative comparison of lung cancer imaging with PET/MRI and PET/CT. Society of Nuclear Medicine and Molecular Imaging Mid-Winter Meeting New Orleans, LA, U S A 2013.
- [21] Nekolla SG, Martinez-Moeller A, Saraste A. PET and MRI in cardiac imaging: from validation studies to integrated applications. *Eur J Nucl Med Mol Imaging* 2009; 36 Suppl 1: S121-130.
- [22] Keereman V, Holen RV, Mollet P, Vandenberghe S. The effect of errors in segmented attenuation maps on PET quantification. *Medical Physics* 2011; 38: 6010-6019.
- [23] Somer EJ, Marsden PK, Benatar NA, Goodey J, O'Doherty MJ, Smith MA. PET-MR image fusion in soft tissue sarcoma: accuracy, reliability and practicality of interactive point-based and automated mutual information techniques. *Eur J Nucl Med Mol Imaging* 2003; 30: 54-62.
- [24] Tateishi U, Yamaguchi U, Maeda T, Seki K, Terauchi T, Kawai A, Arai Y, Moriyama N, Kakizoe T. Staging performance of carbon-11 choline positron emission tomography/computed tomography in patients with bone and soft tissue sarcoma: comparison with conventional imaging. *Cancer Sci* 2006; 97: 1125-1128.
- [25] Buchbender C, Heusner TA, Lauenstein TC, Bockisch A, Antoch G. Oncologic PET/MRI, part 2: bone tumors, soft-tissue tumors, melanoma, and lymphoma. *J J Nucl Med* 2012; 53: 1244-1252.
- [26] Piperkova E, Mikhaeil M, Mousavi A, Libes R, Viejo-Rullan F, Lin H, Rosen G, Abdel-Dayem H. Impact of PET and CT in PET/CT studies for staging and evaluating treatment response in bone and soft tissue sarcomas. *Clin Nucl Med* 2009; 34: 146-150.
- [27] Wang X, Jacobs MA, Fayad L. Therapeutic response in musculoskeletal soft tissue sarcomas: evaluation by MRI. *NMR Biomed* 2011; 24: 750-763.
- [28] Baum SH, Fruhwald M, Rahbar K, Wessling J, Schober O, Weckesser M. Contribution of PET/CT to prediction of outcome in children and young adults with rhabdomyosarcoma. *J Nucl Med* 2011; 52: 1535-1540.
- [29] Somaiah N, Von Mehren M. New drugs and combinations for the treatment of soft-tissue sarcoma: a review. *Cancer Manag Res* 2012; 4:397-411.
- [30] Therasse P, Arbuck SG, Eisenhauer EA, Wanders J, Kaplan RS, Rubinstein L, Verweij J, Van Glabbeke M, Van Oosterom AT, Christian MC, Gwyther SG. New guidelines to evaluate the response to treatment in solid tumors. European Organization for Research and Treatment of Cancer, National Cancer Institute of the United States, National Cancer Institute of Canada. *J Natl Cancer Inst* 2000; 92: 205-216.
- [31] Weber WA. Use of PET for monitoring cancer therapy and for predicting outcome. *J Nucl Med* 2005; 46: 983-995.
- [32] Fuglo HM, Jorgensen SM, Loft A, Hovgaard D, Petersen MM. The diagnostic and prognostic value of (1)(8)F-FDG PET/CT in the initial assessment of high-grade bone and soft tissue sarcoma. A retrospective study of 89 patients. *Eur J Nucl Med Mol Imaging* 2012; 39: 1416-1424.
- [33] Schnapauff D, Zeile M, Niederhagen MB, Fleige B, Tunn PU, Hamm B, Dudeck O. Diffusion-weighted echo-planar magnetic resonance imaging for the assessment of tumor cellularity in patients with soft-tissue sarcomas. *J Magn Reson Imaging* 2009; 29: 1355-1359.
- [34] Dudeck O, Zeile M, Pink D, Pech M, Tunn PU, Reichardt P, Ludwig WD, Hamm B. Diffusion-weighted magnetic resonance imaging allows monitoring of anticancer treatment effects in patients with soft-tissue sarcomas. *J Magn Reson Imaging* 2008; 27: 1109-1113.
- [35] Evilevitch V, Weber WA, Tap WD, Allen-Auerbach M, Chow K, Nelson SD, Eilber FR, Eckardt JJ, Elashoff RM, Phelps ME, Czernin J, Eilber FC. Reduction of glucose metabolic activity is more accurate than change in size at predicting histopathologic response to neoadjuvant therapy in high-grade soft-tissue sarcomas. *Clin Cancer Res* 2008; 14: 715-720.
- [36] Heijmen L, Verstappen MC, Ter Voert EE, Punt CJ, Oyen WJ, de Geus-Oei LF, Hermans JJ, Heerschap A, van Laarhoven HW. Tumour response prediction by diffusion-weighted MR imaging: ready for clinical use? *Crit Rev Oncol Hematol* 2012; 83: 194-207.
- [37] Koh DM, Collins DJ. Diffusion-weighted MRI in the body: applications and challenges in oncology. *AJR Am J Roentgenol* 2007; 188: 1622-1635.
- [38] Kim SH, Lee JM, Hong SH, Kim GH, Lee JY, Han JK, Choi BI. Locally advanced rectal cancer: added value of diffusion-weighted MR imaging in the evaluation of tumor response to neoadjuvant chemo- and radiation therapy. *Radiology* 2009; 253: 116-125.
- [39] Maretto I, Pomerrri F, Pucciarelli S, Mescoli C, Belluco E, Burzi S, Ruggie M, Muzzio PC, Nitti D. The potential of restaging in the prediction of pathologic response after preoperative chemo-

PET/MRI in sarcoma

- radiotherapy for rectal cancer. *Ann Surg Oncol* 2007; 14: 455-461.
- [40] Chopra S, Foltz WD, Milosevic MF, Toi A, Bristow RG, Ménard C, Haider MA. Comparing oxygen-sensitive MRI (BOLD R2*) with oxygen electrode measurements: a pilot study in men with prostate cancer. *Int J Radiat Biol* 2009; 85: 805-813.
- [41] Rijpkema M, Kaanders JH, Joosten FB, Van Der Kogel AJ, Heerschap A. Effects of breathing a hyperoxic hypercapnic gas mixture on blood oxygenation and vascularity of head-and-neck tumors as measured by magnetic resonance imaging. *Int J Radiat Oncol Biol Phys* 2002; 53: 1185-1191.
- [42] Shah T, Jayasundar R, Singh VP, Sarkar C. In vivo MRS study of intraventricular tumors. *J Magn Reson Imaging* 2011; 34: 1053-1059.
- [43] Steffen-Smith EA, Venzon DJ, Bent RS, Hipp SJ, Warren KE. Single- and multivoxel proton spectroscopy in pediatric patients with diffuse intrinsic pontine glioma. *Int J Radiat Oncol Biol Phys* 2012; 84: 774-779.
- [44] Pearce MS, Salotti JA, Little MP, McHugh K, Lee C, Kim KP, Howe NL, Ronckers CM, Rajaraman P, Sir Craft AW, Parker L, Berrington de González A. Radiation exposure from CT scans in childhood and subsequent risk of leukaemia and brain tumours: a retrospective cohort study. *Lancet* 2012; 380: 499-505.
- [45] Fahey FH, Treves ST, Adelstein SJ. Minimizing and communicating radiation risk in pediatric nuclear medicine. *J Nucl Med* 2011; 52: 1240-1251.
- [46] Werner MK, Schmidt H, Schwenzer NF. MR/PET: a new challenge in hybrid imaging. *AJR Am J Roentgenol* 2012; 199: 272-277.
- [47] Hirsch FW, Sattler B, Sorge I, Kurch L, Viehweger A, Ritter L, Werner P, Jochimsen T, Barthel H, Bierbach U, Till H, Sabri O, Kluge R. PET/MR in children. Initial clinical experience in paediatric oncology using an integrated PET/MR scanner. *Pediatr Radiol* 2013 Jul; 43: 860-75.
- [48] Chawla SC, Federman N, Zhang D, Nagata K, Nuthakki S, McNitt-Gray M, Boechat MI. Estimated cumulative radiation dose from PET/CT in children with malignancies: a 5-year retrospective review. *Pediatr Radiol* 2010; 40: 681-686.