

## Original Article

# Long-term effects of forgotten biliary stents: a case series and literature review

Mehmet Odabasi<sup>1</sup>, Cem Arslan<sup>1</sup>, Sami Akbulut<sup>2</sup>, Hacı Hasan Abuoglu<sup>1</sup>, Erkan Ozkan<sup>1</sup>, Mehmet Kamil Yildiz<sup>1</sup>, Cengiz Eris<sup>1</sup>, Emre Gunay<sup>1</sup>, Kemal Tekesin<sup>1</sup>, Tolga Muftuoglu<sup>1</sup>

<sup>1</sup>Department of Surgery, Haydarpaşa Education and Research Hospital, 34688, Istanbul, Turkey; <sup>2</sup>Department of Surgery, Diyarbakir Education and Research Hospital, 21400, Diyarbakir, Turkey

Received June 18, 2014; Accepted July 27, 2014; Epub August 15, 2014; Published August 30, 2014

**Abstract:** There are many studies about the biliary stents, however there is a little information about the long-term stayed forgotten biliary stents except a few case reports. We have reported the results of a number of cases with biliary stents that were forgotten or omitted by the patient and the endoscopist. During February 2010 to May 2013, five patients were referred to the general surgery clinic of Haydarpaşa Numune Training and Research Hospital, Istanbul Turkey. Past history and medical documents submitted by the patient did not indicate a replacement of the biliary stent in 3 patients. Two patients knew that they had biliary stents. We also conducted a literature review via the PubMed and Google Scholar databases of English language studies published until March 2014 on forgotten biliary stent. There were 3 men and 2 women ranging in age from 22 to 68 years (mean age 41.6 years). Patients presented with pain in the upper abdomen, jaundice, fever, abnormal liver function tests or dilatation of the biliary tract alone or in combination. Patients' demographic findings are presented in Table 1. A review of three cases reported in the English medical literature also discussed. The mean duration of the patency of the stent is about 12 months. The biliary stenting is performed either with plastic or metal stents, studies recommending their replacement after 3-6 months. Patients with long stayed forgotten biliary stents are inevitably treated with surgical intervention. We recommend for all endoscopic retrograde cholangiopancreatography units provide a stent registry system that the stents placed for various therapeutic procedures are not forgotten both by the patient as well as the physician. There should be a deadline for biliary stents in the registry system for each patient.

**Keywords:** Biliary stent, ERCP, forgotten stent, cholangitis

## Introduction

Endoscopic sphincterotomy (EST) and stone extraction is the widely accepted treatment modality for common bile duct (CBD) stones and this procedure can clear the bile ducts in 85% to 90% of patients [1]. In some patients, however, successful endoscopic removal of biliary stones is impossible, especially when large or impacted stones are present, or in case of a concomitant narrowing of the distal common bile duct. Endoscopic insertion of biliary endoprosthesis has been proposed as an alternative for frail, elderly patients or in those with high surgical risk [1-7]. The major aim of this therapeutic option is directed toward prevention of stone impaction at the ampulla and a subsequent life-threatening complication, cholangitis.

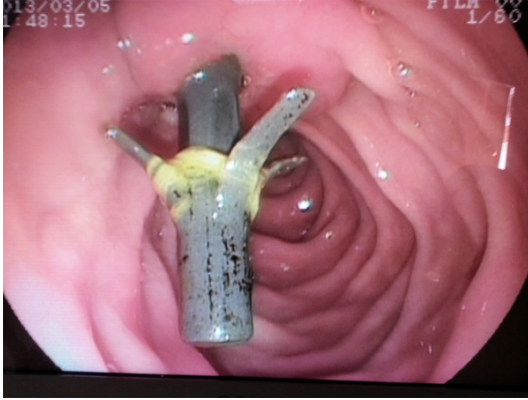
The biliary stenting is performed either with plastic or metal stents, studies recommending

their replacement after 3-6 months [8-11], in order to avoid complications such as occlusion, migration of the stent or cholangitis [11]. Common bile duct obstruction by a foreign body is a rare cause of obstructive jaundice, especially when it occurs due to a biliary stent on which de novo gallstones have formed. There are many studies about the biliary stents, however there is a little information about the long-term stayed or forgotten biliary stents except a few case reports. We have reported the results of a number of cases with biliary stents that were forgotten or omitted by the patient and the endoscopist.

## Materials and methods

During February 2010 to May 2013, five patients were referred to the general surgery clinic of Haydarpaşa Numune Education and Research Hospital, Istanbul Turkey, from other hospitals in Istanbul. At the beginning, some

## Management of forgotten biliary endoprosthesis



**Figure 1.** Endoscopic view of the omitted plastic stent.

patients admitted to the other hospitals complaining of recurrent episodes of upper abdominal pain, progressive jaundice, light stools and dark urine. Diagnosis of cholangitis was made by the findings of fever, jaundice, abdominal pain, and leukocytosis. Past history and medical documents submitted by the patient did not indicate a replacement of the biliary stent in three patients. Two patients knew that they had biliary stents.

Abdominal ultrasound revealed significant intrahepatic bile duct dilatation due to the obstacle at the level of the CBD. Magnetic resonance cholangiopancreatography showed the presence of a foreign body in the CBD (stent).

It was decided to perform an endoscopic intervention. Pharyngeal anesthesia was induced with a spray of 10% lidocaine. Midazolam (3-5 mg) and pethidine (20-30 mg) were given by i.v. injection to relieve anxiety and pain of patients. Hyoscine butylbromide (20 mg) was given by i.v. injection for duodenal relaxation. Prophylactic intravenous antibiotics were administered in each patient before endoscopic retrograde cholangiopancreatography (ERCP). Antibiotics were also used for a few days after the procedure.

An ERCP was performed with a standard sideviewing duodenoscope (Fujinon ED-450-XT5). After opacification of the bile ducts with contrast material, the size of the stones was estimated by using the diameter of the scope on the x-ray film as a reference. For patients with multiple CBD stones, the largest stone was measured. The CBD diameter was arbitrarily

defined as the width of CBD at the cystic duct insertion level as described by Han *et al.* [12].

The attempts to retrieve the biliary stent failed in patient 1 and patient 2, because they had biliary stents migrated to CBD, and it was impossible to remove them, so second stents were introduced to CBDs in order to avoid biliary obstruction. Hence, surgical procedures were necessary. After unsuccessful attempts at stone extraction, straight 10 Fr 9 cm polyethylene stents with side flaps were pushed through the endoscope over a 0.035 mm guide wire into the bile duct using a pusher. The guide wire was then slowly withdrawn and the stent positioned with the proximal end lying in the CBD above the stone and distal end lying free in the duodenum, so that the stones were trapped proximally, thus preventing distal obstruction (**Figure 1**). The following information was collected for each patient: age, gender, clinical presentation, gallbladder stone, biochemical blood tests, and ERCP findings, duration of stent stay, stent insertion, ERCP-related complications and type of surgery.

### Results

There were three men and two women ranging in age from 22 to 68 years (mean age 41.6 years). Patients presented with pain in the upper abdomen, jaundice, fever, abnormal liver function tests or dilatation of the biliary tract alone or in combination. Clinic and demographic characteristics of all patients summarized in **Table 1**.

Patient 1 was 35 years old women and had multiple intrahepatic stones with forgotten biliary stent migrated to CBD and recurrent cholangitis. She admitted to our hospital 48 months after the insertion of a stent. Past history was not clear and patient was not know why the stent was inserted to CBD. She had cholangitis that could be controlled by antibiotic therapy. Stent and stones could not be removed by ERCP, so the second biliary stent was inserted to CBD. Because of multiple intrahepatic stones, hepaticojejunostomy was performed.

Patient 2 was 68 years old and had stent migrated to CBD and admitted to our hospital 84 months after insertion of biliary stent. She had right upper quadrant pain with slightly increased bilirubin levels and hepatic enzymes.

## Management of forgotten biliary endoprosthesis

**Table 1.** Demographic and clinical characteristics of patients with forgotten biliary stent

	Patient 1	Patient 2	Patient 3	Patient 4	Patient 5
Age	35	68	45	38	22
Sex	F	F	M	M	M
Clinical Presentation	Cholangitis	Cholangitis	Jaundice	Abdominal Pain	Jaundice
Gallbladder Stone	Operated	Operated	Operated	Multiple millimetric Stones	Multiple millimetric stones
Diameter of CBD	12	11	10	20	35
Diameter of Stone	Intrahepatic multiple stones	Multiple (the biggest one is 20 mm.)	Sludge	15 mm.	20 and 40 mm stones
AST	137	47	291	44	115
ALT	134	45	229	49	111
ALK. P	300	298	140	255	90
GGT	214	274	370	214	258
T. Bilirubin	4.46	1.79	3.46	0.53	36.47
D. Bilirubin	3.38	0.67	2.49	0.33	28.31
Amylase	49	22	31	49	48
Lipase	6	11	13	15	34
WBC	18300	14600	9100	7450	7540
CRP	31.3	26	5	8	13
Stone Removal (ERCP)	Sludge	Failed	Sludge	Failed (Diameter of stone is larger than spincterotomy)	Failed (Impacted stone)
Duration of stent stay	48 months	84 months	23 months	36 months	36 months
Stent insertion in ERCP	No	Yes	No	Yes	Yes
Type of Operation	Hepaticojejunostomy	Choledochoduodenostomy	Successful ERCP	Cholecystectomy + CBD exploration + T-tube	Cholecystectomy + CBD exploration + T-tube

Choledochoduodenostomy was performed. Patient 3 had omitted the stent and came 23 months after the insertion of a stent. He had jaundice and the stent was taken out (**Figure 1**) and there was only sludge, the patient was discharged on the same day.

Patient 4 had also omitted the stent and came 49 months after the insertion of a stent. He had right upper quadrant pain, stent was taken out, and there was 15 mm. Stone that could not be crushed by mechanical lithotripter, so the second stent was introduced to CBD.

Patient 5 was 22 years old, had hereditary spherocytosis, and had omitted the stent. He had jaundice and multiple large stones in the CBD and stent was encased by stone (**Figures 2 and 3**). Patient 4 and patient 5 had stones in gallbladder also, so cholecystectomy, CBD exploration and the extraction of the biliary prosthesis and of the gallstones from the bile ducts were performed. The surgical procedure was completed by choledochography and a T-tube placed inside the CBD.

Because of hereditary spherocytosis, splenectomy was offered to the patient 5, but the patient refused the splenectomy. The samples

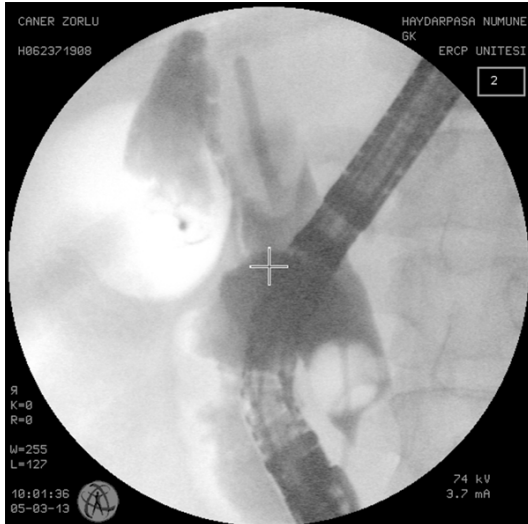
of forgotten or omitted biliary stents are shown in **Figure 4**. The patients had an uneventful postoperative evolution with complete symptom resolution. The repeated laboratory analysis revealed normalized liver function tests. The operated patients were discharged between the 7<sup>th</sup> and 10<sup>th</sup> days.

### Discussion

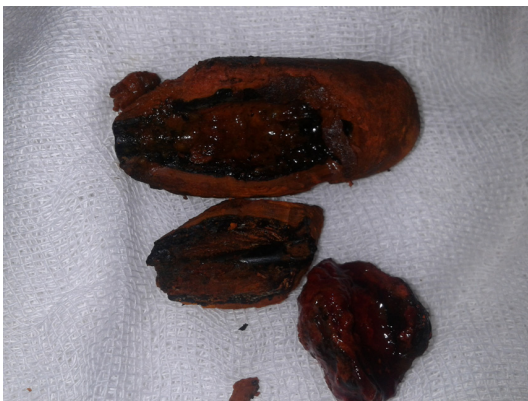With the progress of the ERCP techniques, the treatment of CBD stones has become safer and easier, so the indication of EST and stone extraction has broadened quickly. When endoscopic removal of CBD duct stone fails, insertion of endoprosthesis is indicated, in order to facilitate bile drainage and to prevent stone impaction or cholangitis, before a subsequent surgical intervention or a second attempt for stone extraction [13, 14].

The early outcome, including good drainage and low complication rate has been well established, but the late outcome has remained uncertain. Most reports revealed that the success rate of endoscopic biliary stenting was nearly 100% and early morbidity is low and can be controlled well [2, 15-17].

## Management of forgotten biliary endoprosthesis



**Figure 2.** Endoscopic retrograde cholangiopancreatography of patient 5. Impression of stent inside the stone.



**Figure 3.** Stones are surgically removed by choledochotomy.

The major disadvantage of this technique is the clogging of the endoprosthesis, which happens only a few days or several months later, and makes necessary frequent endoprosthesis exchanges to prevent cholangitis. We know that the sphincter of Oddi acts as a mechanical barrier, preventing the regression of the duodenal contents. The breakdown of this barrier with sphincterotomy or transpapillary insertion of an endoprosthesis results in microbial infection of the bile by ascending infection [18-20]. Additionally the presence of a foreign body in the biliary system has been proven to facilitate bacterial adhesion and biofilm formation [19]. However, when endoprostheses are used in nonextractable choledocholithiasis, they can



**Figure 4.** Samples of forgotten or omitted stents.

remain in place for longer periods than the required patency of endoprosthesis. It may be considered that the endoprosthesis does not serve as the sole conduit for the bile duct flow when used for choledocholithiasis [2, 20].

As expected, there remains a lumen in the common bile duct after placement of endoprosthesis alongside the stones, and this lumen may provide a pathway for bile flow even when the endoprostheses are completely obstructed.

Dislodgment of an endoprosthesis can expose a patient to the danger of stone impaction and cholangitis. In our two of the patients, forgotten biliary stents migrated totally into CBD causing stone formation and cholangitis. We think that the main role of the stent is bile flow, if bile flow stops stent act as a nidus for stone and bacteria. However, cholangitis can easily be controlled by antibiotic therapy and the insertion of a new biliary stent.

Katsinelos *et al.* [21] observed this complication in three patients in his study, and cholangitis was dealt with by the administration of fluids, antibiotics, and placement of a new endoprosthesis. It was noted that none of the patients with gallbladder in situ had developed gallbladder symptoms.

Dobronte *et al.* [22] reported that the average duration of symptom relief after biliary stenting was 22 months. The mean duration of the patency of the stent was about 12 months and the rate of late complications such as stent occlusion and cholangitis was 33.4-40.8% [15, 23-25]. For patients who cannot endure the process of definitive treatment, the biliary stent

## Management of forgotten biliary endoprosthesis

**Table 2.** Summarized of the published article about forgotten biliary stent until March 2014

Parameters	Gupta	Bansal	Bajbouj
Year	2013	2009	2008
Age	50		97
Sex	F	M	M
Primary Disease	Cholelithiasis + Choledocholithiasis	Cholelithiasis + Choledocholithiasis Cholelithiasis?	Gallbladder Carcinoma
Previously Management	Cholecystectomy + Sphincterotomy + Plastic stenting with ERCP	Sphincterotomy + Plastic stenting with ERCP	Plastic stenting with ERCP (2 stent)
Duration of Stent stay	4 years	6 years	10 years
Last clinical Presentation	Jaundice Epigastric pain	Nause + Vomiting Colicky abd pain	Jaundice Fever
AST	61	29	NS
ALT	58	29	NS
Bilirubin	3.8	NS	NS
ALP	388	285	NS
Forgotten Stent type	Plastic	Plastic	Plastic
Management	CBD exploration + Choledochoduodenostomy	Laparoscopic CBD exploration + T-tube drainage + Cholecystectomy	Occluded stents were extracted + Re-stenting with ERCP
Postoperative Course	Uneventful	Uneventful	Uneventful

should be changed after 1 year. All of our patients had biliary stents more than 1 year.

Most of the patients with stents in situ remained asymptomatic. Cholangitis is the most common complication after biliary stenting. Due to its recurrent character, the risk of liver abscesses, secondary sclerosing cholangitis and biliary cirrhosis is increased. It also may develop as an icterouremigenic cholangitis that is potentially fatal. In case of CBD stenosis, the healing process may take a while. Therefore, in young patients or in patients with repeated episodes of cholangitis, the surgical biliodigestive reconstruction surgery (choledochojejunal anastomosis with a Roux loop) is preferred [26-28]. In our patient 1 we preferred Roux-en Y hepaticojejunostomy because of intrahepatic multiple stones and recurrent episodes of cholangitis. Also in patient 2 because of recurrent attacks of cholangitis we performed choledochoduodenostomy.

Bartos *et al.* [29] presented that in the case of their patient, the endoscopic stenting solved the iatrogenic complication that occurred after cholecystectomy. However, inadequate follow up of the postoperative and postendoscopic period led finally to the need for another surgical procedure. Without this surgical procedure, the life of the patient could have been jeopardized

by complications secondary to biliary obstruction: liver cirrhosis, liver failure. In their patient, the lithogenic process was initiated on the remnant biliary stent that had not been replaced or extracted and caused repeated episodes of cholangitis.

We conducted a systematic literature search of the PubMed and Google Scholar databases using the search term "forgotten and biliary stent or forgotten and biliary endoprosthesis" and investigated the fulltext of only three published case reports until March 2014 (**Table 2**). All three studies were also summarized in below as chronological order: Bajbouj *et al.* [30] presented a case of a 97-year-old male with progressive jaundice and fever. Ten years previously, he had a carcinoma of the gallbladder with an infiltrative growth and consecutive constriction of both biliary hepatic ducts was diagnosed via sonography and computed tomography. A palliative biliary drainage was conducted, endoscopic retrograde cholangiopancreatography revealed a 3 cm stricture of the common bile duct below the hepatic hilus, and two plastic stents were inserted. Over the following 10 years, the patient remained symptom free. Then he presented to the clinic with the same symptoms, and cholecystolithiasis was detected sonographically; a tumor was identified. During ERCP, two occluded stents were extract-

## Management of forgotten biliary endoprosthesis

ed. The biliary tract displayed a short stricture of the distal common bile duct. The formerly described 3-cm stricture of the common bile duct below the hepatic hilus was no longer present. After a single plastic stent was placed, cholestasis parameters returned to normal. Three months later, reassessment by means of ERCP showed stable findings, and they therefore inserted a metal stent as a definite therapy. Whether the stents occluded before and operated as place holders or indeed kept on draining bile remains unclear. However, this is the first time that a plastic-stent remained in the common bile duct for such a long period.

Bansal *et al.* [31] reported a 62-year-old male patient suffered severe biliary colic in January 2000. He underwent endoscopic clearance of the common bile duct with papillotomy. A 7 Fr plastic stent was placed in the common bile duct. The patient did not appear for follow up and in January 2006, he once again had a severe attack of acute colicky pain in the abdomen. There was no history of cholangitis or jaundice. On abdominal ultrasound there were multiple stones in the gall bladder with multiple stones in the common bile duct. A plain X-ray abdomen revealed the biliary stent in situ. ERCP showed the previous biliary stent in situ. The stent was impacted in the common bile duct and could not be removed endoscopically. The patient was taken up for laparoscopic CBD exploration. The retained biliary stent was seen encased in a cast of biliary sludge, which had turned into hard calculi. Multiple small fragments of stones were also cleared from the common bile duct. A check choledochoscopy confirmed the clearance of the common bile duct, and a cholecystectomy was done. A T-tube cholangiogram performed a week later, revealed a small residual calculus, which was removed by ERCP 6 weeks later. The patient is doing well at two and a half years follow up.

Gupta *et al.* [32] presented a 50-years-old woman underwent open cholecystectomy after endoscopic retrograde cholangiography, clearance of the common bile duct (CBD), and plastic stent placement. She had undergone sphincterotomy for cholangitis 4 years previously, but did not report for follow-up as she apparently remained asymptomatic. Abdominal ultrasound revealed a large (18 mm × 15 mm) stone along with a stent within the dilated CBD. Endoscopy confirmed the presence of a stent. Endoscopic

CBD clearance, however, was not attempted in view of the large size of the stone. Open CBD exploration revealed a large cast of stone (8 cm × 2 cm) encasing the intrabiliary part of the stent which was removed with difficulty. After choledochoscopy to ensure complete CBD clearance, choledochoduodenostomy was carried out with an uneventful postoperative course.

There are many case reports and series in the urological literature of calculi forming around the retained ureteric stent. These 'forgotten stents' have been documented to obstruct the urinary system and may result even in renal failure and death. A majority of these forgotten stents is dealt with endoscopically [33].

In a study, which investigated foreign body infection in the biliary tract it was found that implants in the biliary tract impaired the local host defense mechanism, resulting in an increased susceptibility to microbial infection and fibrosis. These plastic stents if kept for a prolonged period promote bacterial proliferation, and release of bacterial beta-glucuronidase, which results in the precipitation of calcium bilirubinate. Calcium bilirubinate is then aggregated into stones by an anionic glycoprotein [34].

In conclusion, endoscopic placement of the endoprosthesis is a simple and safe method, but after insertion of endoprosthesis, all patients should be informed to be having biliary stents and the possibility of complications related to long-term endoprosthesis placement and were requested to contact to ERCP unit if symptoms suggestive of cholangitis. As the stent may get impacted within the stone, an endoscopic procedure may not be successful in such cases, especially with a large stentolith, mandating surgical removal. Biliary stents staying more than 3 years and dislodgement of stent to the CBD are major risk factors for forgotten or omitted stents in our experience. Such cases are treated mostly by surgical intervention.

We recommend for all ERCP units provide a stent registry system that the stents placed for various therapeutic procedures are not forgotten both by the patient as well as the physician. There could be a deadline for biliary stents in registry system for each patient.

# Management of forgotten biliary endoprosthesis

## Disclosure of conflict of interest

None.

**Address correspondence to:** Mehmet Odabasi, Department of General Surgery, Haydarpasa Numune Education and Research Hospital, Tibbiye cad, No. 1 Uskudar, Istanbul, Turkey. Tel: +905324310630; E-mail: hmodabasi@gmail.com

## References

- [1] Chopra KB, Peters RA, O'Toole PA, Williams SGJ, Gimson AES, Lombard MG, Westaby D. Randomized study of endoscopic biliary endoprosthesis versus duct clearance for bile duct stones in high-risk patients. *Lancet* 1996; 348: 791-93.
- [2] Bergman JJ, Rauws EA, Tijssen JG, Tytgat GN, Huibregtse K. Biliary endoprostheses in elderly patients with endoscopically irretrievable common bile duct stones: report on 117 patients. *Gastrointest Endosc* 1995; 42: 195-201.
- [3] Cotton PB, Forbes A, Leung JWC, Dineen L. Endoscopic stenting for long-term treatment of large bile duct stones: 2- to 5-year follow-up. *Gastrointest Endosc* 1987; 33: 411-2.
- [4] De Palma GD, Galloro G, Siciliano S, Catanzano C. Endoscopic stenting for definitive treatment of irretrievable common bile duct calculi. A long-term follow-up study of 49 patients. *Hepatogastroenterology* 2001; 48: 56-8.
- [5] Navicharern P, Rhodes M, Flook D, Lawrie B. Endoscopic retrograde cholangiopancreatography (ERCP) and stent placement in the management of large common bile duct stones. *Aust N Z J Surg* 1994; 64: 840-2.
- [6] Soomers AJ, Nagengast FM, Yap SH. Endoscopic placement of biliary endoprostheses in patients with endoscopically unextractable common bile duct stones. *Endoscopy* 1990; 22: 24-6.
- [7] Van Steenberg W, Pelemans W, Fevery J. Endoscopic biliary endoprosthesis in elderly patients with large bile duct stones. *J Am Geriatr Soc* 1992; 40: 57-60.
- [8] Bruno M, Rauws E, Gouma DJ. Use of removable covered expandable metal stents (RCEMS) in the treatment of benign distal common duct (CBD) strictures: a feasibility study. *Gastrointest Endosc* 2005; 61: AB 199.
- [9] Cahen DL, Rauws EA, Gouma DJ, Fockens P, Bruno MJ. Removable fully covered self-expandable metal stents in the treatment of common bile duct strictures due to chronic pancreatitis: a case series. *Endoscopy* 2008; 40: 697-700.
- [10] Park do H, Lee SS, Lee TH, Ryu CH, Kim HJ, Seo DW, Park SH, Lee SK, Kim MH, Kim SJ. Anchoring flap versus flared end, fully covered self-expandable metal stents to prevent migration in patients with benign biliary strictures: a multicenter, prospective, comparative pilot study (with videos). *Gastrointest Endosc* 2011; 73: 64-70.
- [11] Srinivasan I, Kahaleh M. Biliary stents in the millennium. *Adv Ther* 2011; 28: 960-972.
- [12] Han J, Moon JH, Koo HC, Kang JH, Choi JH, Jeong S, Lee DH, Lee MS, Kim HG. Effect of biliary stenting combined with ursodeoxycholic acid and terpene treatment on retained common bile duct stones in elderly patients: a multicenter study. *Am J Gastroenterol* 2009; 104: 2418-21.
- [13] Cotton PB. Endoscopic management of bile duct Stones (apples and oranges). *Gut* 1984; 25: 587-97.
- [14] Sherman S, Hawes R, Lehman G. Management of bile duct stones. *Sem Liver Dis* 1990; 10: 205-17.
- [15] Tiing LA, Kwong MF, Eng KT, Chua TS, Tan J. An audit of the outcome of long-term biliary stenting in the treatment of common bile duct stones in a general hospital. *J Gastroenterol* 2006; 41: 765-71.
- [16] Yoshitsugu K, Takaoka M, Fujimura K, Ogura M, Kin H, Yamamoto S, Tsuji K, Mizuno T, Inoue K. Endoscopic endoprosthesis for large stones. *Intern Med* 1994; 33: 597-601.
- [17] De Palma GD, Galloro G, Siciliano S, Magno L, Catanzano C. Results of the use of endoprostheses in the treatment of retained common bile duct stones. *Minerva Chir* 2000; 55: 823-7.
- [18] Groen AK, Out T, Huibregtse K, Delzenne B, Hoek FJ, Tytgat GNJ. Characterization of the contents of occluded biliary endoprosthesis. *Endoscopy* 1987; 19: 57-9.
- [19] Leung JW, Sung JY, Costerton JW. Bacteriological and electron microscopy examination of brown pigment stones. *J Clin Microbiol* 1989; 27: 915-21.
- [20] Speer AG, Cotton PB, Rhode J, Seddon AM, Neal CR, Holton J, Costerton JW. Biliary stent blockage with bacterial biofilm. *Ann Intern Med* 1988; 108: 546-53.
- [21] Katsinelos P, Galanis I, Pilpilidis I, Paroutoglou G, Tsolkas P, Papaziogas B, Dimiropoulos S, Kamperis E, Katsiba D, Kalomenopoulou M, Papagiannis A. The effect of indwelling endoprosthesis on stone size or fragmentation after long-term treatment with biliarystenting for large stones. *Surg Endosc* 2003; 17: 1552-5.
- [22] Dobronte Z, Patai A. Palliative treatment of large bile duct stones by endoscopic implantation of endoprosthesis in high risk patients. *Orv Hetil* 1996; 137: 461-4.
- [23] Ku MK, Lai KH, Lo GH, Cheng JS, Hsu PI, Lin CK, Chan HH, Hsu JH, Lin WT, Wang EM, Peng

## Management of forgotten biliary endoprosthesis

- NJ. Long-term effect of large biliary endoprosthesis in high-risk surgical patients with irretrievable common bile duct stones. *Zhonghua Yi Xue Zazhi (Taipei)* 1999; 62: 666-72.
- [24] Gong J, Sun X, Chen B. The evaluation of endoprosthesis for the management of common bile duct occlusion by stones in elderly patients. *Chin J Genatr* 2002; 21: 188-90.
- [25] Pisello F, Geraci G, Li Volsi F, Modica G, Sciumè C. Permanent stenting in 'unextractable' common bile duct stones in high risk patients. A prospective randomized study comparing two different stents. *Langenbecks Arch Surg* 2008; 393: 857-63.
- [26] Sherlock S, Dooley J. Imaging of the Biliary Tract: Interventional Radiology and Endoscopy. In: *Diseases of the Liver and Biliary System*. Oxford: Blackwell Science; 2002. pp. 573-575.
- [27] Sherlock S, Dooley J. Benign Stricture of the Bile Ducts. In: *Diseases of the Liver and Biliary System*. Oxford: Blackwell Science; 2002. pp. 629-634.
- [28] Turcu F, Dragomirescu C, Pletea S, Bănescu B. Problematika leziunilor iatrogene de cale biliară principală, sau o imagine a unui vârf de aisberg. *Chirurgia* 2011; 106: 187-94.
- [29] Bartos D, Bartos A, Acalovschi I, Iancu C. Biliary plastic stent as matrix core for lithogenesis in the common bile duct: a rare cause of jaundice. *J Gastrointest Liver Dis* 2012; 21: 427-9.
- [30] Bajbouj M, Treiber M, Ludwig L, Frimberger E, Schmid RM, Neu B. Forgotten biliary endoprosthesis. "Follow up" after 10 years. *Endoscopy* 2008; 40 Suppl 2: E221.
- [31] Bansal VK, Misra MC, Bhowate P, Kumar S. Laparoscopic management of common bile duct "Stentolith". *Trop Gastroenterol* 2009; 30: 95-6.
- [32] Gupta V, Chandra A, Noushif M, Singh SK. Giant stentolith: complication of a forgotten biliary stent. *Endoscopy* 2013; 45 Suppl 2: E126.
- [33] Aron M, Ansari MS, Singh I, Gautam G, Kolla SB, Seth A, Gupta NP. Forgotten ureteral stents causing renal failure: multimodal endourologic treatment. *J Endourol* 2006; 20: 423-8.
- [34] Yu JL, Andersson R, Wang LQ, Ljungh A, Bengmark S. Experimental foreign-body infection in the biliary tract in rats. *Scand J Gastroenterol* 1995; 30: 478-83.