

Case Report

Agenesis of dorsal pancreas confirmed by three-dimensional reconstruction CT

Yang Zhou¹, Munan Chen², Yang Liu¹

¹Department of Radiology, Harbin Medical University Cancer Hospital, Harbin 150081, Heilongjiang Province, Republic of China; ²Department of PET-CT/MR, Harbin Medical University Cancer Hospital, Harbin 150081, Heilongjiang Province, Republic of China

Received July 30, 2014; Accepted August 26, 2014; Epub September 15, 2014; Published September 30, 2014

Abstract: Agenesis of the dorsal pancreas (ADP) is a rare congenital pancreatic malformation in which all or part of the dorsal pancreatic body is absent. ADP is usually confirmed by magnetic resonance cholangiopancreatography (MRCP) or endoscopic retrograde cholangiopancreatography (ERCP), but these methods are undesirable to patients because of strict limitations or invasiveness. We propose abdominal contrast-enhanced and three-dimensional reconstruction CT images as an improved method for ADP diagnosis, and present a case study of ADP confirmed with these methods.

Keywords: Dorsal pancreas, agenesis, CT

Introduction

The pancreas develops from ventral and dorsal pancreatic buds on both ends of the foregut. The ventral pancreatic bud forms the inferior part of the head and uncinate process, and the dorsal pancreatic bud forms the superior part of the head, tail, and body. In the seventh gestational week, the two buds merge together and each develops two branches and a treelike duct system. The most common congenital pancreatic malformation is pancreas divisum, in which the buds fail to merge. Other pancreatic malformations include annular pancreas and agenesis of the ventral or dorsal pancreas.

Agenesis of the dorsal pancreas (ADP) is a rare congenital malformation of all or part of the dorsal portion of the pancreas. Common clinical symptoms of ADP are abdominal pain, pancreatitis, and diabetes. However, most ADP cases are asymptomatic, so the malformation is usually found incidentally by abdominal imaging for other reasons [1].

With improved imaging technologies, the number of reported ADP cases is increasing. Generally, abdominal ultrasound for detecting ADP has limitations, while magnetic resonance imaging (MRI) or computed tomography (CT)

scans can reveal the pancreatic head, an enlarged or absent pancreatic body, and the pancreatic tail. At present, magnetic resonance cholangiopancreatography (MRCP) and endoscopic retrograde cholangiopancreatography (ERCP) are the best methods for ADP diagnosis because they can demonstrate the absence of the dorsal pancreatic duct.

However, ERCP and MRCP are undesirable methods from a patient's perspective because of discomfort or limitations, so we sought to improve methods for diagnosis of ADP. We present here a case study of a patient with lung cancer and suspected ADP, which we confirmed using abdominal contrast-enhanced CT and three-dimensional reconstruction CT images.

Case report

A 56-year-old male patient was diagnosed with poorly differentiated pulmonary adenocarcinoma of the right lung by CT-guided biopsy at Harbin Medical University Cancer Hospital. Auscultation revealed weak breath sounds from the right lung, but physical examination was unremarkable and other items were also normal. He had no history of pancreatitis, diabetes, or operations. Laboratory tests revealed that he had normal fasting blood glucose levels (5.5 mmol/L; reference range 3.9 - 6.1 mmol/L),

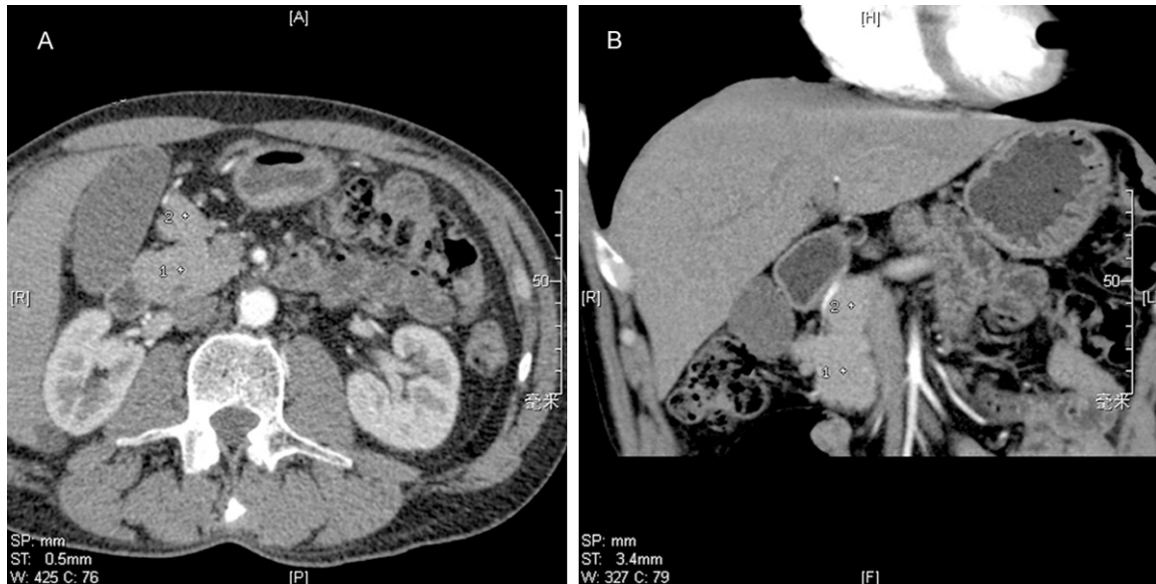


Figure 1. Abdominal contrast-enhanced CT images reveal the presence of a pancreatic head and uncinate process. A fat density gap shadow is visualized between the inferior pancreatic head (A) and superior pancreatic head (B).

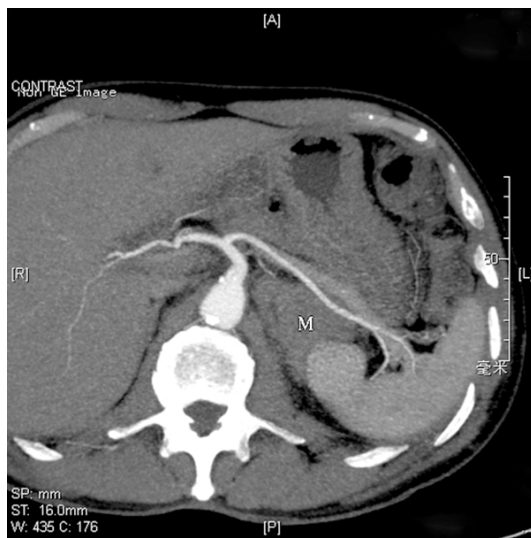


Figure 2. Axial CT maximum intensity projection (MIP) image demonstrates absence of a pancreatic body and tail around the splenic artery and vein, a lack of splenic artery branches to the dorsal pancreas, and a left adrenal metastatic tumor (M).

normal full blood count results, and normal kidney and liver function. Pancreatic enzymes were not examined. He had elevated levels of tumor markers neuron-specific enolase (NSE) (16.78 ng/mL; reference range 0 - 15.2 ng/mL) and CA125II (114.8 ng/mL; reference range 0 - 35 ng/mL).

Abdominal contrast-enhanced CT images demonstrated the presence of a pancreatic head

and uncinate process, absence of a pancreatic body and tail, and a lump in the left adrenal gland. The patient was suspected to have ADP and a left adrenal metastatic tumor. Abdominal contrast-enhanced CT imaging revealed the presence of an uncinate process and enlarged pancreatic head (diameter of 39 mm). In addition, the superior head, developed from dorsal pancreas, was not merged with the inferior head, developed from ventral pancreas. A fat density gap shadow was visualized on the front edge (**Figure 1**). The pancreatic body and tail left of the portal vein were not seen. Three-dimensional reconstruction CT images showed that the splenic artery stemmed from the celiac trunk and continued to the splenic hilum, but no corresponding arterial branches of the dorsal pancreas (dorsal pancreatic artery, inferior pancreatic artery, greater pancreatic artery, and caudal pancreatic artery) were present (**Figure 2**). Based on these results, we confirmed a diagnosis of ADP.

Discussion

Abdominal ultrasound imaging does not identify ADP well because of organ screen and bowel gas interference. However, CT or MRI scans can usually reveal the presence of a pancreatic head, which can be enlarged, and the absence of a pancreatic tail. However, because pancreas divisum and autodigestion secondary to chronic pancreatitis present imaging results

similar to ADP, careful differential diagnosis is required.

Previous reports indicate that ERCP and MRCP can reveal absence of the dorsal pancreatic duct as diagnostic evidence for ADP [2-6]. However, ERCP is technically difficult and invasive, and Oddi sphincterotomy can cause post-operative complications such as pancreatitis. MRCP is not invasive and does not expose patients to radiation, but it has high requirements on patients. Further, patients with cardiac pacemakers or other metallic implants are not suitable for MRI.

As three-dimensional reconstruction CT technologies have matured, however, the blood supply of viscera can now be clearly viewed. Therefore, three-dimensional reconstruction CT is a better method for ADP diagnosis. With these methods, congenital ADP can be confirmed when no pancreatic tail and splenic artery branches to the pancreas are observed. However, because this study only represents one case of ADP, further analysis of additional patients is needed to confirm the utility of abdominal contrast-enhanced and three-dimensional reconstruction CT for accurate and reliable diagnosis of ADP.

Disclosure of conflict of interest

None.

Address correspondence to: Dr. Yang Liu, Department of Radiology, Harbin Medical University Cancer Hospital, Harbin 150081, Heilongjiang Province, P. R. China. Tel: +86-0451-86298583; E-mail: lyang0451@yeah.net

References

- [1] Schnedl WJ, Piswagner-soelkner C, Wallner SJ, Reittner P, Krause R, Lipp RW, Hohmeier HE. Agenesis of the dorsal pancreas and associated diseases. *Dig Dis Sci* 2009; 54: 481-487.
- [2] Güclü M, Serin E, Ulucan S, Kul K, Ozer B, Gümürdülü Y, Pata C, Cosar A, Gür G, Boyacıoğlu S. Agenesis of the dorsal pancreas in a patient with recurrent acute pancreatitis: case report and review. *Gastrointest Endosc* 2004; 60: 472-475.
- [3] Masanori S, Naoko K, Erisa S, Mitsuhiro H, Kazufumi H. Agenesis of the dorsal pancreas: a rare cause of diabetes. *Intern Emerg Med* 2012; 7: 83-84.
- [4] Low JP, Williams D, Chaganti JR. Polysplenia syndrome with agenesis of the dorsal pancreas and preduodenal portal vein presenting with obstructive jaundice-a case report and literature review. *Br J Radiol* 2011; 84: e219-e222.
- [5] Pasaoglu L, Vural M, Hatipoglu HG, Terelioglu G, Koparal S. Agenesis of the dorsal pancreas. *World J Gastroenterol* 2008; 14: 2915-2916.
- [6] Lale P, Murat V, Hatice GH, Gokce T, Suha K. Agenesis of the dorsal pancreas. *World J Gastroenterol* 2008; 18: 2915-2916.