

Original Article

Meta-analysis of peritumoural rCBV values derived from dynamic susceptibility contrast imaging in differentiating high-grade gliomas from intracranial metastases

Ruofei Liang, Xiang Wang, Mao Li, Yuan Yang, Jiewen Luo, Qing Mao, Yanhui Liu

Department of Neurosurgery, West China Hospital of Sichuan University, Chengdu, P. R. China

Received August 3, 2014; Accepted August 28, 2014; Epub September 15, 2014; Published September 30, 2014

Abstract: Background and purpose: In the preoperative period, it is very important to accurately differentiate high-grade gliomas from intracranial metastases, as treatment strategies vary. Hence we performed a meta-analysis to evaluate the sensitivity and specificity of peritumoural relative cerebral blood volume (rCBV) values derived from dynamic susceptibility contrast imaging (DSCI) in differentiating high-grade gliomas from intracranial metastases. Materials and methods: Between 2004 and June 2014, relevant studies were searched from the databases of Medline and Embase for analysis. A total of 3 eligible studies were included in this analysis. Statistical analysis was performed with Meta-Disc 1.4. Results: A total of 136 patients included in the rCBV analysis: 79 with high-grade glioma and 57 with metastasis. The pooled sensitivity, specificity, positive likelihood ratio (+LR), negative likelihood ratio (-LR) and diagnostic odds ratio (DOR) for differentiating high-grade glioma from metastasis were 82% (95% CI 0.72-0.90), 96% (95% CI 0.88-1.00), 18.04 (95% CI 5.41-60.15), 0.19 (95% CI 0.12-0.31), and 90.20 (95% CI 23.10-352.27), respectively. The value of Cochran's Q of DOR was 0.78 ($P = 0.6774$), and I² was 0.0%, revealing that no statistically significant between-study heterogeneity was found. Conclusions: The results of this present study clearly present that the peritumoural rCBV values derived from DSCI could be used in distinguishing high-grade gliomas from intracranial metastases in the preoperative.

Keywords: Relative cerebral blood volume, dynamic susceptibility contrast imaging, high grade gliomas, metastases, meta-analysis

Introduction

High-grade gliomas and intracranial metastases are the two most commonly identified brain neoplasms in the adult population. In the preoperative period, discriminating those two tumor types is of the utmost importance as treatment strategies vary [1]. In patients with a suspected intracranial metastasis without a clinical history of systemic malignancy should experience a complex systemic staging to find the primary cancer site, and evaluate the other distant lesions before any surgery or medical treatment [2]. On the contrary, in patients with a high-grade glioma, tumor resection followed by postoperative radiotherapy and chemotherapy (usually temozolomide, TMZ) represents the standard of care [3]. As the imaging fea-

tures and contrast-enhancement patterns are typical for both [4], so these two entities may be indistinguishable. At present, a surgical biopsy remains the gold-standard reference, however, it should be acknowledged that it might provide histopathological data about a limited part of the tumor and not necessarily about the whole tumor tissue [5]. However, various advanced oncologic imaging techniques have been searched in an attempt to differentiate intracranial tumor type without histopathological examination, such as diffusion tensor imaging (DTI) [6], magnetic resonance spectroscopy (MRS) [7], and positron emission tomography (PET) [8].

As an advanced magnetic resonance images (MRI) technique, dynamic susceptibility contrast imaging (DSCI) could be used to calculate

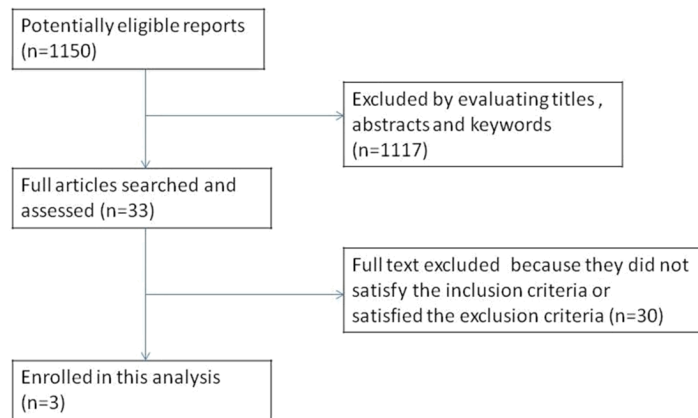


Figure 1. Flow diagram of the search results.

neovascularization areas via the quantification of relative cerebral blood volume (rCBV) parameter, which reveals the quantity of blood present within a tissue [5]. Previous studies have attempted to differentiate high-grade gliomas from intracranial metastases by analyzing the characteristics of peritumoral rCBV values, with controversial results [5, 9-12].

Hence, the aim of this meta-analysis was to assess the potential role of peritumoral rCBV values derived from dynamic susceptibility contrast imaging in differentiating high-grade gliomas from intracranial metastases.

Materials and methods

We searched the Medline and Embase database from 2004 to June 2014, using the following strategy: (dynamic susceptibility contrast or relative cerebral blood volume or magnetic resonance imaging or DSC or rCBV or MRI) and metastas* and (glioma* or anaplastic astrocytoma* or glioblastoma*). Studies were included in this study regardless of language used.

The inclusion criteria were as follows: (1) all patients underwent DSCI before the biopsy or surgery; (2) the diagnosis of the brain tumor cases were confirmed histopathologically; (3) the regions of interest (ROI) were placed on the peritumoural region; (4) the index used to describe the rCBV (minimum, maximum or average expression) could be obtained.

The exclusion criteria were as follows: (1) the articles could not provide enough data to rebuild fourfold table; (2) the patients were replicated in other articles; (3) the type of article was a review, editorial or letter; (4) the patients

having more than one lesion. Disagreements were resolved by consensus.

Two authors (R.F.L., X.W.) independently performed the search, reviewed all eligible articles and excluded obviously irrelevant studies by reading titles, abstracts, and keywords. And then, three authors (R.F.L., X.W., M. L.) independently assessed the full text of the rest publications and selected those studies that met the inclusion criteria of this meta-analysis. Disagreements were resolved by consensus.

Two authors (R.F.L., X.W.) independently assessed the quality of each article according to the QUADAS criteria [13], and disagreements were resolved by consensus. The QUADAS tool includes 14 items, and each item can be replied by “unclear”, “no”, or “yes”. We weighted all items equally and scored each item 1 for “unclear”, 0 for “no”, and 2 for “yes”.

The same independent authors extracted data from included articles and solved disagreement by consensus. Extracted information from included articles comprised about information of the study design, the nation of origin, the patients, the authors, the publication year, QUADAS score, MRI field strength and the index used to describe the rCBV (minimum, maximum or average expression). As the statistical data, the numbers of true negative (TN), false negative (FN), true positive (TP) and false positive (FP) were extracted. If there was not sufficient information in the article to rebuild fourfold table, we contacted the corresponding author.

For all of the included articles, the sensitivity, specificity, positive likelihood ratio, negative likelihood ratio and their diagnostic odds ratio were counted. I^2 , Chi-square tests and Cochran-Q tests were performed to assess the heterogeneity between studies. And an I^2 value $>50\%$ indicated heterogeneity [14]. If the heterogeneity was statistically significant, we pooled the sensitivities and specificities and diagnostic odds ratio by the random effect model. On the contrary, the fix effect model was performed if heterogeneity was not statistically significant. The above mentioned analyses were performed employing Meta-Disc 1.4 [15].

Table 1. Characteristics of the included studies

Study	Year	Nation	No. of patients (n)	Study design	Field strength (T)	Index	QUADAS score
Tsougos [16]	2012	Greece	49	P	3.0	MrCBV	25
Hakyemez [17]	2010	Turkey	48	R	1.5	MrCBV	24
Bulakbasi [18]	2005	Turkey	39	P	1.5	MrCBV	23

P, Prospective; R, Retrospective; MrCBV, maximum relative cerebral blood volume; QUADAS score, the quality assessment of diagnostic accuracy studies score.

Table 2. The data and diagnostic accuracy in included studies

Study	TP	FP	FN	TN	PLR	NLR	SEN	SPE	DOR
Tsougos [16]	28	1	7	13	11.20	0.22	0.80	0.93	52.00
Hakyemez [17]	17	1	5	25	20.09	0.24	0.77	0.96	85.00
Bulakbasi [18]	20	0	2	17	32.09	0.11	0.91	1.0	287.00

PLR, Positive likelihood ratio; NLR, Negative likelihood ratio; TP, True positive; FP, False positive; FN, False negative; TN, True negative; SEN, Sensitivity; SPE, Specificity; DOR, Diagnostic odds ratio.

Results

From the initial 1150 articles, 1117 articles were regarded as irrelevant for this analysis and excluded by reviewed their titles, abstracts and keywords. Full text of the 33 relevant articles was obtained and assessed. Only 3 of these articles were included this analysis which [16-18] contained the appropriated data. The study selection flow diagram was showed in **Figure 1**. The relevant information of the articles included in this analysis was listed in **Tables 1** and **2**.

A total of 136 patients included in the rCBV analysis: 79 with high-grade glioma and 57 with metastasis. The pooled sensitivity, specificity, positive likelihood ratio (+LR), negative likelihood ratio (-LR) and diagnostic odds ratio (DOR) for differentiating high-grade glioma from metastasis were 82% (95% CI 0.72-0.90), 96% (95% CI 0.88-1.00), 18.04 (95% CI 5.41-60.15), 0.19 (95% CI 0.12-0.31), and 90.20 (95% CI 23.10-352.27), respectively (Forrest plot see **Figure 2**). The value of Cochran's Q of DOR was 0.78 ($P = 0.6774$), and I^2 was 0.0%, revealing that no statistically significant between-study heterogeneity was found.

Discussion

In the present study, the rCBV derived from DSCI, which had 82% (72-90%) sensitivity, 96% (88-100%) specificity and 90.20 (23.10-352.27) DOR, is confirmed to own a high diagnostic value for the differentiation high-grade gliomas from intracranial metastases.

High-grade gliomas consist of WHO grade III and IV glial tumors. WHO grade III gliomas have the feature of mitoses and anaplasia activity, and anaplastic astrocytoma is the most common sub-type, however, WHO grade IV gliomas have the feature of necrosis and micrangium proliferation, and are often referred to as glioblastoma

[19]. Lung and breast cancers are the two most common primary tumors metastasize to the brain [20]. As the imaging characteristics of high-grade gliomas are similar to those of metastatic tumors, so these two tumor types may be indistinguishable. The key to making the differentiating between intracranial metastases and high-grade gliomas seems to lie in detecting the changes of the peritumoral area [21]. The peritumoral edema of intracranial metastases is considered as pure vasogenic edema, whereas, the peritumoral edema of high-grade gliomas is referred to as infiltrative edema [21]. Since the advent of DSCI, the ability to distinguish high-grade gliomas from intracranial metastases has been a source of interest. DSCI could be used to quantitative measure neovascularization areas via the quantification of rCBV values [5]. The rCBV values were calculated by using the ratio between the CBV values in the diseased region and in the contralateral white matter [21].

Our meta-analysis demonstrates that peritumoral rCBV values of the high-grade gliomas significantly increased compared with that of the intracranial metastases and own a high diagnostic value. The peritumoral areas of high-grade gliomas suggest an increase in the rCBV values due to tumour infiltration and associated neoangiogenesis [16]. And the increase of peritumoral rCBV values may also reveal diffuse migration of glial tumor cells along vessels of the white matter tracts migrating beyond the visible tumor edges on the contrast-enhanced

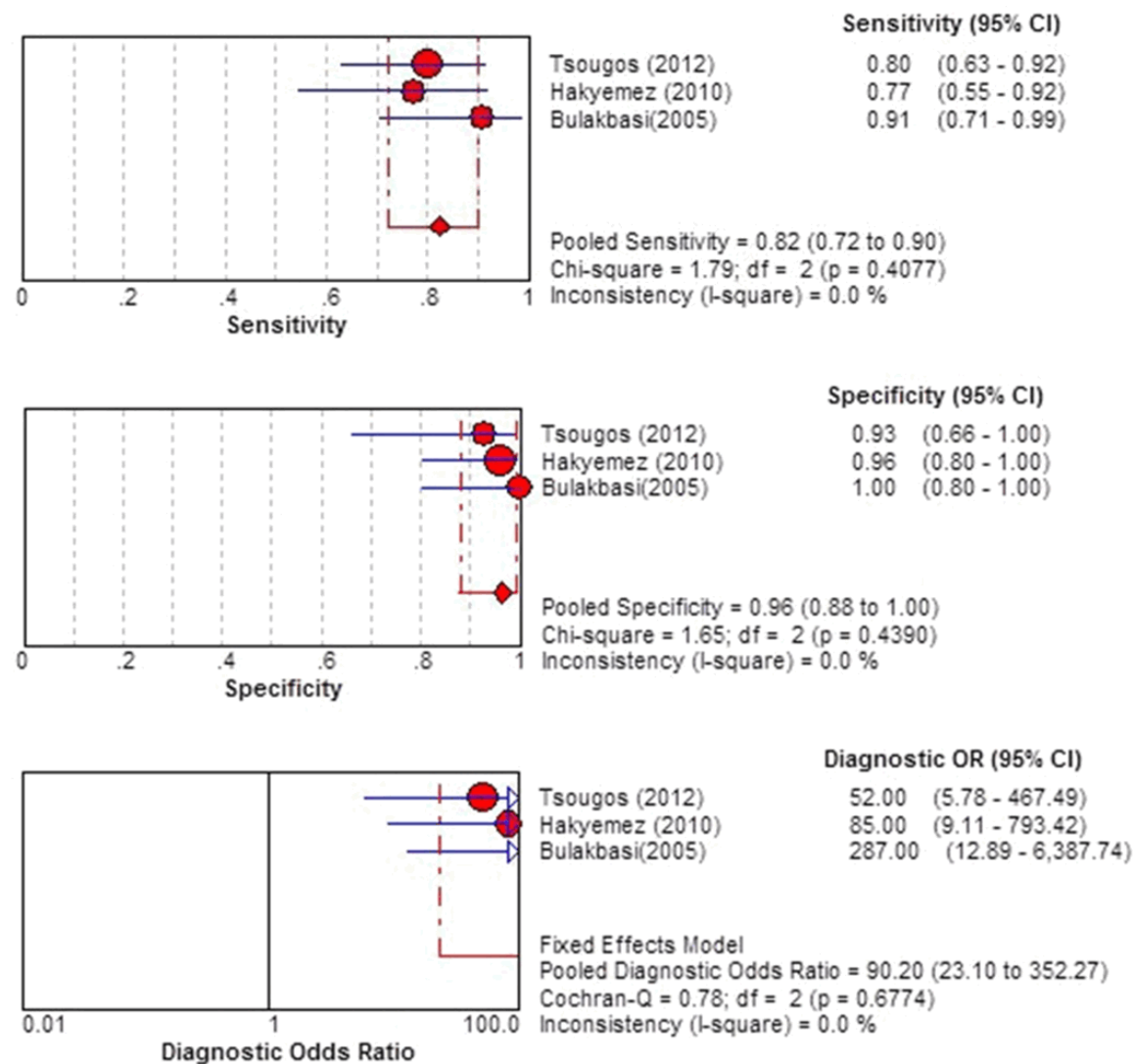


Figure 2. Forest plot of the sensitivity, specificity, and DOR of rCBV for discriminating high-grade gliomas from intracranial metastases.

T1-weighted images [21]. Whereas, intracranial metastases migrate via the blood flow and intrude into the capillary blood-brain barrier (BBB) without inducing neoangiogenesis [21]. Instead, metastatic brain tumors contain highly leaky capillaries that resemble those of the primary systemic cancers [22]. Hence, T2-weighted regions of hyperintensities seen in peritumoral areas surrounding metastatic tumors are likely to be vasogenic oedema related with the leakiness of those abnormal capillaries [23]. In addition, experiments in animals have suggested that blood flow in edematous peritumoral tissue is decreased as a result of the local compression of the micro-circulation by

extravasated edema fluid [24]. These two factors may result in the decrease in rCBV values in the peritumoral area of the metastases [23].

Some limitations in this present study should be acknowledged. First, our study was merely based on published studies, which tend to report significant or positive results; whereas, those articles with negative or insignificant results are much more vulnerable to rejection by some publications. Hence, the diagnostic value may be overestimated. Second, due to the relative small sample size in our study, we did not evaluate the publication bias and failed to draw the funnel plots and the summary

receiver operating characteristic (SROC) curve. We will perfect this analysis, if more relevant studies are published in the future.

In conclusion, the results of this present study clearly present that the peritumoral rCBV values derived from DSCI could be used in distinguishing high-grade gliomas from intracranial metastases in the preoperative.

Disclosure of conflict of interest

None.

Address correspondence to: Dr. Yanhui Liu, Department of Neurosurgery, West China Hospital of Sichuan University, Chengdu, P. R. China. E-mail: Yhliu2011@163.com

References

- [1] Chiang IC, Kuo YT, Lu CY, Yeung KW, Lin WC, Sheu FO, Liu GC. Distinction between high-grade gliomas and solitary metastases using peritumoral 3-T magnetic resonance spectroscopy, diffusion, and perfusion imaging. *Neuroradiology* 2004; 46: 619-627.
- [2] Lee EJ, Ahn KJ, Lee EK, Lee YS, Kim DB. Potential role of advanced MRI techniques for the peritumoral region in differentiating glioblastoma multiforme and solitary metastatic lesions. *Clin Radiol* 2013; 68: e689-e697.
- [3] Stupp R, Tonn JC, Brada M, Pentheroudakis G. High-grade malignant glioma: ESMO Clinical Practice Guidelines for diagnosis, treatment and follow-up. *Ann Oncol* 2010; 21: v190-v193.
- [4] Svolos P, Kousi E, Kapsalaki E, Theodorou K, Fezoulidis I, Kappas C, Tsougos I. The role of diffusion and perfusion weighted imaging in the differential diagnosis of cerebral tumors: a review and future perspectives. *Cancer Imaging* 2014; 14: 20.
- [5] Svolos P, Tsolaki E, Kapsalaki E, Theodorou K, Fountas K, Fezoulidis I, Tsougos I. Investigating brain tumor differentiation with diffusion and perfusion metrics at 3T MRI using pattern recognition techniques. *Magn Reson Imaging* 2013; 31: 1567-1577.
- [6] Lu S, Ahn D, Johnson G, Cha S. Peritumoral diffusion tensor imaging of high-grade gliomas and metastatic brain tumors. *AJNR Am J Neuroradiol* 2003; 24: 937-941.
- [7] Howe FA, Barton SJ, Cudlip SA, Stubbs M, Saunders DE, Murphy M, Wilkins P, Opstad KS, Doyle VL, McLean MA, Bell BA, Griffiths JR. Metabolic profiles of human brain tumors using quantitative in vivo 1H magnetic resonance spectroscopy. *Magn Reson Med* 2003; 49: 223-232.
- [8] Wong TZ, van der Westhuizen GJ, Coleman RE. Positron emission tomography imaging of brain tumors. *Neuroimaging Clin N Am* 2002; 12: 615-626.
- [9] Tsolaki E, Svolos P, Kousi E, Kapsalaki E, Fountas K, Theodorou K, Tsougos I. Automated differentiation of glioblastomas from intracranial metastases using 3T MR spectroscopic and perfusion data. *Int J Comput Assist Radiol Surg* 2013; 8: 751-761.
- [10] Chen R, Wang S, Poptani H, Melhem ER, Herskovits EH. A bayesian diagnostic system to differentiate glioblastomas from solitary brain metastases. *Neuroradiol J* 2013; 26: 175-183.
- [11] Halshtok NO, Sadetzki S, Chetrit A, Raskin S, Yaniv G, Hoffmann C. Perfusion-weighted imaging of peritumoral edema can aid in the differential diagnosis of glioblastoma multiforme versus brain metastasis. *Isr Med Assoc J* 2013; 15: 103-105.
- [12] Fayed N, Dávila J, Medrano J, Olmos S. Malignancy assessment of brain tumours with magnetic resonance spectroscopy and dynamic susceptibility contrast MRI. *Eur J Radiol* 2008; 67: 427-433.
- [13] Whiting P, Rutjes AWS, Reitsma JB, Bossuyt PM, Kleijnen J. The development of QUADAS: a tool for the quality assessment of studies of diagnostic accuracy included in systematic reviews. *BMC Med Res Methodol* 2003; 3: 25.
- [14] Higgins JP, Thompson SG, Deeks JJ, Altman DG. Measuring inconsistency in meta-analyses. *BMJ* 2003; 327: 557-560.
- [15] Zamora J, Abaira V, Muriel A, Khan K, Coomarasamy A. Meta-DiSc: a software for meta-analysis of test accuracy data. *BMC Med Res Methodol* 2006; 6: 31.
- [16] Tsougos I, Svolos P, Kousi E, Fountas K, Theodorou K, Fezoulidis I, Kapsalaki E. Differentiation of glioblastoma multiforme from metastatic brain tumor using proton magnetic resonance spectroscopy, diffusion and perfusion metrics at 3T. *Cancer Imaging* 2012; 12: 423-436.
- [17] Hakyemez B, Erdogan C, Gokalp G, Dusak A, Parlak M. Solitary metastases and high-grade gliomas: radiological differentiation by morphometric analysis and perfusion-weighted MRI. *Clinical Radiology* 2010; 65: 15-20.
- [18] Bulakbasi N, Kocaoglu M, Farzaliyev A, Tayfun C, Ucoz T, Somuncu I. Assessment of diagnostic accuracy of perfusion MR imaging in primary and metastatic solitary malignant brain tumors. *AJNR Am J Neuroradiol* 2005; 26: 2187-2199.
- [19] Louis DN, Ohgaki H, Wiestler OD, Cavenee WK, Burger PC, Jouvet A, Scheithauer BW, Kleihues

- P. The 2007 WHO classification of tumours of the central nervous system. *Acta Neuropathol* 2007; 114: 97-109.
- [20] Eichler AF, Chung E, Kodack DP, Loeffler JS, Fukumura D, Jain RK. The biology of brain metastases-translation to new therapies. *Nat Rev Clin Oncol* 2011; 8: 344-356.
- [21] Lee E J, Ahn K J, Lee E K, Lee YS, Kim DB. Potential role of advanced MRI techniques for the peritumoural region in differentiating glioblastoma multiforme and solitary metastatic lesions. *Clin Radiol* 2013; 68: e689-e697.
- [22] Cha S, Knopp EA, Johnson G, Wetzel SG, Litt AW, Zagzag D. Intracranial Mass Lesions: Dynamic Contrast-enhanced Susceptibility-weighted Echo-planar Perfusion MR Imaging. *Radiology* 2002; 223: 11-29.
- [23] Law M, Cha S, Knopp EA, Johnson G, Arnett J, Litt AW. High-Grade Gliomas and Solitary Metastases: Differentiation by Using Perfusion and Proton Spectroscopic MR Imaging. *Radiology* 2002; 222: 715-721.
- [24] Hossman KA, Blöink M. Blood flow and regulation of blood flow in experimental peritumoral edema. *Stroke* 1981; 12: 211-217.