

Case Report

A case of spontaneous tubal pregnancy with caesarean scar pregnancy

Jie Zhu¹, Yue-Ying Shen², Yu-Qing Zhao¹, Ru Lin³, Fang Fang¹

¹Department of Gynecology, Obstetrics and Gynecology Hospital of Fudan University, Shanghai Key Laboratory of Female Reproductive Endocrine Related Diseases, Shanghai, China; ²Department of Gynecology and Obstetrics, Maternity and Child Health Hospital of Tongxiang, Zhejiang, China; ³Department of Ultrasonics, Obstetrics and Gynecology Hospital of Fudan University, Shanghai, China

Received August 5, 2014; Accepted August 28, 2014; Epub September 15, 2014; Published September 30, 2014

Abstract: Tubal pregnancy with caesarean scar pregnancy is rare. Early, accurate diagnosis and treatment for this kind of ectopic pregnancy can lead to a decrease of maternal morbidity and mortality. Here, we report a rare case of spontaneous tubal pregnancy co-existing with caesarean scar pregnancy. After timely emergency laparoscopy and curettage, the patient was cured.

Keywords: Ectopic pregnancy, fallopian pregnancy, caesarean scar pregnancy, laparoscopy, curettage

Introduction

Ectopic pregnancy, a leading cause of maternal morbidity and mortality, occurs in approximately 2% of all pregnancies worldwide [1]. The majority of ectopic pregnancies are located in the fallopian tube. Atypical ectopic pregnancies, including those in the cervix, ovary, abdomen, caesarean section scar, and the interstitial portion of fallopian tube are rare and occur in less than 10% of all ectopic pregnancies. These atypical forms of ectopic pregnancies are not only difficult to diagnosis, but also are associated with high morbidity [2]. The present case report describes a rare case spontaneous tubal pregnancy co-existing with caesarean scar pregnancy.

Case report

A 33-year-old pregnant female, gravita 3 para 1, who was at 41 days gestation (the patient has a menstrual cycle of 28 days and her menstrual period usually lasts about 3-4 days) based on last menstrual period, presented to the emergency department with lower abdominal pain starting the afternoon of presentation. Her previous obstetric history includes one induced abortion and one caesarean delivery without complications. Her previous gynecologic

history was unremarkable. Upon admission, physical examination revealed stable vital signs with diffuse lower abdominal tenderness and signs of peritoneal irritation. During the bimanual examination, cervical motion tenderness was present but no blood was seen in the vaginal vault. Enlarged uterus, corresponding to about 50 days of pregnancy, was detected and lower uterine tenderness was notable. Meanwhile, the bimanual examination revealed an irregular palpable mass in the right adnexa, measuring 5-6 cm, which was associated with slight tenderness. The serum β -hCG level was 25,793 mIU/ml. Transvaginal ultrasonographic examination demonstrated a gestational sac with a small yolk sac in the anterior cervico-isthmus region, an echogenic ring within the anterior myometrium at the site of caesarean section scar (**Figure 1A**), and the thickness of the uterine wall between gestational sac and serosa was only 3-4 mm. In addition, ultrasound examination also showed a 6.2 × 4.7 × 3.4 cm heterogenous lesion in front of the right ovary with increased vascularity (**Figure 1B**) and free fluid in the cul-de-sac suggestive of ectopic gestation with hemoperitoneum. Moreover, an irregular echo free zone about 3.5 × 3.2 × 3.2 cm was seen in the left ovary. Provisional diagnosis of tubal pregnancy co-existing with caesarean scar pregnancy was

Tubal pregnancy with caesarean scar pregnancy

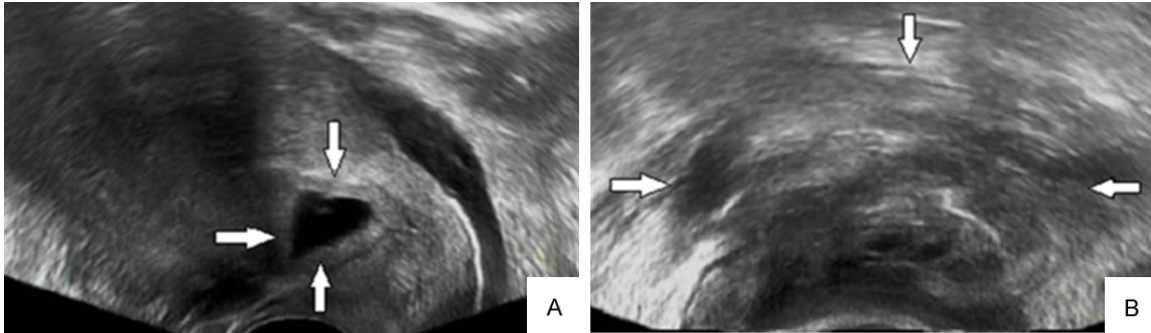


Figure 1. A. Transvaginal ultrasound showed a gestational sac about $1.7 \times 1.3 \times 1.0$ cm with a small yolk sac in the anterior cervico-isthmic region and an echogenic ring within the anterior myometrium at the site of cesarean section scar. B. Transvaginal ultrasound showed a $6.2 \times 4.7 \times 3.4$ cm heterogenous lesion in front of right ovary.

made and she was scheduled for emergency diagnostic laparoscopy. During the laparoscopic exploration, the presence of a 200 ml pelvic hemocele was noted, the lower segment of the uterus bulged slightly at the site of previous cesarean section scar without obvious rupture. The ampulla and fimbria of the tube was enlarged to about 5-6 cm with dark blood clots around the fimbria. Meanwhile, a small left ovarian cyst was found. The right ovary and left fallopian were normal in appearance. Right salpingectomy and left oophorectomy was then performed. Subsequently, the patient underwent successful curettage. The post-surgical pathologic examination revealed villi tissue in both the resected right fallopian tube and in tissue scratched out from the uterus which supported the diagnosis of tubal pregnancy co-existing with caesarean scar pregnancy. The postoperative course was uneventful. The patient was discharged on the third postoperative day and her serum β -hCG decreased to normal level within 37 days after the surgery. The patient resumed normal menstruation within 50 days after the surgery.

Discussion

Implantation of the zygote outside the uterine cavity occurs in about 2% of all pregnancies. Since 1970, the rate of ectopic pregnancies has increased from 0.5% to 2%. However, the mortality rate of ectopic pregnancies has significantly declined. Two hundred years ago, the mortality rate due to ectopic pregnancy was greater than 60%, but currently, it has decreased to 9% of pregnancy-related mortality and less than 1% of overall female mortality [3].

The majority of ectopic pregnancies occur in the fallopian tube at locations of the, ampulla, isthmus, fimbria, and interstitial portion in descending order. Unusual sites of ectopic pregnancies, including caesarean scar pregnancy, cervical pregnancy, and abdominal pregnancy, are rare. Caesarean scar pregnancy (CSP) is defined as an ectopic pregnancy located in the myometrium of a previous caesarean scar [4]. Along with the increase of caesarean rate, the occurrence of CSP has also significantly increased. According to a recent case series, the incidence of CSP is approximately 1:2,226 of all pregnancies with a rate of 0.15% in women with a previous caesarean section and a rate of 6.1% of all ectopic pregnancies in women who have had at least one caesarean delivery [5]. The cause of this condition is not clear and there are many theories proposing an explanation. The most probable mechanism is that the embryo implants into the uterine wall through a tract from the endometrial canal up to the scar tissue or through a small internal dehiscence of the scar [5]. This form of gestation is a potentially life-threatening ectopic pregnancy with possible consequences of uterine rupture and massive bleeding which are directly related to maternal and fetal morbidity and mortality [6]. We present an extremely rare case of spontaneous tubal pregnancy co-existing with caesarean scar pregnancy which, to our knowledge, has never been reported in the literature either in natural conception or in pregnancy incorporating the use of assisted reproductive technology.

Thanks to progress made in the transvaginal ultrasound, radioimmunoassays for serum

Tubal pregnancy with caesarean scar pregnancy

β -hCG levels, and increased vigilance by clinicians with more experience performing diagnostic laparoscopy, most ectopic pregnancies can be diagnosed and treated before progressing to life threatening conditions. As a direct result of positive diagnosis of ectopic pregnancy being made before the occurrence of hemoperitoneum and/or hypovolemic shock, the mortality related to ectopic pregnancies has dramatically decreased [7]. The straightforward diagnosis of ectopic pregnancy should combine three pillars which include symptoms and positive signs during physical examination, ultrasonic features, and laboratory tests, especially serum β -hCG level, which can substantiate a primary suspicion [8]. Our patient presented with lower abdominal pain. Tubal pregnancy co-existing with caesarean scar pregnancy was initially diagnosed by ultrasound examination. The treatment was emergency surgery which created a good outcome. From this case, it can be learned that when pregnancy is conformed, any details of exceptions observed under ultrasound deserve attention.

Treatment of ectopic pregnancy depends on individual conditions. Treatment options for ectopic tubal pregnancies include expectant management, medical treatment with methotrexate, and operative management (from conservative to radical operative treatment) [9]. For caesarean section scar, expectant treatment has a poor prognosis because of risk of rupture [5]. There are several types of conservative treatment available including curettage, excision of trophoblastic tissues (laparoscopy or laparotomy) [10-12], and local and/or systemic administration of methotrexate [13]. Meanwhile, bilateral hypogastric artery ligation followed by trophoblastic evacuation, and selective uterine artery embolization combined with curettage and/or MTX administration are also viable treatment options to preserve the uterus and greatly reduce morbidity and mortality [14, 15]. Nevertheless, adequate consideration should be maintained to the risk of hemorrhage and subsequent hysterectomy. There are several approaches to handle caesarean scar pregnancy. As outlined above, we choose different treatments according to individual conditions. We will choose selective uterine artery embolization if there are high risks for acute massive bleeding or if the lesions are large and abundant in blood supply (according

to PI and RI under ultrasonic examination). We then do curettage under ultrasonic or laparoscopic monitoring 24-48 hours after UAE. If there is little risk for acute hemorrhage or the lesion is small and with light vascularity, we usually do curettage operation pre-treatment with MTX. If the thickness of the uterine wall between lesion and serosa is 3 mm or less, there is a high probability of scar rupturing during dilation and curettage. In the case of scar rupturing, dilation and curettage with laparoscopic monitoring is chosen so that we can laparoscopically resect the lesion and repair the gap in a timely fashion. If the thickness of the uterine wall between lesion and serosa is more than 3 mm, the chances of scar rupturing are relatively low. Under this condition, we usually choose curettage guided by ultrasonic monitoring. During the operation, we can view the lesion under real-time monitoring and find active bleeding timely. If the scar site remains actively bleeding after lesion resection and oxytocin is unsuccessful, a Foley catheter could be placed inside the uterine cavity to add 30 ml of normal saline in the air sac for compression hemostasis.

In this case, we had three hypothetical diagnoses prior to the operation: 1. Ruptured caesarean scar pregnancy which leads to pelvic hemothecoele. 2. Ruptured tubal pregnancy which leads to pelvic hemothecoele, meanwhile, shedding of deciduas leading to hemothecoele in uterine cavity. 3. Tubal pregnancy co-existing with caesarean scar pregnancy. Although the third condition is extremely rare, the detailed ultrasound report presented by the experienced radiologist made us believe that it had the highest probability. Considering the possibility of scar rupture or tubal rupture which resulted in internal hemorrhage, treatment with UAE or pre-treatment with MTX was not appropriate. Surgical intervention should be done at once and appropriate preparations should be made for the possibilities of scar rupture or the rupture of near-by organs, such as the bladder. Fortunately, no rupture was found during the operative exploration, and we successfully performed laparoscopic salpingectomy and curettage. A favorable outcome depends on early, accurate diagnosis and timely treatment supported by the entire team.

Disclosure of conflict of interest

None.

Tubal pregnancy with caesarean scar pregnancy

Address correspondence to: Fang Fang, Department of Gynecology, Obstetrics and Gynecology Hospital of Fudan University, Shanghai Key Laboratory of Female Reproductive Endocrine Related Diseases, No. 419 Fangxie Road, Shanghai, China. Tel: +86-21-33189900; Fax: +86-21-63455090; E-mail: fangfang1968@hotmail.com

References

- [1] Orazulike NC and Konje JC. Diagnosis and management of ectopic pregnancy. *Womens Health (Lond Engl)* 2013; 9: 373-85.
- [2] Barnhart KT. Clinical practice. Ectopic pregnancy. *N Engl J Med* 2009; 361: 379-87.
- [3] Alkatout I, Honemeyer U, Strauss A, Tinelli A, Malvasi A, Jonat W, Mettler L, Schollmeyer T. Clinical diagnosis and treatment of ectopic pregnancy. *Obstet Gynecol Surv* 2013; 68: 571-81.
- [4] Lai YM, Lee JD, Lee CL, Chen TC, Soong YK. An ectopic pregnancy embedded in the myometrium of a previous cesarean section scar. *Acta Obstet Gynecol Scand* 1995; 74: 573-6.
- [5] Ash A, Smith A and Maxwell D. Cesarean scar pregnancy. *BJOG* 2007; 114: 253-63.
- [6] Sadeghi H, Rutherford T, Rackow BW, Campbell KH, Duzyj CM, Guess MK, Kodaman PH, Norwitz ER. Cesarean scar ectopic pregnancy: case series and review of the literature. *Am J Perinatol* 2010; 27: 111-20.
- [7] Murray H, Baakdah H, Bardell T, Tulandi T. Diagnosis and treatment of ectopic pregnancy. *CMAJ* 2005; 173: 905-12.
- [8] Alkatout I, Honemeyer U, Strauss A, Tinelli A, Malvasi A, Jonat W, Mettler L, Schollmeyer T. Clinical diagnosis and treatment of ectopic pregnancy. *Obstet Gynecol Surv* 2013; 68: 571-81.
- [9] Orazulike NC and Konje JC. Diagnosis and management of ectopic pregnancy. *Womens Health (Lond Engl)* 2013; 9: 373-85.
- [10] Graesslin O, Dedecker F Jr, Quereux C, Gabriel R. Conservative treatment of ectopic pregnancy in a cesarean scar. *Obstet Gynecol* 2005; 105: 869-71.
- [11] Jiang S and Zhao S. Laparoscopic surgery for ectopic pregnancy within a cesarean scar. *Clin Exp Obstet Gynecol* 2013; 40: 440-4.
- [12] Nankali A, Ataee M, Shahlazadeh H, Daeichin S. Surgical management of the cesarean scar ectopic pregnancy: a case report. *Case Rep Obstet Gynecol* 2013; 2013: 525187.
- [13] Gong LL, Zhang L and Fang F. Inquisition of treatment methods of cesarean scar pregnancy. *Chinese J Clin Med* 2013; 20: 524-6.
- [14] Persadie RJ, Fortier A and Stopps RG. Ectopic pregnancy in a caesarean scar: a case report. *J Obstet Gynaecol Can* 2005; 27: 1102-6.
- [15] Yang MJ and Jeng MH. Combination of transarterial embolization of uterine arteries and conservative surgical treatment for pregnancy in a cesarean section scar. A report of 3 cases. *J Reprod Med* 2003; 48: 213-6.