

Original Article

Autologous platelet-rich plasma promotes endometrial growth and improves pregnancy outcome during *in vitro* fertilization

Yajie Chang¹, Jingjie Li¹, Yuqing Chen², Lina Wei¹, Xing Yang¹, Yanan Shi¹, Xiaoyan Liang¹

¹Center for Reproductive Medicine, Sixth Affiliated Hospital of Sun Yat-Sen University, Guangzhou 510000, China;

²Department of Gynecology and Obstetrics, The First Affiliated Hospital of Sun Yat-Sen University, Guangzhou 510080, China

Received October 29, 2014; Accepted January 7, 2015; Epub January 15, 2015; Published January 30, 2015

Abstract: Introduction: This study was to evaluate the effectiveness of PRP in the therapy of infertile women with thin endometrium (≤ 7 mm). Material and methods: Five women undergoing *in vitro* fertilization (IVF) with poor endometrial response still had thin endometrium (< 7 mm) after standard hormone replacement therapy (HRT) and had to cancel embryo transfer cycle. In addition to HRT, intrauterine infusion of PRP was performed. PRP was prepared from autologous blood by centrifugation, and 0.5-1 ml of PRP was infused into the uterine cavity on the 10th day of HRT cycle. If endometrial thickness failed to increase 72 h later, PRP infusion was done 1-2 times in each cycle. Embryos were transferred when the endometrium thickness reached > 7 mm. Results: Successful endometrial expansion and pregnancy were observed in all the patients after PRP infusion. Intrauterine PRP infusion represent a new method for the thin endometrium with poor response. Conclusion: This article reported that platelet-rich plasma (PRP) was able to promote the endometrial growth and improve pregnancy outcome of patients with thin endometrium.

Keywords: Thin endometrium, in vitro fertilization, platelet-rich plasma

Introduction

Successful embryo implantation requires an appropriate embryonic development coincident with a receptive endometrium. In clinical practice, adequate endometrial growth is required for successful implantation. The minimal endometrial thickness required for embryo transfer is 7 mm at the end of follicular phase [1]. Thin endometrium non-responsive to standard treatments is still a challenge in assisted reproductive technique (ART), which usually results in cycle cancellation and unplanned embryo cryopreservation. Various strategies have been developed for the treatment of thin endometrium, including extended use of exogenous estrogen [2], use of low-dose aspirin [3], vitamin E [4] and vaginal sildenafil citrate [5], electroacupuncture [6] and application of granulocyte colony stimulation factor (G-CSF) [7]. However, a number of women with thin endometrium remain non-

responsive even these remedies have been performed.

Platelet-rich plasma (PRP) is prepared from fresh whole blood which is collected from a peripheral vein, stored in acid citrate dextrose solution A (ACD-A) anticoagulant and processed to increase platelets by separating various components of blood [8]. Through activating platelets in PRP, cytokines and growth factors (GFs) become bioactive and are secreted within 10 min after clotting. These factors include vascular endothelial growth factor (VEGF), transforming growth factor (TGF), platelet-derived growth factor (PDGF) and epidermal growth factor (EGF) [9]. They can regulate cell migration, attachment, proliferation and differentiation, and promote extracellular matrix accumulation. Nowadays, PRP has been widely applied in different clinical scenarios, such as orthopedics, ophthalmology and wound healing [10] to improve the tissue regeneration. However, little is known regarding the application of PRP in the

Autologous platelet-rich plasma promotes pregnancy

Table 1. Patients' characteristics

Patient	Age (year)	Diagnosis	Endometrium (mm) with-out/with PRP infusion	Embryotransfer	Pregnancy	Outcome
1 ^a	31	Partial Asherman	5.9/7.0	2 blastocysts	Yes	Ongoing
2 ^b	35	Salpingitis	6.0/7.3	2 blastocysts	Yes (twin)	Ongoing
3 ^c	39	Repeated IVF failures	6.2/7.8	1 blastocyst	Yes	Missed abortion
4 ^d	36	POI	6.6/8.0	2 D3 embryos	Yes	Ongoing
5 ^e	33	Salpingitis	6.4/7.5	2 blastocysts	Yes (twin)	Ongoing

Footnotes: POI = primary ovarian insufficiency, FET = frozen embryo transfer, PRP = platelet-rich plasma, HRT = hormone replacement therapy. ^aThird FET cycle. Hysteroscopic resection of adhesion treatment was performed when the patient with a history of Asherman syndrome underwent dilation and curettage after miscarriage. Before this cycle, hysteroscopic examination was done again, there were no fibroids, and the endometrial lining was quite little. After the second PRP infusion in HRT cycle, the endometrial thickness was improved, and two blastocysts were transferred with a normally progressing singleton pregnancy. ^bSecond FET cycle. The endometrial thickness reached to 7.3 mm after single PRP infusion in HRT cycle, and two blastocysts were transferred with a progressing twin pregnancy. ^cFourth ET cycle. The patient had failed three IVF cycles with seven embryos transferred, and all cycles were ascribed to inadequate endometrial thickness. The endometrial thickness reached 7.8 mm after PRP infusion, and only one blastocyst was transferred. Serum HCG was 226 IU/ml at 3 weeks after embryo transfer, and an intrauterine gestational sac with fetal heart beat was observed by transvaginal ultrasonography in 7th pregnancy. However, fetal heart was undetectable by ultrasonography at the 9th week of pregnancy suggesting a missed abortion. The patient had accepted dilation and curettage. Chromosome detection of the trophoblast showed 45, XO. ^dSecond FET cycle. The patient had only 4 antral follicles, and AMH was 0.46 ng/ml. She was diagnosed as having POI, and just had two cleavage-stage embryos. Fresh ET cycle was cancelled because of inadequate endometrial thickness. In this HRT cycle, the endometrial thickness reached to 7.5 mm with two PRP infusions, and a normally progressing singleton pregnancy was observed. ^eSecond FET cycle, the endometrial thickness increased after PRP infusion in HRT cycle, and two blastocysts were transferred with a progressing twin pregnancy.

treatment of thin endometrium. This study was to evaluate the effectiveness of PRP in the therapy of infertile women with thin endometrium (≤ 7 mm).

Patients and methods

Demographics

Five patients with a history of the maximal endometrial thickness of < 7 mm were recruited on the day of administration of human chorionic gonadotropin (hCG), which resulted in fresh embryo transfer cancellation and unplanned embryos cryopreservation, and underwent frozen embryo transplantation in the Center for Reproductive Medicine of the Sixth Affiliated Hospital of Sun Yat-sen University from March 2014 to Jun 2014. The age of these patients ranged from 31 years to 39 years. **Table 1** summarizes their characteristics and *in vitro* fertilization (IVF) cycle outcome.

In conventional hormone replacement therapy (HRT) treatment cycles, estradiol valerate (Progynova; Bayer Schering Pharma, France) at 6 mg/d was given on day 3 of menstrual cycle. The dosage was steadily increased every 4

days, and the maximal dose was 12 mg/d. All the five patients showed inadequate thin endometrium (5.9-6.6 mm) on the day of administration of progesterone, resulting in cycle cancellation. To evacuate the intrauterine adhesions, hysteroscopic examination was performed. There were no fibroids or polyps in diagnostic hysteroscopy. Chronically non-responsive thin endometrium resistant to standard treatment-caused embryo transfer cancellation. They then received administration of PRP, which was approved by the Ethical Review Board of the Sixth Affiliated Hospital of Sun Yat-Sen University, and informed consent was obtained before study.

HRT protocol and PRP preparation

Estradiol valerate (Progynova; Bayer Schering Pharma, France) at 12 mg/d was given on day 3 of menstrual cycle. PRP was prepared from autologous blood by a modified method of Yamaguchi *et al* [11]. On the 10th day of HRT cycle, 15 ml of venous blood was drawn from the syringe pre-filled with 5 ml of anticoagulant solution (ACD-A), and centrifuged immediately at 200^g for 10 min. The blood was divided into three layers: red blood cells at the bottom, cellular plasma in the supernatant and a buffy

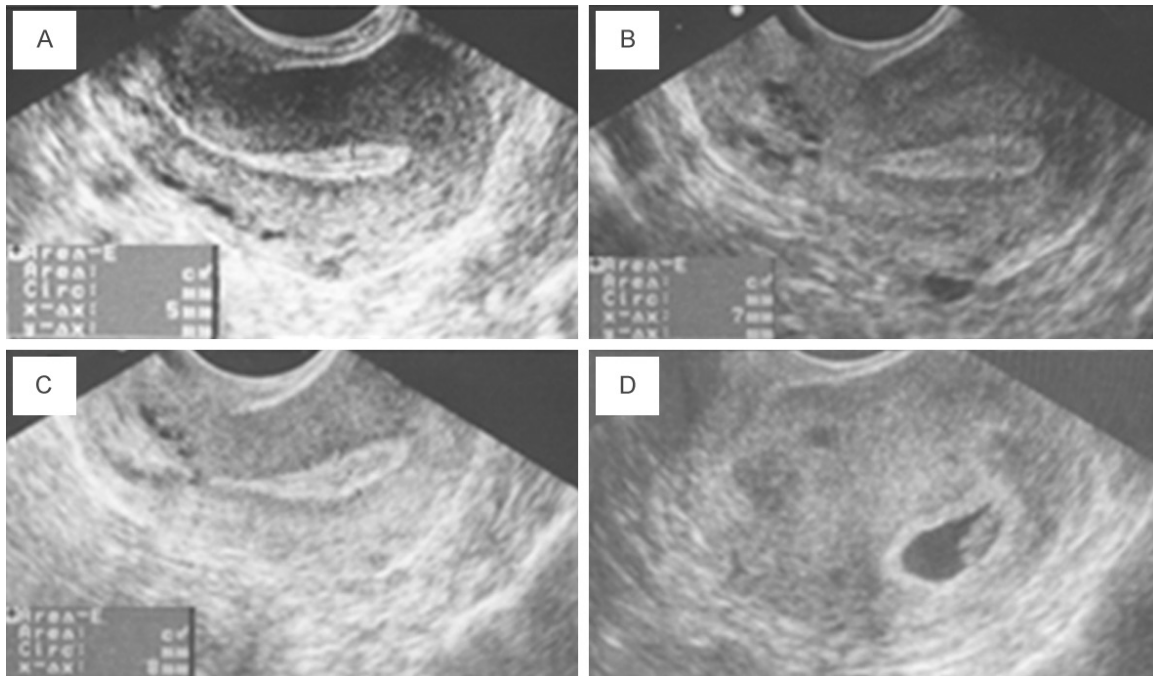


Figure 1. Ultrasonography in patient 1. A. Quite thin endometrium (only 5 mm) on the day of progesterone administration in traditional treatment. B. Remarkable improvement in endometrial thickness after first infusion of PRP (7 mm on day 5 before progesterone administration). C. After second infusion of PRP, the endometrial thickness reached near 8 mm on day 2 before progesterone administration. D. An intrauterine gestational sac was confirmed by transvaginal ultrasonography at approximately 6 weeks.

coat layer between them. The plasma layer and buffy coat were collected to another tube and re-centrifuged at 500* g for 10 min. The resulting pellet of platelets was mixed with 1 ml of supernatant, and then 0.5-1 ml of PRP was obtained. It was infused into the uterus cavity immediately with Tomcat catheter (0.5-1 ml). Endometrial thickness was re-assessed 72 h later. If the endometrial thickness was not satisfied, infusion of PRP was performed 1-2 times. Of five patients, only patient 2 received a single infusion, and the remaining 4 underwent 2 infusions.

Treatment assessment

Endometrial thickness was measured at the thickest part at the longitudinal axis of the uterus by an experienced ultrasonographer (**Figure 1**). The thickness was measured thrice to confirm thin endometrium, and the average from 3 measurements was recorded. The primary endpoint was endometrial thickness measured in transvaginal sonography, the second endpoint was clinical pregnancy after embryo transfer. Clinical pregnancy was confirmed when an

intrauterine gestational sac was identified by transvaginal ultrasonography and an increase in serum β -HCG was present.

Results

The endometrial thickness increased at 48-72 h after PRP infusion in all the patients, and reached > 7 mm on the day of progesterone administration. Patients 1, 2 and 5 underwent transfer of two blastocysts, patient 3 had transferred one blastocyst and patient 4 had transferred two cleavage-stage embryos. Cleavage-stage embryos were transferred on the 3rd day after progesterone administration, and blastocysts were transferred on the 5th day after progesterone administration.

All the five patients were pregnant. Patients 2 and 5 had twin pregnancy, and the remaining 3 had one intrauterine gestational sac. Patient 3 experienced a missed abortion at the 9th week of pregnancy. After induced abortion, detection of chromosomes of the trophoblast showed 45, XO. Pregnancies in remaining 4 patients were normally progressing.

Discussion

The major functions of platelets are preventing acute blood loss and repairing vascular walls and adjacent tissues after injury. During wound healing, platelets are activated and aggregate to release granules containing growth factors, such as TGF- β , PDGF, IGF, VEGF, EGF and FGF-2 [12, 13], which stimulate the inflammatory cascade and healing process. PRP is defined as a plasma fraction of autologous blood with the concentration of platelets 4-5 times above normal [14]. It is fractionated plasma from autologous blood and contains concentrated platelets. With the functions of platelets, PRP is nowadays widely applied in clinical scenarios, even in mucous tissues such as eye [15] and mouth [16], to improve tissue regeneration. In addition, the combined PRP and mesenchymal stem cells have been widely studied *in vitro* [17]. This study was to investigate the effectiveness of PRP in improving the endometrial regeneration and the inherent regenerating capacity of endometrium.

In this study, five patients had extraordinarily poor endometrial quality and the endometrium was non-responsive to conventional estrogen therapy, resulting in cycle cancellation, low possibility of pregnancy and heavily emotional distress. After application of PRP, the endometrial thickness was satisfactory in all the patients, who became pregnant after ET. Of them, the pregnancy was normally progressing in 4 women and one had missed abortion.

As the diagnosis of implantation failure is always tentative, clinical efficacy of PRP in this indication is difficult to assess. However, the potential proliferative effect of PRP on the endometrium can be sonographically evaluated. In addition, the endometrial thickness is an important indicator for reproduction [18]. Thus, the endometrial thickness was employed to assess the effect of PRP. The improvement in the endometrial thickness in this study is great likelihood attributable to the infusion of PRP. Although more studies are needed to investigate which degree PRP affects endometrium, and how it improves the reproduction, our findings suggest that endometrial infusion of PRP is able to increase the endometrial thickness and help the embryo implantation.

Unfortunately, one patient (patient 3) had a missed abortion due to chromosomal abnormality.

No evidence attributed to the infusion of PRP, as the other four cases had ongoing pregnancy.

Since PRP is prepared from autologous blood, theoretically there are minimal risks for disease transmission, immunogenic reactions and cancers [19]. Based on the pioneering and long-term clinical experience on the application of PRP in the oralmaxillary field and thousands of patients having received this therapy so far, the use of PRP is considered safe [20]. In this study, no infection or injury was observed.

As we know, our study for the first time reported the application of intrauterine infusion of PRP to improve the endometrial thickness in women with thin endometrium. Increase in endometrial thickness after infusion of PRP in all the patients suggests that intrauterine infusion of PRP represents a novel strategy for the thin endometrium with poor response to conventional therapy. The findings provide evidence for future randomized, controlled trials with large sample size in this field.

Acknowledgements

This work was supported by the National Natural Science Foundation of China (No. 30973202 and 81100401), Research Program of Guangdong Province (No. S2011010004621), and the Doctoral Fund of the Ministry of Education of China (No. 20090171110059).

Disclosure of conflict of interest

None.

Address correspondence to: Xiaoyan Liang, Center for Reproductive Medicine, Sixth Affiliated Hospital, Sun Yatsen University, 17th Shougou Ling Road, Guangzhou 510000, China. Tel: +86-20-38048012; Fax: +86-20-38048013; E-mail: liangxiaoyan_gz@163.com

References

- [1] Khalifa E, Brzyski RG, Oehninger S, Acosta AA and Muasher SJ. Sonographic appearance of the endometrium: the predictive value for the outcome of in-vitro fertilization in stimulated cycles. *Hum Reprod* 1992; 7: 677-680.
- [2] Chen MJ, Yang JH, Peng FH, Chen SU, Ho HN and Yang YS. Extended estrogen administration for women with thin endometrium in frozen-thawed in-vitro fertilization programs. *J Assist Reprod Genet* 2006; 23: 337-342.

Autologous platelet-rich plasma promotes pregnancy

- [3] Khairy M, Banerjee K, El-Toukhy T, Coomarasamy A and Khalaf Y. Aspirin in women undergoing in vitro fertilization treatment: a systematic review and meta-analysis. *Fertil Steril* 2007; 88: 822-831.
- [4] Takasaki A, Tamura H, Miwa I, Taketani T, Shimamura K and Sugino N. Endometrial growth and uterine blood flow: a pilot study for improving endometrial thickness in the patients with a thin endometrium. *Fertil Steril* 2010; 93: 1851-1858.
- [5] Sher G and Fisch JD. Effect of vaginal sildenafil on the outcome of in vitro fertilization (IVF) after multiple IVF failures attributed to poor endometrial development. *Fertil Steril* 2002; 78: 1073-1076.
- [6] Ho M, Huang LC, Chang YY, Chen HY, Chang WC, Yang TC and Tsai HD. Electroacupuncture reduces uterine artery blood flow impedance in infertile women. *Taiwan J Obstet Gynecol* 2009; 48: 148-151.
- [7] Gleicher N, Vidali A and Barad DH. Successful treatment of unresponsive thin endometrium. *Fertil Steril* 2011; 95: 2123.e13-7.
- [8] Amable PR, Carias RB, Teixeira MV, da Cruz Pacheco I, Correa do Amaral RJ, Granjeiro JM and Borojevic R. Platelet-rich plasma preparation for regenerative medicine: optimization and quantification of cytokines and growth factors. *Stem Cell Res Ther* 2013; 4: 67.
- [9] Lee JW, Kwon OH, Kim TK, Cho YK, Choi KY, Chung HY, Cho BC, Yang JD and Shin JH. Platelet-rich plasma: quantitative assessment of growth factor levels and comparative analysis of activated and inactivated groups. *Arch Plast Surg* 2013; 40: 530-535.
- [10] Dhillon RS, Schwarz EM and Maloney MD. Platelet-rich plasma therapy - future or trend? *Arthritis Res Ther* 2012; 14: 219.
- [11] Yamaguchi R, Terashima H, Yoneyama S, Tadanoto S and Ohkohchi N. Effects of platelet-rich plasma on intestinal anastomotic healing in rats: PRP concentration is a key factor. *J Surg Res* 2012; 173: 258-266.
- [12] Christgau M, Moder D, Hiller KA, Dada A, Schmitz G and Schmalz G. Growth factors and cytokines in autologous platelet concentrate and their correlation to periodontal regeneration outcomes. *J Clin Periodontol* 2006; 33: 837-845.
- [13] Vogrin M, Ruprecht M, Crnjac A, Dinevski D, Krnjc Z and Recnik G. The effect of platelet-derived growth factors on knee stability after anterior cruciate ligament reconstruction: a prospective randomized clinical study. *Wien Klin Wochenschr* 2010; 122 Suppl 2: 91-95.
- [14] Marx RE. Platelet-rich plasma (PRP): what is PRP and what is not PRP? *Implant Dent* 2001; 10: 225-228.
- [15] Alio JL, Arnalich-Montiel F and Rodriguez AE. The role of "eye platelet rich plasma" (E-PRP) for wound healing in ophthalmology. *Curr Pharm Biotechnol* 2012; 13: 1257-1265.
- [16] Pal US, Mohammad S, Singh RK, Das S, Singh N and Singh M. Platelet-rich growth factor in oral and maxillofacial surgery. *Natl J Maxillofac Surg* 2012; 3: 118-123.
- [17] Nagata MJ, de Campos N, Messori MR, Pola NM, Santinoni CS, Bomfim SR, Fucini SE, Ervolino E, de Almeida JM, Theodoro LH and Garcia VG. Platelet-rich plasma, low-level laser therapy, or their combination promotes periodontal regeneration in fenestration defects: a preliminary in vivo study. *J Periodontol* 2014; 85: 770-778.
- [18] Fatemi HM and Popovic-Todorovic B. Implantation in assisted reproduction: a look at endometrial receptivity. *Reprod Biomed Online* 2013; 27: 530-538.
- [19] Anitua E and Orive G. Short implants in maxillae and mandibles: a retrospective study with 1 to 8 years of follow-up. *J Periodontol* 2010; 81: 819-826.
- [20] Everts PA, Knape JT, Weibrich G, Schonberger JP, Hoffmann J, Overvest EP, Box HA and van Zundert A. Platelet-rich plasma and platelet gel: a review. *J Extra Corpor Technol* 2006; 38: 174-187.