

Original Article

A novel specialized staging system for cancellous fracture healing, distinct from traditional healing pattern of diaphysis cortical fracture?

Duanyang Han*, Na Han*, Feng Xue*, Peixun Zhang

*Department of Orthopedics and Trauma, Peking University People's Hospital, Beijing, China. *Co-first authors.*

Received December 10, 2014; Accepted December 18, 2014; Epub January 15, 2015; Published January 30, 2015

Abstract: Metaphysis cancellous bone fracture is one of the most common fracture types in clinical orthopedic practice. The specialized healing process of cancellous bone fracture has long been ignored by the academic society. Comparing with diaphyseal cortical bone healing, cancellous bone healing showed less bone tissue necrosis, barely any hematoma formation, limited inflammation events and no external callus formation. Based on our clinical practice and preliminary study, we hypothesize that the healing process of metaphysis cancellous fracture is a distinct process which could be concluded into five overlapping stages with distinguished histological features of each other. Different from the traditional theory defining diaphyseal cortical fracture, our novel staging theory is specialized in cancellous bone tissue fully considering its unique histological features. This novel staging system may help clinical orthopedists gain specialized understanding concerning cancellous healing process and aid in their clinical evaluation and treatment to metaphysis cancellous bone fracture.

Keywords: Metaphysis cancellous, bone healing, fracture, stage

Introduction

Cancellous fracture is a major cause of extremities fractures [1-4]. Clinically, fractures in cancellous bone heal in a much more rapid fashion and have several unique features comparing with diaphyseal fractures. For examples, distal radial fracture and lateral malleolus fracture will heal directly without callus formation under the conditions of anatomical reduction and rigid internal fixation. Some authors refer to this pattern of fracture healing as "primary healing". Although numerous studies using various animal models have been performed on fracture healing and treatment, most of them address the diaphyseal cortical fracture of long bones [5]. Healing processes of cancellous fractures have not been well investigated. The healing of diaphyseal fractures is a complex multistep process. One important fact is the presence periosteum, where intramembranous and endochondral ossifications combine to complete the healing process [6, 7]. Trabecular bone fractures heal through a different process than most diaphyseal fractures [4]. Charnley

and Baker observed that the woven bone trabeculae soon increased in thickness by surface deposition of new bone matrix [8]. Moreover, Uthoff and Rahn showed similar findings in various animal models (rats, rabbits and dogs) when they stabilized the metaphyseal fractures. As long as the fractures healing weren't disturbed, trabeculae throughout the region were lined with osteoblasts, cartilage was not formed internally and no periosteal callus was observed [9, 10]. Intrigued by these findings, we turn to focus on pursuing of the healing process of cancellous fracture. Distinguished from traditional theory of diaphyseal cortical fracture healing, here in this paper we propose a novel staging system of cancellous fracture healing.

Hypotheses

Based on our preliminary findings and clinical experience, we hypothesize that healing process of metaphysis cancellous fracture is unique from the traditional theory defining diaphyseal fracture. It could be concluded into a five overlapping stage process with distin-

Specific staging system for the unique healing pattern of cancellous fracture

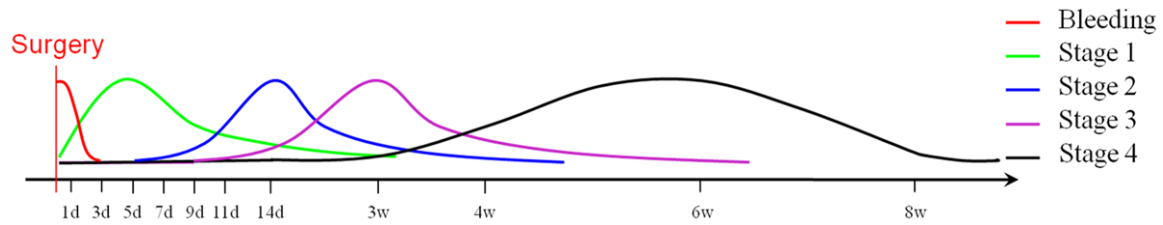


Figure 1. The stages of extremities fracture healing process.

guished histological landmarks of each other. They are bleeding stage, cell proliferation stage, woven bone formation stage, lamellar bone formation stage and bone remodeling stage. This novel staging system may guide the orthopedists in clinical practice with more specialized apprehension and treatment to metaphysis cancellous bone fracture.

Evaluation of the hypothesis

Function of bone remodeling compartment in cancellous bone remodeling

Many complex network of interrelated regulatory systems such as systemic hormones, nerve signals, and local factors are involved in the mechanism controlling the bone resorption-formation coupling process [11-20]. However, how this diversity of signals are integrated and transduced into well-coordinated osteoclast and osteoblast responses is still unclear. Recent studies found an anatomical structure so-called bone remodeling compartment (BRC) where this integration occurs [21, 22]. As illustrated by 3D evaluation, BRCs are structures formed by a canopy of flattened osteoblast-like cells which cover remodeling areas, thereby separating osteoclasts and osteoblasts from the bone marrow cavity [21]. Moreover, these BRC canopies are adjacent to capillaries. As a result, it allows a fast access of systemic regulators and enabling guidance of osteoclast and osteoblast progenitors to critical points of the bone surface [22]. Jensen reported that BRC canopy loss before initiation of bone formation coincided with significantly less bone-forming surface compared with canopy loss at a later stage. This finding show that BRC canopy are an indispensable structure of cancellous bone remodeling [23].

Skeptical relationship between cancellous bone remodeling and fracture

The finding of BRCs gave us an unique chance to look into the relationship between cancel-

lous bone remodeling and fracture processes. The most obvious feature in common is that both processes need the participant and coordination of osteoclasts and osteoblasts. As found in the cancellous bone remodeling process, we postulate that, in a pathological process like cancellous fracture, the healing of the fracture also need osteoclasts and osteoblasts gathering, preexisted bone-like tissue deposit and followed by bone remodeling.

Our novel staging theory of cancellous bone heal

Although numerous previous studies investigated diaphyseal cortical fracture healing, the processes of cancellous fracture healing have long been ignored [5, 24]. Majority of clinicians presume the cancellous fracture healing follows the same pathological processes of diaphyseal cortical fracture which is consist of hematoma stage, inflammation stage, callus formation stage and bone remodeling stage. However, cancellous bone tissue exhibit distinct morphological and histological structures all of which render advantages to its healing process. Comparing with cortical fracture, cancellous fractures possess much larger internal contact surface area which enable sufficient fixation. Moreover, cancellous bone tissues have more abundant blood supply system than cortical bones [25]. Furthermore, cancellous bone tissue is substantially immersed in bone marrow cells. Thus, cancellous fracture may enjoy closer proximity with the abundant source of mesenchymal stem cell that is able to differentiate into osteoclast-osteoblast cell line to promote cancellous bone healing [6]. In our preliminary animal study we found that, comparing with cortical bone healing, cancellous bone healing showed less bone tissue necrosis, barely any hematoma formation, limited inflammation events and no external callus formation. Accordingly, we propose a novel staging system specialized for cancellous fracture healing.

Specific staging system for the unique healing pattern of cancellous fracture

Histologically, the whole healing process of cancellous fracture can be divided into five overlapping stages with distinct features separating each apart. The first stage, hematoma stage, which is characterized by limited bleeding event, lies in the first three days. The second stage, cell proliferation stage, is characterized by mesenchymal-like cell activation and differentiation from immediately after surgery to 3 weeks. The third stage, woven bone formation stage, is characterized by the formation of woven bone or new trabeculae from 5 days to 4 weeks. The fourth stage, lamellar bone formation stage, is characterized by the transformation of newly formed woven bone to lamellar structure from 9 days to 6 weeks. The final stage, bone remodeling stage, is initiated from 2 weeks and reaches its peak at 6 weeks (Figure 1). At the end of the fifth stage the structure of fracture site shows no obvious difference with the normal structure.

Conclusion

In summary, considering the unique characteristics of cancellous bone tissue, we demonstrated that cancellous fracture healing may follow a specialized five stage process rather than another version of diaphyseal cortical fracture healing. This novel staging system may act as guidance to the orthopedists in clinical practice with more specialized apprehension and treatment to metaphysis cancellous bone fracture.

Acknowledgements

This work was funded by Chinese National Ministry of Science and Technology 973 Project Planning (No. 2014CB542200); The ministry of education innovation team (IRT1201); the National Natural Science Fund (No. 31271284, 31171150, 81171146, 30971526, 31100860, 31040043, 31471144, 31371210 and 8137-2044), and the Educational Ministry New Century Excellent Talents Support Project (No. BMU20110270). The Beijing Natural Science Foundation (7142164).

Disclosure of conflict of interest

None.

Address correspondence to: Peixun Zhang, Department of Orthopedics and Trauma, Peking University People's Hospital, Beijing, China. E-mail: zhangpeixun@bjmu.edu.cn

References

- [1] Armocida F, Barfield WR, Hartsock LA. Conventional plate fixation of periarticular fractures. *J Surg Orthop Adv* 2009; 18: 163-9.
- [2] Lerner A, Stein H, Hybrid thin wire external fixation: an effective, minimally invasive, modular surgical tool for the stabilization of periarticular fractures. *Orthopedics* 2004; 27: 59-62.
- [3] Carr JB. Surgical techniques useful in the treatment of complex periarticular fractures of the lower extremity. *Orthop Clin North Am* 1994; 25: 613-24.
- [4] Lis Mosekilde, ENE, Tornvig L, Thomsen JS. Trabecular bone structure and strength-remodelling and repair. *J Musculoskel Neuron Interact* 2000; 1: 25-30.
- [5] Nunamaker DM. Experimental models of fracture repair. *Clin Orthop Relat Res* 1998; Suppl 355: S56-65.
- [6] Shapiro F. Bone development and its relation to fracture repair. The role of mesenchymal osteoblasts and surface osteoblasts. *Eur Cell Mater* 2008; 15: 53-76.
- [7] Rabie AB, Dan Z, Samman N. Ultrastructural identification of cells involved in the healing of intramembranous and endochondral bones. *Int J Oral Maxillofac Surg* 1996; 25: 383-8.
- [8] Charnley J, Baker SL. Compression arthrodesis of the knee: A clinical and histological study. *J Bone Joint Surg* 1952; 34: 187-99.
- [9] Jarry L, Uthoff HK. Differences in healing of metaphyseal and diaphyseal fractures. *Can J Surg* 1971; 14: 127-35.
- [10] Uthoff HK, Rahn BA. Healing patterns of metaphyseal fractures. *Clin Orthop Relat Res* 1981; 160: 295-303.
- [11] Arnett TR. Acidosis, hypoxia and bone. *Arch Biochem Biophys* 2010; 503: 103-9.
- [12] Bonewald LF. The amazing osteocyte. *J Bone Miner Res* 2011; 26: 229-38.
- [13] Brandi ML, Collin-Osdoby P. Vascular biology and the skeleton. *J Bone Miner Res* 2006; 21: 183-92.
- [14] Elefteriou F. Regulation of bone remodeling by the central and peripheral nervous system. *Arch Biochem Biophys* 2008; 473: 231-6.
- [15] Karsdal MA, Martin TJ, Bollerslev J, Christiansen C, Henriksen K. Are nonresorbing osteoclasts sources of bone anabolic activity? *J Bone Miner Res* 2007; 22: 487-94.
- [16] Kaunitz JD, Yamaguchi DT. TNAP, TrAP, ectopurinergeric signaling, and bone remodeling. *J Cell Biol* 2008; 105: 655-62.
- [17] Matsuo K, Irie N. Osteoclast-osteoblast communication. *Arch Biochem Biophys* 2008; 473: 201-9.
- [18] Pederson L, Ruan M, Westendorf JJ, Khosla S, Ousler MJ. Regulation of bone formation by osteoclasts involves Wnt/BMP signaling and the

Specific staging system for the unique healing pattern of cancellous fracture

- chemokine sphingosine-1-phosphate. *Proc Natl Acad Sci U S A* 2008; 105: 20764-9.
- [19] Tang Y, Wu XW, Lei WQ, Pang LJ, Wan C, Shi ZQ, Zhao L, Nagy TR, Peng XY, Hu JB, Feng X, Van Hul W, Wan M, Cao X. TGF-beta 1- induced migration of bone mesenchymal stem cells couples bone resorption with formation. *Nat Med* 2009; 15: 757-66.
- [20] Wauquier F, Leotoing L, Coxam V, Guicheux J, Wittrant Y. Oxidative stress in bone remodeling and disease. *Trends Mol Med* 2009; 15: 468-77.
- [21] Andersen TL, Sondergaard TE, Skorzynska KE, Dagnaes-Hansen F, Plesner TL, Hauge EM, Plesner T, Delaisse JM. A physical mechanism for coupling bone resorption and formation in adult human bone. *Am J Pathol* 2009; 174: 239-47.
- [22] Hauge EM, Qvesel D, Eriksen EF, Mosekilde L, Melsen F. Cancellous bone remodeling occurs in specialized compartments lined by cells expressing osteoblastic markers. *J Bone Miner Res* 2001; 16: 1575-82.
- [23] Jensen PR, Andersen TL, S e K, Hauge EM, Bollerslev J, Amling M, Barvencik F, Delaisse JM. Premature loss of bone remodeling compartment canopies is associated with deficient bone formation:a study of healthy individuals and patients with Cushing's syndrome. *J Bone Miner Res* 2012; 27: 770-80.
- [24] Phillips AM. Overview of the fracture healing cascade. *Injury* 2005; 36 Suppl 3: S5-7.
- [25] Buckwalter JA, Cooper RR. Bone structure and function. *Instr Course Lect* 1987; 36: 27-48.