

## Original Article

# Operative strategy and clinical outcomes of ROI-C™ fusion device in the treatment of Hangman's fracture

Guijun Cao<sup>1,2</sup>, Chunyang Meng<sup>2</sup>, Weihong Zhang<sup>2</sup>, Xiangqing Kong<sup>2</sup>

<sup>1</sup>Qingdao University, Qingdao 266000, China; <sup>2</sup>Department of Spine Surgery, The Affiliated Hospital of Jining Medical University, Jining 272000, China

Received June 2, 2015; Accepted September 18, 2015; Epub October 15, 2015; Published October 30, 2015

**Abstract:** Objective: to compare the clinical outcomes of anterior fusion with ROI-C™ and titanium plate in the treatment of Hangman's fractures. Methods: From Dec 2005 to Jan 2015, a total of 21 patients with Hangman's fracture, who underwent anterior internal fixation with titanium plate or ROI-C™, were retrospectively reviewed. All patients underwent anteroposterior, lateral, and flexion-extension radiography and computed tomography of cervical spine preoperatively and postoperatively at 3 days and 3 months. Cervical visual analog scale (VAS) score, Bazaz dysphagia score, angular displacement (AD), horizontal displacement (HD), fusion rate, and blood loss were measured. Results: The VAS and Bazaz dysphagia score at postoperative 3 days were significantly lower in ROI-C™ group, as compared to titanium plate group ( $P < 0.05$ ). AD and HD were significantly decreased in both groups after operation ( $P < 0.05$ ). The postoperative rate of complete reduction of spondylolisthesis was significantly higher in ROI-C™ group than that in titanium plate group ( $P < 0.05$ ). The operative time and blood loss was significantly decreased in ROI-C™ group, as compared to titanium plate group ( $P < 0.05$ ). Conclusion: ROI-C™ device showed superiority to titanium plate in the treatment of Hangman's fractures, suggesting that anterior operation with ROI-C™ device may be a better choice for treating Hangman's fractures.

**Keywords:** Hangman's fracture, cervical fusion cage, internal fixation, fusion rate

## Introduction

Hangman's fracture, also known as traumatic spondylolisthesis of axis, is a fracture involves injury of pedicle, articular facet, and pars interarticularis of the axis [1-3] and is frequently accompanied by C2-C3 intervertebral fracture. In 1982, Levine and Edwards classified Hangman's fracture into four types [4]. Conservative methods, such as cervical orthosis, halo-vest immobilization and skull traction, are favored for the treatment of Hangman's fracture. However, poor fixation and slow healing rate greatly affect the quality of patients' lives. Even if the fracture heals well, the cervical instability induced by cervical disc damage still exists and patients may have C2/3 kyphosis or false articuli, and pain in neck, shoulders and arms in the late period.

With the development of anterior cervical plate and posterior pedicle screws, surgical treatment with reduction internal fixation shows

superiority for unstable Hangman's fracture. Surgical methods commonly used in the treatment of Hangman's fracture mainly include C2/3 anterior approach with titanium plates and posterior approach with pedicle screws. Anterior approach has several advantages, such as easy operation, less injury, satisfactory stability, and conducting discectomy and spinal decompression at the same time. These advantages make anterior approach the first choice for the treatment of Hangman's fracture to most spine surgeons. However, this approach is often associated with poor exposure, difficult internal implantation and fixation, and high frequency of complications [5]. Posterior screw fixation is favored for treating III fracture, which provides good exposure and can treat articular facet noose meanwhile. But some patients may still have to conduct anterior decompression to solve the problems such as disc relict and compression of the cervical spine cord after reduction [2, 3]. To decrease the effects of thick titanium plate on the esophagus and pharynx, low

## ROI-C™ fusion device for Hangman's fracture treatment

profile or zero notch internal fixation materials are constantly emerging. ROI-C™ device has double locking tabs that can lock the upper and lower vertebral body at a time, avoiding displacement of the fusion device. The usage of double locking tabs provides good immediate stability, thereby resulting in improved intervertebral space and cervical physiological curvature and higher fusion rate [6-8].

Currently, ROI-C™ device has been widely used in the treatment of disorders of subaxial cervical spine and cervical spine fractures; however, its application in the treatment of Hangman's fractures has not been reported. In the present study, we retrospectively compared the effects of ROI-C™ device and titanium plate on postoperative immediate stability and clinical outcomes in the treatment of Hangman's fractures.

### Subjects and methods

#### *Design*

Retrospective clinical study.

#### *Subjects*

Between December 2005 and January 2015, 21 patients with Hangman's fractures were included in this study. 15 patients were treated with anterior fixation with titanium plates and 6 patients were treated with anterior fixation with ROI-C™ devices.

#### *Diagnostic criteria*

(1) Typical neck trauma history and clinical symptoms, such as neck pain, stiffness, and limited mobility. Some patients may also have concomitant injury of the neck or other parts. (2) X-ray films and CT of cervical spine showing: type II with translation (>3 mm) and kyphosis after C2-C3 angulation; type IIa with translation (<3 mm) and C2-C3 angulation (>15°); type III with severe translation, angulation, and facet noose. MR shows spinal cord or nerve compression, and T1 and T2 image signal may be changed.

#### *Inclusion criteria*

Patients with Type II and IIa Hangman's fractures classified by Levine and Edwards.

#### *Exclusion criteria*

(1) type I Hangman's fracture; (2) developmental spinal stenosis and severe ossification of posterior longitudinal ligament; (3) severe heart failure, respiratory failure, renal failure, and metal allergies surgical contraindications; (4) severe swallowing discomfort before operation; (5) type III Hangman's fracture.

#### *Basic information*

All the cases were retrospectively analyzed. According to the types of fusion devices, patients were divided into two groups, the ROI-C™ group and the titanium plate group. There were 13 males and 8 females. Mean age at surgery was 43.2±13.9 years (range 25-62 years). Patients and their families were informed and consent for the treatment. The cause of injury: fall injury 4 cases, traffic accident 15 cases, heavy injured 2 cases. Classification by Levine-Edwards: type II 15 cases, type IIa 6 cases. Most of the patients were complicated with varying degrees of neurological symptoms. Classification of spinal cord function (Frankel): C grade 1 case, D grade 8 cases, E grade 12 cases.

#### *Methods*

#### *Materials*

ROI-C™ fusion device was obtained from LDR (France), with 5 mm, 6 mm or 7 mm in height and 12 mm or 14 mm in length. Titanium plate was from Cervilock Anterior Cervical Plate System (Weigao, China).

#### *Surgical procedures*

*Titanium plate group:* All patients were conducted inhalation anesthesia mediated by endotracheal intubation. Patients were placed in a supine position, avoiding hyperextension. After anesthesia, patient's shoulders and back were padded and the neck was slightly extended. Axial reduction was observed under fluoroscopy. A standard horizontal incision was made 2 cm below the jaw. Hypoglossal nerve was elevated used a long thyroid retractor and the carotid artery was held to the lateral. The hyoid bone was retracted medially without harming the deep laryngeal nerve. After exposure of pharyngeal space and prevertebral fascia,

## ROI-C™ fusion device for Hangman's fracture treatment

**Table 1.** Comparison of baseline characteristics in patients of two groups

Items	ROI-C™ group	Titanium plate group	P value
M/F(n)	5/1	12/3	>0.05
Age ( $\bar{X} \pm s$ , years)	41.2±12.7	45.9±13.6	>0.05
Levine-Edwards classification			>0.05
Type II	4	11	
Type IIa	2	4	

Note: There were no significant difference in gender, age, Hangman's fracture type between ROI-C™ group and titanium plate group preoperatively.

C2/3 anterior exposure was obtained. Anterior C2/3 discectomy and decompression were performed with the help of an intervertebral expander. After endplate treatment, cage filled with comminuted bone was impacted into the prepared disc space. Anterior titanium plate with appropriate length was curved and placed in the C2, C3 vertebral bodies. Final alignment was achieved by tightening the screws. After confirming the positions of titanium plate, screws, and cage, and the satisfactory C2, C3 vertebral reduction, a drainage tube was placed and the surgical incision was sutured.

*ROI-C™ group:* Anesthesia and surgical operation were performed as the titanium plate group. After anterior C2/3 discectomy, decompression, and removal of intervertebral expander, depth limiting screw was adjusted according to the degree of spondylolisthesis to achieve satisfactory vertebral reduction. Then an appropriate type of ROI-C™ fusion device was chosen, filled with comminuted bone, and impacted into the intervertebral space. While the surgical assistant holding the skull and pushing down the trailing, locking tabs of ROI-C™ were fixed to C2, C3 vertebrae. After confirming the vertebral reduction and fixation, a drainage tube was placed and the surgical incision was sutured.

### Postoperative treatment

At 1 day postoperatively, patients without severe cervical cord and neural lesions could have out-of-bed activities while wearing a neck brace, but the brace would be not necessary while lying down. Drainage tube was removed when the drainage was less than 50 ml within 24 h. Radiographs were taken at 3 day postoperatively. Cervical support with neck brace was used for 3 months. All patients were rechecked at 3 months postoperatively.

### *Statistical analysis*

#### Non-radiographic indexes

Operative time and blood loss were measured. Bazaz dysphagia was classified into mild, moderate and severe degree. Visual analogue scale (VAS) score was used to evaluate the neck pain.

#### Radiographic indexes

Cervical anteroposterior, lateral, and flexion-extension radiography and computed tomography (CT) were performed preoperatively and postoperatively at 3 days and 3 months. Angular displacement (AD) and horizontal displacement (HD) were also measured. Fusion criteria: (1) Bone trabecula goes through bilateral interfaces and bone bridge is formed between the upper and lower edges of the vertebral body. (2) Space between vertebral body and fusion device is disappeared. (3)  $AD \leq 2^\circ$  at heperflexion or heperextension state. (4) Having enough intervertebral height and there is no collapse and scoliosis [9].

### Statistical analysis

Statistical analyses were performed using SPSS 16.0. Data was expressed as  $\bar{X} \pm S$ . Pair comparison was performed using T-test. Bazaz dysphagia was analyzed with rank sum test. Fusion rate was analyzed with Chi-square test. P value <0.05 was considered to be statistically significant.

## Results

### *Comparison of baseline characteristics*

There were no significant difference in gender, age, Hangman's fracture type between ROI-C™ group and titanium plate group preoperatively ( $P > 0.05$ ) (Table 1).

### *Comparison of non-radiographic indexes*

The cervical VAS score, Bazaz dysphagia score were significantly decreased at postoperative 3 days in ROI-C™ group, as compared to titanium plate group ( $P < 0.05$ ); however, at postoperative 3 months, there was no significant difference in the cervical VAS score and Bazaz dysphagia score between the two groups ( $P > 0.05$ ). The operative time and blood loss was significantly lower in ROI-C™ group ( $62.3 \pm 18.7$  min

## ROI-C™ fusion device for Hangman's fracture treatment

**Table 2.** Comparison of non-radiographic indexes in patients of two groups

Items	ROI-C™ group (n=6)	Titanium plate group (n=15)	P value
Operative time ( $\bar{X} \pm s$ , min)	62.3±18.7	125.4±31.4	<0.05
Blood loss ( $\bar{X} \pm s$ , ml)	39.6±17.7	69.8±23.9	<0.05
Dysphagia classification (3 days after operation)			<0.05
Mild	0	5	
Moderate	0	2	
Severe	0	0	
Dysphagia classification (3 months after operation)			>0.05
Mild	0	2	
Moderate	0	0	
Severe	0	0	
VAS score ( $\bar{X} \pm s$ ) (3 days after operation)	2.5±0.4	3.9±0.9	<0.05
VAS score ( $\bar{X} \pm s$ ) (3 months after operation)	0	0	>0.05

Note: There were significant differences in the operative time, blood loss, Bazaz dysphagia score and VAS score at 3 days postoperatively between the two groups (P<0.05). There was no significant difference in Bazaz dysphagia score and VAS score at 3 months postoperatively between the two groups (P>0.05).

**Table 3.** Comparison of radiographic indexes in patients of two groups

Groups	AD (mm)	HD (mm)	Fusion rate (%)	Complete reduction rate (%)
ROI-C™ group (n=6)				100
Before operation	21.7±4.6	4.2±1.4		
3 days after operation	2.2±0.4	0.9±0.3		
3 months after operation	0.4±0.1	0.0±0.0	83.3%	
Titanium plate group (n=15)				46.6
Before operation	20.8±5.3	4.7±1.6		
3 days after operation	2.1±0.5 <sup>a</sup>	0.3±0.0 <sup>a</sup>		
3 months after operation	0.3±0.0 <sup>a</sup>	0.0±0.0 <sup>a</sup>	80.0%	

Note: Angular displacement (AD) and horizontal displacement (HD) at 3 day and 3 months postoperatively were significantly decreased, as compared to preoperation (P<0.05); however, there was no significant difference between the two groups (P>0.05). No significant difference in fusion rate at 3 day postoperatively was found between ROI-C™ group (83.3%) and titanium plate group (80.0%), (P>0.05). The rates of complete reduction of spondylolisthesis after operation in ROI-C™ group (100%) was significantly higher than that in titanium plate group (46.6%), (P<0.05). <sup>a</sup>Represents the statistically significant difference of AD and HD at 3 day and 3 months postoperatively as compared to preoperation.

and 39.6±17.7 ml), as compared to titanium plate group (125.4±31.4 min and 69.8 ml±23.9 ml) (P<0.05) (**Table 2**).

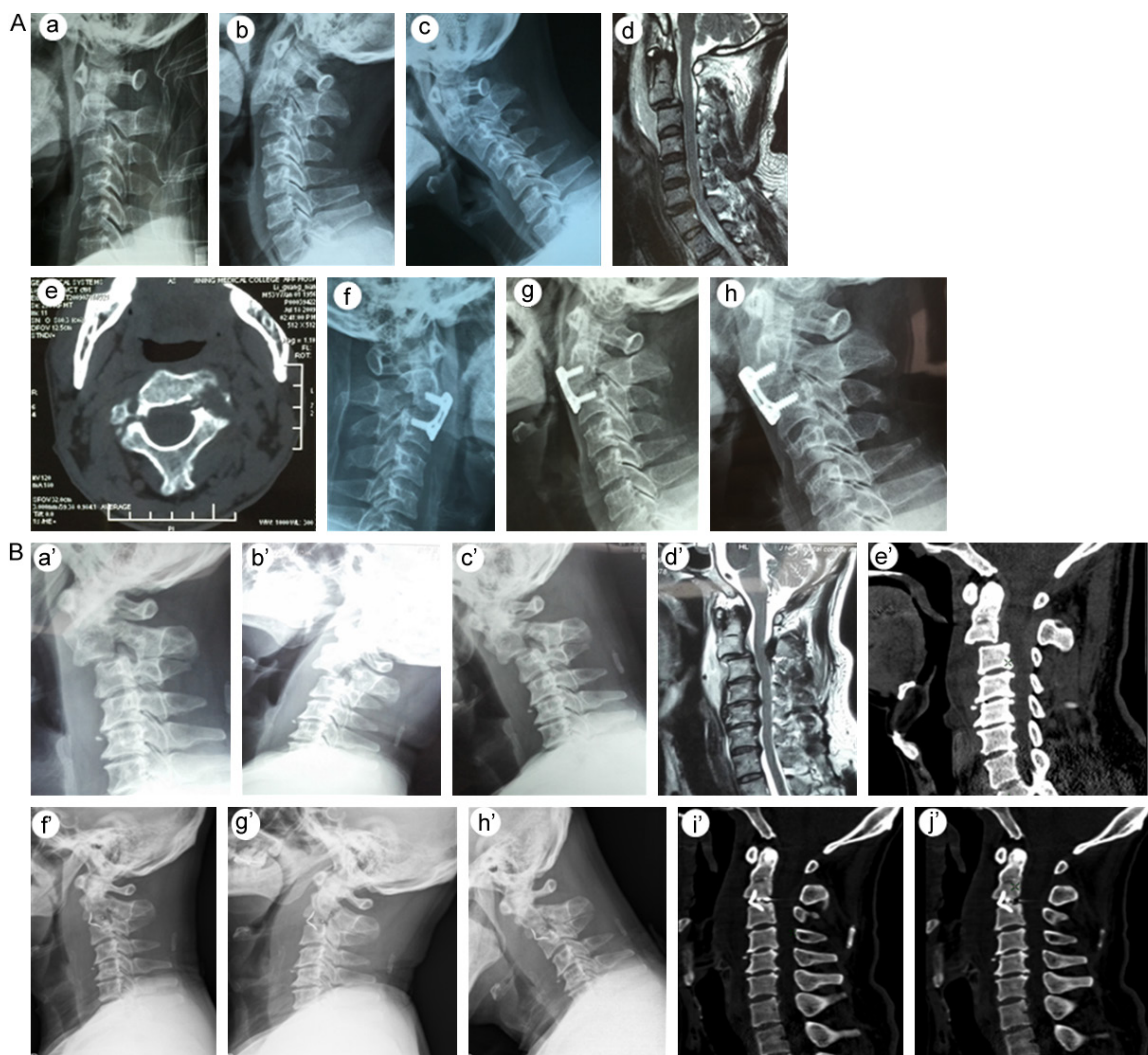
### Comparison of radiographic indexes

AD and HD at postoperative 3 days and 3 months in both groups were significantly decreased after operation (P<0.05), but there was no difference in AD and HD at postoperative 3 days and 3 months between the two groups. No significant difference was observed in the fusion rate 3 months postoperatively between the two groups (P>0.05). The rate of complete reduction of spondylolisthesis after operation in ROI-C™ group (100%) was significantly

higher than that in titanium plate group (46.6%), (P<0.05) (**Table 3**).

### Typical case

A 49-year-old male (\*\*Jiang), who was involved in a car accident, had neck pain and limited mobility for 2 days. Upon examination, his neck movements were restricted, and his muscle power of left upper limb was grade 4. His superficial sensibility was lost, but his muscle power of right limb was normal. Hoffmann sign -, knee tendon reflexes ++. Auxiliary examination: X-ray showed vertebral displacement forward 6 mm, and there was a clear C2 pars interarticularis fracture (**Figure 1A**). Flexion-extension radio-

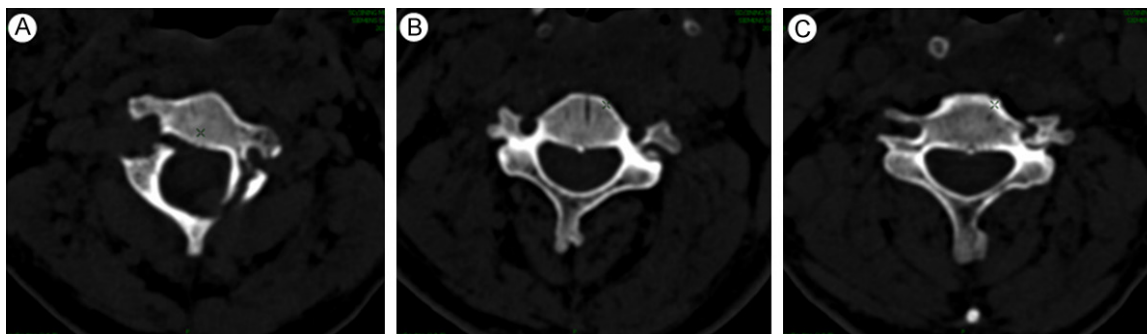


**Figure 1.** Images of a patient with Hangman's fractures before and after treatment. (A) Images of a patient with Hangman's fractures before and after treatment with Titanium plate. Cervical vertebra lateral radiograph (a), heperextension radiograph (b), heperflexion radiograph (c), MR (d) and CT (e) before operation. Cervical vertebra lateral radiograph 2 weeks postoperatively (f), cervical vertebra lateral radiograph 3 months postoperatively (g), cervical vertebra lateral radiograph 6 months postoperatively (h). (B) Images of a patient with Hangman's fractures before and after treatment with ROI-C™ device Cervical vertebra lateral radiograph (a'), heperextension radiograph (b'), heperflexion radiograph (c'), MR (d') and CT (e') before operation. Cervical vertebra lateral radiograph (f'), heperextension radiograph (g'), heperflexion radiograph (h'), and CT (i', j') 3 days postoperatively.

graph showed unstable C2/3 segment (**Figure 1b'** and **1c'**). Cervical MR showed that C2 dislocated forward, but had no sign of cerviculp and radiculopathy symptom. Diagnosis: type II Hangman's fracture. This patient was performed anterior cervical discectomy and internal fixation with ROI-C™ device. The operative time and blood loss were 60 min and 20 ml, respectively. Patient underwent lateral (**Figure 1f'**) and flexion-extension (**Figure 1h'**) radiography and CT at 3 days postoperatively. CT scan showed a complete fusion at 3 months postoperatively (**Figure 1i'**).

### Discussion

Axis fracture, as known as traumatic spondylolisthesis of the axis, accounts for 4%-7% of all cervical fractures, and its incidence is significantly increased attributed to elevated car accidents and aloft works. Axis is a transitional vertebra between the upper and lower cervical spines. Anatomical differences between the superior and inferior articular process makes pars interarticularis of axis a mechanical lever, which is the stress concentration point of two segments of cervical spine and has both roles



**Figure 2.** Comparison of C2, C3 and C4 curvature. A. The curvature of C2 vertebral frontal edge. B. The curvature of C3 vertebral frontal edge. C. The curvature of C4 vertebral frontal edge.

of pedicle and isthmus. However, because of its anatomical and biomechanical characteristics, the pars interarticularis is prone to fracture when the neck is subjected to external force [1, 10].

According to the mechanisms and fracture characteristics, Levine-Edwards classified Hangman's fracture into four types, type I, II, IIa and III [11]. Type II is often accompanied by compression fractures of anterior vertebral body edge and shows significant displacement (>3 mm) and slight angulation. Type IIa is a variant of type II caused by flexion and traction violence. Type IIa is unstable and shows severe angulation and slight displacement (<3 mm). In 1980s, Hangman's fracture is mainly treated with conservative methods, but with the improvement of surgery and the emergence of better fixation material, more and more of type II~III, and even part of type I fractures are tend to treated with surgical methods [12, 13]. Surgical treatments include anterior and posterior approach. Anterior approach is mainly used in the treatment of type IIa, type II and part of type III that can be reduced by traction. The biggest advantage of the anterior approach is that it can solve the problems of cervical spine instability and cervical cord compression. However, it still has some disadvantages, including (1) complicated anatomical operation, difficult exposure, and high incidence of laryngeal and hypoglossal nerve damage and complications; (2) unsatisfactory vertebra reduction; (3) fracture malunion due to the indirect fixation; (4) less immediate biomechanical stability compared with posterior approach. Skilled operation and fixation postoperatively can greatly overcome these disadvantages. Thus, it can still be a good choice for the treat-

ment of type II and most of type III (excluding those that are hard to be reduced by traction) [5].

Dysphagia commonly occurs after anterior operation, with an incidence of 3-12% in patients with the lower cervical spine fracture [16-19]. ROI-C™ cage is a zero-notch self-locking cervical interbody cage. Unless there is serious vertebral osteophytosis, dissection of a wide range of soft tissues is not necessary when using this self-locking cage, and this will greatly reduce dysphagia. Wang et al. have reported that 25.9% of patients treated with titanium plate show dysphagia, while only 7.8% of patients treated with intervertebral cages show dysphagia, and those who underwent cervical fusion procedures without intervertebral cages or cervical artificial discs, do not have dysphagia. Their findings suggest that dysphagia is associated with the implants [20]. Qi et al. also showed that the incidence of dysphagia was significantly higher in plate plus cage group (41.53%) than that in Zero-p cage group (33.33%), suggesting that the choice of implants and the surgical margin significantly influences the postoperative dysphagia [21]. Zhang et al. compared the effects on clinical efficacy by anterior cervical decompression and internal fixation using self-locking interbody fusion MC+® or ROI-C™ in the treatment of cervical spondylosis and they found that at 3 days or 3 months postoperatively, AD and HD were significantly higher in MC+® group than that in ROI-C™ group, suggesting that ROI-C™ has superiority to MC+® for stability [6]. In this study, we found that in ROI-C™ group, none had dysphagia, while in titanium plate group, 46.6% of patients had dysphagia. Cervical VAS score was significantly lower in ROI-C™ group than

that in titanium plate group. The decreased dysphagia and cervical pain in ROI-C™ group may be attributed to zero-profile of ROI-C™, shorter operative time, and smaller range of soft tissue dissection, which can greatly reduce the traction and irritation of the throat.

Atlantoaxial frontal curvature analysis showed that the frontal edge of C2>C3>C4 (**Figure 2**). Due to the axial frontal curvature difference, titanium plate cannot patch to the vertebral body perfectly, and its thickness has a high irritation to the pharyngeal soft tissues. The appearance of zero-notch ROI-C™ greatly improves the problems raised by titanium plate. First, ROI-C™ was implanted into the intervertebral space directly and then the locking tabs are implanted to lock the upper and lower vertebrae; thus, axial frontal curvature is no more an issue. Second, spondylolisthesis reduction was achieved by directly adjustment of the depth adjusting lever. Furthermore, due to small range of vertical and horizontal tissue dissection less blood loss was achieved.

Coming to C2 pedicle fracture or C2 at a floating state, ROI-C™ implantation and fixation has to be conducted with the help of an intervertebral expander. However, when performing C2/3 cage implantation, an expander is not recommended. The reasons for this suggestion include: (1) Because of cervical extension curvature, the expander will firstly reach the end of C3 vertebral nail but not the end of C2 vertebral nail, and thus cannot reduce the C2 vertebra. (2) The expander influences the adjustment of depth adjusting lever, leading to unavailable compression reduction. (3) Due to insufficient exposure, vertebral screws are hard to be implanted in the lower edge of vertebral body (>5 mm), and screw implantation further obstructs the implantation of locking tabs [6, 22]. How to achieve good reduction and fixation without an expander? Following is our experience. First, we adjust the depth adjusting lever to conduct compression reduction. Then the assistant gives skull downgrade support, which can provide satisfactory reduction and solves the problem of intervertebral space compression. In the present study, we found that the rate of complete reduction of spondylolisthesis after operation was significantly higher in ROI-C™ group than that in titanium plate group. Moreover, the operative time and blood loss were significantly less in ROI-C™ group than

those in titanium plate group. These data suggest that ROI-C™ has superiority in vertebral reduction, operative time, blood loss and dysphagia.

In summary, ROI-C™ device shows advantages in the treatment of Hangman's fractures, such as achieving satisfactory postoperative immediate stability, having less neck pain, dysphagia and blood loss, and easy operation. Furthermore, ROI-C™ demonstrates superiority to titanium plate for both implantation and complete reduction of spondylolisthesis. Together, our data suggest that anterior operation with ROI-C™ device can be a better choice for the treatment of Hangman's fractures.

### Disclosure of conflict of interest

None.

**Address correspondence to:** Chunyang Meng, Department of Spine Surgery, The Affiliated Hospital of Jining Medical College, Guhuai Road 79, Jining 272000, Shandong Province, China. Tel: +860537-2903236; Fax: +860537-2903236; E-mail: mengchunyang@163.com

### References

- [1] Zavanone M, Guerra P, Rampini P, Crotti F and Vaccari U. Traumatic fractures of the craniovertebral junction. Management of 23 cases. *Eurosurg Sci* 1991; 35: 17-22.
- [2] Chaudhary SB, Martinez M, Shah NP and Vives MJ. Traumatic atlantoaxial dislocation with Hangman fracture. *Spine J* 2015; 1: 1529-9430.
- [3] Jeong DH, You NK, Lee CK, Cho KH and Kim SH. Posterior C2-C3 fixation for unstable Hangman's fracture. *Korean Spine J* 2013; 10: 165-169.
- [4] Effendi B, Roy D, Cornish B, Dussault RG and Laurin CA. Fractures of the ring of the axis. A classification based on the analysis of 131 cases. *J Bone Joint Surg Br* 1981; 63-B: 319-27.
- [5] Li Z, Li F, Hou S, Zhao Y, Mao N, Hou T and Tang J. Anterior discectomy/corpectomy and fusion with internal fixation for the treatment of unstable hangman's fractures: a retrospective study of 38 cases. *J Neurosurg Spine* 2015; 22: 387-93.
- [6] Zhang W, Yuan S, Meng C, Gao F and Yuan W. MC+® and ROI-CTM cervical fusion cage for cervical spondylosis: comparison of early post-operative cervical stability and fusion rate. *Chinese Journal of Tissue Engineering Research* 2014; 18: 4973-4979.

## ROI-C™ fusion device for Hangman's fracture treatment

- [7] Wang Z, Jiang W, Zhang Z, Wang H, Li X, Shi J, Chen J and Yang H. [Comparison of ROI-C and traditional cage with anterior plating for anterior cervical discectomy and fusion]. *Zhonghua Wai Ke Za Zhi* 2014; 52: 425-430.
- [8] Zhang Z, Jiang W, Li X, Wang H, Shi J, Chen J and Yang H. Bridge Intervertebral fusion lock device (ROI-C) in cervical spondylosis anterior decompression fusion application in clinical research. *Chinese Journal of Spine and Spinal Cord* 2014; 24: 510-516.
- [9] Xu G and Jia L. Imaging evaluation methods and standers in the treatment with anterior decompression discectomy and fusion. *Chinese Journal of Surgery* 2009; 12: 1824-1825.
- [10] Marton E, Billeci D and Carteri A. Therapeutic indications in upper cervical spine instability. Considerations on 58 cases. *Neurosurg Sci* 2000; 44: 192-202.
- [11] Levine AM and Edwards CC. The management of traumatic spondylolisthesis of the axis. *J Bone Joint Surg Am* 1985; 67: 217-226.
- [12] Ma W, Xu R, Sun S, Huang L, Ying J and Jiang WC. Pedicle screw fixation for management of unstable Hangman fractures. *Chinese Journal of Orthopaedics* 2006; 26: 590-593.
- [13] Wang Q, Wang S, Zhong D, Kang J, Wang G and Xiu P. Choice of anterior or posterior approach for unstable Hangman fracture. *Chinese Journal of Spine and Spinal Cord* 2012; 22: 526-530.
- [14] Sun H, Cai X, Zhang J, Liao W, Cai Y, Han J and Dong G. Choice and clinical analysis of treatment for Hangman fracture. *Chinese Journal of Spine and Spinal Cord* 2011; 21: 554-560.
- [15] Chowdhury FH and Haque MR. C1-C3 Lateral Mass Screw-Rod Fixation and Fusion for C2 Pathologies and Hangman's Fractures. *Asian Spine J* 2014; 8: 735-746.
- [16] Yue WM and Brodner W, Highland TR. Persistent swallowing and voice problems after anterior cervical discectomy and fusion. *Eur Spine J* 2005; 14: 677-682.
- [17] Goffin J, Casey A and Kehr P, Kehr P, Liebig K, Lind B, Logroscino C, Pointillart V, Van Calenbergh F, van Loon J. Preliminary clinical experience with the Bryancervical disc prosthesis. *Neurosurg* 2002; 51: 840-847.
- [18] Fountas KN, Kapsalaki EZ, Nikolakakos LG, Smisson HF, Johnston KW, Grigorian AA, Lee GP and Robinson JS. Anterior cervical discectomy and fusion associated complications. *Spine* 2007; 32: 2310-2317.
- [19] Pickett GE, Sekhon LH, Sears WR and Duggal N. Complications with cervical arthroplasty. *Neurosurg Spine* 2006; 4: 98-105.
- [20] Wang X and Wang S. Relative factor analysis of dysphagia after anterior discectomy and fusion. *Chinese Journal of Spine and Spinal Cord* 2006; 12: 913-916.
- [21] Qi M, Liang L, Wang X, Chen H, Cao P and Yuan W. Analysis on the causes of dysphagia after multilevel anterior cervical discectomy and fusion. *Chinese Journal of Orthopaedics* 2013; 33: 467-472.
- [22] Hua J, Liu F and Wang W. Applying ROI interbody fusion cage for anterior cervical intervertebral disc resection arthrodesis treat early cervical degenerative disease. *Zhejiang Zhongyi Yiyao Daxue Xuebao* 2013; 37: 877-880.