

## Case Report

# Piriform sinus carcinoma with a paraneoplastic syndrome misdiagnosed as adult onset Still's disease: a case report

Liu Yang, Wen Li, Jintao Du

*Department of Otolaryngology, Head and Neck Surgery, West China Hospital, Sichuan University, Chengdu 610041, Sichuan, China*

Received July 13, 2015; Accepted October 8, 2015; Epub October 15, 2015; Published October 30, 2015

**Abstract:** Paraneoplastic syndromes (PS) occur less commonly in association with otolaryngologic neoplasms than other carcinomas such as those of lung or breast. Piriform sinus carcinoma with PS is extremely rare. We here report a case of piriform sinus carcinoma accompanied by PS that was initially misdiagnosed as adult onset Still's disease and describe our diagnosis and treatment. One lesson we have drawn from the experience of this misdiagnosis is that PS symptoms may manifest before the primary tumor is evident and complicate the diagnostic process.

**Keywords:** Hypopharyngeal carcinoma, piriform sinus, misdiagnosis, paraneoplastic syndrome, adult onset Still's disease

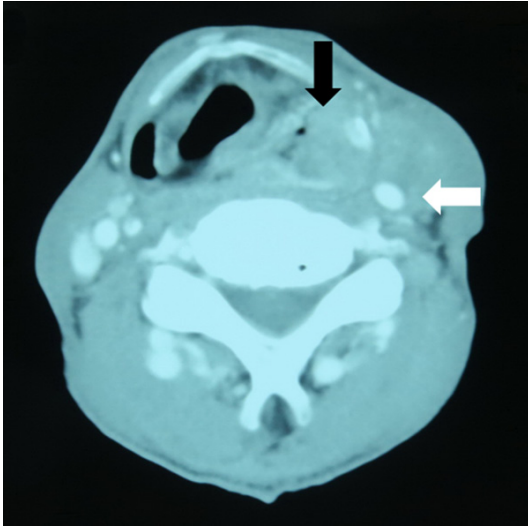
## Introduction

Paraneoplastic syndrome (PS) used to be termed as paraneoplastic neurologic syndrome (PNS), was first named by Guichard in 1956. Along with more and more researches have indicated that PNS is not only concerned with neuroendocrine system, but also related with other systems such as cardiovascular and immune systems, recently, more researchers prefer to the term of PS rather than PNS. PS is defined as a series of symptoms and signs associated with a primary neoplasm, but not directly related to the position, local effects or metastasis of the tumor. The incidence of PS is about 1.0%-7.4%. An association of PS with otolaryngologic neoplasms is not usual, nasopharyngeal carcinoma being the commonest among those head and neck tumors [1-4, 9, 15]. To our knowledge, piriform sinus carcinoma presenting with a paraneoplastic osteoarthicular or rheumatological syndrome as the initial manifestation has not yet been reported in Asia population.

## Case presentation

A 60-year-old Chinese man was referred to the Department of Rheumatism and Immunology

of the West China Hospital in June 2012, complaining progressive pain and weakness in the major joints and muscles of the extremities accompanied by pharyngalgia and prolonged fever for some months. The symmetrical joints disorder manifested first in the shoulders and then extended to the wrists, eventually reached to the knees. The lower limbs were more severely affected than the upper ones. The pain was most intense at night, while the stiffness of the joints was worst in the morning. The above symptoms had rapidly worsened 10 days prior to his admission to our hospital, accompanied by development of an erythematous rash on anterior thoracic wall and forearms. He has smoked 40 cigarettes per day for 40 years and taken 500 g Chinese distillate spirits per day for 30 years. He denied any history of infectious diseases, allergy or surgery. On examination, tenderness and limited range of movement in the major joints of the extremities were noted, accompanied by elevated temperature of the skin around those joints. The floating patella test was positive. His temperature was 38.3°C. Laboratory tests showed increased white blood cell counts (fluctuating in the range of  $15-20 \times 10^9/L$ ), the percentage of polymorphonuclear leucocytes (90.1%), C reactive protein (122



**Figure 1.** Enhanced CT image demonstrating a neoplasm (black arrow) in the left piriform sinus and enlarged lymph nodes (white arrow) with no clear demarcation from the internal carotid artery.

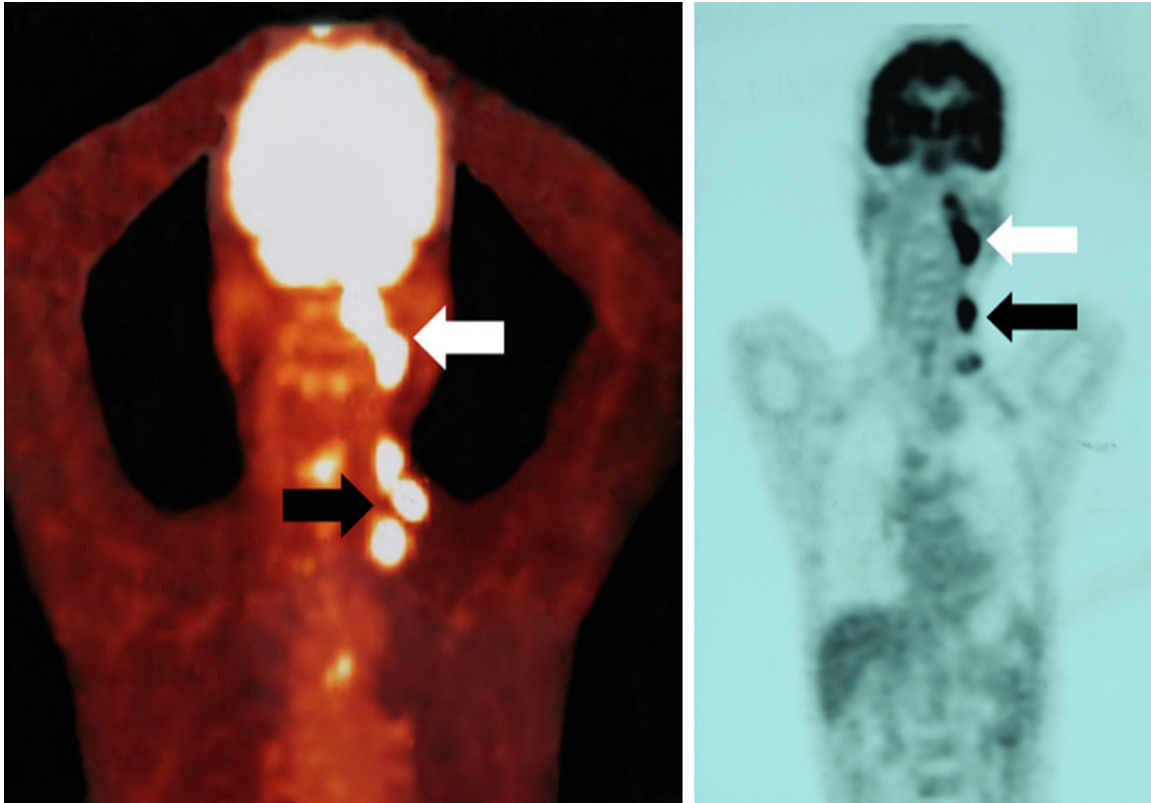
mg/L), erythrocyte sedimentation rate (120 mm/h), and the serum ferritin level (674.4 ng/ml), whereas concentrations of autoimmune antibodies such as antinuclear, extractable nuclear antigen, and double stranded DNA antibodies and rheumatoid factor were normal. Percentage of hypoglycosylated ferritin was 16% and the blood culture result was negative. During the next week he was given antibiotic treatment with no improvement; however, his symptoms improved after methylprednisolone administration, including a return to normal temperature. On the basis of the clinical examination and effects of treatment therapy, he was diagnosed as having adult onset Still's disease (AOSD) and was discharged after a month of routine treatment for this condition.

Three months later, his previous symptoms recurred with greater severity and the erythematous rash extended to the inguinal area. About 10 days before his return to our hospital, he discovered a painless, hard, fixed mass in the left side of his neck. An enhanced computed tomography (CT) scan of the neck revealed a neoplasm in the left piriform sinus and enlarged left-sided lymph nodes without clear demarcation from the internal carotid artery at the level of the hyoid bone and thyroid cartilage (**Figure 1**). Positron emission tomography CT (PETCT) revealed hypermetabolic foci in the left hypopharynx and adjacent and lower cervical lymph

nodes, with possible cervical and thoracic esophageal involvement (**Figure 2**). Laryngofiberscopic examination showed a neoplasm in the left piriform sinus, pathological diagnosis of the biopsied specimen was squamous cell carcinoma. Esophagogastrosocopy showed a rough mucosa where the patient refused to be performed a biopsy. The diagnosis in this case was thus revised to piriform sinus carcinoma with cervical lymph node metastases. The patient would rather receive radiotherapy and chemotherapy than surgery. Five months later, he died of hemorrhagic shock because of carotid artery rupture resulting from tumor erosion.

### Discussion

PS is associated with tumors, but does not directly depend on their sites, local symptoms or metastases [5]. The term of PS generally refers to remote effects associated with tumors. It does not only present in association with malignant tumors, but can also occur with some potentially malignant tumors, such as hypopharyngeal paraganglioma [6]. The pathogenesis of PS involves an autoimmune mechanism, namely, the tumor activates an immune response that generates homologous immune factors (i.e., Hu, Yo, CV2, Ri, Ma2, or amphiphysin), which typically attack target organs that co-express some antigens with the primary tumor [7-9]. The types of tumor that cause PS include squamous cell carcinoma [10], adenocarcinoma [11, 12], lymphoepithelial carcinoma [13, 14], sarcoma, and lymphoma [2]. PS can cause abnormalities in relevant systems, such as the integumentary [3], neuromotor [15], neuropsychiatric system [16, 17], hematological [18], cardiovascular [19, 20], and ocular systems. Osteoarticular or rheumatological changes in the neuromotor system are rare, they are even more rare when associated with otolaryngologic neoplasms. PETCT is a strongly recommended diagnostic method when the tumors are associated with PS [21]. The key to successfully managing PS is early detection and treatment of the primary lesion. Although PS is less commonly associated with otolaryngologic neoplasms than other carcinomas such as lung or breast carcinoma, it does reportedly occur with nasopharyngeal and tonsillar cancers [15, 21]. Cases of laryngeal carcinoma with PS have been reported sporadically, including some in which the manifestations of



**Figure 2.** PETCT image demonstrating hypermetabolic foci in the left hypopharynx (white arrow) and adjacent and lower cervical lymph nodes (black arrow), with possible cervical and thoracic esophageal involvement; however, the PETCT fusion image (left) is not in full accord with the PET image (right).

PS are in the form of osteoarticular or rheumatological syndromes [22]. Hypopharyngeal carcinoma with PS is rare, with fewer than ten cases having been reported [23]. To our knowledge, this is the first case of piriform sinus carcinoma with paraneoplastic osteoarticular or rheumatological syndrome as the initial symptom in an Asian. Only one similar case has been reported in 1999 in Spain [24].

Piriform sinus carcinoma is a type of hypopharyngeal carcinoma with poor prognosis, the cause of which is undetermined. Long-term heavy smoking or drinking, malnutrition, and viral infection have been implicated. Pharyngalgia is the most common manifestation of this cancer. Because symptoms are typically minimal or absent in the early stage, piriform sinus carcinoma is often advanced at the time of diagnosis. When it is complicated by PS, the chance of misdiagnosis would be much higher.

AOSD is a syndrome with unclear etiology and pathogenesis. Its typical manifestations in-

clude hyperpyrexia (almost in all patients), transient rash, arthritis, arthralgia and pharyngalgia. The criteria for diagnosis of PS, which were first proposed by Graus et al. [7], require serum rheumatoid factor titer < 1 and antinuclear antigen 80-100 IU/ml. The following two factors support the diagnosis of piriform sinus carcinoma with PS rather than AOSD in this case: (1) piriform sinus carcinoma was diagnosed for over 5 months after the onset of rheumatological symptoms; and (2) the patient's osteoarticular and rheumatological symptoms temporarily resolved after chemoradiotherapy.

Because piriform sinus carcinoma with paraneoplastic osteoarticular or rheumatological syndrome is rare while the pharyngalgia is the common symptom of AOSD and piriform sinus carcinoma, it is unsurprising that AOSD was readily diagnosed for this patient, whose main clinical manifestations were arthralgia, muscle weakness, erythematous rash, and prolonged fever. We suppose that many physicians with limited awareness of PS would not identify these constitutional symptoms to be indicative

## Piriform sinus carcinoma with a uncommon paraneoplastic syndrome

of PS, especially when the primary tumor does not cause any local symptoms. To make a correct diagnosis in such a situation would strongly challenge the clinical experience and expertise. A delay in diagnosis has contributed to the poor prognosis in this case since most of the hypopharyngeal carcinoma patients are effectively treated with a combination of surgery and radiochemotherapy. The following experiences can be learned from this case. First, piriform sinus carcinoma always results in pharyngalgia at some stage of the disease. In order not to be distracted by the symptoms of arthrosis or rheumatism, a CT scan of the neck or laryngofiberscopy should be carried out to rule out a hypopharyngeal carcinoma. Secondly, a patient with long-term heavy smoking and drinking was more likely to have a digestive carcinoma than an autoimmune disease. Thirdly, AOSD mainly occurs at the age between 16 and 35 years old. It is an exclusionary diagnosis. In other words, some diseases such as infectious disease, malignant tumor, connective tissue diseases, and vasculitis shall be ruled out before this diagnosis can be reached.

In conclusion, although piriform sinus carcinoma with paraneoplastic osteoarticular or rheumatological syndrome is rare, it is important to avoid a delayed diagnosis by recognizing this form of PS. Because the primary tumor was not confirmed until 5 months after the patient's first presentation to the hospital, he died of aggressive tumor. Does piriform sinus carcinoma with osteoarticular or rheumatological syndrome of PS imply a more aggressive tumor or poorer prognosis? This question requires further investigations.

### Disclosure of conflict of interest

None.

**Address correspondence to:** Dr. Wen Li, Department of Otolaryngology Head & Neck Surgery, West China Hospital, Sichuan University, Chengdu 610041, Sichuan, China. Tel: 008618980601420; E-mail: church.ent.wc@163.com

### References

- [1] Gulya AJ. Neurologic paraneoplastic syndromes with neurologic manifestations. *Laryngoscope* 1993; 103: 754-61.
- [2] Zuffa M, Kubancok J, Rusnak I, Mensatoris K, Horváth A. Early paraneoplastic syndrome in

medical oncology: clinicopathological analysis of 1694 patients treated over 20 years. *Neoplasma* 1984; 31: 231-6.

- [3] Chakroun A, Guigay J, Lusinchi A, Marandas P, Janot F, Hartl DM. Paraneoplastic dermatomyositis accompanying nasopharyngeal carcinoma: diagnosis, treatment and prognosis. *Eur Ann Otorhinolaryngol Head Neck Dis* 2011; 128: 127-31.
- [4] Toro C, Rinaldo A, Silver CE, Politi M, Ferlito A. Paraneoplastic syndromes in patients with nasopharyngeal cancer. *Auris Nasus Larynx* 2009; 36: 513-20.
- [5] Ferlito A, Rinaldo A. Paraneoplastic syndromes in patients with cancer of the larynx and hypopharynx. *Ann Otol Rhinol Laryngol* 2007; 116: 502-13.
- [6] Tian H, Chen Z, Wang C, Xing G. Hypopharyngeal paraganglioma with a paraneoplastic neurologic syndrome: a case report. *Head Neck* 2013; 35: E304-7.
- [7] Graus F, Delattre JY, Antoine JC, Dalmau J, Giometto B, Grisold W, Honnorat J, Smitt PS, Vedeler Ch, Verschuuren JJ, Vincent A, Voltz R. Recommended diagnostic criteria for paraneoplastic neurological syndromes. *J Neurol Neurosurg Psychiatry* 2004; 75: 1135-40.
- [8] Storstein A, Vedeler CA. Paraneoplastic neurological syndromes and onconeural antibodies: clinical and immunological aspects. *Adv Clin Chem* 2007; 44: 143-85.
- [9] Miyachi H, Akizuki M, Yamagata H, Mimori T, Yoshida S, Homma M. Hypertrophic osteoarthropathy, cutaneous vasculitis, and mixed-type cryoglobulinemia in a patient with nasopharyngeal carcinoma. *Arthritis Rheum* 1987; 30: 825-9.
- [10] Fasanmade A, Farrell K, Perkins CS. Bazex syndrome (acrokeratosis paraneoplastica): persistence of cutaneous lesions after successful treatment of an associated oropharyngeal neoplasm. *Br J Oral Maxillofac Surg* 2009; 47: 138-9.
- [11] Saxby AJ, Chin M. Paraneoplastic syndrome in a case of sinonasal adenocarcinoma. *Otolaryngol Head Neck Surg* 2009; 141: 547-8.
- [12] Ali M, Keir M, Dodd H, Cerio R. Flexural Bazex syndrome associated with tonsillar adenocarcinoma. *J Drugs Dermatol* 2004; 3: 557-9.
- [13] Henke C, Rieger J, Hartmann S, Middendorp M, Steinmetz H, Ziemann U. Paraneoplastic cerebellar degeneration associated with lymphoepithelial carcinoma of the tonsil. *BMC Neurol* 2013; 13: 147.
- [14] Sobas MA, Galiano LMA, de la Fuente Cid R, Pereiro Zabala I. Paraneoplastic limbic encephalitis and epidermoid carcinoma of the pyriform. *An Med Interna* 2006; 23: 331-4.

## Piriform sinus carcinoma with a uncommon paraneoplastic syndrome

- [15] Chan KH, Leung SY, Cheung RT, Ho SL, Mak W. Paraneoplastic motor neuropathy and inflammatory myopathy associated with nasopharyngeal carcinoma. *J Neurooncol* 2007; 81: 93-6.
- [16] Adams C, McKeon A, Silber MH, Kumar R. Narcolepsy, REM sleep behavior disorder, and supranuclear gaze palsy associated with Ma1 and Ma2 antibodies and tonsillar carcinoma. *Arch Neurol* 2011; 68: 521-4.
- [17] Tan KC, Nicholls J, Kung AW, Leong L, Lam KS. Unusual endocrine presentations of nasopharyngeal carcinoma. *Cancer* 1996; 77: 1967-72.
- [18] Cohen PR, Holder WR, Tucker SB, Kono S, Kurzrock R. Sweet syndrome in patients with solid tumors. *Cancer* 1993; 72: 2723-31.
- [19] Marglani O, Al-Herabi A, Odell P. Marantic endocarditis as an unusual paraneoplastic syndrome of head and neck squamous cell carcinoma. *J Otolaryngol Head Neck Surg* 2009; 38: E76-7.
- [20] Okada M, Suzuki K, Hidaka T, Shinohara T, Takada K, Nakajima M, Nakanishi T, Ohsuzu F. Polyarteritis associated with hypopharyngeal carcinoma. *Intern Med* 2002; 41: 892-5.
- [21] Janus JR, Chinnadurai S, Moore EJ. Case report: Paraneoplastic neurologic syndrome associated with squamous cell carcinoma of the tonsil. *Ear Nose Throat J* 2013; 92: E13.
- [22] Eggelmeijer F, Macfarlane JD. Polyarthrititis as the presenting symptom of the occurrence and recurrence of a laryngeal carcinoma. *Ann Rheum Dis* 1992; 51: 556-7.
- [23] Miller TR, Davis J. Acanthosis nigricans occurring in association with squamous carcinoma of the hypopharynx. *N Y State J Med* 1954; 54: 2333-6.
- [24] Sandoval M, Girons Bonells J, Foglia Fernández M, Amilibia Cabeza E. Paraneoplastic syndrome as a manifestation of cancer of the hypopharynx. *Acta Otorrinolaringol Esp* 1999; 50: 405-9.