

Original Article

Percutaneous transhepatic embolization of gastroesophageal varices combined with partial splenic embolization for the treatment of variceal bleeding and hypersplenism

Wei-Dong Gong^{1*}, Ke Xue^{2*}, Yuan-Kui Chu³, Qing Wang³, Wei Yang⁴, Hui Quan², Peng Yang⁴, Zhi-Min Wang¹, Zhi-Qun Wu¹

¹Division of Interventional Radiology, Tang Du Hospital, The Fourth Military Medical University, Xian 710038, China; ²Division of Interventional Radiology, Baoji Zhongxin Hospital, Baoji 710038, China; ³Division of Surgery, Tang Du Hospital, The Fourth Military Medical University, Xian 710038, China; ⁴Department of Biostatistics, The Fourth Military Medical University, Xian 710032, China. *Co-first authors.

Received August 7, 2015; Accepted October 5, 2015; Epub October 15, 2015; Published October 30, 2015

Abstract: This study aims to evaluate the therapeutic results of percutaneous transhepatic embolization of gastroesophageal varices combined with partial splenic embolization in patients with liver cirrhosis, and to explore the role of this minimally invasive treatment as an alternative to surgery. 25 patients with liver cirrhosis were received percutaneous transhepatic embolization of gastroesophageal varices combined with partial splenic embolization. Another 25 patients with liver cirrhosis underwent Hassab's operation. They were followed up, and received endoscopy, B ultrasound, liver function and hematologic examination at 24 months after the therapy. In minimal invasive group, before treatment and after 24 month following up after treatment, improved varices, improved portal hypertension and improved hypersplenism were showed comparing with the surgery group, and that they were measured by endoscopic visualization, ultrasound and blood counts. the white blood cell and platelet count were 2.33 ± 0.65 ($10^9/L$) and 3.63 ± 1.05 ($10^{10}/L$), 7.98 ± 3.0 ($10^9/L$) and 16.3 ± 9.10 ($10^{10}/L$) ($P<0.05$); the diameter of the portal vein were 1.47 ± 0.25 cm, 1.31 ± 0.23 cm ($P<0.05$). Esophageal varices passed from grade III to lower grade II in 11 patients, and from grade II to lower grade I in 6 patients at 24 month following up. In surgical group, the white blood cell and platelet count were 2.2 ± 0.60 ($10^9/L$), 4.1 ± 1.25 ($10^{10}/L$) before treatment; 9.3 ± 2.56 ($10^9/L$), 32.1 ± 12.47 ($10^{10}/L$) after the treatment at 24 month following up ($P<0.05$). The diameter of the portal vein were 1.43 ± 0.22 cm before the treatment and 1.28 ± 0.18 cm after the treatment ($P<0.05$). Esophageal varices passed from grade III to lower grade II in 13 patients, and from grade II to lower grade I in 7 patients. The combination of PGEV and PSE can be considered as an option for the treatment of variceal bleeding with hypersplenism.

Keywords: Partial splenic embolization, percutaneous transhepatic embolization of gastroesophageal varices, variceal bleeding, hypersplenism

Introduction

Liver cirrhosis is one of most common disease in china, and patients with decompensated liver cirrhosis suffer many complications including ascites, variceal bleeding and hypersplenism [1-3]. Among them the variceal bleeding is usually lethal [2, 3]. The immediate mortality from uncontrolled bleeding is about 4-8% [2, 4, 5], and 20% of cirrhotic patients with an acute variceal bleeding episode will die within 6 weeks [2, 4, 5]. Even the acute variceal bleed-

ing episode was controlled, more than 50%-60% patients may suffer from recurrent bleeding [6, 7], and the mortality of variceal rebleeding is as high as 78% in patients with advanced hepatic decompensation [5].

Pharmacological treatment modalities for portal hypertension with variceal bleeding include surgery, interventional radiology, and endoscopic treatment. A number of surgical procedures have been developed including shunting procedures and nonshunting procedures.

Treatment of variceal bleeding

Table 1. Modified endoscopic classification of EV

| Grade | Endoscopic appearance |
|-------|----------------------------------------------------------------------------------------------------------|
| 0 | No varices |
| I | Varices run straight (<3 mm) |
| II | Varices show beaded appearance (3-5 mm in diameter) |
| III | Varices run in oblique course and are tortuous with tumorlike appearance (>5 mm) (with red colour signs) |

Table 2. Patient's characteristics

| Patient's characteristics | | Group A (non-surgical) | Group B (surgical) | Statistic analysis |
|---------------------------|-------------|---------------------------|-----------------------|-----------------------|
| Number of patients | | 25 | 25 | |
| Gender | Male | 20 | 19 | P=0.733 |
| | Female | 5 | 6 | |
| Age (yrs) | Mean | 41.3±9.06 | 44.3±9.03 | t=-1.173 |
| | Range | 30-56 | 29-62 | P=0.247 |
| Etiology of cirrhosis | Hepatitis A | 8% (2) | 8% (2) | P=0.711 |
| | Hepatitis B | 88% (22) | 84% (21) | |
| | Hepatitis C | 4% (1) | 8% (2) | |
| Degree of variceal | 0 | 0 | 0 | P=0.773 |
| | I | 0 | 0 | |
| | II | 40% (10) | 36% (9) | |
| | III | 60% (15) | 64% (16) | |
| Child-Pugh Grade | A | 32% (8) | 28% (7) | P=0.754 |
| | B | 68% (17) | 72% (18) | |
| | C | 0 | 0 | |
| Variceal bleeding history | Yes | 25 | 25 | |
| | No | 0 | 0 | |

Two groups have no statistical difference.

These procedures are very effective in relieving portal vein pressure and preventing rebleeding, but these operations have their limitations: mainly their invasiveness and post-procedure complications including a high incidence of portal thrombosis, serious gastric mucosa damage and gastric emptying delay, encephalopathy and worsening liver function [8-10], and so it was not the first choice for the patients with variceal bleeding and was excluded for the patients with functional hepatic reserve of grade Child-Pugh C.

Minimal invasive techniques that have been recommended for the treatment of variceal bleeding include endoscopic sclerotherapy (ES) [11-13], variceal ligation (EVL) [11, 12], transjugular intrahepatic portosystemic shunt (TIPS) [14-16], percutaneous trans-hepatic embolization of gastroesophageal varices (PEGV)

[17, 18], and other combined therapies [19-22]. The endoscopic therapies are effective in preventing variceal bleeding by eradicating the varices, but these treatments does not help to relieve portal hypertension and other complications, and the rate of rebleeding is still significantly high despite treatment [12]. TIPS was very effective in decreasing portal pressure and preventing rebleeding, but the main problem with TIPS was that may enhance liver failure and increase the risk of encephalopathy of about 29% [14]. Therefore, TIPS is not recommended as a first-choice treatment to prevent rebleeding, but rather as a rescue therapy [12, 15]. Percutaneous splenic embolization (PSE) was effective for hypersplenism, and it was also benefit for the improvement of liver function and portal hypertension, although it was not effective in decreasing portal hyperten-

sion as well as TIPS [23]. PEGV was successful in controlling bleeding in 70-90% of such patients [18, 24, 25]. However, the underlying portal hypertension and hepatic insufficiency are not affected by PEGV, and recurrent bleeding occurred in 35-65% of patients within a few months after embolization [17, 18, 24]. Meanwhile it has no effect to hypersplenism too. In this study, we combined PEGV with PSE to treat the patients with variceal bleeding history and hypersplenism based on hypothesis that combining PEGV with PSE should relieve not only portal hypertension but also hypersplenism, and thus prevent the rebleeding of esophageal varices. However, whether combined PEGV and PSE is effective remains unknown. Thus, the purpose of our study was to compare the rebleeding rates between patients treated with surgery and those treated with PEGV combined with PSE.

Treatment of variceal bleeding

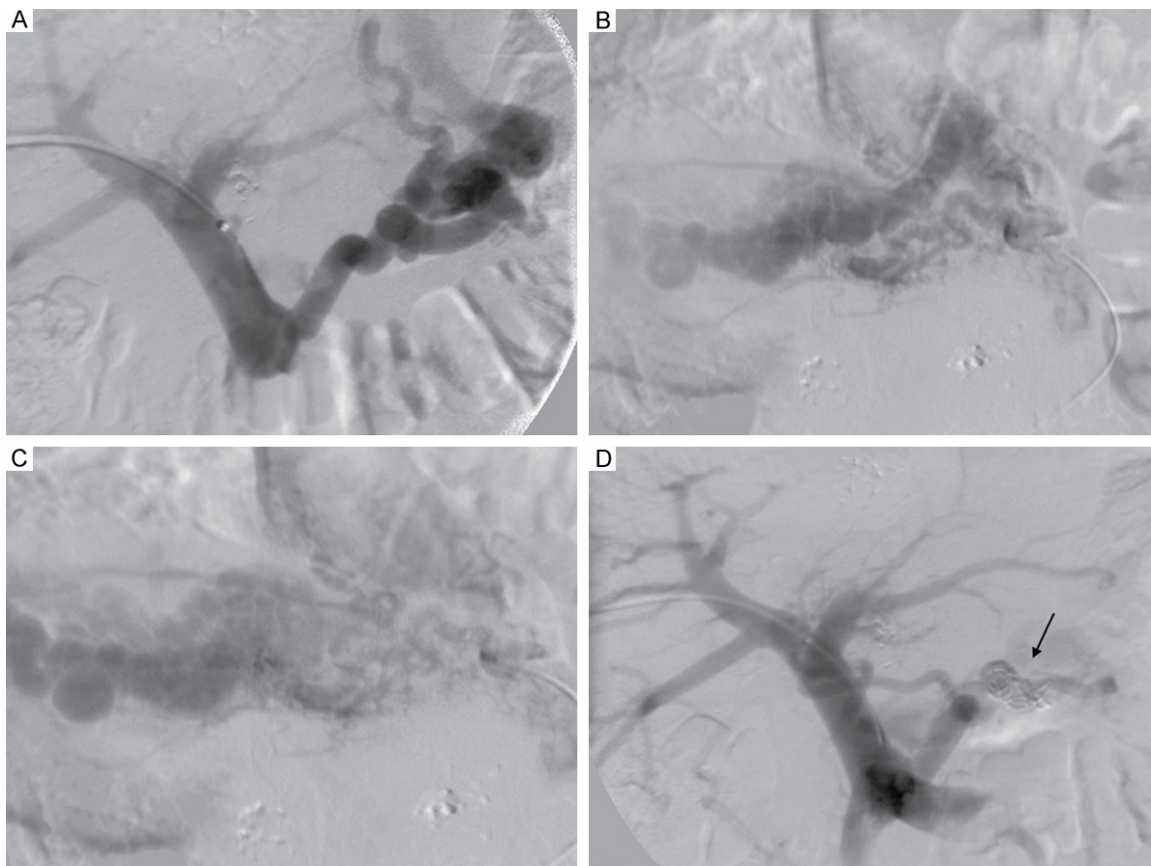


Figure 1. Percutaneous transhepatic embolization of the gastroesophageal varices. A-C. Selective catheterization of left gastric vein shows the varices. D. After embolization with 8 ml absolute alcohol and stainless-steel coils, left gastric vein is occluded, portography shows no other veins feeding varices. The arrow indicates the coils.

Methods

Patients

The study was conducted at the Department of Interventional Radiology and the Department of Surgery, and was approved by the University's Institutional Review Board.

Inclusion criteria were clinically diagnosed portal hypertension caused by hepatitis-induced cirrhosis, esophageal varices with a medium or large size by the endoscopy (grade II or III) (**Table 1** show the criteria of varice grade by the endoscopy), a history of upper gastrointestinal hemorrhage not with acute bleeding, the functional hepatic reserve belong to grade A or B according to the Pugh-modified Child's scales, and hypersplenism indicated by hematologic examination.

Exclusion criteria were bleeding with other sources such as erosions and duodenal ulcer,

hepatoma, Budd-Chiari Syndrome, cavernous transformation of portal vein, or the functional hepatic reserve of grade C.

Randomization procedure

50 patients during the study period from January 2006 to December 2006 were involved in this trial. Patients will be randomly allocated to either minimal invasive group (group A) or surgery group (group B). **Table 2** showed the clinical characteristics of the two groups of patients. All patients meet the inclusion and exclusion criteria, and all the patients signed the paper of agreement for the treatment. During the first visit to the outpatient clinic of the department, the patient's history and a standard examination will be documented. Conform our selection criteria, the doctors decides whether a patient is eligible for this trial. The study will be explained to the patient, and after the patients signed the paper of agreement for the treatment, the patients were

Treatment of variceal bleeding

Table 3. Cell counts of two groups before and after the treatment

| Result | Group A (non-surgical) | Group B (surgical) | Statistical analysis |
|--------------------------------------------------------------|------------------------|--------------------|----------------------|
| White blood cell before the procedure ($10^9/L$) | 2.33±0.65 (n=25) | 2.2±0.60 (n=25) | P=0.466 |
| White blood cell in 6 months ($10^9/L$) | 7.98±3.0 (n=23) | 9.3±2.56 (n=22) | P=0.101 |
| White blood cell in 1 years ($10^9/L$) | 7.98±3.0 (n=22) | 9.3±2.56 (n=22) | P=0.101 |
| White blood cell in 2 years after the procedure ($10^9/L$) | 7.98±3.0 (n=21) | 9.3±2.56 (n=21) | P=0.101 |
| Platelets before the procedure ($10^{10}/L$) | 3.63±1.05 (n=25) | 4.1±1.25 (n=25) | P=0.157 |
| Platelets in 6 months after the procedure ($10^{10}/L$) | 16.3±9.10 (n=23) | 32.1±12.47 (n=22) | P<0.001 |
| Platelets in 1 years after the procedure ($10^{10}/L$) | 16.3±9.10 (n=22) | 32.1±12.47 (n=22) | P<0.001 |
| Platelets in 2 years after the procedure ($10^{10}/L$) | 16.3±9.10 (n=21) | 32.1±12.47 (n=21) | P<0.001 |

admitted by the research nurse to the department of interventional radiology or the department of surgery according to the random numbers formed by the computer to ensure equal distribution of the randomization treatments. Then the questionnaires are filled.

The treatment was carried out by two specialists, one was responsible for the minimal invasive procedure, the other for the surgery, and they are not allowed to participate the assessment of the results. Research nurses are kept blinded for the allocated treatment during the follow-up period of 2 year. After the treatment, two doctors, who were blinded with the treatment, will call the patients at 24 months and the therapeutic effect (Platelets and white blood cell count, degree of varices, bleeding episode, diameter of the portal vein, etc) was assessed, and the main questionnaire will be filled and sent to researchers.

The statistical methods used include Chi-square test, t test and Wilcoxon test.

Minimal invasive procedures (PEGV + PSE)

A standardized PEGV and PSE technique were performed in 25 patients, and C-arm fluoroscopy was used for the procedures and DSA films were obtained for documentation purposes. Antibiotic prophylaxis was started 48 h before the PSE using cefoperazone and gentamicin, and continued for 5 days after the procedure.

PEGV

Percutaneous transhepatic embolization of gastroesophageal varices was performed in a non-germ surgical operation room. After pre-medication with 50 mg ciorazepate and local

anesthetic, the liver was punctured through the axillary line with a 22-gauge, 15-cm-long Disp Chiba Introducer Needle (Cook Incorporated) directed toward right branch of the portal vein under the guidance of ultrasound. After the success of the puncture, the Neff sheath with 7 French O.D. (Cook Incorporated) was inserted into right branch of the portal vein and a 4F catheter was introduced to portal vein, gastric vein, splenic vein and mesenteric vein respectively, then DSA of these veins were performed and the hemodynamics of the portal vein were reviewed independently by two investigators. After the catheter was selectively inserted into the left gastric vein, and the embolization was performed by injection of 5-25 ml absolute ethiodol according to DSA. When the blood flow of the left gastric vein was very slow, the main trunk of the vein was occluded with appropriate size stainless-steel coils [17]. After embolization, portography was performed again to ascertain left gastric vein obliteration and the tip of the catheter was inserted into the splenic vein to detect the presence of other venous collaterals for eventual occlusion with same method. After the procedure was finished, pull out the catheter first and then pull the sheath out of the right branch of the portal vein very slowly but still keep the tip of sheath inside the liver for 5 minutes until no bleeding. If the bleeding was not stopped, the needle tract was embolized with Fibrin Sealant (Guanzhou Bioseal Biotech Co. Ltd), and finally the puncture site was wrapped with a compression bandage, then the patient was moved to the ICU for 48 hours to make sure no bleeding (**Figure 1**).

PSE

PSE was performed using the Seldinger method in the third day after the PEGV. In brief, the femoral artery approach was used for superse-

Treatment of variceal bleeding

Table 4. Outcomes of two groups before and after the treatment at 24 months

| Result | Group A (non-surgical) | Group B (surgical) | Statistical analysis |
|------------------------------------------------------|-------------------------------------------------|-------------------------------------------------|----------------------|
| The diameter of the portal vein before the procedure | 1.47±0.25 (n=21)§ | 1.43±0.22 (n=21)¶ | P=0.551 |
| The diameter of the portal vein after the procedure | 1.31±0.23 (n=21)§ | 1.28±0.18 (n=21)¶ | P=0.609 |
| Rebleeding rate in 2 years after the procedure | 16% (4) | 20% (5) | P=0.713 |
| Death rate in 2 years after the procedure | 16% (4) (3 for rebleeding, 1 for liver failure) | 16% (4) (2 for rebleeding, 2 for liver failure) | P=1 |
| Times in hospital (days) | 17.56±8.79 | 32.3±12.2 | P<0.001 |
| Mean Cost (¥) | 19662.4±5768.04 | 46285.02±12376.1 | P<0.001 |

Note: §P=0.023, ¶P=0.011.

lective catheterization of the splenic artery, after splenic arteriography was performed, the arteriograms were reviewed independently by two investigators, and embolization was achieved by injecting 2-mm gelatin-sponge cubes suspended in a saline solution containing antibiotics until there was a 60% to 70% reduction in splenic blood flow. Strict aseptic technique was used throughout the procedure.

After the operation, patients were infused antibiotics for five days and gave some painkiller if necessary. The patients were followed up for 24 months.

Surgery (Hassab's operation)

Patients assigned to group B (n=25) underwent Hassab's operation as previously described in detail by Yang and Qiu [26]. In brief, extended left subcostal incision or L incision of the left upper abdomen was used for extreme splenomegaly. After routine splenectomy, the gastric branch and 5-8 small branches of the gastric coronary veins were disconnected. The esophageal branch was disconnected and suture-ligated. The gastric posterior vein was ligated by suturing, and then the left subphrenic vein was ligated as well. In addition, the arteries accompanied by the veins including the left gastric artery, left gastroepiploic artery, gastric posterior artery and left subphrenic artery, were disconnected.

Two groups of patients were followed up, and the endoscopy, B ultrasound, liver function and hematologic examination were performed at 24 months after the therapy.

Results

Between January and December 2006, 25 patients were treated with the PGEV plus PSE

and 25 patients with surgery respectively. The procedure of embolization and surgery were successful in all patients. All the patients treated once and the results are summarized in **Table 4**.

In minimal invasive group, the white blood cell and platelet count were 2.33±0.65 (10⁹/L) and 3.63±1.05 (10¹⁰/L) before the treatment, 7.98±3.0 (10⁹/L) and 16.3±9.10 (10¹⁰/L) after the treatment at 24 month following up (P<0.05) (**Table 3**). The diameter of the portal vein were 1.47±0.25 cm before the treatment and 1.31±0.23 cm after the treatment at 24 month following up (P<0.05) (**Table 4** and **Figure 2**). Esophageal varices passed from grade III to lower grade II in 11 patients, and from grade II to lower grade I in 6 patients at 24 month following up. All patients had mild fever and left flank pain in the 5-7 days following the procedure, well controlled with non-steroidal anti-inflammatory drugs. 1 cases of portal thrombosis have been observed. No patient developed a splenic abscess. The recurrent bleeding rate was 16% (4/25) at 24 month following up. 3 patients died of the recurrent bleeding, 1 patient died of liver failure (**Figure 3**).

In surgical group, the white blood cell and platelet count were 2.2±0.60 (10⁹/L) and 4.1±1.25 (10¹⁰/L) before treatment; 9.3±2.56 (10⁹/L) and 32.1±12.47 (10¹⁰/L) after the treatment at 24 month following up (P<0.05). The diameter of the portal vein were 1.43±0.22 cm before the treatment and 1.28±0.18 cm after the treatment (P<0.05). Esophageal varices passed from grade III to lower grade II in 13 patients, and from grade II to lower grade I in 7 patients. 4 patients developed portal thrombosis after the procedure. The recurrent bleeding rate was 20% (5/25), two patients died of living failure after the surgery, 2 died of recurrent

Treatment of variceal bleeding

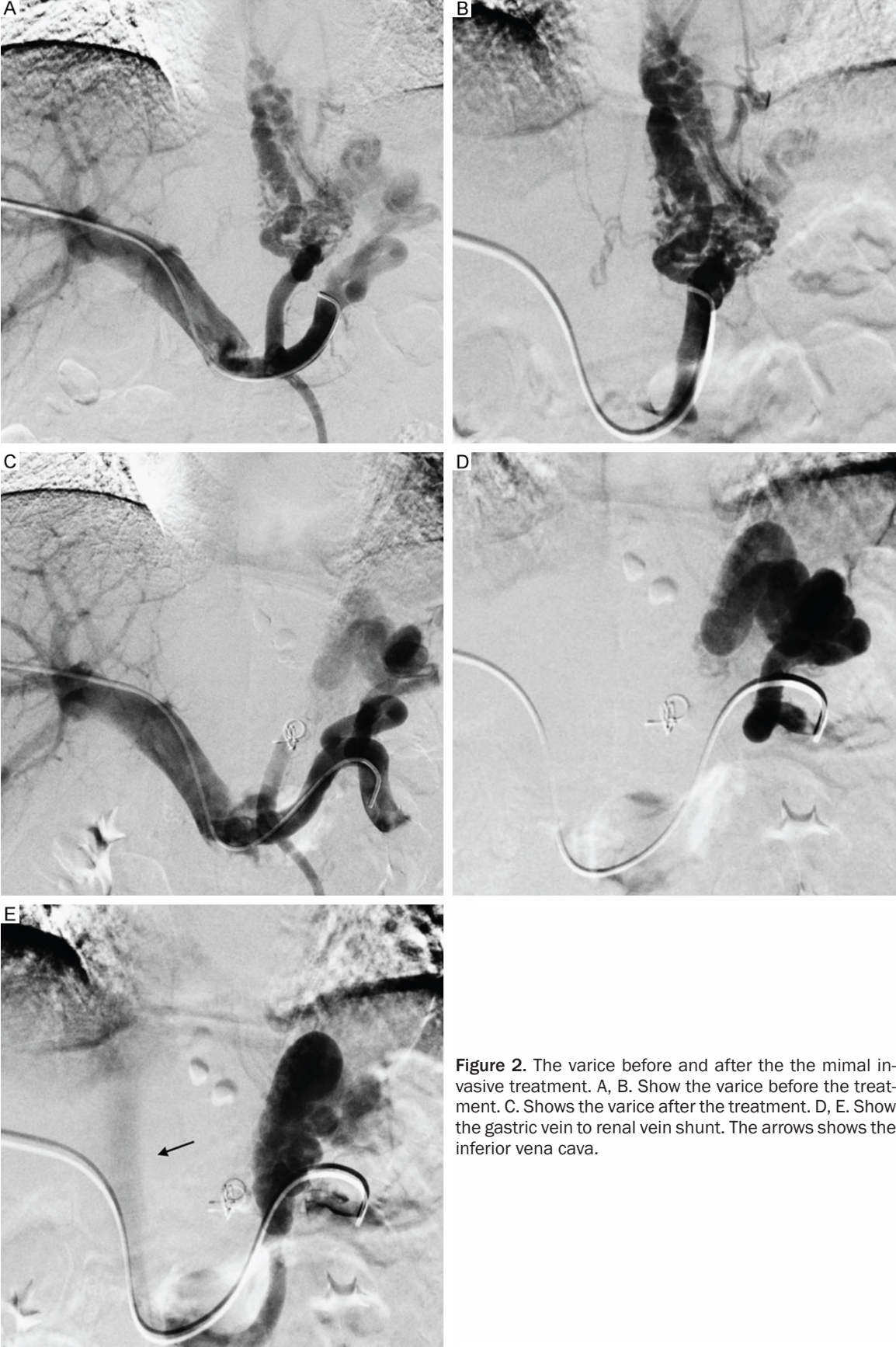

Figure 2. The varice before and after the the mimal invasive treatment. A, B. Show the varice before the treatment. C. Shows the varice after the treatment. D, E. Show the gastric vein to renal vein shunt. The arrows shows the inferior vena cava.

Treatment of variceal bleeding

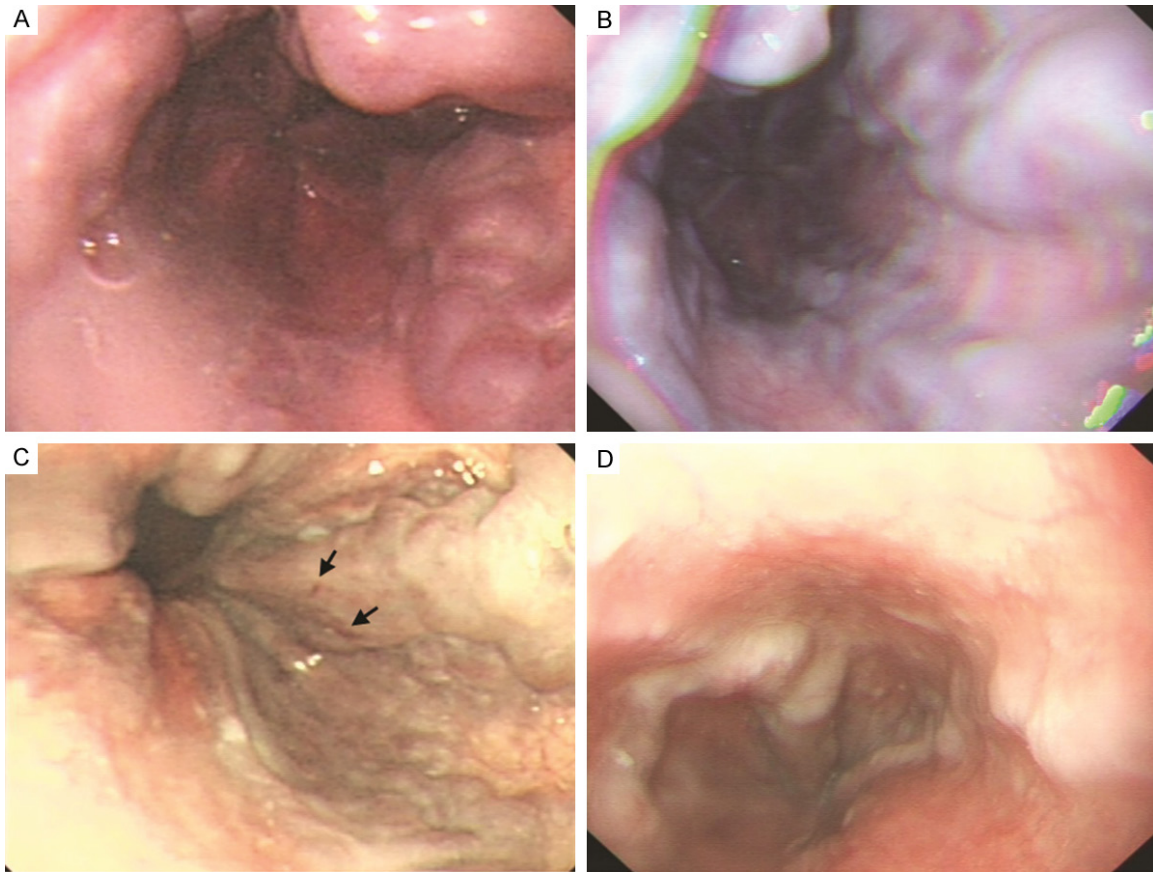


Figure 3. The conventional endoscopy results of the varice before and after the minimal invasive treatment. A. Shows the large varices before the treatment. B. Shows the small varice after the treatment. C. Shows the the beaded esophageal varices and prominent red signs, which indicate grade 3 varices before the treatment. D. Shows the small varice without the red sign after the treatment. The arrows show the varices.

Table 5. Degree of variceal of two groups before and after the treatment at 24 months

| Result | Degree of variceal | Group A (non-surgical) | Group B (surgical) |
|---------------------------|--------------------|------------------------|--------------------|
| Before the treatment (25) | 0 | 0 | 0 |
| | I | 0 | 0 |
| | II | 40% (10) | 36% (9) |
| After the treatment (21) | III | 60% (15) | 64% (16) |
| | 0 | 0 | 0 |
| | I | 28.6% (6) | 33.3% (7) |
| | II | 47.6% (10) | 52.4% (11) |
| | III | 23.8% (5) | 14.3% (3) |

bleeding (**Table 5**). Most of the patients have dysfunction of stomach, mainly complaining of distension, no appetite and anorexia.

Discussion

Liver cirrhosis will lead to portal hypertension and hypersplenism. One of main complications

of portal hypertension is varices. It is estimated that varices are present in about 30-40% of compensated patients and 60% of decompensated patients at the time of diagnosis [3, 7]. And the rate of the bleeding is closely related with the size of the varices. The risk of variceal bleeding in patients with small varices is about 7% at 2 years, and 30% in patients with large varices [5]. Thrombocytopenia caused by hypersplenism is the other independent predictors of bleeding from large varices [23]. The treatments for the variceal bleeding

include two kinds of method, eradication of varices and relieving of portal hypertension. And on theory, the methods which can relieve the portal hypertension should be the most effective way. The endoscope treatment does not change the pressure of the portal vein; it does not prevent the recurrent bleeding, although it can benefit the variceal bleeding.

TIPS can relieve portal hypertension effectively, and decrease the recurrent bleeding rate, but it was not the first choice for the treatment of variceal bleeding.

It has been proved that PGEV and PSE can improve the clinical outcomes of the patients with variceal bleeding respectively, especially PGEV for the controlling of the acute bleeding [17, 18]. But PGEV does not relieve the portal hypertension effectively. If the patients have the hypersplenism, the very lower platelet will enhance the rebleeding. So the recurrent bleeding rate is still higher. In our study, we combined the PGEV and PSE to increase the platelet count, blood supply to the liver and decrease the blood supply to the portal vein relieving the portal hypertension, and finally to decrease the recurrent bleeding episode. Our results suggested the combination was successful. A significant and progressive increase in white blood cell and platelet count has been observed in all patients; the diameter of the portal vein was decreased in all patients and esophageal varices disappeared or passed from higher grade to lower grade in most of the patients. The rate of recurrent bleeding episode in minimal invasive group was 16% at 2 years following up, which were significantly lower than that reported in the PGEV procedure only [17, 18]. The more important thing is that the recurrent bleeding rate in minimal invasive group was no different with the rate in the surgical group, and the mortality in the minimal group was lower than that in the surgical group, although the statistical analysis was no different. Meanwhile, the minimally invasive procedure has several possible advantages compared to the surgical procedure: 1) PGEV and PSE has little trauma compared to the surgery. PGEV can be completed under guidance of ultrasound with a thin needle and a 4F catheter, so it has avoided the more times acupuncture and damage to the liver (compared to the acupuncture without guidance of ultrasound in the past). PSE was completed through the femoral artery way, it was with very little trauma. Therefore this combination was safe. 2) The minimal invasive procedure has little complications compared to the surgery. In minimal group, no serious complications occurred. But in the surgical group, 3 patients died of the liver failure after the surgery. 4 patients have the portal vein thrombosis, because of the higher

platelet count after the splenectomy. Most of patients in the surgical group have dysfunction of stomach, mainly complaining of distension, no appetite and anorexia. 3) Overall financial advantages compared to the surgical group. The times in the hospital or the mean cost in the minimal invasive group was significantly shorter or lower than that in the surgical group. 4) The procedure was easy to perform compared to surgery. The success rate of the procedures in our minimal invasive group was 100% [27-29].

In conclusion, it suggests a lower likelihood of rebleeding versus historically described controls with the combination of PGEV and PSE. The success rate and the rebleeding rate was no different in minimally invasive group compared to the surgery, but minimally invasive procedure has more advantages compared to the surgery.

Acknowledgements

The authors thank Liu Yu-Feng and Liu Yuan for the help with the equipment. The authors also thank Dr. Anne Robert (Chief of Vascular and Interventional Radiology; Executive Vice-Chair of Radiology; Thornton Hospital/UCSD Medical Center, La Jolla, CA92014, USA) for the preview of manuscripts.

Disclosure of conflict of interest

None.

Address correspondence to: Dr. Zhi-Qun Wu, Division of Interventional Radiology, Tang Du Hospital, The Fourth Military Medical University, Xian 710038, China. Tel: 86-29-83377864; Fax: 86-29-835466-46; E-mail: tdjrfsk@126.com

References

- [1] de Franchis R, Dell'Era A and Primignani M. Diagnosis and monitoring of portal hypertension. *Dig Liver Dis* 2008; 40: 312-317.
- [2] D'Amico G and de Franchis R. Upper digestive bleeding in cirrhosis. Post-therapeutic outcome and prognostic indicators. *Hepatology* 2003; 3: 599-612.
- [3] D'Amico G, Garcia-Tsao G and Pagliaro L. Natural history and prognostic indicators of survival in cirrhosis: a systematic review of 118 studies. *J Hepatol* 2006; 1: 217-231.
- [4] D'Amico G and Luca A. Natural history. Clinical-haemodynamic correlations. Prediction of the

Treatment of variceal bleeding

- risk of bleeding. *Baillieres Clin Gastroenterol* 1997; 11: 243-256.
- [5] de Franchis R and Primignani M. Natural history of portal hypertension in patients with cirrhosis. *Clin Liver Dis* 2001; 5: 645-663.
- [6] de Franchis R. Evolving consensus in portal hypertension report of the Baveno IV consensus workshop on methodology of diagnosis and therapy in portal hypertension. *J Hepatol* 2005; 43: 167-176.
- [7] Bosch J, Berzigotti A, Garcia-Pagan JC and Abraldes JG. The management of portal hypertension: rational basis, available treatments and future options. *J Hepatol* 2008; 48: 68-92.
- [8] Yoshida H, Mamada Y, Taniai N and Tajiri T. New methods for the management of esophageal varices. *World J Gastroenterol* 2007; 13: 1641-1645.
- [9] Borgonovo G, Costantini M, Grange D, Vons C, Smadja C and Franco D. Comparison of a modified Sugiura procedure with portal systemic shunt for prevention of recurrent variceal bleeding in cirrhosis. *Surgery* 1996; 119: 214-221.
- [10] Li Nn, Liu B, Xu RY, Fang HP and Deng MH. Splenectomy with endoscopic variceal ligation is superior to splenectomy with pericardial devascularization in treatment of portal hypertension. *World J Gastroenterol* 2006; 12: 7375-7379.
- [11] Tomikawa M, Hashizume M, Okita K, Kitano S, Ohta M, Higashi H and Akahoshi T. Endoscopic injection sclerotherapy in the management of 2105 patients with esophageal varices. *Surgery* 2002; 131: 171-175.
- [12] Villanueva C, Colomo A, Aracil C and Guarner C. Current endoscopic therapy of variceal bleeding. *Best Pract Res Clin Gastroenterol* 2008; 22: 261-278.
- [13] Krige JE, Kotze UK, Bornman PC, Shaw JM and Klipin M. Variceal recurrence, rebleeding, and survival after endoscopic injection sclerotherapy in 287 alcoholic cirrhotic patients with bleeding esophageal varices. *Ann Surg* 2006; 244: 764-770.
- [14] Tesdal IK, Filser T, Weiss C, Holm E, Dueber C and Jaschke W. Transjugular intrahepatic portosystemic shunts: adjunctive embolotherapy of gastroesophageal collateral vessels in the prevention of variceal rebleeding. *Radiology* 2005; 236: 360-367.
- [15] Portal Hypertension IV. In: De Franchis R, editor. *Proceedings of the fourth Baveno international consensus workshop on methodology of diagnosis and treatment*. Oxford UK: Blackwell; 2006. pp. 262-284.
- [16] Rosch J and Keller FS. Transjugular intrahepatic portosystemic shunt: present status, comparison with endoscopic therapy and shunt surgery, and future prospectives. *World J Surg* 2001; 25: 337-345.
- [17] L'Herminé C, Chastanet P, Delemazure O, Bonnière PL, Durieu JP and Paris JC. Percutaneous transhepatic embolization of gastroesophageal varices: results in 400 patients. *AJR Am J Roentgenol* 1989; 152: 755-760.
- [18] Zhang CQ, Liu FL, Liang B, Sun ZQ, Xu HW, Xu L, Feng K and Liu ZC. A Modified Percutaneous Transhepatic Variceal Embolization with 2-Octyl Cyanoacrylate Versus Endoscopic Ligation in Esophageal Variceal Bleeding Management: Randomized Controlled Trial. *Dig Dis Sci* 2008; 53: 2258-2267.
- [19] Ohmoto K, Yoshioka N, Tomiyama Y, Shibata N, Takesue M, Yoshida K, Kuboki M and Yamamoto S. Improved prognosis of cirrhosis patients with esophageal varices and thrombocytopenia treated by endoscopic variceal ligation plus partial splenic embolization. *Dig Dis Sci* 2006; 51: 352-358.
- [20] Lin N, Liu B, Xu RY, Fang HP and Deng MH. Splenectomy with endoscopic variceal ligation is superior to splenectomy with pericardial devascularization in treatment of portal hypertension. *World J Gastroenterol* 2006; 12: 7375-7379.
- [21] Taniai N, Onda M, Tajiri T, Yoshida H and Mamada Y. Combined endoscopic and radiologic intervention to treat esophageal varices. *Hepatogastroenterology* 2002; 49: 984-988.
- [22] Huang LY, Cui J, Wu CR and Liu YX. Embolization combined with endoscopic variceal ligation for the treatment of esophagogastric variceal bleeding in patients with cirrhosis. *Chin Med J* 2007; 120: 36-40.
- [23] Koconis KG, Singh H and Soares G. Partial Splenic Embolization in the Treatment of Patients with Portal Hypertension: A Review of the English Language Literature. *J Vasc Interv Radiol* 2007; 18: 463-481.
- [24] Smith-Laing G, Scott J, Long RG, Dick R and Sherlock S. Role of percutaneous transhepatic obliteration of varices in the management of hemorrhage from gastroesophageal varices. *Gastroenterology* 1981; 80: 1031-1036.
- [25] Benner KG, Keeffe EB, Keller FS and Rosch J. Clinical outcome after percutaneous transhepatic obliteration of esophageal varices. *Gastroenterology* 1983; 85: 146-153.
- [26] Yang Z and Qiu F. Pericardial devascularization with splenectomy for the treatment of portal hypertension. *Zhonghua Wai Ke Za Zhi* 2000; 38: 645-648.
- [27] Sauer P, Theilmann L, Stremmel W, Benz C, Richter GM and Stiehl A. Transjugular intrahepatic portosystemic stent shunt versus sclerotherapy plus propranolol for variceal rebleeding. *Gastroenterology* 1997; 113: 1623-1631.

Treatment of variceal bleeding

- [28] Escorsell A, Bañares R, García-Pagán JC, Gilibert R, Moitinho E, Piqueras B, Bru C, Echenagusia A, Granados A and Bosch J. TIPS versus drug therapy in preventing variceal re-bleeding in advanced cirrhosis: a randomized controlled trial. *Hepatology* 2002; 35: 385-392.
- [29] Burroughs AK and Vangeli M. Transjugular intrahepatic portosystemic shunt versus endoscopic therapy: randomized trials for secondary prophylaxis of variceal bleeding: an updated metaanalysis. *Scand J Gastroenterol* 2002; 37: 249-252.