

Case Report

Favorable outcome of extended treatment with adding pegylated Interferon α -2a to entecavir for HBeAg-positive chronic hepatitis B: a case report

Ying Zhang¹, Xuefeng Li², Jiao Xu¹, Yong Zhang¹

¹Sixth Department of Liver Diseases, Dalian Sixth People Hospital, Dalian 116031, Liaoning Province, China;

²Department of Infectious Diseases, The Second Hospital of Dalian Medical University, Dalian 116027, China

Received August 8, 2015; Accepted October 5, 2015; Epub October 15, 2015; Published October 30, 2015

Abstract: Hepatitis B virus (HBV) surface antigen (HBsAg) to anti-HBsAg (anti-HBs) seroconversion is the best and final objective of all available chronic hepatitis B (CHB) therapies. Unfortunately, this goal is not commonly obtained with current therapeutic approaches. Here, we reported a case that a Chinese CHB patient successfully achieved HBsAg seroconversion under extended individualized therapeutic schedule. At 48 weeks after entecavir (ETV) monotherapy, pegylated interferon alpha-2a (PEG-IFN- α -2a) was added, and the titers of HBsAg decreased and HBsAg loss was achieved. After 96 weeks of combination therapy, PEG-IFN- α -2a was stopped and ETV monotherapy was continued for additional 24 weeks. HBsAg seroconversion was sustained, 48 weeks after the end of all treatment.

Keywords: Chronic hepatitis B, sequential combination, PEG-IFN- α -2a, entecavir

Introduction

In despite of potent viral suppression activity of current NAs, the efficacy to achieve short-term therapeutic goals is still not satisfactory. The one-year HBeAg seroconversion rate is only 12-23% after NA treatment and 30-36% after Peg-IFN therapy. Current therapies can only suppress or control the viral replication, and the cure rate of CHB is still low [1-3]. More efforts are required to improve the therapeutic responses. Combining interferon and NA could be a novel approach with synergic effect of immunomodulatory and antiviral action [4]. However, a few trials have shown that the simultaneous combination with IFN and lamivudine failed to demonstrate superiority to IFN monotherapy [5, 6]. Nonetheless, the combination therapy is still attractive [7] and it seems to be encouraged with sequential combination with NA, before interferon administration. However, the current guidelines for the treatment of CHB do not support the combination therapy, including adding PEG-IFN α -2a to the current NA therapy [8]. Herein, we report a case that a Chinese patient with HBeAg positive chronic hepatitis B achieved HBsAg seroconversion and regres-

sion of liver fibrosis after extended combination therapy of adding PEG-IFN- α -2a to the initial ETV therapy.

Case report

A 35 year old Chinese man was admitted to our ward, with chief complaints of fatigue and anorexia for one month in June 2010, who was found to be HBsAg positive in infancy and had fluctuating values of aminotransferase values over time during his teenage. The patient did not have familial history of HBV infection or other major risk factors for HBV infection. The patient's body mass index was normal and did not have a history of drug or alcohol abuse. The laboratory testing, such as hepatitis A, C and E serology, cytomegalovirus, EB virus, anti-nephrotic cytoplasmic antibody, antibodies to liver/kidney microsome, smooth muscle antibodies, anti-neutrophil cytoplasmic antibody, immunoglobulin pattern, TSH, renal function and urine routine test, were all negative or within the normal range. Serum HBsAg, HBeAg and HBc-Ab were positive and HBV-DNA was 1.76×10^7 IU/ml. The viral genotype was C. The liver biochemistry showed the ALT level of 157

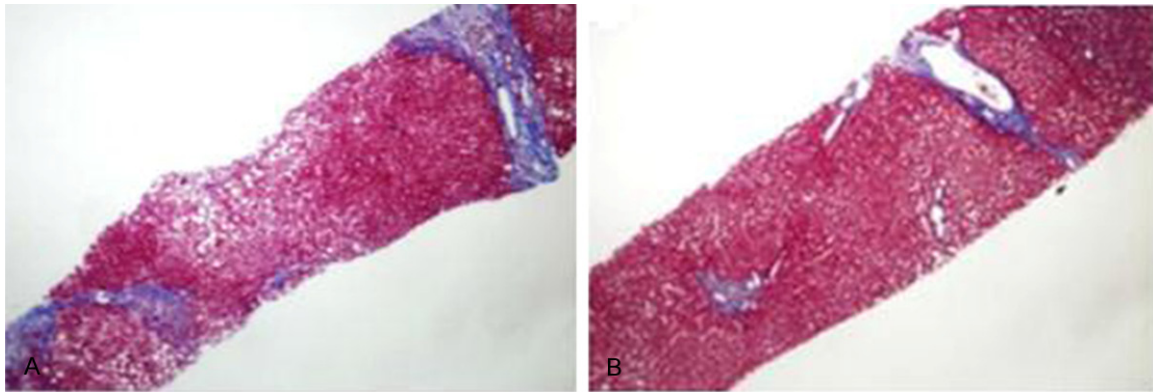


Figure 1. Liver biopsy samples stained with Masson's trichrome and demonstrates regression of liver fibrosis after 2 years PEG-IFN treatment. Biopsy of the liver shows septal collagenous fibrosis of moderate thickness at baseline (A) and periportal fibrosis with occasional long slender fibrosis at the end of PEG-IFN treatment (B).

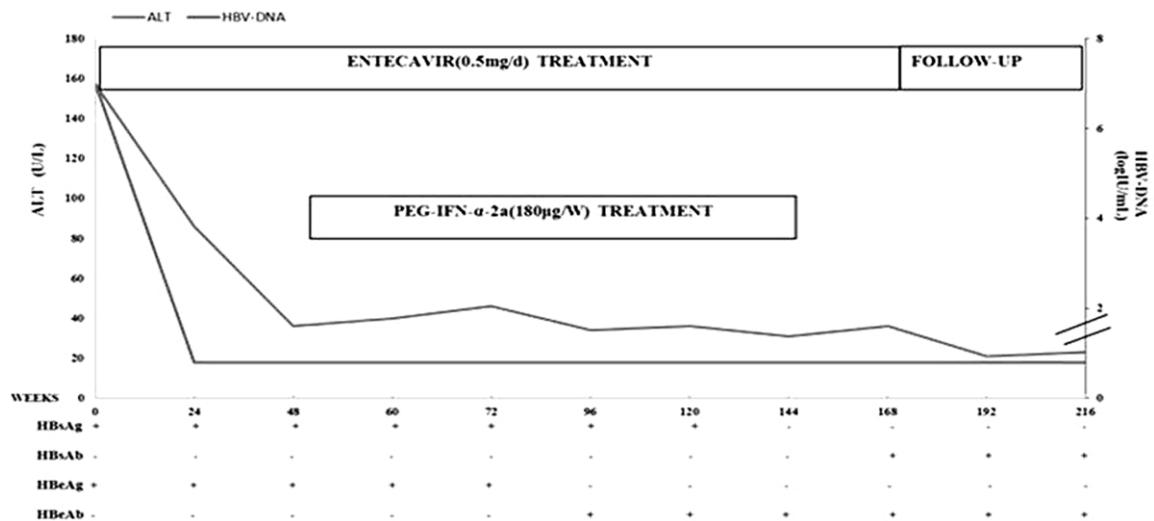


Figure 2. Virological profile and ALT levels during and after the treatment.

U/L and the AST level of 141 U/L. Serum bilirubin, albumin, globulin and prothrombin time were within normal range. The ultrasonography showed the echo enhancement of the liver with mild splenomegaly, and no ascites was detected. The patient was diagnosed with HBeAg positive CHB and was treated with ETV 0.5 mg/d. The patient achieved a prompt virological/biochemical response, including normalized ALT values and undetectable HBV-DNA, after 3 months. At the following visits, normal ALT levels and undetectable HBV DNA were sustained, but HBsAg and HBeAg were still positive at high titers. At 12 months after ETV therapy, the laboratory testing showed normal ALT Level, HBV-DNA < 20 IU/ml (Roche COBAS AmpliPrep/COBAS TaqMan), positive HBsAg (11989 IU/ml), and positive HBeAg (1330S/

CO) (Abbott ARCHITECT chemiluminescence microparticle immunoassay), and the patient expressed doubts about taking ETV every day for an indefinite duration. Then, after a long discussion, the add-on of PEG-IFN- α -2a (180 μ g/w) was proposed to continuing ETV for a period of 12 months and the patient accepted the individualized combination therapy. At the initiation of PEG-IFN treatment, we performed a needle liver biopsy showing significant liver fibrosis (F3, according to the METAVIR scoring system). During the first week of combination therapy, the patient suffered typical side effects of IFN, such as fever and fatigue, whereas the liver function tests were persistently normal with undetectable HBV DNA. Twelve weeks later, a slight decline of HBsAg of 11914 IU/ml and a significant decline of HBeAg were

observed. At 24 weeks, the level of HBsAg rapidly declined to 4791 IU/ml. And ALT level slightly increased. At 48 weeks, the HBeAg seroconversion was achieved and HBsAg declined to 3060 IU/ml. Considering the rapid decline of HBsAg levels followed by HBeAg seroconversion during 48 w of combination treatment, an extended treatment course was proposed to obtain HBsAg loss/seroconversion. The patient accepted to prolong the combination therapy for another 48 weeks. During the follow-up, rapid decline of HBsAg was observed and HBsAg loss was achieved after 96 weeks of combination therapy. Then, PEG-IFN α -2a was stopped, and ETV monotherapy was continued for additional 24 weeks and then stopped. HBsAg seroconversion was achieved after 12 weeks. Moreover, regression of hepatic fibrosis was documented using liver biopsy (F2, according to the METAVIR scoring system) at the end of PEG-IFN treatment (**Figure 1**). Till now, a completely sustained treatment response was noted for more than 12 months after stopping all treatment (**Figure 2**). The long-term safety profile of combination therapy was achieved, without serious side effects.

Discussion

Although antiviral treatment for CHB has been significantly improved, most patients do not obtain HBsAg seroclearance. Furthermore, the relapse is common during post NA therapy follow-up. Therefore, the combination therapy could be considered as the ideal treatment for CHB [9]. One aim of sequential therapy starting with NA is to lower the viral load, before IFN therapy is initiated, thereby restoring treatment sensitivity for low HBV DNA levels are associated with a favorable response to IFN. Another aim of sequential therapy is to prevent the relapse of hepatitis following the discontinuation of NA therapy through the use of IFN. Moreover, because of the substantial side effects and high cost of interferon-based therapies, the data about long-term interferon sequential combination therapy remain limited. Here, we reported a case that the patient achieved the sustained HBsAg/anti-HBs seroconversion using individualized sequential combination treatment with ETV and PEG-IFN α -2a.

In this case, HBeAg rapidly declined for the first 6 months of the add-on therapy, and then HBeAg/anti-HBe seroconversion achieved after

48 weeks, followed with a sharp decline of HBsAg, subsequently with the HBsAg clearance and the rise in Anti-HBs titers in the extended treatment and follow-up. None of these events was associated with ALT flares, which could have suggested a cytotoxic T cell attack of infected hepatocytes. However, we cannot exclude the killing by T cells of a minor proportion of the liver, since ALT levels slightly increased before HBsAg elimination. Furthermore, HBeAg clearance was simultaneous to that of rapid decline of HBsAg, and did not precede it.

An early decline of HBsAg, i.e. after week 12, is a well-established predictor for the efficacy of peg-IFN treatment [10, 11]. However, in this report, the patient had a slight decline of HBsAg after week 12, but a rapid decline after week 24, therefore, it seems reasonable to perform the combination therapy for at least 24 weeks.

Some studies have demonstrated the prolonged survival, lower rates of hepatic decompensation and hepatocellular carcinoma in patients with cirrhosis, who had HBsAg seroclearance [12, 13]. More and more evidence supported the view that HBsAg seroclearance could be a potential end point in the treatment of CHB patients [14]. Despite the additional clinical importance of HBsAg seroclearance, this event has not been included as a primary end point in treatment trials.

In this report, a therapeutic schedule based on the maintenance of ETV and the add-on of PEG-IFN- α -2a for a period of 48 weeks were proposed. We hope this regimen could help to accelerate the decline of HBsAg and induce HBsAg seroconversion, consequently, to prevent reactivation after discontinuance of ETV. Even though the patient did not achieve HBsAg seroclearance or seroconversion after the add-on of PEG-IFN- α -2a for 48 weeks, on-treatment viral suppression was more vigorous and HBeAg seroconversion was achieved. The reason for this might be the short duration of treatment of only 48 weeks. Under this condition, a rebound after stopping all treatment inevitably offsets some efficacy. Considering the high probability of HBV reactivation in the event of stopping all treatment and the fact that the best chances of success of PEG-IFN- α -2a therapy in CHB appear to occur, when the rapidly decline of HBsAg levels were followed by HBeAg seroconversion after added-on PEG-IFN- α -

2a for 48 weeks. An individualized extended treatment course was proposed to obtain HBsAg loss or seroconversion. HBsAg loss was achieved after a total of 96 weeks of the combination therapy. Therefore, extending the duration of therapy might enhance the HBsAg seroclearance.

The time point to end the treatment after HBsAg seroconversion remains undetermined. Heathcote et al [15] observed one reversion in 1 out of 12 patients with tenofovir-induced seroconversion. Since anti-HBs as the surrogate parameter of immunological control did not reach a titer above 100 U/L in the patient, the ETV maintenance therapy was continued for an additional 24 weeks. Till the time of this report writing, the patient has stopped all treatment for 1 year with sustained HBsAg seroconversion, serum Anti-HBs titers maintained more than 100 IU/L, undetectable HBVDNA and normal liver function tests.

For the evaluation of histological response during the treatment, we performed liver biopsy at the initiation and end of PEG-IFN treatment. The liver biopsy showed the improvement of inflammation and regression of fibrosis. This observation is consistent with the reported findings that the treatment with Peg-IFN therapy improved liver inflammation and fibrosis in HBeAg positive CHB patients, particularly in Peg-IFN responders. Some studies demonstrated that PEG-IFN inhibited the activation of HSCs and induced the apoptosis of HSC in a rat model of experimental liver fibrosis [16, 17]. Whether this plays a role in the regression of liver fibrosis during sequential combination therapy with PEG-IFN and NAs needs to be investigated.

In summary, the extended treatment of add-on of PEG-IFN to an ongoing ETV therapy is an understudied approach for the cure of CHB. In fact, there is no reliable information concerning which NAs is best to combine with IFN, the timing in giving each drug and the duration of their administration. The excellent outcome of this case may encourage the design of the large scale clinical trials necessary to definitively clarify the usefulness and the best schedule of this combination therapy.

Acknowledgements

We thank Ms Du Jinghua for assistance with the preparation of the submitted manuscript.

Disclosure of conflict of interest

None.

Address correspondence to: Dr. Ying Zhang, Sixth Department of Liver Diseases, Dalian Sixth People Hospital, Dalian 116031, Liaoning Province, China. Tel: 86-411-39728716; Fax: 86-411-39728716; E-mail: zy730302@aliyun.com

References

- [1] Liaw YF, Chu CM. Hepatitis B virus infection. *Lancet* 2009; 373: 582-92.
- [2] National Institute for Health and Care Excellence. NICE issues guideline on the diagnosis and management of chronic hepatitis B. London: NICE; 2013.
- [3] Bertolotti A, Rivino L. Hepatitis B: future curative strategies. *Curr Opin Infect Dis* 2014; 27: 528-34.
- [4] Rijckborst V, Sonneveld MJ, Janssen HL. Review article: chronic hepatitis B anti-viral or immunomodulatory therapy? *Aliment Pharmacol Ther* 2011; 33: 501-13.
- [5] Lau GK, Piratvisuth T, Luo KX, Marcellin P, Thongsawat S, Cooksley G, Gane E, Fried MW, Chow WC, Paik SW, Chang WY, Berg T, Flisiak R, McCloud P, Pluck N; Peginterferon Alfa-2a HBeAg-Positive Chronic Hepatitis B Study Group. Peginterferon Alfa-2a, lamivudine, and the combination for HBeAg positive chronic hepatitis B. *N Engl J Med* 2005; 352: 2682-95.
- [6] Marcellin P, Lau GK, Bonino F, Farci P, Hadziyannis S, Jin R, Lu ZM, Piratvisuth T, Germanidis G, Yurdaydin C, Diago M, Gurel S, Lai MY, Button P, Pluck N; Peginterferon Alfa-2a HBeAg-Negative Chronic Hepatitis B Study Group. Peginterferon alfa-2a alone, lamivudine alone, and the two in combination in patients with HBeAg-negative chronic hepatitis B. *N Engl J Med* 2004; 351: 1206-17.
- [7] Enomoto M, Tamori A, Nishiguchi S, Kawada N. Combination therapy with a nucleos(t)ide analogue and interferon for chronic hepatitis B: simultaneous or sequential. *J Gastroenterol* 2013; 48: 999-1005.
- [8] European Association for the Study of the Liver. EASL clinical practice guidelines: management of chronic hepatitis B virus infection. *J Hepatol* 2012; 57: 167-85.
- [9] Enomoto M, Tamori A, Nishiguchi S, Kawada N. Combination therapy with a nucleos(t)ide analogue and interferon for chronic hepatitis B: simultaneous or sequential. *J Gastroenterol* 2013; 48: 999-1005.
- [10] Marcellin P, Bonino F, Yurdaydin C, Hadziyannis S, Moucari R, Kapprell HP, Rothe V, Popescu M, Brunetto MR. Hepatitis B surface antigen levels: association with 5-year response to pegin-

- terferon alfa-2a in hepatitis B e-antigen-negative patients. *Hepatol Int* 2013; 7: 88-97
- [11] Sonneveld MJ, Rijckborst V, Cakaloglu Y, Simon K, Heathcote EJ, Tabak F, Mach T, Boucher CA, Hansen BE, Zeuzem S, Janssen HL. Durable hepatitis B surface antigen decline in hepatitis B e antigen-positive chronic hepatitis B patients treated with pegylated interferon- α 2b: relation to response and HBV genotype. *Antivir Ther* 2012; 17: 9-17.
- [12] Fattovich G, Olivari N, Pasino M, D'Onofrio M, Martone E, Donato F. Long-term outcome of chronic hepatitis B in Caucasian patients: mortality after 25 years. *Gut* 2008; 57: 84-90.
- [13] Moucari R, Korevaar A, Lada O, Martinot-Peignoux M, Boyer N, Mackiewicz V, Dauvergne A, Cardoso AC, Asselah T, Nicolas-Chanoine MH, Vidaud M, Valla D, Bedossa P, Marcellin P. High rates of HBsAg seroconversion in HBsAg-positive chronic hepatitis B patients responding to interferon: a long-term follow-up study. *J Hepatol* 2009; 50: 1084-92.
- [14] Iloeje UH, Yang HI, Chen CJ. Natural history of chronic hepatitis B: what exactly has REVEAL revealed? *Liver Int* 2012; 32: 1333-41.
- [15] Heathcote EJ, Marcellin P, Buti M, Gane E, De Man RA, Krastev Z, Germanidis G, Lee SS, Flisiak R, Kaita K, Manns M, Kotzev I, Tchernev K, Buggisch P, Weilert F, Kurdas OO, Shiffman ML, Trinh H, Gurel S, Snow-Lampart A, Borroto-Esoda K, Mondou E, Anderson J, Sorbel J, Rousseau F. Three-year efficacy and safety of tenofovir disoproxil fumarate treatment for chronic hepatitis B. *Gastroenterology* 2011; 140: 132-43.
- [16] Giannelli G, Bergamini C, Marinosci F, Fransvea E, Napoli N, Maurel P, Dentico P, Antonaci S. Anti fibrogenic effect of IFN- α 2b on hepatic stellate cell activation by human hepatocytes. *J Interferon Cytokine Res* 2006; 26: 301-8.
- [17] Tasci I, Mas MR, Vural SA, Deveci S, Comert B, Alcigir G, Mas N, Akay C, Bozdayi M, Yurdaydin C, Bozkaya H, Uzunalimoglu O, Isik AT, Said HM. Pegylated interferon-alpha plus taurine in treatment of rat liver fibrosis. *World J Gastroenterol* 2007; 13: 3237-44.