

Case Report

Value of ^{18}F -FDG-PET/CT in ocular sebaceous adenocarcinoma: a case report and literature review

Xin Zhao¹, Guang-Fa Wang¹, Kui Zhao¹, Hong-Guang Cui², Wei Ding³

Departments of ¹PET-CT, ²Ophthalmology, ³Pathology, The First Affiliated Hospital, College of Medicine, Zhejiang University, 310003, China

Received August 21, 2015; Accepted October 13, 2015; Epub October 15, 2015; Published October 30, 2015

Abstract: Ocular sebaceous adenocarcinoma is a rare malignant tumor. We report an unusual case of orbital sebaceous adenocarcinoma in a 48-year-old woman. The patient underwent F-18 2-fluoro-2-deoxy-glucose positron emission tomography/computed tomography (^{18}F -FDG-PET/CT) to determine the initial clinical stage. ^{18}F -FDG-PET/CT showed strong uptake in the orbital lesion, but neither regional lymphatic nor distant metastases were seen. ^{18}F -FDG-PET/CT plays a role in the diagnosis, staging, restaging, and follow-up of ocular sebaceous carcinoma, although its application has some limitations in other primary and ocular malignancies due to the rarity of ocular sebaceous carcinoma.

Keywords: ^{18}F -FDG-PET/CT, ocular neoplasm, sebaceous adenocarcinoma, diagnosis

Introduction

^{18}F -FDG-PET/CT is a useful technique in diagnosis, staging, restaging, and assessment of treatment and follow-up of many malignancies, including lymphoma, head and neck cancer, lung cancer, and colorectal carcinoma [1-5], and it is often better than single routine work-ups, such as magnetic resonance imaging (MRI) [6] and computed tomography (CT) [7]. PET/CT is also an effective diagnostic work-up in carcinoma of unknown primary (CUP) [8-10]. However, there are few reports about the use of PET/CT in the field of ophthalmic neoplasms [11-13]. PET/CT is used mainly for detecting ocular lymphoma, melanoma, and metastatic carcinoma [14-17]. To the best of our knowledge, there are only two previous reports on the use of PET/CT in ocular sebaceous cell carcinoma [12, 18].

Here, we report an additional case of ocular sebaceous adenocarcinoma detected by PET/CT. We also review the English-language literature pertaining to the use of ^{18}F -FDG-PET/CT in ophthalmic neoplasms.

Case report

A 48-year-old female presented with exophthalmos of the left eye for half a year and was admitted to the ophthalmology department of our hospital in October 2014. She also had epiphora (watery eye) and occasional diplopia. Since onset, she was free of other symptoms, except for the gradually progressive lump in the left orbit accompanied by pain. Her visual acuity was 20/20 right eye (RE) and 20/25 left eye (LE). The irregular and hard mass was located at the left outer canthus extending into the left orbit. The left eye was displaced anteromedially. No preauricular or cervical lymph nodes were palpable. Laboratory examination showed that the level of the tumor marker carcinoembryonic antigen was 8.4 ng/ml. A MRI T1 image showed an abnormal signal outside the left orbital extraconal orbital compartment, with an obscure boundary, and involvement of the eyelid (**Figure 1**). Computed tomography (CT) showed an irregular mass in the left orbit involving the left superior rectus, external rectus, and inferior oblique muscle and medial rectus muscle (**Figure 2**). Subsequently, the patient underwent

The role PET/CT in orbital tumor

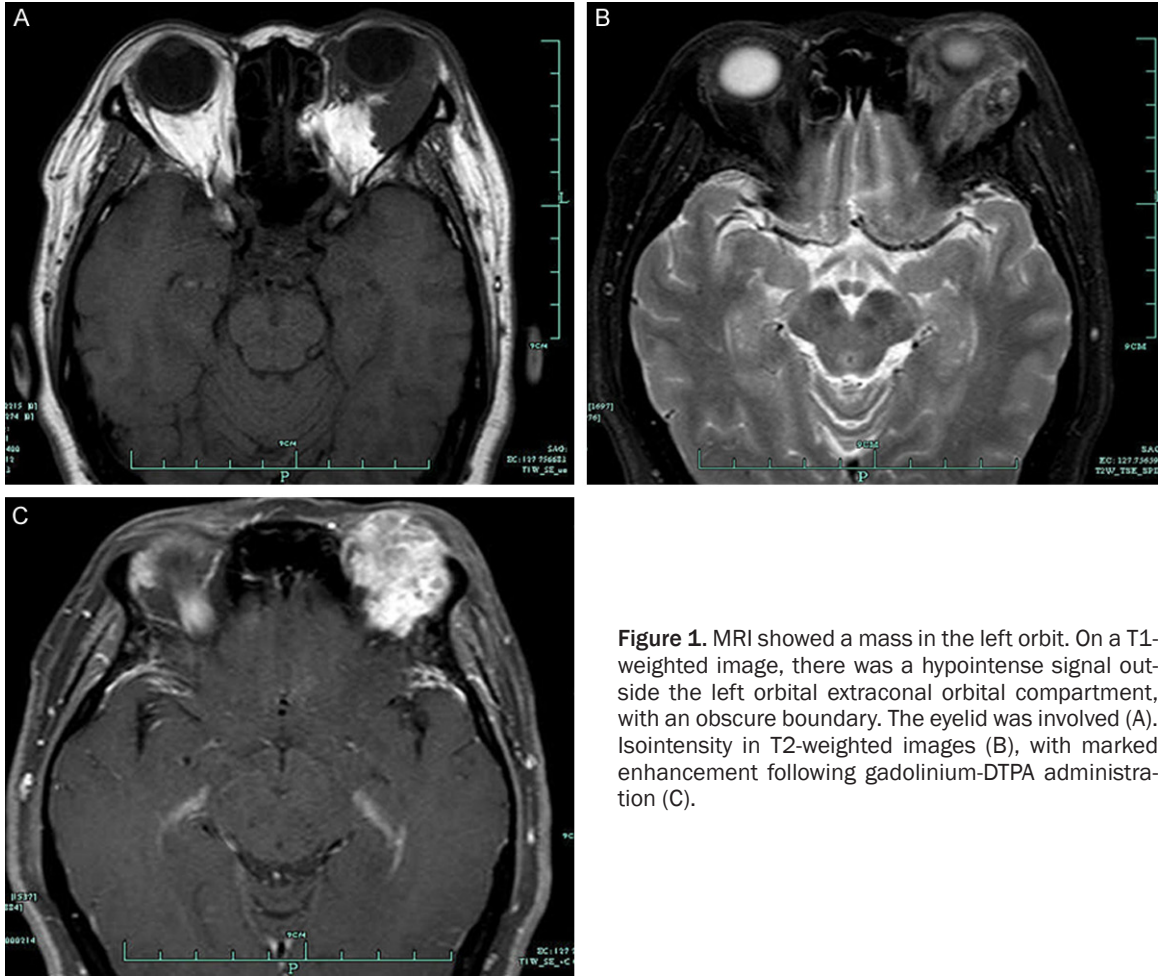


Figure 1. MRI showed a mass in the left orbit. On a T1-weighted image, there was a hypointense signal outside the left orbital extraconal orbital compartment, with an obscure boundary. The eyelid was involved (A). Isointensity in T2-weighted images (B), with marked enhancement following gadolinium-DTPA administration (C).

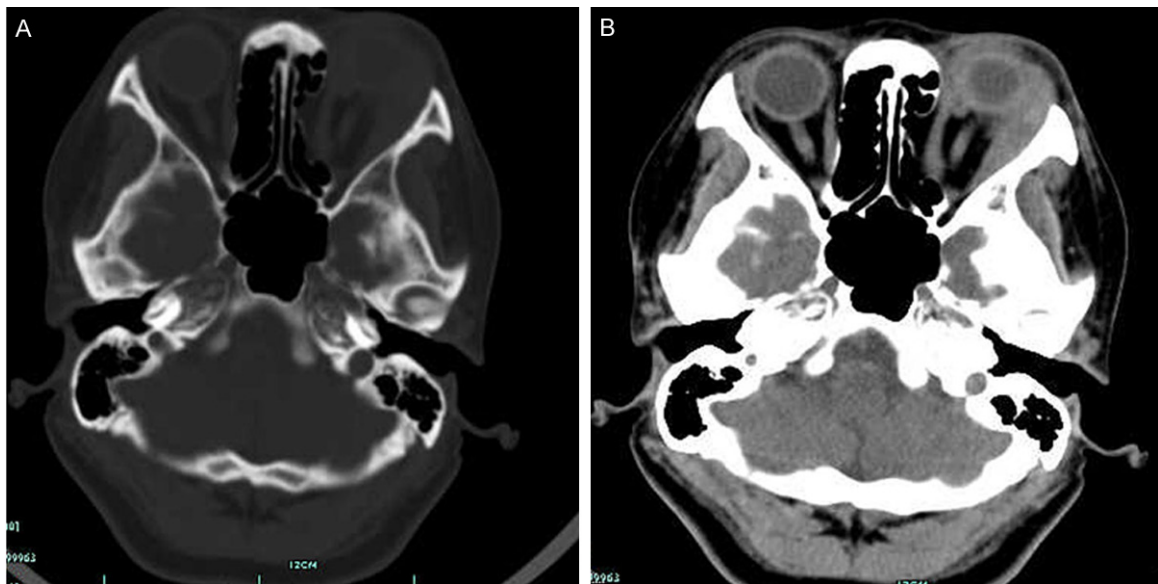


Figure 2. CT showed an irregular mass in the left orbit involving the left superior rectus, external rectus, and inferior oblique and medial rectus muscles (A). (B) Contrast-enhanced imaging showed that the tumor was enhanced markedly.




Figure 3. ^{18}F -FDG-PET/CT showed a lesion in the left orbit. A: Coronal PET images showed increased intensity in the left orbit. The maximum calculated standardized uptake value (SUV_{max}) of the lesion was approximately 3.1. B: Coronal CT images showed a soft tissue mass with irregular contours in the left orbit. The lesion extended along the lateral side of the eyeball. The superior rectus, lateral rectus, internal rectus, and inferior oblique muscle of the eyeball were involved, but the circumambient bone was not broken. C: The combination PET/CT image showed increased uptake of ^{18}F -FDG in the left orbit.

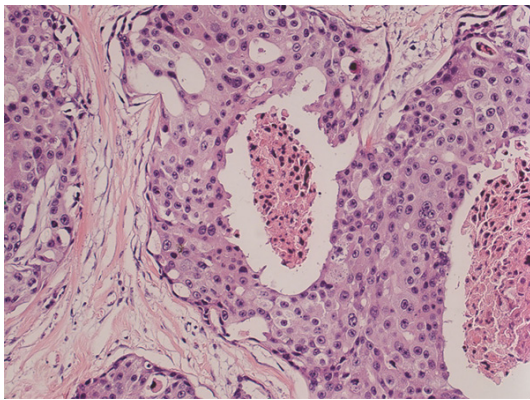


Figure 4. Postoperative pathologic results of the surgical specimens. The lesions are arranged in nests, and abundant and eosinophilic cytoplasm, with large nuclei and mitoses, an obvious nucleolus, and cell nests of acne, can be seen in the necrosis (H&E, original magnification $\times 40$).

a combined ^{18}F -FDG-PET/CT whole-body scan. PET/CT showed a soft tissue mass with irregular contours in the left orbit with high signal; the maximum calculated standardized uptake value (SUV_{max}) of the lesion was approximately 3.1. The lesion extended along the lateral side of the eyeball; the superior rectus, lateral rectus, internal rectus, and inferior oblique muscle of the eyeball were involved, but the circumambient bone was not broken (**Figure 3**). The patient was hospitalized for further treatment. An incisional biopsy revealed a poorly differentiated adenocarcinoma of sebaceous gland origin. An exenteration was performed to remove the left globe, eyelids, and anterior orbit. Postoperative pathological results demonstrated a poorly differentiated adenocarcinoma and

tumor invasion of the eyeball, nerve, muscle, and lacrimal gland (**Figure 4**).

The patient's postoperative course was unremarkable, and she received postoperative radiotherapy (50 Gy). At the 1-year follow-up, her exenteration revealed well-healed incisions, with no signs of recurrence or distant metastasis.

Discussion

Sebaceous carcinoma accounts for approximately 0.2~4.6% of all malignant neoplastic cutaneous lesions [19]. Ocular sebaceous adenocarcinoma accounts for 0.6-10.2% of all eyelid malignancies [20, 21]. The entity is easily misdiagnosed. Ocular sebaceous carcinoma may present as a nodular mass or diffuse thickening of the eyelids, and it always involves adjacent structures including the caruncle and bulbar conjunctiva [20]. In the present case, the tumor invaded the eyeball, nerve, muscle, and lacrimal gland. In some cases, ocular sebaceous carcinomas are multicentric [20, 22]. Some patients also have a history of multiple sebaceous neoplasms, called Muir-Torre syndrome [20].

There are some limitations to the routine work-up for detecting recurrent cases, multicentric lesions, and multiple sebaceous neoplasms [18]. PET/CT may play a role in the diagnosis, detecting the recurrent or multicentric lesions of ocular sebaceous carcinoma [12, 18]. There have been only two previous reports of the use of PET/CT in ocular sebaceous cell carcinoma [12, 18]. Krishna et al reported that ^{18}F -FDG-

PET/CT was used to stage two cases of ocular sebaceous cell carcinoma successfully and helped direct the treatment to preserve two eyes and vision in both patients [12]. Sahai et al found that ^{18}F -FDG-PET/CT may accurately detect local recurrence and nodal metastasis [18]. In extraocular sebaceous carcinomas, ^{18}F -FDG-PET/CT also accurately predicted nodal status and precisely determined the initial stage of a sebaceous carcinoma originating in the parotid gland [23]. To our knowledge, this is the third report on the detection of primary ocular sebaceous carcinoma by ^{18}F -FDG-PET/CT. In the present case, ^{18}F -FDG-PET/CT accurately detected that the tumor extended along the lateral side of the eyeball, and that the superior rectus, lateral rectus, internal rectus, and inferior oblique muscle of the eyeball were involved, but the circumambient bone was not broken. In previous reports of ocular sebaceous carcinoma, the SUV_{max} values were 2.8 [12] and 3.1 [18], respectively. In the present case, the SUV_{max} was 3.1. These values of SUV_{max} in primary ocular sebaceous carcinoma appear to be lower than that in sebaceous carcinoma of the parotid gland ($\text{SUV}_{\text{max}}=16.9$). In other primary ocular and orbital tumors, no standard cutoff value for SUV_{max} has been found to differentiate benign from malignant lesions successfully [24]. However, the FDG metabolic activity of primary ocular melanoma is relatively high, and previous studies used SUV_{max} values of 2.5 [25] or 4 [26] as the cutoff for differentiating melanoma from benign lesions. Recently, Papastefanou et al found that a $\text{SUV}_{\text{max}} >4$ in primary uveal melanoma might be more helpful in identifying monosomy 3 and gain of chromosome 8 tumors [27].

Local recurrence, lymph metastasis, and distant metastasis may be observed in ocular sebaceous carcinoma after treatment [18, 20, 28]. ^{18}F -FDG-PET/CT may be a useful follow-up workup test for ocular sebaceous carcinoma. As mentioned above, Sahai et al found that ^{18}F -FDG-PET/CT accurately detected preauricular nodal metastasis with the third local recurrence [18]. The patient received wide local excision of the primary site and ipsilateral extended modified neck region III dissection with total parotidectomy and postoperative adjuvant radiotherapy (45 Gy in 25 fractions). However, the patient experienced another recurrence

and underwent right exenteration with temporalis flap reconstruction and postoperative adjuvant reirradiation (30 Gy in 15 fractions). The patient survived more than 9 years after the initial diagnosis [18]. Baek et al used ^{18}F -FDG-PET/CT to evaluate lymph node metastasis in 15 cases of periobital malignancies, 5 of which were sebaceous carcinomas of the eyelid. Over a follow-up period of 11-240 months, they detected regional lymph node metastasis in 4 cases of five sebaceous carcinomas, including 2 cases in the intra-parotid lymph nodes and 2 cases in the intra-parotid, peri-parotid, and upper jugular cervical lymph nodes. There were no metastases in 5 cases, as detected by ^{18}F -FDG-PET/CT. The value of SUV_{max} ranged from 2.2 to 8.1 (mean 5.3) for these five sebaceous carcinomas. The authors suggested that an SUV of 2.0 in the lymph nodes is an appropriate cut-off value to determine the presence of metastasis. According to these findings, an accurate surgical plan was devised in two patients, and the extent of surgery was changed in another two other patients. These five patients survived without any evidence of disease for 50, 20, 10, 3, and 8 months, respectively, after the last treatment. In this study, they found that in all 15 cases of periobital malignancy, ^{18}F -FDG-PET/CT had a sensitivity of 100%, while CT had a sensitivity of 57% for nodal metastasis in level-by-level analysis. ^{18}F -FDG-PET/CT had a specificity of 97%, a positive predictive value of 93%, a negative predictive value of 100%, and a diagnostic accuracy of 98%, while the CT values for these same parameters were 97%, 89%, 82%, and 84%, respectively. ^{18}F -FDG-PET/CT correctly predicted N staging with an accuracy of 100%, while CT was only 83% accurate with regard to the impact on patient care and the extent of surgery for regional lymph nodes. Treatment decisions were modified by ^{18}F -FDG-PET/CT in 39% of patients, and thus it was concluded that ^{18}F -FDG-PET/CT provides useful information on the management of regional lymph node metastases in patients with periobital malignancies [28].

Although ^{18}F -FDG-PET/CT plays a role in the diagnosis, staging, restaging, and follow-up of ocular sebaceous carcinoma, there are some limitations for its application in other primary and ocular malignancies due to the rarity of ocular sebaceous carcinoma. The application

of PET/CT for orbital disease has been hampered by several technical factors. In an anatomic site of only 30 mm³, the current image resolution of 5-8 mm may be too cumbersome to detect very small intraorbital tumors. The background activity of the nearby cerebral hemispheres may attract attention away from a weakly positive orbital signal. Moreover, the extraocular muscles and lacrimal glands exhibit some background FDG uptake, making it potentially difficult to distinguish normal background uptake from tumor uptake. In a study of uveal melanoma, glucose consumption was heterogeneous [29], even in tumors large enough to be visualized, and therefore could not be used reliably to exclude the presence of viable tumors. This type of imaging may not be specific for cancer, since ¹⁸F-FDG-PET/CT shows uptake in benign infectious and inflammatory lesions and fractures, as well as in foci of malignancy. Some authors found that ¹⁸F-FDG-PET can determine the malignancy of orbital tumors but cannot distinguish malignant tumors from inflammatory diseases such as pseudotumors [11]. Thus, care must be taken when evaluating orbital lesions using ¹⁸F-FDG-PET/CT.

Conclusion

¹⁸F-FDG-PET/CT plays a role in the diagnosis, staging, restaging, and follow-up of ocular sebaceous carcinoma, although its application has some limitations in other primary and ocular malignancies due to the rarity of ocular sebaceous carcinoma.

Disclosure of conflict of interest

None.

Address correspondence to: Dr. Kui Zhao, Department of PET-CT, The First Affiliated Hospital, College of Medicine, Zhejiang University, 310003, China. Tel: 86-13819180021; Fax: 86-571-87-236228; E-mail: zhaokuizh@163.com

References

[1] Zhou ML, Zhao K, Zhou SH, Wang QY, Zheng ZJ and Lu ZJ. Role of PET/CT in the diagnosis, staging, and follow-up of a nasal-type natural killer T-cell lymphoma in the larynx: a case report and literature review. *Int J Clin Exp Med* 2014; 7: 4483-4491.

[2] Liu LP, Zhang XX, Cui LB, Li J, Yang JL, Yang HN, Zhang Y, Zhou Y, Tang X, Qi S, Fang Y, Zhang J and Yin H. Preliminary comparison of diffusion-weighted MRI and PET/CT in predicting histologic type and malignancy of lung cancer. *Clin Respir J* 2015; [Epub ahead of print].

[3] Wang J, Zheng J, Tang T, Zhu F, Yao Y, Xu J, Wang AZ and Zhang L. A Randomized Pilot Trial Comparing Position Emission Tomography (PET)-Guided Dose Escalation Radiotherapy to Conventional Radiotherapy in Chemoradiotherapy Treatment of Locally Advanced Nasopharyngeal Carcinoma. *PLoS One* 2015; 10: e0124018.

[4] Kawase T, Naka G, Kubota K, Sakashita B and Takeda Y. NUT Midline Carcinoma in Elderly Patients: Usefulness of ¹⁸F-FDG-PET/CT for Treatment Assessment. *Clin Nucl Med* 2015; 40: 764-5.

[5] Artiko V, Odalovic S, Sobic-Saranovic D, Petrovic M, Stojiljkovic M, Petrovic N, Kozarevic N, Grozdic-Milojevic I and Obradovic V. Can (18)F-FDG-PET/CT scan change treatment planning and be prognostic in recurrent colorectal carcinoma? A prospective and follow-up study. *Hell J Nucl Med* 2015; 18: 35-41.

[6] Maffione AM, Lopci E, Bluemel C, Giammarile F, Herrmann K and Rubello D. Diagnostic accuracy and impact on management of (18)F-FDG-PET and PET/CT in colorectal liver metastasis: a meta-analysis and systematic review. *Eur J Nucl Med Mol Imaging* 2015; 42: 152-163.

[7] Adkins D, Ley J, Dehdashti F, Siegel MJ, Wildes TM, Michel L, Trinkaus K and Siegel BA. A prospective trial comparing FDG-PET/CT and CT to assess tumor response to cetuximab in patients with incurable squamous cell carcinoma of the head and neck. *Cancer Med* 2014; 3: 1493-1501.

[8] Zhao K, Luo XM, Zhou SH, Liu JH, Yan SX, Lu ZJ, Yang SY, Lin LL and Dong MJ. ¹⁸F-fluorodeoxyglucose positron emission tomography/computed tomography as an effective diagnostic workup in cervical metastasis of carcinoma from an unknown primary tumor. *Cancer Biother Radiopharm* 2012; 27: 685-693.

[9] Zhang XX, Zhao K, Zhou SH, Wang QY, Liu JH and Lu ZJ. Metastatic squamous cell carcinoma of the gingiva appearing as a solitary branchial cyst carcinoma: diagnostic role of PET/CT. *Int J Clin Exp Pathol* 2014; 7: 7059-7063.

[10] Elboga U, Kervancioğlu S, Sahin E, Basibuyuk M, Celen YZ and Aktolun C. Utility of F-18 fluorodeoxyglucose positron emission tomography/computed in carcinoma of unknown primary. *Int J Clin Exp Pathol* 2014; 7: 8941-8946.

The role PET/CT in orbital tumor

- [11] Miyamoto J, Tatsuzawa K, Owada K, Kawabe T, Sasajima H and Mineura K. Usefulness and limitations of fluorine-18-fluorodeoxyglucose positron emission tomography for the detection of malignancy of orbital tumors. *Neurol Med Chir (Tokyo)* 2008; 48: 495-499; discussion 499.
- [12] Krishna SM, Finger PT, Chin K and Lacob CE. 18-FDG PET/CT staging of ocular sebaceous cell carcinoma. *Graefes Arch Clin Exp Ophthalmol* 2007; 245: 759-760.
- [13] Tafti BA, Shaba W, Li Y, Yevdayev E and Berenji GR. Staging and follow-up of lacrimal gland carcinomas by 18F-FDG-PET/CT imaging. *Clin Nucl Med* 2012; 37: e249-252.
- [14] Zanni M, Moulin-Romsee G, Servois V, Validire P, Bénamor M, Plancher C, Rouic LL, Dendale R, Vincent-Salomon A, Asselain B, Sahli R and Decaudin D. Value of 18FDG PET scan in staging of ocular adnexal lymphomas: a large single-center experience. *Hematology* 2012; 17: 76-84.
- [15] Papastefanou VP, Islam S, Szyszko T, Grantham M, Sagoo MS and Cohen VM. Metabolic activity of primary uveal melanoma on PET/CT scan and its relationship with monosomy 3 and other prognostic factors. *Br J Ophthalmol* 2014; 98: 1659-1665.
- [16] Iwaya Y, Takenaka K, Akamatsu T, Yamada Y, Haba S, Matsuda K, Nakazawa H, Muraki T, Kaneko Y, Ito T, Sano K, Arakura N, Tanaka E and Ishida F. Primary gastric diffuse large B-cell lymphoma with orbital involvement: diagnostic usefulness of 18F-fluorodeoxyglucose positron emission tomography. *Intern Med* 2011; 50: 1953-1956.
- [17] Karunanithi S, Chakraborty PS, Dhull VS, Nadarajah J, Salunkhe NR and Kumar R. Ciliary body metastasis in a patient with non-small cell lung carcinoma—incidental detection with 18F-FDG-PET/CT. *Nucl Med Rev Cent East Eur* 2014; 17: 40-43.
- [18] Sahai P, Shukla NK, Arora S and Mohanti BK. Recurrent sebaceous carcinoma of the eyelid: Outcome following post-operative reirradiation. *Head Neck* 2015; [Epub ahead of print].
- [19] Buitrago W and Joseph AK. Sebaceous carcinoma: the great masquerader: emerging concepts in diagnosis and treatment. *Dermatol Ther* 2008; 21: 459-466.
- [20] Yin VT, Merritt HA, Sniegowski M and Esmali B. Eyelid and ocular surface carcinoma: diagnosis and management. *Clin Dermatol* 2015; 33: 159-169.
- [21] Bolm I, Babaryka G, Moergel M, Al-Nawas B and Kämmerer PW. Multifocalmetastasizing extra-ocular facial sebaceous carcinoma as diagnostic challenge: case report and systematic review. *J Maxillofac Oral Surg* 2015; 14: 331-337.
- [22] Muqit MM, Foot B, Walters SJ, Mudhar HS, Roberts F and Rennie IG. Observational prospective cohort study of patients with newly diagnosed ocular sebaceous carcinoma. *Br J Ophthalmol* 2013; 97: 47-51.
- [23] Kumabe A, Kawase T, Miura K, Tada Y, Masubuchi T, Kamata SE, Tanada S, Kubo A, Tajima Y and Shigematsu N. Sebaceous carcinoma of the parotid gland: F-18 FDG PET/CT findings. *Clin Nucl Med* 2010; 35: 260-262.
- [24] Hui KH, Pfeiffer ML and Esmali B. Value of positron emission tomography/computed tomography in diagnosis and staging of primary ocular and orbital tumors. *Saudi J Ophthalmol* 2012; 26: 365-371.
- [25] Finger PT and Chin KJ. [(18)F] Fluorodeoxyglucose positron emission tomography/computed tomography (PET/CT) physiologic imaging of choroidal melanoma: before and after ophthalmic plaque radiation therapy. *Int J Radiat Oncol Biol Phys* 2011; 79: 137-142.
- [26] Finger PT, Kurli M, Reddy S, Tena LB and Pavlick AC. Whole body PET/CT for initial staging of choroidal melanoma. *Br J Ophthalmol* 2005; 89: 1270-1274.
- [27] Papastefanou VP, Islam S, Szyszko T, Grantham M, Sagoo MS and Cohen VM. Metabolic activity of primary uveal melanoma on PET/CT scan and its relationship with monosomy 3 and other prognostic factors. *Br J Ophthalmol* 2014; 98: 1659-1665.
- [28] Baek CH, Chung MK, Jeong HS, Son YI, Choi J, Kim YD, Choi JY, Kim HJ and Ko YH. The clinical usefulness of (18)F-FDG-PET/CT for the evaluation of lymph node metastasis in periorbital malignancies. *Korean J Radiol* 2009; 10: 1-7.
- [29] Modorati G, Lucignani G, Landoni C, Freschi M, Trabucchi G, Fazio F and Brancato R. Glucose metabolism and pathological findings in uveal melanoma: preliminary results. *Nucl Med Commun* 1996; 17: 1052-1056.