

## Original Article

# Rare malposition following left jugular vein catheterization: Case reports and a literature review

Lin Wang<sup>1</sup>, Zhangsuo Liu<sup>1</sup>, Changan Wang<sup>2</sup>, Dongwei Liu<sup>1</sup>, Yiqiang Yuan<sup>2</sup>

<sup>1</sup>Department of Nephropathy, The First Affiliated Hospital of Zhengzhou University, Zhengzhou 450052, China;

<sup>2</sup>Department of Nephropathy, Zhengzhou Cardiovascular Hospital, Zhengzhou 450016, China

Received August 21, 2015; Accepted October 13, 2015; Epub October 15, 2015; Published October 30, 2015

**Abstract:** The number of patients requiring chronic hemodialysis via a tunneled cuffed catheter is increasing. The right internal jugular vein (IJV) is generally the preferred site of percutaneous insertion. In certain situations, for example, in patients with a history of multiple access failures, catheterization of the left IJV is an important option. In this report, we present two rare cases of catheter malposition after left IJV catheterization; catheter adjustments, with the help of chest radiographs, resulted in a positive outcome in both cases. These cases exemplify the difficulties associated with left IJV catheterization, of which there are few reports in the published literature.

**Keywords:** Central venous catheter, catheter malposition, complications, left internal, jugular vein catheterization

## Introduction

Central venous catheter (CVC) is commonly used for vascular access in uremic patients, and has advantages over other delivery methods for hemodialysis. Various complications of central venous catheterization have been reported; the most common complications arise from insertion of the catheter, and include pneumothorax, misplacement, arterial puncture, local infection, hematomas, and thrombosis [1-4]. Malposition of a central venous hemodialysis catheter is an uncommon complication (4%), requiring appropriate management [5].

Physicians often prefer to cannulate the right internal jugular vein (IJV) to establish central venous access, since it provides a more direct path to the superior vena cava. The left IJV is considered the second best option in patients with a history of multiple access failures. During insertion of a left IJV catheter, two 90° turns must be negotiated: the junction with the subclavian vein, and the junction with the superior vena cava (**Figure 1**) [6, 7]. It is reported that cannulation of the left IJV is more difficult, and is associated with a higher incidence of malpositions than cannulation of the right IJV [3, 4]. One reason is that the left brachiocephalic vein

is longer and has a greater number of smaller tributaries than the right brachiocephalic vein [2, 3]. Another reason is that the tributaries of the left anastomose with the brachiocephalic vein [8]; a CVC can be misdirected into small tributaries of central veins, particularly when inserting a catheter on the left.

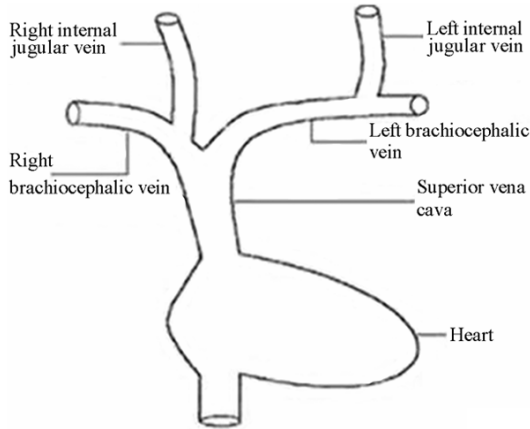
This report described two cases of malposition of a CVC during left IJV catheterization, despite the use of fluoroscopy for confirmation of positioning. The main reasons of this rare complication of central venous catheterization and the methods of prevention are discussed below. Although the complications we describe are uncommon, information on sources of malposition can be extracted to increase the quality of catheterization during insertion, particularly in difficult cases.

## Case presentation

### Patient 1

A 63-year-old woman with end-stage renal disease had been maintained on hemodialysis since 2009. This study was conducted in accordance with the declaration of Helsinki. This study was conducted with approval from the

## Complications during the left IJV catheterization



**Figure 1.** Anatomic diagram for catheterization at the jugular vein. It shows that left internal jugular vein catheter negotiate two 90 turns.

Ethics Committee of Zhengzhou University. Written informed consent was obtained from all participants. The patient experienced repeated arteriovenous fistula (AVF) thrombosis. A tunneled cuffed catheter was therefore inserted in the right IJV for long-term dialysis in October 2009. On July 11 2013, the tunneled cuffed catheter fell out from the percutaneous tunnel, without any symptoms. Ultrasonography detected narrowing of the right IJV (**Figure 2A**). We attempted to place the tunneled cuffed catheter in the left IJV instead, after obtaining consent from the patient. Under local anesthesia, a long-term, dual-lumen, cuffed, hemodialysis catheter (BARD, diameter: 14.5 Fr, cuff to tip 40 cm) was inserted through the left IJV, and tunneled subcutaneously at the left prothorax area. Gentle suction using a needle showed no blood from the venous lumen. A chest radiograph was evaluated for evidence of malfunction of the catheter. The chest radiograph (**Figure 2B**) showed that the venous lumen back-folded along its route, and the catheter was extracted. During the second attempt at insertion, we chose to insert a tunneled cuffed catheter close to the original site of catheterization. We attempted to adjust the direction and depth of the catheter, after which blood was observed to return satisfactorily during withdrawal of the needle. A chest radiograph taken after the procedure showed the position of the replacement catheter (**Figure 2C**).

### Patient 2

A 38-year-old woman had been maintained on hemodialysis for 6 months due to stage V dia-

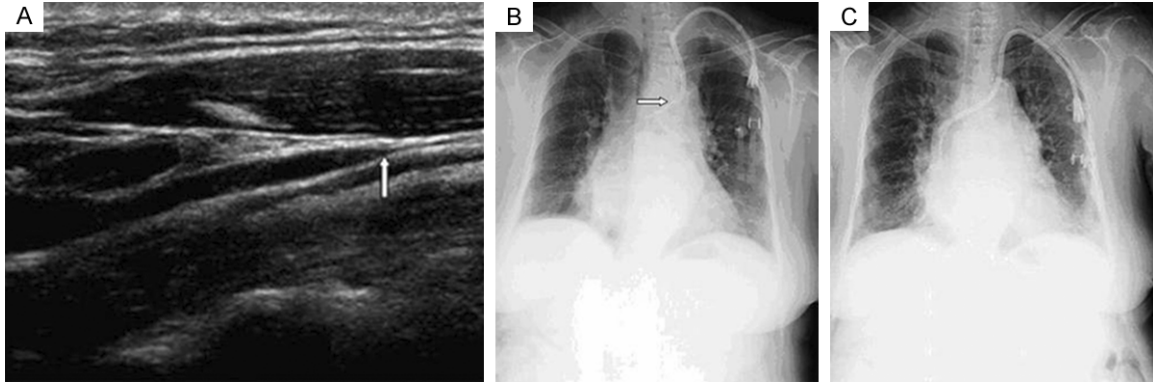
beti nephropathy. This study was conducted in accordance with the declaration of Helsinki. This study was conducted with approval from the Ethics Committee of Zhengzhou University. Written informed consent was obtained from all participants. In January 2013, a catheter was placed in the right IJV to allow temporary access for dialysis. She rejected to exchange for permanent catheter after the AVF failed and her dialysis course turned to be difficult. We had to remove the catheter because of frequent, serious catheter infections. Ultrasonography, performed after removal of the catheter, detected a thrombus in the lumen of the IJV (**Figure 3A**). A dual-lumen cuffed catheter was placed in the left IJV under the former procedure. Aspirated blood through each lumen and little flow of the lumen returned with passage. The chest radiograph (**Figure 3B**) showed that both of the lumens had lost their traces and turned to the right IJV. After removal of the catheter, we extended the guide-wire and reintroduced the catheter by passing it over the wire. Blood returned smoothly during withdrawal of the needle. Chest radiography performed after the procedure, showed that the catheter remained malpositioned (**Figure 3C**). However, the catheter was found to work well during the follow-up period, and so further adjustment was not attempted.

### Discussion

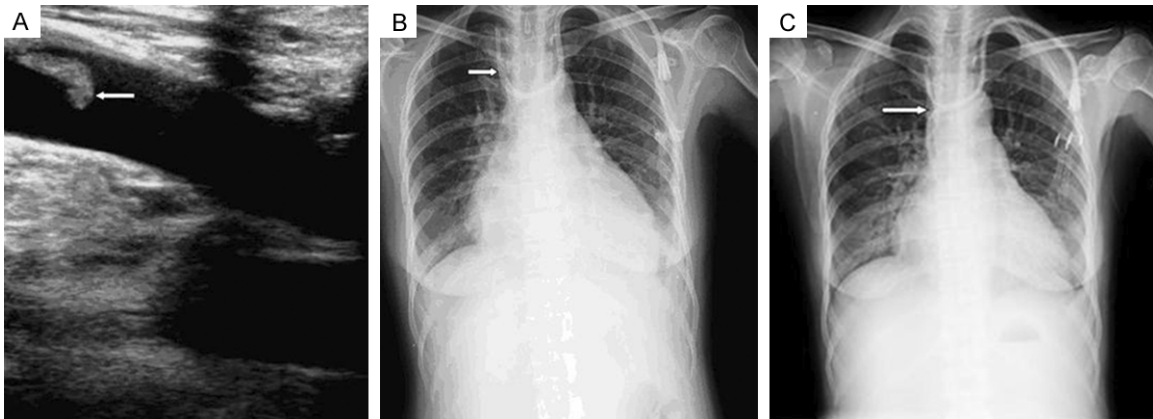
The left IJV is selected when cannulation of the right IJV is unsuccessful or is contraindicated for hemodialysis patients with exhaustive AVF. The anatomy of the left IJV makes cannulation of the left IJV more difficult, with a higher incidence of complications than cannulation of the right IJV. The resultant complications are painful and possibly fatal [9-12]. Previous studies indicate that 15% patients with a tunneled CVC experience complications, whereas 10% of patients who undergo right IJV cannulation experience complications [11, 13, 14].

There are reports of hemodialysis catheter malposition when insertion was attempted through a vein distal to central vein that was hypoplastic, stenosed, or thrombosed [4, 12-15]. Malposition of the catheter is a relatively uncommon complication (4%), which results in catheter malfunction and requires appropriate management (re-positioning, replacement, or removal) [16-20]. The anatomic disadvantage

## Complications during the left IJV catheterization



**Figure 2.** Graphs showing the adjustment of the catheter resulting from kinking of one lumen in 63-year-old female. A. The stenotic right jugular vein. The ultrasonography detects that narrowing along the right internal jugular vein; arrow indicates stenosis. B. Malposition location of a left internal jugular vein catheter. The chest film shows venous lumen reentrant in the vein; Arrow indicates fold. C. Corrected location of the left internal jugular vein catheter. The chest radiograph shows that lumens are at the right position.



**Figure 3.** Graphs showing the adjustment of the catheter resulting from bifurcation of one lumen in 38-year-old female. A. The thrombotic right jugular vein. It reveals there is thrombus in the lumen of right internal jugular vein. Arrow indicates thrombus. B. The misplacement of a left internal jugular vein catheter. The chest film shows both of lumens's inadvertent insertion into the right internal jugular vein. C. Corrected location of the left internal jugular vein catheter. The chest film shows the left internal jugular vein catheter is still at malposition after replacement.

highlights the need for radiographic confirmation of proper catheter location, which has been described in the two cases reported here.

In the first case, the arterial lumen of the catheter was withdrawn and overlapped at the junction of the left brachiocephalic vein and the superior vena cava; this may have resulted from a stenosis or bend in the left brachiocephalic vein. Subsequent adjustments to the site and direction and depth of the puncture needle with the help of radiographic examination resulted in a good outcome. In the second case, the issue was the inadvertent insertion of the catheter into the right IJV. Both lumens of

the catheter were directed away from the left IJV to the junction of the left brachiocephalic vein and superior vena cava, and then to the contralateral IJV. Following adjustment, the arterial lumen still could not be induced unsatisfactorily, adverse into the right IJV after reinsertion, though the arterial lumen induced properly. Therefore, it was not incomprehensible that the split-tip catheters used in these two cases were aberrantly placed.

Tunneled CVCs for dialysis are classified into either split-tipped (dual-lumen) or step-tipped (single-lumen) catheters, depending on the catheters tip design. Differences in design

## Complications during the left IJV catheterization

influence the incidence of complications; malposition is more likely to occur when inserting a split-tipped catheter through the left IJV, because left-sided catheter placement is anatomically more challenging due to the longer passage and more tortuous route [20, 21]. Dual-lumen catheters inserted through the left IJV are at risk of bifurcating between lumens that pass through a curved path [2, 5, 20]. It appears that the arterial lumen is easier to kink, overlap or reentrant in the vein even step to other vein for lack of wire guidance during the advance of catheter, while venous lumen is not for the guide-wire passing through. Thus, we consider that the step-tipped catheter is less likely to be malpositioned than the split-tipped catheter, although dual-lumen catheters are widely believed to reduce recirculation rates in comparison with single-lumen catheters [22].

As presented in our report, the type of catheter should be taken into account to avoid the bifurcation or offsetting of the lumens while advancing the catheter. Given that dual-lumen catheters are associated with a higher incidence of divarication during insertion, single-lumen catheters may be more suitable for use in left IJV cannulation. Our findings show that the step-tipped catheters would be the preferred choice for left IJV cannulation, and split-tipped catheters seem more susceptible to failure. To our knowledge, this observation has not been reported in the literature.

Meanwhile, the guide-wire plays an important role in steering the successful placement of catheter in the left IJV. If the wire kinks, enters another vein inadvertently, or is too short, the catheter tends to become misplaced or obstructed following the guidance, as in our second case. Non-thrombotic causes of catheter dysfunction include migration and kinking of a wire or port rotation, which can be confirmed on imaging [4]. Chest radiographs reveal the aberrant positioning of the guide-wire or the catheter. Our findings support those previously reported that mention the importance of chest radiographs for the detection of anatomic variants and for judging the placement of the catheter after the procedure [4, 23]. Furthermore, our clinical findings indicate that plain chest radiographs or fluoroscopy can verify correct positioning after advancing the wire before insertion of the lumen. Imaging mid-way thro-

ugh the procedure is invaluable for assessing the position of the tip, and guiding the next adjustment after the insertion. Therefore, radiography can provide real-time imaging during the course of insertion of the lumen into the vessel.

In the two cases presented here, analysis of the malposition increased our understanding of left-sided catheter placement, maximizing the success of central venous access device placement, and minimizing the risk of potential complications. There are few similar case reports in the literature. A limitation of our report would be the small number of patients, which makes generalization of the findings difficult.

### Conclusion

Our findings support those of previous studies that have shown that left IJV placement is associated with higher failure rates and more complications. Single-body catheter is the least favorable one with the help of the imaging examination in the insertion. Radiography during the procedure is invaluable.

### Acknowledgements

This study is supported by grants from the National Key Technology Research and Development (R and D) Program of the Ministry of Science and Technology of China (No. 2013BAI09B04), and National Basic Research Program of China 973 Program (No. 2012CB517600).

### Disclosure of conflict of interest

None.

**Address correspondence to:** Zhangsuo Liu, Department of Nephropathy, The First Affiliated Hospital of Zhengzhou University, No. 1 Jianshe East Road Zhongyuan District, Zhengzhou 450052, China. Tel: +86 371 60609557; Fax: +86 371 60609558; E-mail: zsliucn@126.com

### References

- [1] Gupta P, Guleria S and Sharma S. Mediastinal haematoma: a rare complication following insertion of central venous catheter. *Indian J Chest Dis Allied Sci* 2011; 53: 225-228.
- [2] Skandalos I, Michalopoulos A, Iatrou K and Sombolos K. Hemodialysis catheter malposi-

## Complications during the left IJV catheterization

- tion induced by a brachiocephalic vein stenosed stent. *Ren Failure* 2013; 35: 541-543.
- [3] Bannon MP, Heller SF and Rivera M. Anatomic considerations for central venous cannulation. *Risk Manag Healthc Policy* 2011; 4: 27-39.
- [4] Ahn SJ, Kim HC, Chung JW, An SB, Yin YH, Jae HJ and Park JH. Ultrasound and fluoroscopy-guided placement of central venous ports via internal jugular vein: retrospective analysis of 1254 port implantations at a single center. *Korean J Radiol* 2012; 13: 314-323.
- [5] Skandalos I, Hatzibaloglou A, Evagelou I, Ntitsias T, Samaras A, Visvardis G, Mavromatidis K and Karamoshos K. Deviations of placement/function of permanent central vein catheters for hemodialysis. *Int J Artif Organs* 2005; 28: 583-590.
- [6] Ash SR. Advances in tunneled central venous catheters for dialysis: design and performance. *Semin Dial* 2008; 21: 504-515.
- [7] Shiao CC, Chu TW, Hung JJ, Hong PJ, Yang CL and Kao JL. An unusual left-sided tunneled catheter in a hemodialysis patient. *Ther Apher Dial* 2012; 16: 106-107.
- [8] Sakan S, Basić-Jukić N, Kes P, Stern-Padovan R and Perić M. Malposition of central venous dialysis catheter in the right internal mammary vein in uremic patient: case report. *Acta Clin Croat* 2011; 50: 623-626.
- [9] Stolic RV and Stolic DZ. A left jugular vein catheter for hemodialysis malpositioned in right brachiocephalic vein. *Iran J Kidney Dis* 2012; 6: 98.
- [10] Moeinipour AA, Amouzesi A and Joudi M. A rare central venous catheter malposition: a case report. *Anesth Pain Med* 2014; 4: 160-169.
- [11] Sulek CA, Blas ML and Lobato EB. A randomized study of left versus right internal jugular vein cannulation in adults. *J Clin Anesth* 2000; 12: 142-145.
- [12] Mrozek N, Lautrette A, Timsit JF and Souweine B. How to deal with dialysis catheters in the ICU setting. *Ann Intensive Care* 2012; 2: 48.
- [13] Yaacob Y, Nguyen DV, Mohamed Z, Ralib AR, Zakaria R and Muda S. Image-guided chemoport insertion by interventional radiologists: a single-center experience on periprocedural complications. *Indian J Radiol Imaging* 2013; 23: 121-125.
- [14] Vats HS. Complications of catheters: tunneled and nontunneled. *Adv Chronic Kidney Dis* 2012; 19: 188-194.
- [15] Kayashima K, Habe K and Imai K. Left internal jugular venipuncture in real-time ultrasound-guided pediatric central venous cannulation. *Masui* 2012; 61: 1105-1107.
- [16] Alemohammad M. Central venous catheter insertion problem solving using intravenous catheter: technical communication. *Tehran Univ Med J* 2013; 70: 724-728.
- [17] Shams Vahdati S. Should a Double-Lumen Catheter be withdrawn? *J Cardiovasc Thorac Res* 2011; 3: 97-99.
- [18] Ghatak T, Azim A, Baronia AK and Muzaffar SN. Malposition of central venous catheter in a small tributary of left brachiocephalic vein. *Emerg Trauma Shock* 2011; 4: 523-525.
- [19] Gyaninder PS, Hemanshu P and Bapura KR. Malposition of internal jugular vein catheter into contralateral internal jugular vein: an uncommon position. *Indian J Anaesth* 2012; 56: 205-207.
- [20] Tan EK and Tan SG. The permanent catheter. *Hemodial Int* 2014; 18: 522-524.
- [21] Chintu MR, Chinnappa S and Bhandari S. Aberrant positioning of a central venous dialysis catheter to reveal a left-sided partial anomalous pulmonary venous connection. *Vasc Health Risk Manag* 2008; 4: 1141-1143.
- [22] Lee HJ, Park SW, Chang IS, Jo YI, Park JH, Lee JH, Yun IJ, Hwang JJ and Lee SA. A comparison of standard dual-tip hemodialysis catheter split lumen hemodialysis catheter. *Clin Imaging* 2013; 37: 251-255.
- [23] Venugopal AN, Koshy RC and Koshy SM. Role of chest X-ray in citing central venous catheter tip: A few case reports with a brief review of the literature. *J Anaesthesiol Clin Pharmacol* 2013; 29: 397-400.