

Original Article

Comparison of CO₂ laser and conventional laryngomicrosurgery treatments of polyp and leukoplakia of the vocal fold

Ya Zhang^{1*}, Gengtian Liang^{2*}, Na Sun¹, Linlin Guan³, Yang Meng³, Xiaoyan Zhao³, Li Liu², Guangbin Sun⁴

¹Department of Nurse, Gongli Hospital, Pudong New Area, Shanghai 200135, China; ²Department of Otolaryngology, Affiliated Third Hospital of Wuhan University, Wuhan 430060, China; ³Department of Otolaryngology, Ningxia Medical University, Ningxia 750004, China; ⁴Department of Otolaryngology, Huashan Hospital, Fudan University, Shanghai 200040, China. *Equal contributors.

Received August 22, 2015; Accepted October 13, 2015; Epub October 15, 2015; Published October 30, 2015

Abstract: The efficacies of CO₂ laser and conventional laryngeal microsurgery for vocal cord benign (vocal cord polyp) and precancerous (vocal cord leukoplakia) lesions were compared. Patients with bilateral vocal cord polyps (n = 60) and leukoplakia (n = 30) were divided randomly into two groups. One group was treated with throat microsurgical instruments and underwent routine lesion resection (conventional group) and the other with CO₂ laser (laser group). For the subjective assessment, the tools GRABS and VHI were used. The objective assessment, A multi-dimensional voice program module for voice spectrum analysis was used. The laser group was slightly worse than the conventional group 1 week post-surgery by stroboscopic findings. The subjective and objective data of the two groups pre-and post-surgery showed that the voice recovery of the laser group was significantly better than that of the conventional group ($P < 0.05$). CO₂ laser laryngeal microsurgery for vocal cord polyp and leukoplakia can improve significantly the vocal cord morphology and pronunciation quality. The procedure is especially more effective than conventional surgery in patients with vocal cord leukoplakia.

Keywords: Laser surgery, vocal cords, benign lesions, precancerous lesions, polyps

Introduction

The increasing environmental pollution and interpersonal factors that lead to the improper use of voice resulted in the rising incidence of vocal cord diseases. In the early 1900s, Hirano et al. [1] proposed the famous vocal fold vibration (body-cover) theory. According to vocal cord stroboscope and scanning electron microscopy, the vocal fold is divided into five layers. Only the mucosal epithelial and Reinke's space can produce vibration and a beautiful tone. The increasing demand of voice quality, the fine microstructure of vocal cords, and the body-cover theory require minimal invasive surgery. The effective treatment of vocal cord diseases will result in unchanged sound function and normal voice. Two types of voice microsurgical techniques were developed gradually, namely, the conventional laryngeal microsurgery, which involves the use of cold instru-

ments, such as a throat knife, scissors, pliers, and other instruments, and the laryngeal laser micro-surgery. The advantages of CO₂ laser in the treatment of early laryngocarcinoma have been recognized by scholars [2]. However, its treatment of benign laryngeal diseases and precancerous lesions, such as vocal cord polyps, vocal nodules and vocal cord leukoplakia, remain controversial. Shapshay [3-5] believed that CO₂ laser treatment induces thermal damage causing deepened surgical trauma and affecting the healing of wounds. Benninger et al. [6] suggested that the proper CO₂ laser mode and duration slightly influences early wound healing during the treatment of vocal cord benign diseases. Moreover, in this study, the long-term effects of CO₂ laser were found to be similar to those of laryngeal microsurgical instruments, i.e., no difference was found between their wound healings, and no greater damage to the vocal cords was found. Studies

have been reported on the suitability and efficacy of laser surgery on benign vocal cords and precancerous lesions compared with the conventional surgery.

In the current study, the CO₂ laser and conventional laryngeal microsurgery treatments of the vocal cord benign and precancerous lesions were compared. The groups were assessed through vocal cord morphological observation, mucosal wave vibration comparative analysis, and comparative analysis of their objective and subjective voice assessment parameters.

Materials and methods

Clinical data

From October 2008 to May 2011, 60 patients with bilateral vocal cord polyps in our department were selected and divided into two groups. Thirty patients with bilateral vocal cord leukoplakia were also divided into two groups. A total of 56 males and 34 females, 30 to 70 years of age (average age of 56.5 years), were included in the study. This study was conducted in accordance with the declaration of Helsinki. This study was conducted with approval from the Ethics Committee of Shanghai Gongli Hospital (No: 2010011). Written informed consent was obtained from all participants.

Procedures

General anaesthesia, endotracheal intubation, and oral import laryngoscopy (Karl Storz GmbH & Co. KG, Tuttlingen, Germany) were performed to expose the throat. The operating microscope (HiR1000/FS3233; Moller-Wedel GmbH, Wedel, Germany) with 400 mm objective lens was adjusted, and the lesions were revealed clearly. The cold laryngoscopic microsurgical instruments (Explorent GmbH, Tuttlingen, Germany) included microsurgical laryngeal forceps, scissors, and other instruments.

In the laser treatment group, a CO₂ laser (40-C; Lumenis Ltd., Yokneam, Israel), with 1035 nm wavelength, 2 W power, and under single pulse or continuous super-pulse mode, was used. Under a binocular microscope, the full glottic lesions were exposed, and the saline gauzes were placed at the infraglottic portion to protect the endotracheal intubation and prevent laser damage. The laser was connected to the microscope via a coupler. The main laser tech-

nical parameters were as follows: laser emission, super-pulse mode; output power, 2 W pulse; interval, 0.2 ms; and spot diameter, approximately 0.2 mm. The different surgical methods achieved cutting and vaporization effect. The cutting method was used for patients with vocal cord polyp. The vocal cord polyp was dragged to the midline using forceps, and then polypectomy was applied along the edge of the vocal cords. Adrenaline cotton balls were used to clean the surgical and charring wounds. The wounds were coated with antibiotic ointment. A small amount of precancerous lesions were taken for pathological examination. According to the scope and depth of the vocal cord lesions from the lesion edge, 1 mm to 2 mm CO₂ laser surgery was performed. Mucosal epithelial exfoliation was performed in patients with vocal cord leukoplakia. After submucosal injection of saline containing epinephrine in the vocal cord, cortical lesion exfoliation was completed by laser with 3 W power and intermittent pulses, and superficial lamina propria was reserved. For mucosal stripping, if the vocal cord submucosal injection of saline containing epinephrine could make the mucosa float, the lesions would not invade the sound ligament. The laser power set to 3 W at intermittent pulse mode from the lesion edge at 1 mm to 2 mm laser incised the mucosa, and the laryngeal forceps dragged incised the mucosal edge and submucosal lesions and its surrounding mucosal resection up to the lamina propria. The sound ligament and vocal muscle were protected. This procedure is suitable for wide lesions and moderate to severe dysplasia vocal cord leukoplakia. During surgery, the inspired oxygen concentration should be reduced to less than 30% and the normal mucosa should be protected, especially the anterior commissure mucosa.

Microlaryngeal surgical instruments were used in the conventional surgery group. For the vocal cord polyps, the polyps were pulled to the midline by polyp forceps, and polypectomy was performed along the vocal cord edge. For vocal cord leukoplakia, the mucosa was cut after submucosal injection of saline containing epinephrine to the vocal cord from the lesion edge at 1 mm to 2 mm. The epithelial mucosal lesions were exfoliated by microsurgical stripping. Mucosa lesions and a part of shallow lamina propria were removed, except for the sound ligament and vocal muscle.

Treatment of vocal cord polyp and leukoplakia

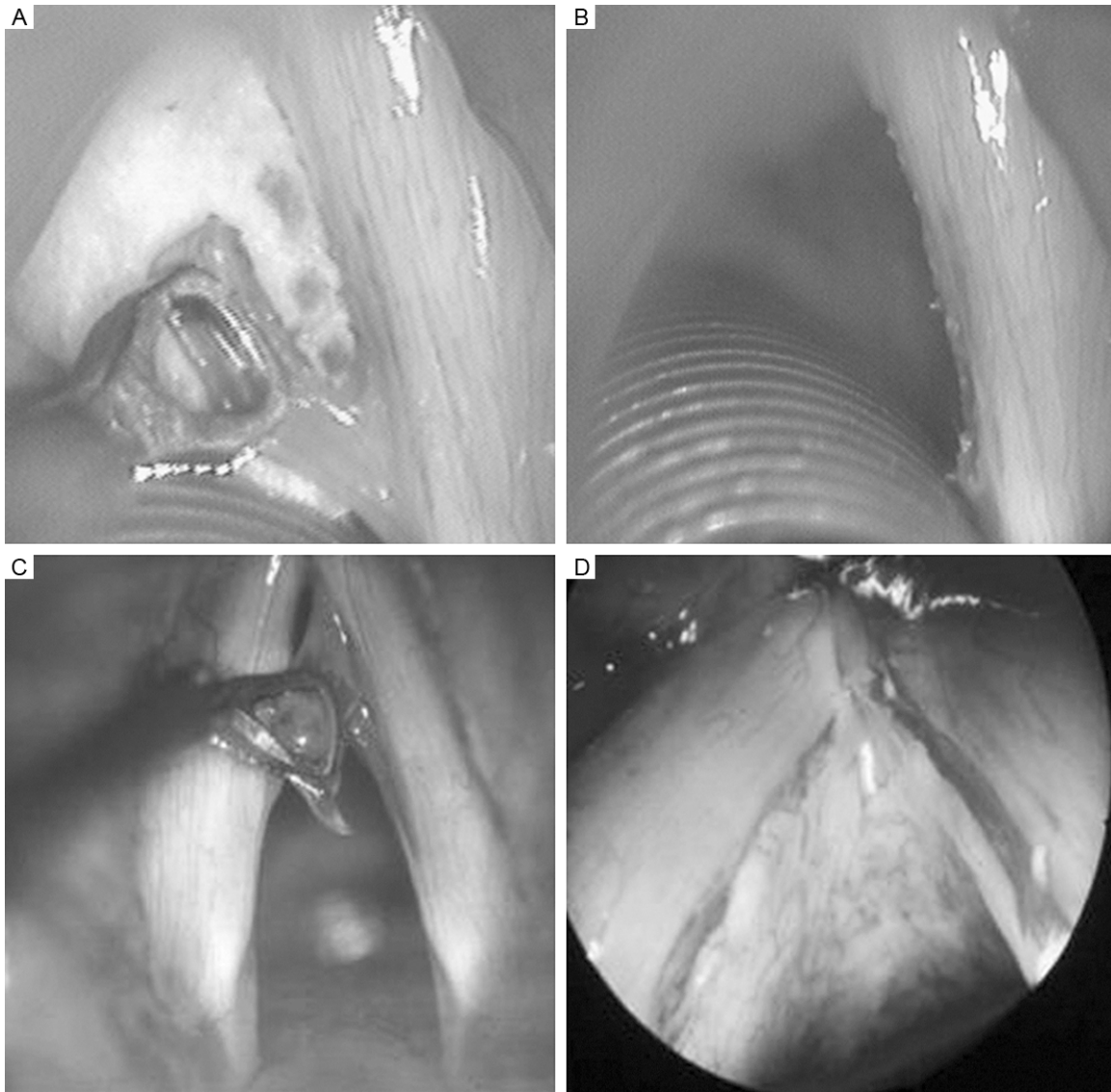


Figure 1. Surgical removal of vocal cord polyps. A, B. Laser group, immediate direct laryngoscopy showed flat and clean vocal cord edge; C, D. Conventional group, vocal cord wound had a little bleeding, and vocal cord edge was not neat enough.

The procedure needed intraoperative intravenous infusion of 10 mg dexamethasone to prevent laryngeal edema. After surgery, the two groups immediately underwent electronic laryngoscopy, stroboscopic laryngoscopy, GRABS, and VHI subjective ratings and objective voice analysis. The procedures were repeated at 1 wk, 1 month, and 3 months post-surgery.

Voice assessment

The voices of the patients were assessed before surgery as well as at 1 week, 1 month, and 3 months post-surgery. For the subjective

assessment, the tools used were Japan Logopedics and voice, the developed GRABS assessment standards, and patient's self-assessment of voice disability Index (VHI) [7]. For the objective assessment, under environmental noise below 45 dB sound pressure level, a megaphone was placed before the patient's mouth 15 cm away. The patient was made to pronounce [a:] thrice with a natural and comfortable voice. The vowel sounds were extracted (1.0 seconds) with the sampling frequency at 44.1 KHz. The voice signal was entered into a computer via a preamplifier, through CSL model 4150 system (United States

Treatment of vocal cord polyp and leukoplakia

Table 1. Preoperative, postoperative subjective assessment of laser and conventional group (vocal cord polyp) ($\bar{x} \pm s$)

Time	Laser group				Cold instruments group			
	G	R	B	VHI	G	R	B	VHI
Before surgery	2.3±0.4	2.4±0.4	2.3±0.5	33.5±15.2	2.4±0.5	2.3±0.6	2.3±0.3	33.8±19.2
After surgery 1 week	2.1±0.6	2.0±0.3 ^Δ	1.8±0.4	25.3±6.2 ^Δ	1.8±0.9 ^Δ	1.7±0.7 ^Δ	1.9±0.4	26.1±8.8 ^Δ
After surgery 1 month	1.3±0.5*	1.6±0.5 ^Δ	0.9±0.3*	17.7±2.3*	1.2±0.5*	1.4±0.5 ^Δ	1.0±0.3*	16.2±2.3*
After surgery 3 months	1.0±0.4*	1.1±0.5*	0.6±0.1*	9.4±6.0*	1.1±0.5*	1.1±0.5*	0.6±0.2*	10.4±6.7*
P value	0.001	0.044	0.000	0.000	0.000	0.026	0.000	0.000

Note: Compared with the preoperative ^Δ $P < 0.05$, * $P < 0.01$.

Kay Elemetrics), in the Kay Computerized Speech Lab software. A multi-dimensional voice program module for voice spectrum analysis was used. The evaluation parameters included fundamental frequency perturbation, amplitude perturbation, fundamental frequency perturbation quotient, amplitude perturbation quotient, noise harmonic ratio, and maximum phonation time.

Statistical analysis

The SPSS14.0 software was used for variance analysis. Data were expressed as mean \pm standard deviation ($\bar{x} \pm s$), and $P < 0.05$ was considered as statistical significant.

Results

Comparison of surgical efficacy for vocal cord polyp

Each patient underwent resection once, with neat cutting edge under the microscope without any postoperative complications. Immediate direct laryngoscopy showed the flat clean vocal cords edge in the laser group (**Figure 1A** and **1B**). The vocal cord wounds of the conventional group wound showed slight bleeding and their vocal cords edge was not neat enough (**Figure 1C** and **1D**). One week post-surgery, the vocal cord wounds of the laser group were covered by a small amount of pseudomembrane under electronic laryngoscopy with flat edges, contrary to the other group, which had smooth vocal cord wounds smooth, but the vocal cords edges were not neat enough. Then, 1 and 3 months post-surgery, the electronic laryngoscope morphological examination implied a good healing of the wounds, and the glottic close showed no significant difference. Mucosa wave approached nor-

mal under stroboscopic laryngoscope. The objective and subjective assessments of the patients' voice indicate the following. One week post-surgery, the voice of the conventional group began to improve ($P < 0.05$ or $P < 0.01$). After 3 months, significant improvements were found ($P < 0.01$). By contrast, the voice of the laser group slightly worsened 1 wk post-surgery. After 1 and 3 months, the voice function in the laser group improved significantly ($P < 0.05$ or $P < 0.01$). During these periods, the subjective and objective testing data analysis of the two groups indicated no significant difference (**Tables 1** and **2**).

Comparison of surgical efficacy in vocal cord leukoplakia

In the laser group, the postoperative immediate direct laryngoscopy of the patients with vocal cord leukoplakia showed that the wound edges of the exposed vocal cord were neat, clean, and without bleeding (**Figure 2A** and **2B**). In the conventional group, the vocal cord wounds exhibited slight bleeding, and the vocal cord wound edges were not tidy (**Figure 2C** and **2D**). One week post-surgery, the vocal cord wounds of the laser group were smooth and protected by pseudomembrane, as shown by electronic laryngoscopy. By contrast, vocal cord wounds of the conventional group were only partially covered by pseudomembrane. The vocal cord surface was uneven, and vocal cord edges were not neat enough. Then, 1 and 3 months post-surgery, a video laryngoscope morphological examination showed good wound healing of the laser group, and their glottic close was also better than that of the conventional group (**Figure 3A** and **3B**). Stroboscopic laryngoscopy showed that the laser group's mucosal wave was close to normal, with bilateral vibrations better than those of the conventional group. The voice

Treatment of vocal cord polyp and leukoplakia

Table 2. Preoperative, postoperative objective assessment of laser and conventional group (vocal cord polyp) ($\bar{x} \pm s$)

Time	Laser group						Cold instruments group					
	Jitt (%)	PPQ (%)	Shim (%)	APQ (%)	NHR	MPT, s	Jitt (%)	PPQ (%)	Shim (%)	APQ (%)	NHR	MPT, s
Before surgery	5.51±1.04	3.11±0.37	8.37±1.21	7.21±1.76	0.48±0.11	9.6±1.2	5.60±1.15	3.22±0.45	8.15±2.05	7.39±1.70	0.50±0.13	9.9±2.1
After surgery 1 week	4.28±1.02	2.87±0.48	5.32±1.05*	4.91±0.87*	0.43±0.09	11.9±2.1*	3.88±1.85*	2.79±0.68	4.36±2.55*	3.76±1.07*	0.31±0.09*	11.3±3.9*
After surgery 1 month	3.25±0.65*	1.30±0.50#	3.26±0.75#	3.65±0.58#	0.29±0.07#	13.8±3.2#	3.15±0.62#	1.27±0.50#	3.56±0.96#	3.71±0.78#	0.27±0.08#	14.0±2.6#
After surgery 3 months	1.73±0.52#	0.58±0.14#	3.24±0.89#	3.43±0.63#	0.21±0.03#	15.2±3.4#	1.68±0.49#	0.61±0.34#	3.14±0.65*	3.03±0.72#	0.26±0.03#	15.7±3.2#
P value	0.001	0.001	0.000	0.000	0.000	0.000	0.000	0.000	0.000	0.000	0.162	0.000

Note: Compared with the preoperative, * $P < 0.05$, # $P < 0.01$.

Table 4. Preoperative, postoperative objective assessment of laser and conventional group (vocal leukoplakia) ($\bar{x} \pm s$)

Time	Laser group						Cold instruments group					
	Jitt (%)	PPQ (%)	Shim (%)	APQ (%)	NHR	MPT, s	Jitt (%)	PPQ (%)	Shim (%)	APQ (%)	NHR	MPT, s
Before surgery	5.23±1.05	3.29±0.58	8.21±1.25	7.28±1.98	0.48±0.17	10.2±1.2	5.31±1.25	3.32±0.55	7.95±2.35	7.49±1.80	0.51±0.19	9.9±1.1
After surgery 1 week	4.68±1.02	2.99±0.48	7.32±1.05	4.91±0.8#	0.43±0.09	11.9±2.1	4.48±1.85	2.79±0.68	6.76±2.45	5.96±1.07	0.40±0.09	10.3±3.9
After surgery 1 month	2.14±0.6#	2.26±0.5*	3.06±0.7*	2.87±0.5#	0.19±0.0#	13.6±3.2*	3.05±0.6*	2.56±0.5*	3.26±0.9*	3.68±0.7*	0.37±0.0*	12.9±2.6*
After surgery 3 months	1.23±0.5#	1.58±0.1#	2.54±0.6#	2.46±0.4#	0.13±0.0#	15.5±3.4#	1.93±0.4#	1.81±0.3#	3.24±0.8*	3.03±0.7#	0.26±0.0#	13.7±3.2*
P value	0.001	0.001	0.000	0.000	0.000	0.000	0.000	0.001	0.000	0.000	0.006	0.000

Note: Compared with the preoperative, * $P < 0.05$, # $P < 0.01$.

Treatment of vocal cord polyp and leukoplakia

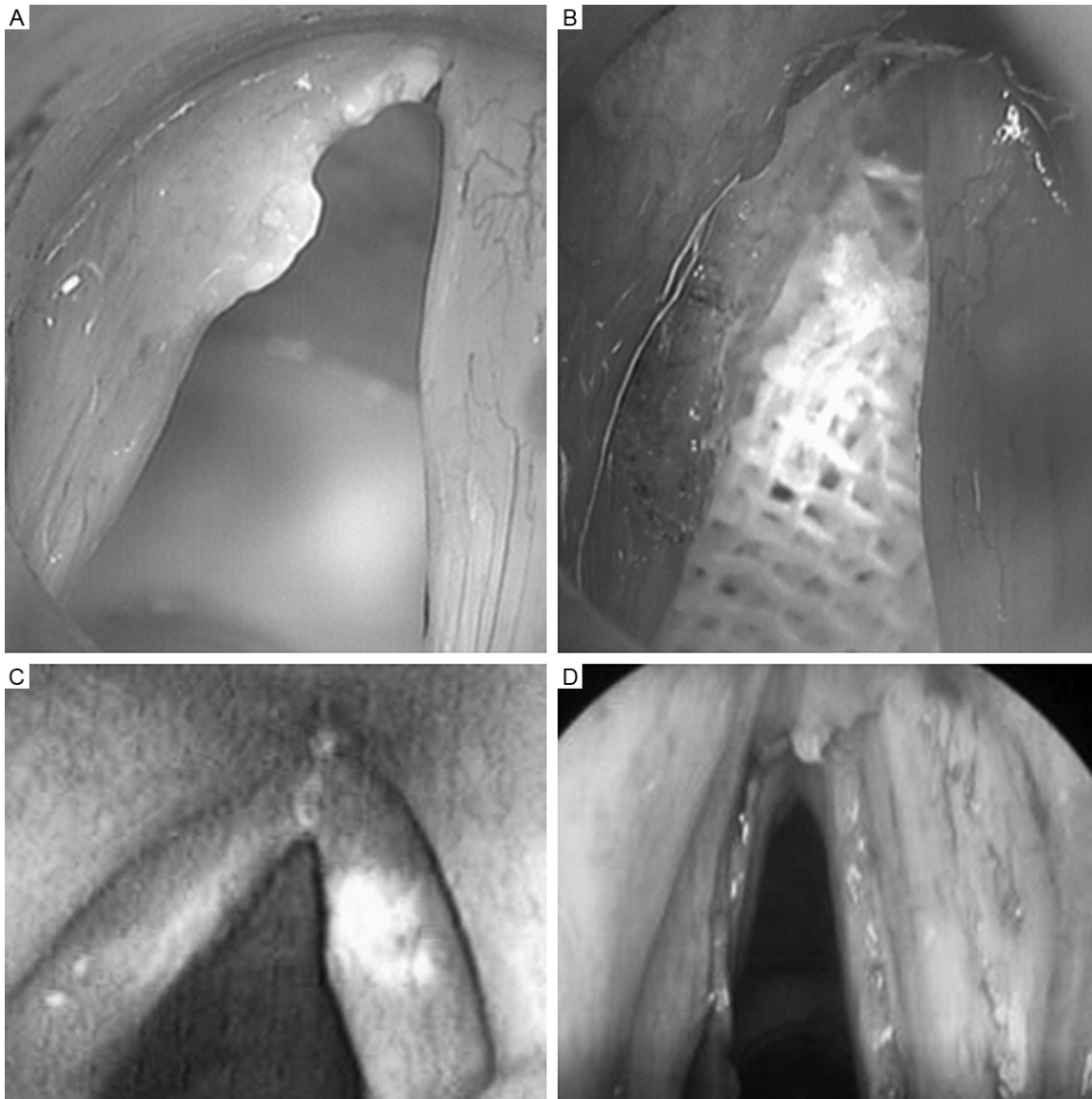


Figure 2. Surgery on vocal cord leukoplakia. A, B. Laser group, immediate direct laryngoscopy showed the exposed vocal cords wound edges were neat and clean, with no bleeding; C, D. Conventional group, vocal cords wounds had a little bleeding, and vocal cord wound edges were not tidy.

would be affected by the coagulation and charring of vocal cord tissue under laser treatment with continuous oscillation mode. However, Benninger et al. [8] suggested that, at early stages, low-powered CO₂ laser (1 W to 3 W), under super-pulse mode and with 0.1 s effective time, has mild impact on benign lesions, such as vocal cord polyps, vocal nodules, vocal cord cyst. However, the long-term effects (> 1 month) are not worse than the conventional laryngeal microsurgical instruments. The wound healings from both treatments in the current study showed no differences, and no

greater damage on the vocal cords was found. Although laser generates high power density, its brightness and strength can be adjusted. In the case of correct focal length, the cutting edge can destroy only a 5 μm to 100 μm radius area and approximately 5 to 10 cells, as long as a piece of soaked cotton is placed to protect bilateral incisions. Only 1 to 5 cells would be damaged because the surgery is extremely accurate, and the normal tissue would not be damaged [9-11]. Benninger et al. [6] examined 37 cases with vocal cord polyps, nodules, or cysts in a prospective randomized study. In this

Treatment of vocal cord polyp and leukoplakia

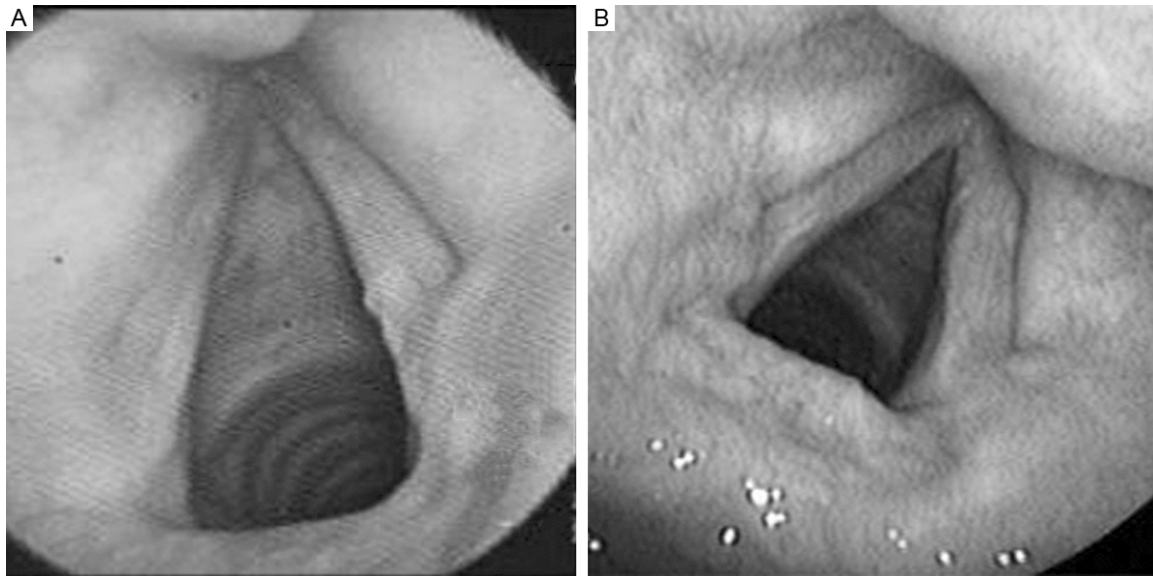


Figure 3. Surgery on vocal cord leukoplakia (3 months after surgery). A. Laser group; B. Conventional group. In laser group, there was a well wound healing, and the glottic close was better than conventional group. Group (vocal leukoplakia) ($\bar{x} \pm s$).

Table 3. Preoperative, postoperative subjective assessment of laser and conventional group (vocal leukoplakia) ($\bar{x} \pm s$)

Time	Laser group				Cold instruments group			
	G	R	B	VHI	G	R	B	VHI
Before surgery	2.3±0.4	2.4±0.4	2.2±0.5	32.5±15.2	2.2±0.5	2.3±0.6	2.3±0.3	31.8±19.2
After surgery 1 week	2.5±0.6	2.2±0.3	2.3±0.4	29.3±5.2	2.4±0.9	2.2±0.7	2.3±0.4	28.3±5.8
After surgery 1 month	1.3±0.5 [#]	1.3±0.4 [#]	0.9±0.3 [*]	11.2±2.3 [*]	1.4±0.5 [#]	1.7±0.5	1.9±0.3	16.2±2.3 [#]
After surgery 3 months	1.0±0.3 [*]	1.0±0.5 [*]	0.6±0.2 [*]	9.4±6.0 [*]	1.1±0.4 [#]	1.1±0.5 [#]	0.6±0.2 [*]	12.4±6.7 [#]
P value	0.001	0.001	0.000	0.000	0.002	0.024	0.000	0.000

Note: Compared with the preoperative, [#] $P < 0.05$, ^{*} $P < 0.01$.

objective and subjective assessment indicators had no obvious improvement 1 wk post-surgery, whereas the sound of the two groups began to improve gradually and significantly 1 and 3 months post-surgery ($P < 0.05$ or $P < 0.01$). The preoperative and postoperative subjective and objective detection data from the two groups showed significant difference, but the laser group recovered better than the conventional group (Tables 3 and 4).

Compare the voice results between laser and cold instrument group. The voice objective and subjective assessment indicators showed to improve significantly 1 and 3 months post-surgery ($P < 0.05$ or $P < 0.01$) for laser group than cold instrument.

This study suggests other superiority of CO₂ laser for benign laryngeal lesion, such as bleed-

ing control, improved mucosal wave, and early recovery, to conventional surgery. We will discuss below.

In all cases, postoperatively followed-up, 1 times a month. 2 cases recurred in half a year in the conventional cold equipment group of vocal cord polyp and leukoplakia each. Reoperation by laser were performed, followed up postoperatively for 2 years without recurrence.

Discussion

Controversies still surround the advantages of CO₂ laser treatment on laryngeal benign disease and precancerous lesions over the conventional microsurgery. Some scholars [2-4] believed that CO₂ laser thermal damage deepens the surgical trauma and wound healing

study, 21 patients were treated with surgical instruments and microsurgical resection and the rest of patients were treated with CO₂ laser to remove lesions. No difference was found between the healings of the two groups, and the subjective judgment of sound recovery was good. Hence, the assisted technology of CO₂ laser in laryngeal microsurgery compared with surgical instruments the normal vocal cords did not show greater damage. These results are consistent with the results of clinical studies. The current study found that during the early stage (1 wk post-surgery), the recovery of bilateral vocal cord polyp patients in laser group was slightly worse than the conventional surgery group. At the late stage (1 month to 3 months post-surgery), electronic laryngoscopy and stroboscopic laryngoscopy mucosal wave indicated no obvious differences. Based on the voice objective and subjective assessment indicators, the conventional surgery group began to improve ($P < 0.05$ or $P < 0.01$). Three months post-surgery, these indicators improved significantly ($P < 0.01$), but the sound of the laser group was slightly worse than that of the conventional group 1 wk post-surgery. After 1 and 3 months, the voice function of the laser group improved significantly ($P < 0.05$ or $P < 0.01$). However, during the same period, subjective and objective testing data analysis showed no statistically significant difference (**Tables 1 and 2**). These results indicated that in the treatment of vocal cord polyps, CO₂ laser does not adversely affect the recovery of the vocal cords. We believe that CO₂ laser surgical treatment for laryngeal benign disease also has the following advantages: 1. This procedure is highly precise because the jitter induced by long distances cutting of conventional "cold equipments" (such as the throat knife, scissors, and pliers) can be avoided, rendering a more accurate and simpler operation; and 2. The laser beam can close the mucosal surface of the small blood vessels, resulting in and a clearer operative field. Complete lesion removal will then be much easier, leading to a high curing rate.

The early practice of CO₂ laser surgery used continuous wave with a large spot diameter, resulting in relatively large heat damage. With the continuous improvement in laser technology, super-pulsed laser is now applied, and its power and spot size can be adjusted to reduce greatly the degree of surrounding tissue thermal damage, offsetting the thermal damage

caused by delayed healing [4, 12-14]. Therefore, according to the results of our previous animal experiments [14], the advantages of CO₂ laser surgery for vocal cord polyps can be realized compared with conventional microsurgery and should be practiced.

Micro-laryngoscope mucosa endarterectomy and laryngeal laser treatment are the primary approaches in the early intervention treatment of laryngeal precancerous lesions. Laryngeal microsurgery and laser surgery have obvious advantages [15]. No neck incision is performed, and sound functional recovery is good. Microscopic surgery is accurate, and normal tissue and diseased tissue are easy to distinguish for precise excision of throat lesions under direct field. Less bleeding and faster recovery are observed, which are particularly suitable for the elderly without surgical contraindications. This procedure requires a short treatment time and has reasonable cost. Additionally, the resulting malignancy rate is low. Several scholars believed that CO₂ laser treatment can reduce significantly the rate of malignant transformation of precancerous lesions. The development of precancerous lesions to laryngeal cancer is a multi-stage process. CO₂ laser treatment can block the pathological process effectively to prevent disease progression [16-20]. The current study showed that, at the early recovery phase (1 wk post-surgery), no significant difference was found in patients with bilateral vocal cord leukoplakia. At the late recovery phase (1 and 3 months post-surgery), good wound healing in the laser group was shown by electronic laryngoscopy. Stroboscopic laryngoscopy showed that the laser group's mucosal wave was close to normal, with bilateral vibrations better than that of the conventional group. The voice objective and subjective assessment indicators had no obvious improvement 1 wk post-surgery. After 1 and 3 months, sound improved gradually and significantly ($P < 0.05$ or $P < 0.01$). Preoperative and postoperative subjective and objective detection data had statistically significant difference (**Tables 1 and 2**). The voice recovery in the laser group was better than those of the conventional group (**Tables 3 and 4**).

The study selected only one of the benign and precancerous lesions of vocal cords for CO₂ laser efficacy comparison. The efficacy of the surgical procedures in other lesions, such as

vocal nodules, vocal cord cyst, laryngeal papilloma, and laryngeal keratosis psychosis, need further studies.

Conclusion

The experimental results suggested that CO₂ laser laryngomicrosurgery will not cause high impact on the vocal cords for benign vocal cord lesions. For precancerous lesions, it can improve significantly the morphology of vocal cords and the quality of pronunciation. CO₂ laser laryngomicrosurgery is more effective than conventional surgery (cold instruments) and worthy to be promoted.

Acknowledgements

Financial support for this project came from the Fund of Shanghai science and technology committee (14DZ1942008), Health Bureau of Wuhan city (WX12C62), Health Bureau of Shanghai (20134074) and the Appropriate technology of Shanghai Municipal Hospital (SHDC12012202).

Disclosure of conflict of interest

None.

Address correspondence to: Guangbin Sun, Department of Otolaryngology, Huashan Hospital, Fudan University, Shanghai 200040, China. Tel: +86 21 52887052; Fax: +86 21 38821635; E-mail: guangbinsuncn@yeah.net

References

- [1] Hirano S, Minamiguchi S, Yamashita M, Ohno T, Kanemaru S and Kitamura M. Histologic Characterization of Human Scarred Vocal Folds. *J Voice* 2009; 23: 399-407.
- [2] Shapshay SM, Wang Z, Rebeiz EE, Perrault DF Jr and Pankratov MM. A combined endoscopic Co2 laser and external approach for treatment of glottic cancer involving the anterior commissure: an animal study. *Laryngoscope* 1996; 106: 273-279.
- [3] Sataloff RT, Spiegel JR, Hawkshaw M and Jones A. Laser surgery of the larynx: the case for caution. *Ear Nose Throat J* 1992; 71: 593-595.
- [4] Devaiah AK, Shapshay SM, Desai U, Shapira G, Weisberg O, Torres DS and Wang Z. Surgical utility of a new carbon dioxide laser fiber: functional and histological study. *Laryngoscope* 2005; 115: 1463-1468.
- [5] Vaughan CW, Blaugrund SM, Gould WJ, Hirano M, Ossoff R and Sataloff RT. Surgical management of voice disorders. *J Voice* 1988; 2: 176-181.
- [6] Benninger MS. Microdissection or microspot CO2 laser for limited vocal fold benign lesions: a prospective randomized trial. *Laryngoscope* 2000; 110: 1-17.
- [7] Xu W, Li HY, Hu R, Hu HY, Hou LZ, Zhang L, Zhuang PY and Han DM. Analysis of reliability and validity of the Chinese version of voice handicap index (VHI). *Zhonghua Er Bi Yan Hou Tou Jing Wai Ke Za Zhi* 2008; 43: 670-675.
- [8] Benninger MS. Laser surgery for nodules and other benign laryngeal lesions. *Curr Opin Otolaryngol Head Neck Surg* 2009; 17: 440-444.
- [9] Yan Y, Olszewski AE, Hoffman MR, Zhuang P, Ford CN, Dailey SH and Jiang JJ. Use of lasers in laryngeal surgery. *J Voice* 2010; 24: 102-109.
- [10] Li S, Chen L and Tan F. Laryngeal surgery using a CO2 laser: is a polyvinylchloride endotracheal tube safe? *Am J Otolaryngol* 2012; 33: 714-717.
- [11] Zozzaro M, Harirchian S and Cohen EG. Flexible fiber CO2 laser ablation of subglottic and tracheal stenosis. *Laryngoscope* 2012; 122: 128-130.
- [12] Remacle M, Ricci-Maccarini A, Matar N, Lawson G, Pieri F, Bachy V and Nollevaux MC. Reliability and efficacy of a new CO₂ laser hollow fiber: a prospective study of 39 patients. *Eur Arch Otorhinolaryngol* 2012; 269: 917-921.
- [13] Geyer M, Ledda GP, Tan N, Brennan PA and Puxeddu R. Carbon dioxide laser-assisted phonosurgery for benign glottic lesions. *Eur Arch Otorhinolaryngol* 2010; 267: 87-93.
- [14] Zhang Y, Cao LH, Chen Q, Chen XP, Xu WH, Fang Q, Zhang JF, Sun N and Sun GB. Experimental study on different power CO2 laser for vocal cord injury. *Zhonghua Er Bi Yan Hou Tou Jing Wai Ke Za Zhi* 2011; 46: 1039-1041.
- [15] Higgins KM. What treatment for early-stage glottic carcinoma among adult patients: CO2 endolaryngeal laser excision versus standard fractionated external beam radiation is superior in terms of cost utility? *Laryngoscope* 2011; 121: 116-134.
- [16] Hamadah O and Thomson PJ. Factors affecting carbon dioxide laser treatment for oral precancer: a patient cohort study. *Lasers Surg Med* 2009; 41: 17-25.
- [17] Hamadah O and Thomson PJ. Severe laryngeal dysplasia in a 20-year-old nonsmoker treated with CO2 laser excision: a case report and review of the literature. *Photomed Laser Surg* 2010; 28: 115-119.

Treatment of vocal cord polyp and leukoplakia

- [18] Xu W, Han D, Hou L, Zhang L, Yu Z and Huang Z. Voice function following CO2 laser microsurgery for precancerous and early-stage glottic carcinoma. *Acta Otolaryngol* 2007; 127: 637-641.
- [19] Henríquez Alarcón M, Altuna Mariezkurrena X, Estéfano Rodríguez J, Vaquero Pérez M and Algaba Guimerá J. Treatment with CO2 laser of premalignant glottic epithelial lesions. *Acta Otorrinolaringol Esp* 2003; 54: 625-632.
- [20] Remacle M. Treatment with laser CO2 cordectomy and clinical implications in management of mild and moderate laryngeal precancerosis. *Eur Arch Otorhinolaryngol* 2008; 265: 261-262.