

Case Report

Severe hydrocephalus complicated with benign paroxysmal positional vertigo: one case report

Jian Jun Chen, Wei Jin Cheng, Jie Rao, Ye Fen Lu, Wei Wen Qiu

Department of Neurology, Lishui Central Hospital, The Fifth Affiliated Hospital of Wenzhou Medical College, Lishui 323000, Zhejiang, China

Received August 26, 2015; Accepted October 27, 2015; Epub November 15, 2015; Published November 30, 2015

Abstract: In this study, we reported one female patient diagnosed with severe hydrocephalus who presented with benign paroxysmal positional vertigo (BPPV). She presented with progressive headache and dizziness prior to hospitalization as chief complaints. She received Diagnostic Dix-Hallpike and Roll tests to make a definite diagnosis. The patient was cured after Gufoni maneuver and did not recur after 6-month follow-up. The diagnostic procedures of this female case prompted that prior to formal treatment, patients developing severe hydrocephalus complicated with BPPV should receive provocative test for positional dizziness, performed by experienced physicians from the Department of neurology and otolaryngology.

Keywords: Severe hydrocephalus, complication, paroxysmal positional vertigo

Introduction

Benign paroxysmal positional vertigo (BPPV) is regarded as one of the most common causes of vertigo in clinical practice [1]. BPPV is characterized with recurrent episodes of vertigo, nausea, vomiting, visual disturbance and alternative symptoms. In addition, it can occur concomitantly with alternative inner ear diseases [2]. In this study, we reported a rare female case suffering from serious hydrocephalus complicated with BPPV. The diagnosis and therapy procedures were evaluated to add to more evidence for patients with severe hydrocephalus accompanied by BPPV.

Case report

Clinical data

A female patient aged 51 years old was admitted to the Neurology Department of our institution with chief complaints of headache and dizziness for half a month and aggravated vertigo developed 4 days later. The patient presented with enlarged head circumference, fontanel enlargement and separation of cranial sutures since childhood. The skull bone seemed trans-

parent. During her childhood, she had a low level of intelligence quotient. She was left untreated due to economic difficulties. As an adult, she could normally communicate with others and live independently. She denied any medical history of dizziness, migraine, tinnitus or hearing loss.

At 6 month prior to admission, she began to present with dizziness, nausea and occasionally vomiting with unknown causes and left untreated. She had no signs of vertigo, diplopia, headache limb numbness, tinnitus, hearing loss, dysphonia or unconsciousness. At 4 days before hospitalization, she suddenly suffered from aggravated dizziness accompanied with positional vertigo, nausea, vomiting and repeated onset of dizziness for ≤ 1 minute. Then, she was admitted to a local hospital for intravenous administration of Danshen injection and showed no improvement. Thus, she was transferred to our hospital for diagnosis and treatment.

Routine examinations

Physical examination: blood pressure 138/84 mmHg, normal heart and lung by auscultation,

Hydrocephalus complicated with BPPV

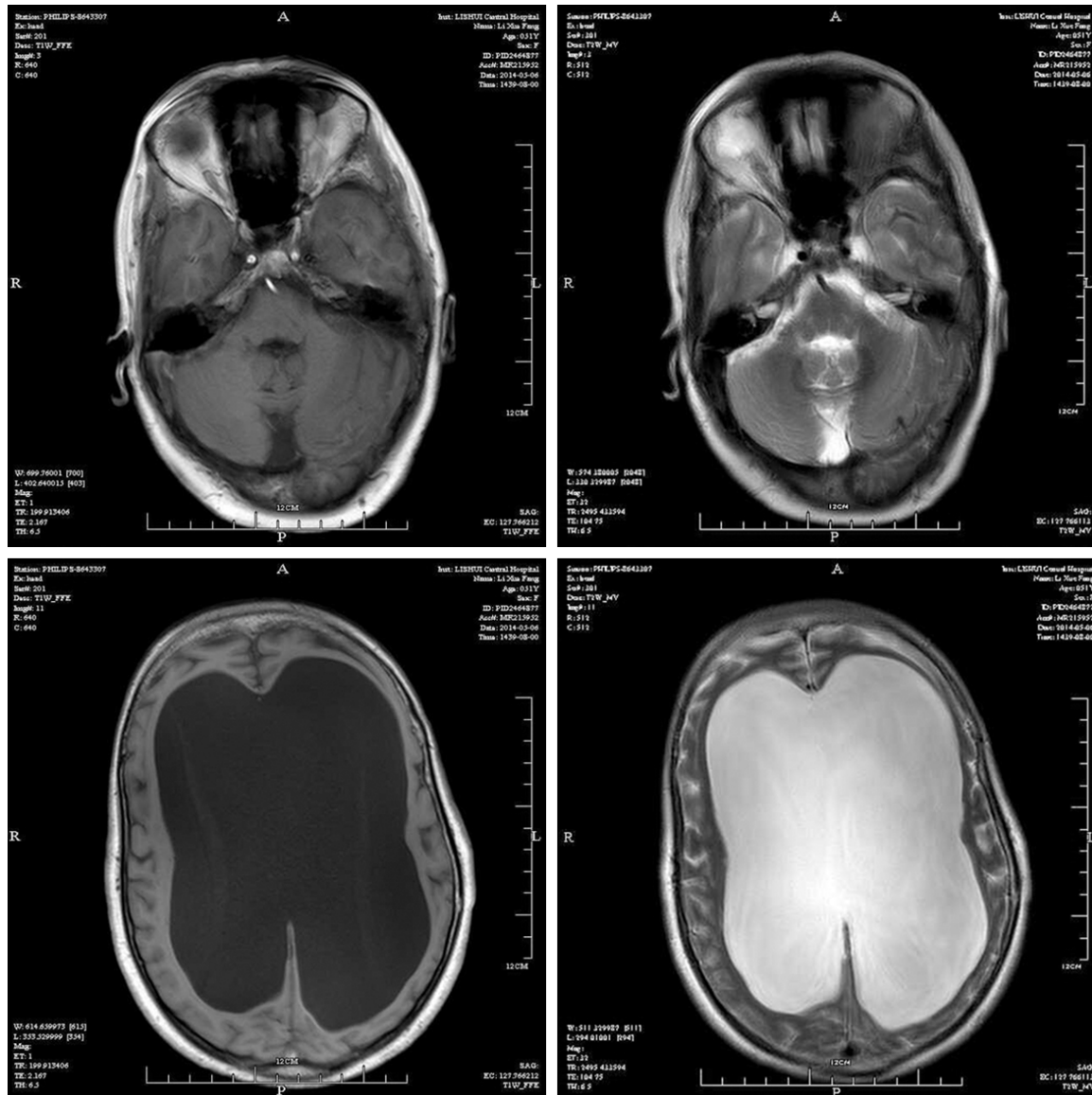


Figure 1. T1- and T2-weighted MRI (T1WI and T2WI) of the head.

soft and plain abdomen, no edema in bilateral lower extremities, clear consciousness, Mini-Mental State Examination score 15, no head tilt or apparent strabismus, no spontaneous nystagmus, no gaze-induced nystagmus, limb myodynamia grade V, normal muscle tension, tendon reflex symmetry, soft neck, negative for Klinefelter syndrome, Dix-Hallpike and Roll tests, normal outcomes in finger-nose test, rombergism, head-rotation test and smooth tracking test. Normal outcomes were obtained in blood test, blood sedimentation, C-reactive protein, thyroid function, syphilis antibody, HIV antibody, blood glucose, hepatic and renal function. Transparent cerebrospinal fluid was

seen by lumbar puncture. Initial cerebrospinal fluid pressure was 90 mmH₂O, white blood cell (WBC) 0/μl, red blood cell (RBC) 0/μl, total protein concentration = 0.27 g/L and the levels of glucose and chloride were detected within the normal range. Auditory steady-state response thresholds in bilateral ears were normal. T1- and T2-weighted MRI (T1WI and T2WI) of the head reveal significant enlargement in the lateral ventricle, compression and thinning of the brain tissues, whereas no enlargement in four ventricles of the brain, as illustrated in **Figure 1**. Sagittal T1-weighted MRI of the head revealing significantly enlarged supratentorial ventricles, compression and thinning of the brain tis-

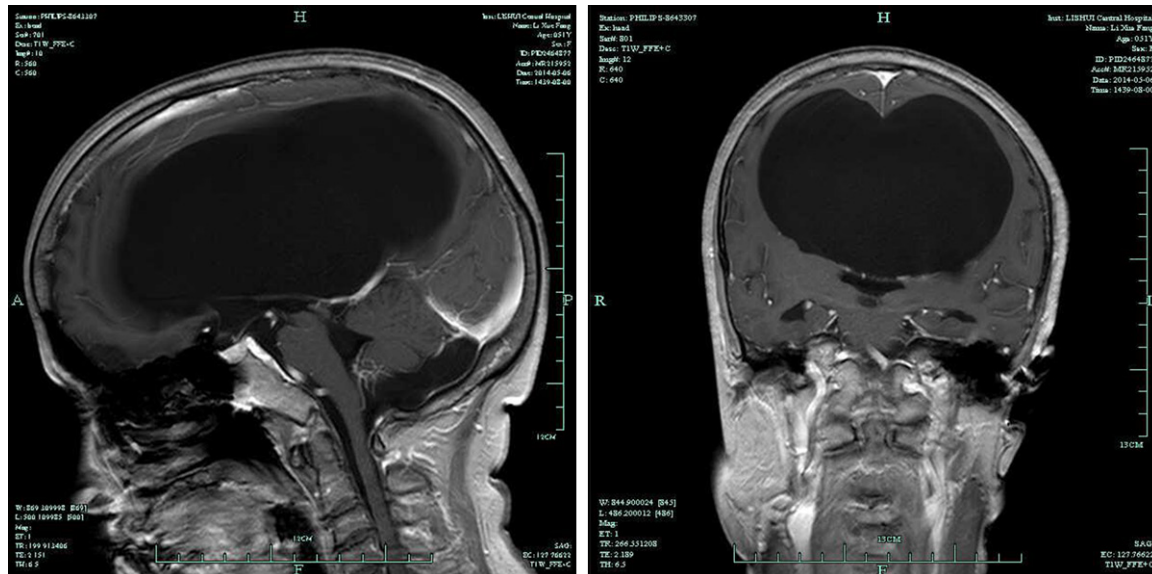


Figure 2. Sagittal T1-weighted MRI of the head.

tissues, compression and aqueduct stenosis of the midbrain, cerebellar maldevelopment, cerebellar hypoplasia and cistern magna enlargement (**Figure 2**). Informed consent was obtained from the patient prior to study.

Diagnostic Dix-Hallpike and Roll tests

At 5 days following hospitalization, she had apparent positional nausea, vomiting and alternative autonomic symptoms, whereas she could walk steadily before the onset of diseases. She was suspected with true vertigo due to the incidence of vertigo, nausea, vomiting and autonomic symptoms. Physical examination found no signs of gaze-induced nystagmus and smooth tracking test detected no abnormality. Hence, she was considered as peripheral vertigo. She received twice Dix-Hallpike and Roll tests for the diagnosis of BPPV. Negative outcomes were obtained, which seemingly excluded the possibility of BPPV. No specific diagnostic test was available for vestibular paroxysmia (VP) and carbamazepine should be supplemented to confirm the diagnosis. In this report, the patient suffered from hydrocephalus for a long period and had no similar medical history, which partially excluded the possibility of hydrocephalus. During Dix-Hallpike test, neither dizziness nor nystagmus was observed when the head rotated to the left side. Then, the other side was tested and no signs of dizziness were seen, whereas nystagmus (approximately 1

second) was suspected. During subsequent roll-test, vertical nystagmus was noted when the head turned to the left side (approximately 1 second) and no dizziness was observed. The right side was tested and transient nystagmus was noted in vertical position (approximately 1-2 seconds). Then, another Roll-test was repeated. She lied in a supine position with her head elevated by 30°. When the intensity and speed of head rotation were accelerated, vertical nystagmus (approximately 5-6 seconds) was observed on the left side and apparent vertical nystagmus (approximately 9-10 seconds) was noted on the right. No latent period of apparent nystagmus was seen. Both nystagmus and transient dizziness were observed simultaneously.

Based on the findings above, the patient was diagnosed with semicircular canal BPPV. Roll-test revealed vertical nystagmus in both eyes, especially the right side. Horizontal semicircular canal BPPV was considered on the affected side.

Treatment and follow-up

Gufoni maneuver was performed on the right horizontal semicircular canal and otolith. Then, she presented with no episodes of dizziness, nausea, vomiting or other symptoms. According to the patient's chief complaint, she suffered from hydrocephalus since childhood without

the incidence of aggravated cognitive disorders, walking gait disorders or urinary incontinence. Thus, she was diagnosed with congenital hydrocephalus, which gradually became balanced after several decades. Current symptoms revealed no evidence of hydrocephalus aggravation. The patient had no operation indications of the hydrocephalus and was discharged after 1-d observation. During 6-month follow-up, no recurrent dizziness or other symptoms were observed.

Discussion

In this report, the patient presented with enlarged head circumference and fontanelles after birth but left untreated. She presented with a slightly lower level of intelligence quotient compared with her counterparts. MRI revealed vermis cerebelli maldevelopment accompanied with posterior cranial fossa cyst, which was connected to the fourth ventricle. Severe hydrocephalus was noted in the lateral ventricle, highly considered as Dandy-Walker syndrome [3]. In recent years, the patient's condition remained stable and experienced no aggravation of cognitive disorders, walking gait abnormality or urinary incontinence, suggesting that the hydrocephalus reached a state of equilibrium. Although previous imaging findings were lacking, current data did not support hydrocephalus aggravation. Noticeably, the case in this report had severe hydrocephalus complicated with CPPV. Initially, she presented with positional nausea and vomiting whereas no apparent vertigo occurred. First, the absence of vertigo should be validated repeatedly. Second, it should not exclude the correlation with low intelligence quotient and inaccurate description of symptoms. Positional vomiting as the major symptom has been rarely reported in clinical practice. Roongpiboonsopit D et al. [4] reported a case of cysticercosis in four ventricles of the brain with positional vomiting as the main manifestations. Cordato DJ et al. [5] found that positional vomiting resulted from spinal dural arteriovenous fistula. The possibility of similar rare diseases was eliminated during the diagnosis and treatment of this case. Clinically, many patients were admitted to the digestion department due to nausea and vomiting, and even received gastroscopy. In this report, the signs of nausea and vomiting were concurrent symptoms of vertigo after explicit

inquiry of her medical history. Hence, positional nausea and vomiting probably are atypical manifestations of vertigo. Dizziness-related symptoms may be provoked when cerebellar hydrocephalus or vestibular nerve transposition occurs.

The manifestations of this case are complicated and misleading. On one hand, she had suffered from hydrocephalus for a long period without medical history of similar diseases. On the other hand, she did not present with the triad of dementia, walking gait disorders and urinary incontinence. She had dizziness as the primary symptoms. Thus, we considered that the incidence of dizziness was not correlated with hydrocephalus. However, potential cause of transposition of the 8th cranial nerves induced by hydrocephalus should not be excluded.

VP is mainly encountered in middle- and old-aged patients, which is characterized as repeated transient dizziness and constantly results from posture changes. The anatomical relationship between nerve and blood vessel could be explicitly displayed by CISS-MRI [6]. The diagnosis of VP mainly depends upon patients' medical history and therapeutic effect of antiepileptic drugs. Auxiliary examination is of limited reference value [7]. Approximately 1/10 of patients with vestibular migraine headache are manifested as transient episodes of dizziness enduring for several seconds, which is constantly correlated with posture [8]. However, the case in this report had no medical history of migraine headache or similar vertiginous diseases. She presented with no symptoms of headache or photophobia, which was inconsistent with the diagnostic criteria of vestibular migraine headache.

In this report, the patient complained about vertigo, nausea, vomiting and alternative autonomic symptoms, suspected as true vertigo. Moreover, she had apparent positional vertigo and she could walk steadily before the onset of diseases, no signs of gaze-induced nystagmus or abnormality detected by smooth tracking test, suggesting the possibility of peripheral vertigo. The patient had temporary nystagmus and dizziness. During episode of diseases, dizziness and nystagmus were observed in a synchronized pattern. When the nystagmus disappeared, the dizziness was alleviated

accordingly. Roll-test revealed vertical nystagmus bilaterally, which was in accordance with the characteristics of horizontal semicircular canal nystagmus. In contrast, central nystagmus is mainly characterized as vertical or rotation nystagmus, occasionally manifested as temporary dizziness but persistent nystagmus, suggesting that the symptoms of dizziness and nystagmus are significantly divergent. In addition, the features of nystagmus are not in accordance with the characteristics of semicircular canal nystagmus [9-13].

BPPV is the most common vertiginous disease. But it is rarely complicated with serious hydrocephalus in clinical practice. The diagnosis and treatment of this patient demonstrated that the dizziness results from BPPV rather than hydrocephalus. The findings in this report prompt that the subjects with positional transient nystagmus, in accordance with the characteristics of BPPV episode, should be considered with BPPV. Even if negative outcomes were obtained during the first Dix-Hallpike test, the test should be repeated to verify the accuracy of test. Severe hydrocephalus did not affect the maneuver reposition.

In this report, based upon physical signs and clinical symptoms of the patient, she was definitely diagnosed with right horizontal semicircular canal BPPV. The patient was cured after Gufoni maneuver and did not recur after 6-month follow-up. She previously received twice Roll-test and had no symptoms of dizziness or nystagmus, probably resulting from slow maneuver and attachment of otolith to the semicircular canal duct, etc. If no nystagmus is observed in the Roll-test, the patients should alter the gazing direction and receive repeated Roll-test. When the patient turns head to the right side, he/she should first gaze at the right direction and then to the left. The symptom of nystagmus may be observed, especially when the otolith attach to the horizontal semicircular canal. The signs of nystagmus could be seen when the patient gazes upward [14]. The otolith is probably not located at the lowest point or attaches to the semicircular canal wall. After repeated tests, typical symptoms of nystagmus may emerge after the otolith dislocates from the semicircular canal wall. The patient was found to have positive Roll-test outcomes on the right side and was cured by corresponding

maneuver. When conventional Roll-test maneuver fails to evaluate the severity of nystagmus, 180 degree Roll-test should be used as a supplementary approach [15].

Disclosure of conflict of interest

None.

Address correspondence to: Wei Wen Qiu, 289 Kuocang Road, Lishui 323000, Zhejiang, China. Tel: 0578-2285230; Fax: 0578-2285230; E-mail: weiw-en0896@sina.com

References

- [1] Bhattacharyya N, Baugh RF, Orvidas L, Barrs D, Bronston LJ, Cass S, Chalian AA, Desmond AL, Earll JM, Fife TD, Fuller DC, Judge JO, Mann NR, Rosenfeld RM, Schuring LT, Steiner RW, Whitney SL, Haidari J. American Academy of Otolaryngology-Head and Neck Surgery Foundation. Clinical practice guideline: benign paroxysmal positional vertigo. *Otolaryngol Head Neck Surg* 2008; 139 Suppl 4: S47-S81.
- [2] Sammartino G, Mariniello M, Scaravilli MS. Benign paroxysmal positional vertigo following closed sinus floor elevation procedure: Mallet osteotomies vs. Screwable osteotomies. A triple blind randomized controlled trial. *Clin Oral Implants Res* 2011; 22: 669-672.
- [3] Can SS, Karakaş Uğurlu G, Cakmak S. Dandy walker variant and bipolar I disorder with graphomania. *Psychiatry Investig* 2014; 11: 336-339.
- [4] Roongpiboonsopit D, Shuangshoti S, Phanthumchinda K, Bhidayasiri R. Positional vomiting as the initial manifestation of Bruns syndrome due to cysticercosis in the fourth ventricle: a symptom reminiscent of an old disease. *Eur Neurol* 2012; 67: 184-185.
- [5] Cordato DJ, Davies MA, Masters LT, Cremer PD, Schwartz RS, Sorby W, Becvarovski Z. Positional vomiting due to a thoracic spinal dural arteriovenous fistula. Case report. *J Neurosurg Spine* 2004; 1: 219-222.
- [6] Hu"fner K, Barresi D, Glaser M, Linn J, Adrion C, Mansmann U, Brandt T, Strupp M. Vestibular paroxysmia: diagnostic features and medical treatment. *Neurology* 2008; 71: 1006-1014.
- [7] Brandt T, Dieterieh M, Danek A. Vestibular cortex lesions affect the perception of verticality. *Ann Neurol* 1994; 35: 403-412.
- [8] Headache Classification Committee of the International Headache Society (IHS). The International Classification of Headache Disorders, 3rd edition (beta version). *Cephalalgia* 2013; 33: 629-808.

Hydrocephalus complicated with BPPV

- [9] Karatas M. Central vertigo and dizziness: epidemiology, differential diagnosis, and common causes. *Neurologist* 2008; 14: 355-364.
- [10] Sekine K, Sato G, Takeda N. Incidence of vertigo and dizziness disorders at a university hospital. *Nihon Jibiinkoka Gakkai Kaiho* 2005; 108: 842-849.
- [11] De la Meilleure G, Dhaene I, Depondt M, Damman W, Crevits L, Vanhooren G. Benign paroxysmal positional vertigo of the horizontal canal. *J Neurol Neurosurg Psychiatry* 1996; 60: 68-71.
- [12] Moon SY, Kim JS, Kim BK, Kim JI, Lee H, Son SI, Kim KS, Rhee CK, Han GC, Lee WS. Clinical characteristics of benign paroxysmal positional vertigo in Korea: a multicenter study. *J Korean Med Sci* 2006; 21: 539-543.
- [13] Tirelli G, D'Orlando E, Giacomarra V, Russolo M. Benign positional vertigo without detectable nystagmus. *Laryngoscope* 2001; 111: 1053-1056.
- [14] Hegemann S, Straumann D, Bockisch C. Alexander's Law in patients with acute vestibular tone asymmetry-evidence for multiple horizontal neural integrators. *J Assoc Res Otolaryngol* 2007; 8: 551-561.
- [15] Lim HJ, Park K, Park HY, Choung YH. The significance of 180-degree head rotation in supine roll test for horizontal canal benign paroxysmal positional vertigo. *Otol Neurotol* 2013; 34: 736-742.