

Original Article

Effects of α -zearalanol on spermatogenesis and sex hormone levels of male mice

Cunxiang Bo^{1*}, Wei Zhao^{2*}, Qiang Jia¹, Zhifeng Yang¹, Linlin Sai¹, Fang Zhang¹, Zhongjun Du¹, Gongchang Yu¹, Lin Xie¹, Zhenling Zhang¹

¹Shandong Academy of Occupational Health and Occupational Medicine, Shandong Academy of Medical Sciences, Jinan, Shandong Province, P. R. China; ²Department of Radiation Oncology, Shandong Cancer Hospital & Institute, Shandong Academy of Medical Sciences, Jinan, Shandong Province, P. R. China. *Equal contributors.

Received September 15, 2015; Accepted November 10, 2015; Epub November 15, 2015; Published November 30, 2015

Abstract: Aims: To investigate the mechanisms of α -zearalanol (Zeranol)-induced male reproductive toxicity, the effects of Zeranol on spermatogenesis and sex hormone levels of male mice were studied. Methods: Forty healthy sexually mature male Kunming mice were randomly divided into four groups. The mice were mock-treated or treated with Zeranol 25, 50 or 100 mg/kg via oral gavage for 35 days. The epididymal sperms were counted and their morphology and motility were analyzed. The testicles were examined by light and electron microscopy. The levels of serum/testicular testosterone (T), serum follicle stimulating hormone (FSH) and serum luteinizing hormone (LH) were determined by radioimmunoassay. Results: Zeranol decreased the epididymal sperm count and sperm motility in a dose depend manner. While there were not significant differences in the sperm malformation rates between the Zeranol treated groups and the control group. Furthermore, Zeranol could decrease the weight and the organ coefficient of the seminal vesicles and the testicles and lead to significant pathological changes of the testicles. Zeranol could also decrease the levels of serum T, FSH, LH as well as the levels of testicular T of male mice. Conclusions: Zeranol induced reproductive toxicity in adult male mice. It could damage spermatogenesis via its direct effects on the testicles and interfere with sex hormone levels of male mice through its effects on the hypothalamic-pituitary-testicular axis.

Keywords: α -zearalanol, sex hormone, spermatogenesis, testicle, mice

Introduction

α -zearalanol (Zeranol) is a nonsteroidal semi-synthetic estrogen produced by *Fusarium* species and derives from Zearalenone via hydrogenation [1, 2]. It is widely used as an animal growth promoter to improve the fattening rates in many countries including USA. It is usually implanted subcutaneously in the animals. Zeranol could promote the pituitary gland to release growth hormone and accelerate the protein synthesis [3].

The toxicity and tissue residues of Zeranol are very low [4]. However, it could disrupt the endocrine system [5]. Long-term ingestion of the food with residues of Zeranol breaks the balance of human sex hormone and affects the development of secondary sexual characteristics. Zeranol and its metabolites are able to adopt molecular conformation, which suffi-

ciently resembles 17 β -oestradiol to allow it to bind to estrogen receptors (ERs) and interfere with the functions of endocrine reproductive system [6, 7]. Exposure to Zeranol might introduce adverse effect in pregnancy. The number of fetuses, fetal weight, fetal length and fetal survival were reduced by Zeranol implants [8, 9]. Increased amount of plasma corticotrophin-releasing hormone (CRH) is associated with pre-mature delivery. Zeranol could activate the signal transduction pathway of protein kinase C and extracellular signal-regulated kinase-1/2 and increase CRH expression in placental cells [10].

Male reproductive process involves a series of physical activities such as sperm production, maturation, transport, sperm capacitation, etc. Sperm production depends on the testicular spermatogenic cells, Sertoli cells and Leydig cells. Sertoli cells provide support, protection

and nutrition to the developing sperm cells. They also act as phagocytes, consuming the metabolites, secreting testis fluid and androgen binding protein (ABP), thus providing a suitable microenvironment for the development and differentiation of sperm cells. Testosterone, secreted by the Leydig cells, is necessary for sperm maturation. Enough amounts of healthy sperms are important for male fertility. Changes in the quality of sperms in male animals may reflect the early reproductive damage. Spermatogenesis in the testicle is also regulated by the hypothalamic-pituitary-testicular axis. Follicle stimulating hormone (FSH) and luteinizing hormone (LH) secreted by the anterior pituitary in response to gonadotropin-releasing hormone (GnRH) released by the hypothalamus together with testosterone (T) secreted by the testicles play important roles in sexual function and reproductive function, thus maintaining homeostasis throughout the growth period. Mounting evidence suggests that environmental exposures of endocrine disruptors relate to decreased male sperm count and male feminization of the animals [11-13]. The effects of endocrine disruptors with estrogenic activity on the male reproductive system have aroused much attention. It could lead to male genital hypoplasia, distortion, male infertile, decline in male fertility, etc.

Zeranol implanted in the early childhood could increase the growth rate of the animals. It could also inhibit sexual development, delay having sex, reduce the circumference of scrotum and the weight of testes and lead to the lack of sperm [14-18]. Subcutaneous injection of Zeranol of 20 mg/kg in prepubescent Wistar male rat stimulated the growth of the seminal vesicles, the prostate gland and the preputial glands. Zeranol 500 mg/kg interrupted spermatogenesis and decreased the weight of the testicles. Zeranol 1000 mg/kg decreased the weight of the preputial glands and the prostate gland while had no effect on the seminal vesicles [19]. Prenatal exposure to Zeranol could induce abnormal spermatogenesis in the mouse [20-22]. The effects correlated with its estrogenic activity. Thus exposure of Zeranol in fetal and early childhood periods could damage the reproductive function of male animals. However, little is known about the effects of Zeranol on the reproductive functions of adult male animals. To investigate the effects of Zeranol on the spermatogenesis of adult male

animals, we studied Zeranol-induced reproductive toxicity in adult male mice and detected the levels of T, FSH, and LH using radioimmunoassay (RIA).

Materials and methods

Reagents

Zeranol (purity, 97.5%) was purchased from Shenzhen Yifei Trading Company, and solved in 2% Tween 80. The RIA kits for T, FSH and LH concentration detection were purchased from Tianjin Jiuding Biological Products Co., Ltd.

Animals and treatment

Forty healthy adult male, specific pathogen free (SPF) Kunming mice (24~28 g) were provided by Experimental Animal Center of Shandong University (governmental license, SCXK Lu 20090001). The study was approved by the Ethics Committee of Shandong Academy of Occupational Health and Occupational Medicine. The mice were divided into 4 groups of 10 by randomization of body weights and were administered with Zeranol via oral gavage at 0, 25, 50 or 100 mg/kg everyday once per day for 35 days. The control group received 2% Tween 80 only. The mice were maintained in SPF laboratory with temperature of 20~24°C and a relative humidity of 40~50%. In the Zeranol 50 mg/kg group, there were 3 mice with scrotal swelling and 1 of these 3 mice was sacrificed at 15 days after the first administration. The other 9 mice were subjected to Zeranol administration for the following 20 days. In the Zeranol 100 mg/kg group, there were 4 mice with scrotal swelling and 2 of these 4 mice were sacrificed at 15 days after the first administration. The other 8 mice were subjected to Zeranol administration for the following 20 days. The mice were examined for food and water consumption, behavioral activity, urine and feces every day. The body weights of the mice were measured once a week. 24 hours after the last administration, the mice were sacrificed.

Sperm analysis

The left cauda epididymis were excised and weighed from each mouse, then shredded in small beakers containing 4 ml of pre-warmed normal saline (NS, 37°C) and filtered with 4 layers of lens cleaning paper. The sperm solution was incubated for 10 min at 37°C. For sperm

Effects of α -zearalanol on male mice

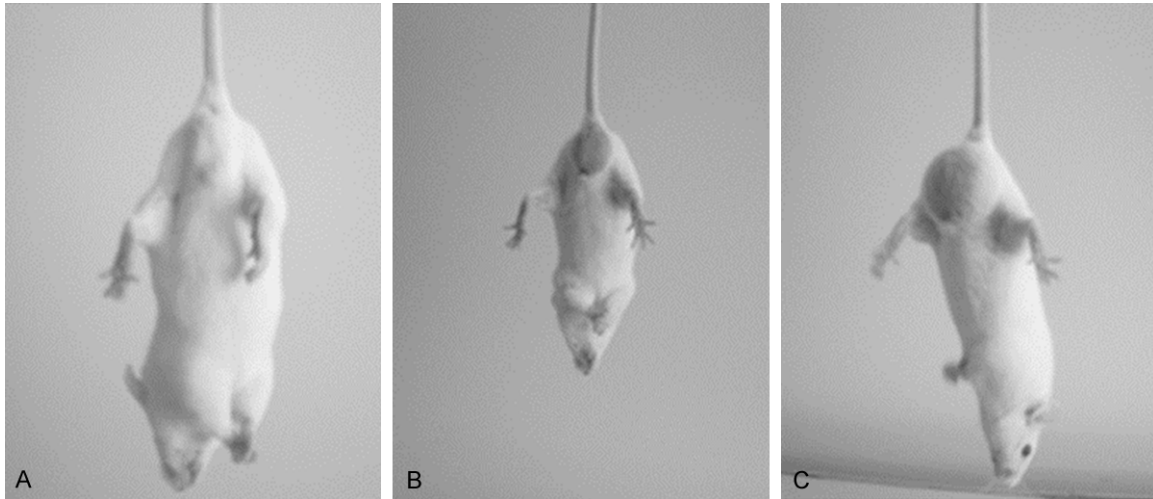


Figure 1. Effects of Zearanol on the scrotum of the mice. Representative pictures of the mice in the control group (A), in the groups treated with Zearanol 50 mg/kg (B) and 100 mg/kg (C) were shown. In the group treated with Zearanol 50 mg/kg, there were 3 mice with scrotal swelling from 8 to 15 days after the first administration. In the group treated with Zearanol 100 mg/kg, there were 4 mice with scrotal swelling from 8 to 15 days after the first administration.

motion detection, 200 sperms of each mouse were observed by the Nikon Eclipse E600 microscope (Nikon, Japan). The motile sperms and the non-motile sperms were counted. The sperm motility was the percentage of the ratio of the number of motile sperms to the number of total sperms (the sum of motile and non-motile sperms) [23]. For sperm count detection, the sperm solutions were placed in the water bath at 60°C and the dead sperms were counted using hemocytometer counting chamber. The relative sperm count represents the percentage of sperm count ($\times 10^8$) per cauda epididymis (g). For sperm morphometry detection, the sperm smears were fixed in methanol and stained in 2% eosin solution. The sperm malformation rates were calculated as reported by Hu et al. [24].

Mice organ weight and organ coefficient detection

Twenty-four hours after the last administration, the body weights of the mice were measured. Then the mice were sacrificed and the testicles, epididymis and seminal vesicles were excised from each mouse. The shape and the size of these organs were recorded. The organs were weighed after excluding the adipose tissue. Organ coefficient was calculated as the percent of the ratio of the wet weight of the organ to the body weight.

Hematoxylin-eosin (HE) staining

Pathological changes of testis tissues of 3 mice randomly selected from each group respectively were examined using HE staining. Briefly, the testis tissues were fixed, embedded in paraffin and cut into tissue sections. Then tissue sections were dewaxed in xylene and rehydrated in graded alcohols. After washing with running water, sections were stained with hematoxylin for 10-15 min. After washing again with running water, sections were differentiated with 1% HCl in alcohol. Then sections were stained with eosin for 1-3 min after washing with running water. After dehydration and differentiation in alcohol, sections were mounted and observed under microscopy.

Transmission electron microscopy

Pathological changes of testis tissues of 3 mice randomly selected from the control group and the group treated with 100 mg/kg Zearanol respectively were observed by transmission electron microscopy. Briefly, the testis tissues were fixed in glutaric dialdehyde at 4°C for 24 h. After rinsing with phosphate buffered saline (PBS) for 3 times, the testis tissues were fixed with 1% osmium tetroxide for 2-3 h. Then the testis tissues were dehydrated in a graded series of alcohols and a final treatment with acetone after washing with PBS. After dehydration, the testis tissues were infiltrated in Epon

Effects of α -zearalanol on male mice

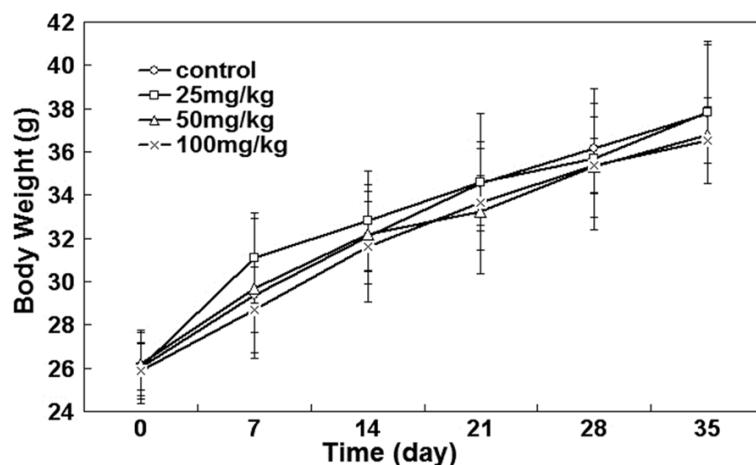


Figure 2. Effects of Zearanol on the body weights of the mice. The body weights of the mice were measured once a week during the administration period. There were no significant differences in the body weights of the mice between each Zearanol treated group and the control group ($P > 0.05$). The data represents means \pm SD. One-way ANOVA.

Table 1. The sperm count, motility and malformation rate of the mice exposed to Zearanol for 35 days

Zearanol dose (mg/kg)	Relative sperm count	Sperm motility (%)	Sperm malformation rate (%)
0	10.18 \pm 2.46	75.55 \pm 6.96	1.89 \pm 0.43
25	6.92 \pm 2.53**	72.65 \pm 3.51	1.88 \pm 0.18
50	6.33 \pm 1.99**	66.67 \pm 3.05**	2.03 \pm 0.21
100	3.95 \pm 1.53**	58.50 \pm 4.41**	2.13 \pm 0.57

Note: The relative sperm count represents the percentage of sperm count ($\times 10^6$) per cauda epididymis (g). The data represents means \pm SD. One-way ANOVA, ** $P < 0.01$.

812 resin/acetone (1:1) for 1 h, then in Epon 812 resin/acetone (3:1) for 3 h, embedded in Epon 812 resin at 70°C overnight, and cut into ultra-thin sections (50-60 nm) by a LKB V ultramicrotome (LKB, Bromma, Sweden). Ultra-thin sections were stained with 3% uranyl acetate-citrate and examined with a transmission electron microscope H-600 (Hitachi, Tokyo, Japan).

RIA

The eyeballs were extracted and the blood was collected from the mice 24 hours after the last administration of Zearanol. The blood was left standing for 30 minutes, followed by centrifugation at 3000 rpm for 10 minutes. The serum was stored at -20°C. The testicles without tunica albuginea were weighed and shredded. Then 20% (v/v) testis homogenates were prepared with NS. After centrifugation at 10000 rpm for 30 minutes and left standing for a while, the

supernatant was divided. The levels of serum T, FSH, LH as well as the levels of T of the supernatant of testis homogenates were detected by RIA kits (Tianjin Jiuding Biological Products Co., Ltd) strictly according to the manufacturer's instructions.

Statistical analysis

All data were processed using SPSS13.0 statistical package. The measurement data were presented as means \pm standard deviation. The one-way ANOVA was performed to determine statistical significance of the differences. χ^2 test was used for analysis of count data.

P value less than 0.05 was considered statistically significant.

Results

Toxic effects of zearanol on the mice

To determine the toxic effects of Zearanol on the mice, the food and water consumption, behavioral activity, appearance and the body weights of the mice were studied during the administration period of 35 days. There were not abnormalities in the food and water consumption, behavioral activity, urine and feces of the mice of each group. From 8 to 15 days after the first administration, 3 of the 10 mice in the Zearanol 50 mg/kg group and 4 of the 10 mice in the Zearanol 100 mg/kg group showed scrotal swelling (**Figure 1**). One of the 3 mice with scrotal swelling in the Zearanol 50 mg/kg group and 2 of the 4 mice with scrotal swelling in the Zearanol 100 mg/kg group were sacrificed at 15 days after the first administration. In all these 3 mice, a portion of the intestine was trapped in the scrotum. The other 4 mice with scrotal swelling were subjected to Zearanol administration for the following 20 days. Their scrotal swelling disappeared 35 days after the first administration. Twenty-four hours after the last administration, the mice were sacrificed and there were no significant abnormalities in the organs such as the hearts, livers, lungs and kidneys of the mice of each group. The body weights of the mice were mea-

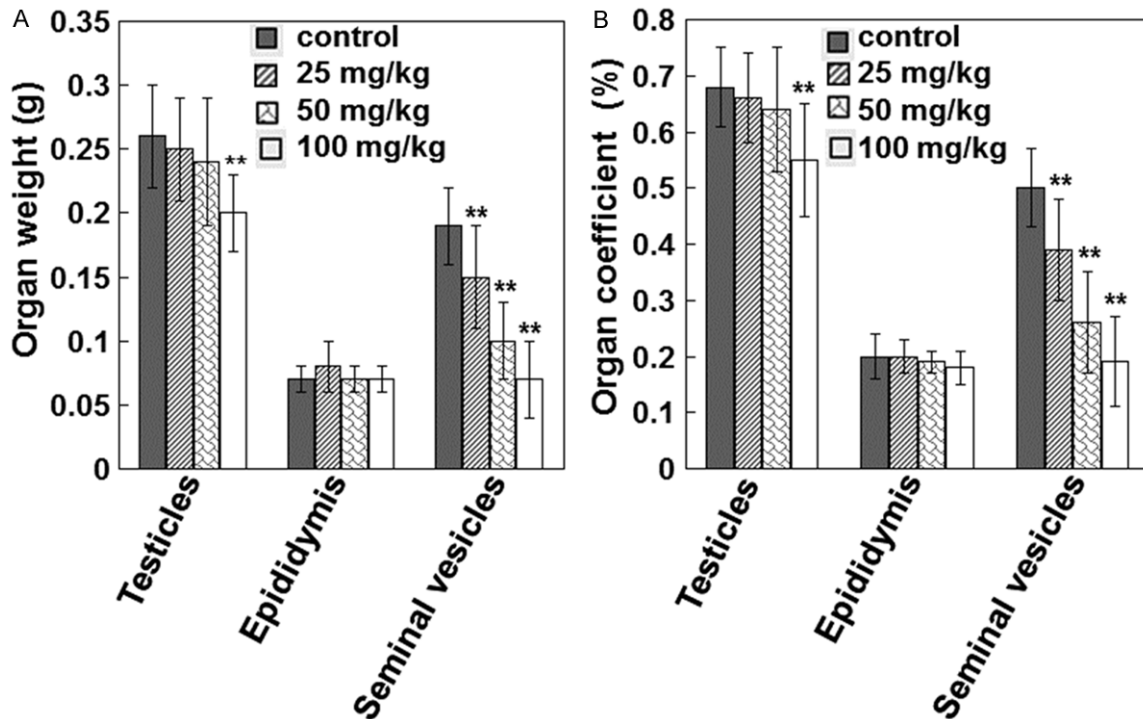


Figure 3. Effects of Zearanol on organ weights and organ coefficients of the sexual organs of the mice. Organ weights (A) and organ coefficients (B) of the sexual organs of the mice were shown. The organs were weighed after excluding the adipose tissue. Organ coefficient was calculated as the percent of the ratio of the wet weight of the organ to the body weight. The data represents means \pm SD. One-way ANOVA, ** $P < 0.01$, compared with the control group.

sured once a week during the administration period. The body weights of the mice increased evenly in the control group. In the mice of Zearanol treated groups, the increase of the body weights slowed down in the late stage of the experiment. However, there were no significant differences in the body weights of the mice between each Zearanol treated group and the control group ($P > 0.05$, **Figure 2**). These results indicate that Zearanol treatment could lead to pseudo scrotal swelling of the male mice, while does not affect the body weights.

Zearanol damages spermatogenesis of male mice

To investigate the effects of Zearanol on spermatogenesis, the number, morphology and motility of the epididymal sperms were analyzed. As shown in **Table 1**, Zearanol decreased the epididymal sperm count in a dose dependent manner. In all the three Zearanol treated groups, the epididymal sperm count was significantly lower than that of the control group ($P < 0.05$). In the groups treated with Zearanol 50 or 100 mg/kg, the sperm motility was significantly

lower than that of the control group ($P < 0.05$). The abnormal sperms may have no hook, double heads, large heads, crooked tails, etc. There were increased abnormal sperms in Zearanol treated groups. However, there differences in the sperm malformation rate between the Zearanol treated groups and the control groups were not significant ($P > 0.05$). These results indicate that Zearanol could decrease the epididymal sperm count and sperm motility, while has no effects on the sperm malformation rate.

Zearanol decreases the weights and organ coefficients of testicles and seminal vesicles

To investigate the mechanism of Zearanol induced spermatogenesis damage, the organ weights and organ coefficients of the sexual organs of the mice were detected after 35 days' treatment with Zearanol. In the control group, the seminal vesicles were large and full of a large amount of milky sperm and seminal fluids. In all the three Zearanol treated groups, the seminal vesicles atrophied with a decrease in the size and weight and contained little sperm and seminal fluids. The weights and the

Effects of α -zearalanol on male mice

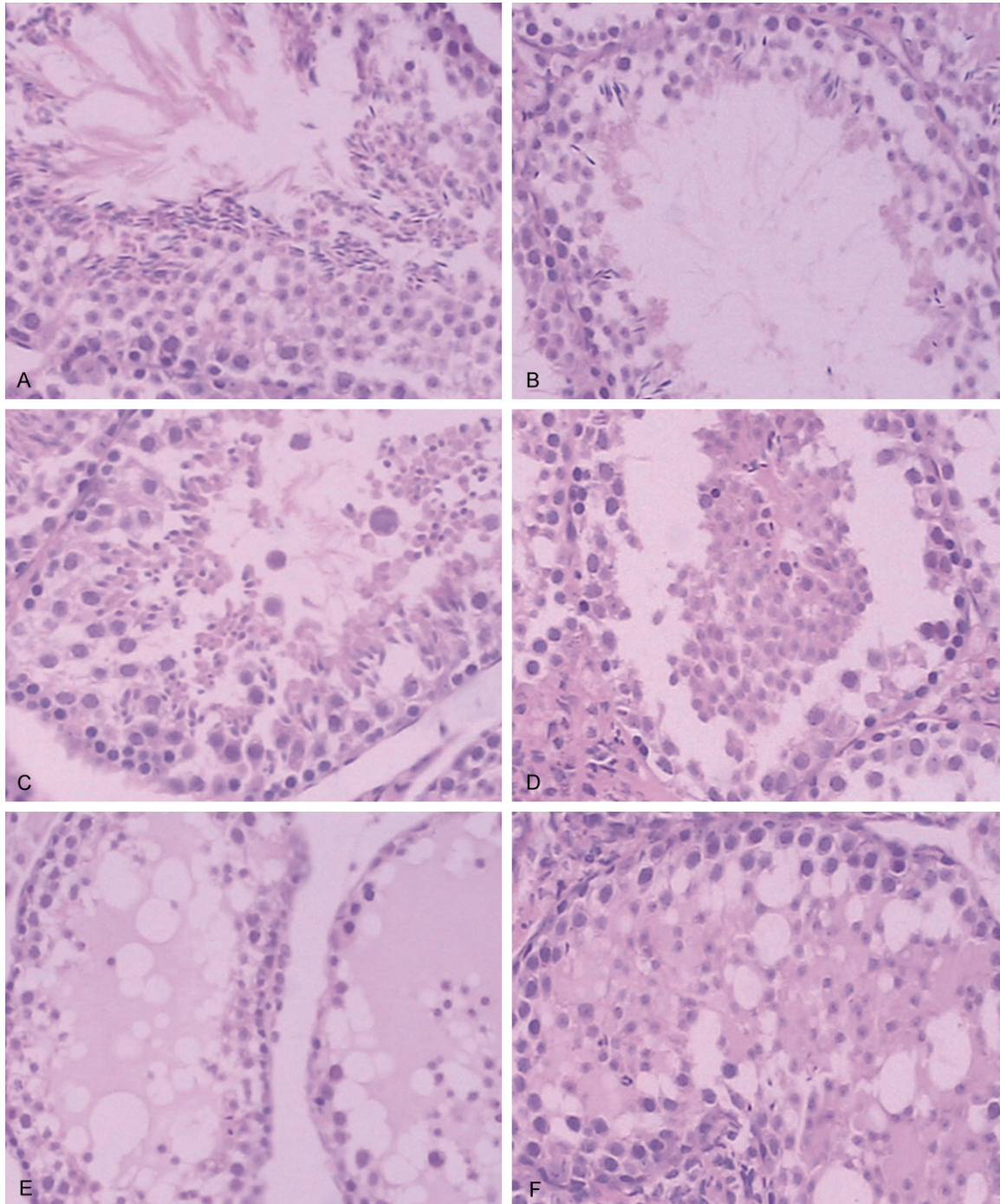


Figure 4. Histopathological findings of the testes ($\times 200$) using HE staining. A. In the control group, the spermatogenic epithelium cells were arranged orderly. There were not exfoliated cells but a large amount of mature sperms in the lumen of the testicular seminiferous tubules. B. In the group treated with Zeranol 50 mg/kg, the arrangements of spermatogenic epithelium cells were irregular and the levels of seminiferous epithelium were reduced. C. In the group treated with Zeranol 50 mg/kg, the arrangements of spermatogenic epithelium cells were irregular and the spermatocytes were exfoliated. D. In the group treated with Zeranol 100 mg/kg, there were exfoliated cells in the lumen of the testicular seminiferous tubules. E and F. In the group treated with Zeranol 100 mg/kg, the arrangements of spermatogenic epithelium cells were irregular and the levels of seminiferous epithelium were reduced and there was protein fluid in the lumen of the testicular seminiferous tubules.

organ coefficients of the seminal vesicles were significantly lower than those of the control

group ($P < 0.05$). In the group treated with Zeranol 100 mg/kg, the weights and organ

Effects of α -zearalanol on male mice

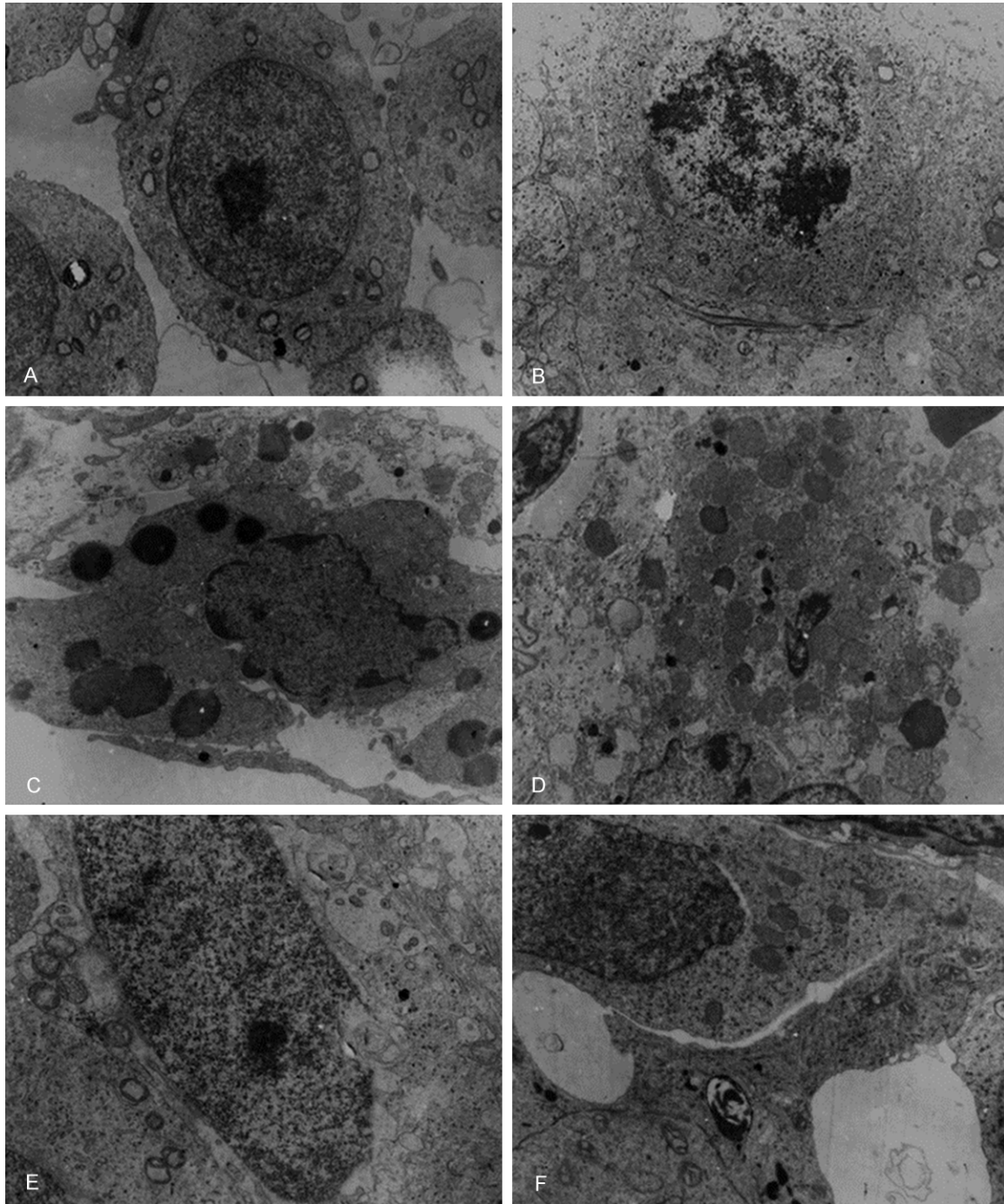


Figure 5. Histopathological findings of the testicles ($\times 200$) by transmission electron microscopy. (A) The spermatocytes in the control group were shown. (B) In the group treated with Zeranor 50 mg/kg, the cell membrane and nuclear membrane of the spermatocyte were incomplete (B), the nuclear membrane of the Leydig cells swelled and dissolved (C), there were increased lipid droplets in the the Leydig cells (D), the nuclear membrane of the sertoli cell was incomplete (E) and the perinuclear space and intercellular space of the sertoli cells were widened (F).

coefficients of the testicles were significantly lower than those of the control group ($P < 0.05$). While there were not significant differences in

the weights and organ coefficients of epididymis between the Zeranor treated groups and the control groups (**Figure 3**). These results

Effects of α -zearalanol on male mice

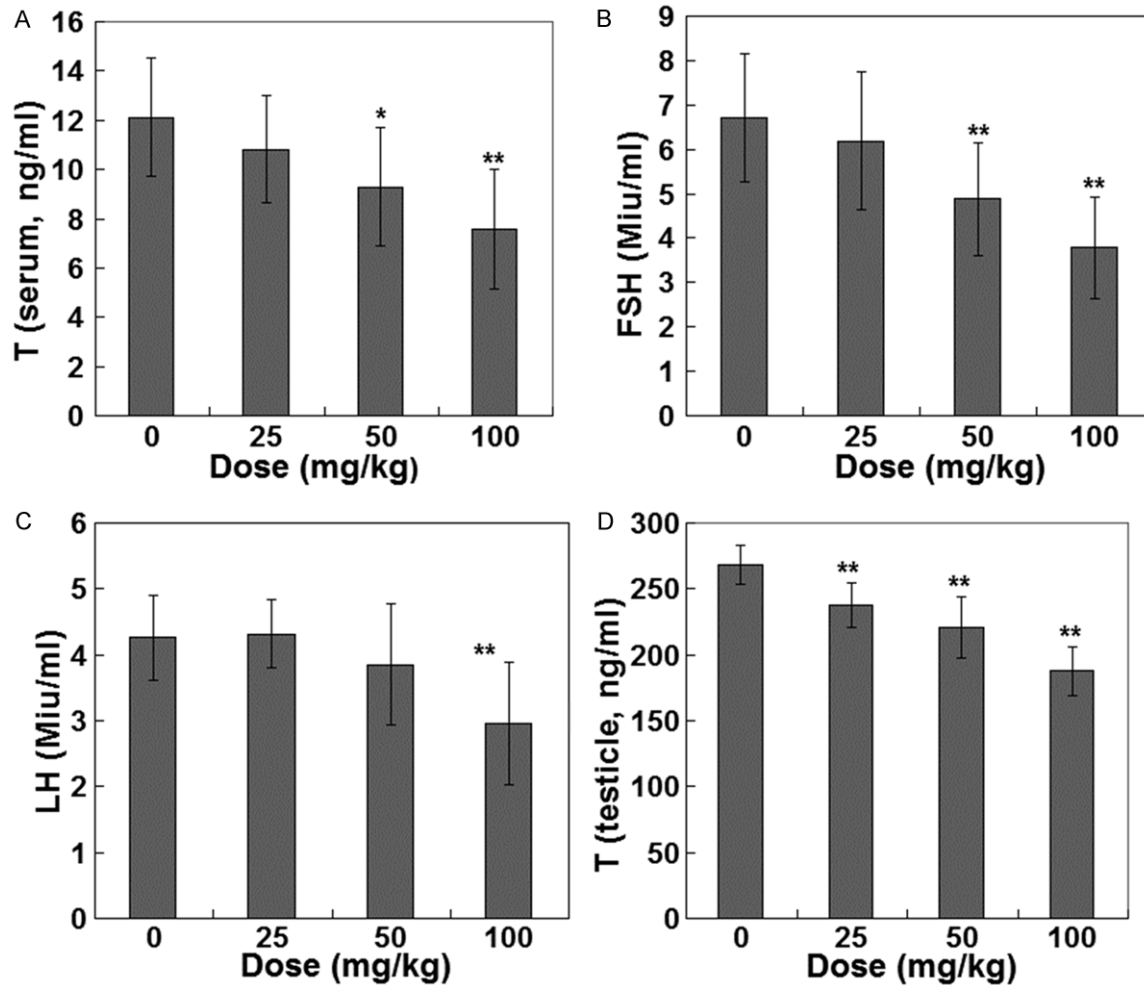


Figure 6. Zearanol decreases the sex hormone levels of male mice. The levels of serum T (A), FSH (B), LH (C) as well as the levels of T of the supernatant of testicles homogenates (D) were detected using RIA after 35 days' treatment with Zearanol. The data represents means \pm SD. One-way ANOVA, * $P < 0.05$, ** $P < 0.01$, compared with the control group. T, testosterone; FSH, follicle stimulating hormone; LH, luteinizing hormone; RIA, radioimmunoassay.

indicate that Zearanol could decrease the weights and organ coefficients of testicles and seminal vesicles of male mice.

Effects of zearanol on the histopathological changes of the testicles

As mentioned above, Zearanol could decrease the weights and organ coefficients of testicles. Then the effects of Zearanol on the histopathological changes of the testicles were further studied by light and electron microscopy. Firstly, pathological changes of testis tissues of 3 mice randomly selected from each group respectively were examined using HE staining. In the control group, the spermatogenic epithelium cells were arranged orderly. There were not exfoliated cells but a large amount of mature sperms in

the lumen of the testicular seminiferous tubules (**Figure 4A**). However, we observed varying degrees of histopathological changes in the testicular seminiferous tubules in the Zearanol treated groups. In the group treated with Zearanol 25 mg/kg, we observed reduced levels of seminiferous epithelium in some areas. In the groups treated with Zearanol 50 mg/kg and 100 mg/kg, there were irregular arrangement of spermatogenic epithelium cells and reduced levels of seminiferous epithelium. There were clustered exfoliated cells but reduced mature sperms in the lumen of the testicular seminiferous tubules (**Figure 4B-D**). We also observed protein fluid in certain areas of the lumen of the testicular seminiferous tubules in the group treated with Zearanol 100 mg/kg (**Figure 4E, 4F**).

Secondly, the pathological changes of the testis tissues of 3 mice randomly selected from the control group and the group treated with 100 mg/kg of Zeranol, respectively were observed by transmission electron microscopy. In the control group, spermatogonial cells were arranged orderly with condensed chromatin; the primary spermatocytes were large with large nucleus and clear nuclear membrane (**Figure 5A**); and the structures of the Sertoli cells and the Leydig cells were normal. In the group treated with 100 mg/kg of Zeranol, we observed partial dissolution of the cell membrane and incomplete nuclear membrane (**Figure 5B**). The nucleus of the Sertoli cells and the Leydig cells was damaged with dissolution of the nuclear membrane. The perinuclear space and intercellular space were widened with increased lipid droplets. There were also many vacuoles in the cytoplasm of these cells (**Figure 5C-F**). However, there were no significant differences in the ultrastructures of the sperms between these two groups. These results indicate that Zeranol could lead to significant pathological changes of the testicles.

Zeranol decreases the sex hormone levels of male mice

Spermatogenesis in the testicles is also regulated by the sex hormones such as T, FSH and LH. Then the levels of serum T, FSH, LH as well as the levels of T of the supernatant of testicles homogenates were detected using RIA after 35 days' treatment with Zeranol. As shown in **Figure 6**, in the groups treated with 50 and 100 mg/kg of Zeranol, the levels of serum T and FSH were significantly lower than those of the control group ($P < 0.05$). In the group treated with 100 mg/kg of Zeranol, the level of serum LH was significantly lower than that of the control group ($P < 0.05$). Zeranol also reduced the levels of testicular T dose dependently. In all the three groups treated with Zeranol, the levels of testicular T were significantly lower than those of the control group ($P < 0.05$). These results indicate that Zeranol could decrease the levels of serum T, FSH, LH as well as the levels of testicular T of male mice.

Discussion

Zeranol has been shown to have estrogenic activity. Estrogen can also be detected in male animals [25]. Estrogen can bind to estrogen

receptors (ERs) and stimulates spermatogenesis and the synthesis of steroids [26, 27]. In this study, Zeranol treatment decreased the epididymal sperm count and sperm motility. Furthermore, it could lead to pseudo scrotal swelling, atrophy of seminal vesicles and testicles, significant pathological changes of the testicles and decrease the levels of serum T, FSH, LH as well as the levels of testicular T of male mice. These results indicate that Zeranol could damages the reproductive system of male mice, which might be due to its roles in the blockage of the physiological functions of ERs by competing with endogenous estrogen for binding to the ERs [28, 29].

Sperm count is an important indicator for detecting the effects of various toxic factors on the spermatogenesis [30]. In all the three groups treated with Zeranol, the epididymal sperm count was significantly lower than that of the control group ($P < 0.05$). Accordingly, Zeranol could also decrease the weights and organ coefficients of testicles. The results of histopathological analysis indicated that the Sertoli cells, Leydig cells, and spermatogenic cells of the testicles were damaged. The sperm motility is closely related to fertility and is one of the important indicators for evaluation of the functions of mature sperms [31]. In the groups treated with Zeranol 50 or 100 mg/kg, the sperm motility was significantly lower than that of the control group ($P < 0.05$). Seminal fluids secreted by seminal vesicles are rich in fructose and ascorbic acid and provide nutrition and energy for sperms. There were seminal vesicles atrophy and reduced seminal fluids production in the mice treated with Zeranol. This might be one of the causes of reduced sperm motility in Zeranol treated mice. Furthermore, it has been reported that Zeranol could damage the cell membrane, lead to overflow of intracellular potassium and interfere electrolyte balance. These may also correlate with reduced sperm motility observed in this study [32, 33]. Compared with the control group, the sperm malformation rates increased in Zeranol treated groups. However, the differences were not significant. It seems that Zeranol does not have toxic effects on DNA. It has been reported that Zeranol was not mutagenic to Salmonella strains [34]. These results indicate that Zeranol could damage spermatogenesis via its direct effects on the testicles.

Spermatogenesis in the testes is also regulated by the hypothalamic-pituitary-testicular axis. Gonadotropin (GTH) cells secrete LH and FSH in response to GnRH. GnRH release could also be regulated by T through a negative feedback loop. LH stimulates T production in Leydig cells and FSH stimulates ABP production in Sertoli cells. ABP binds to T and promotes meiosis of the spermatocytes. In this study, Zearanol could decrease the levels of both serum T and testicular T of male mice. The inhibitory effects of the chemicals with estrogenic activities on sex hormone (such as T) secretion have also been reported by several other groups [7, 35-37]. Furthermore, Zearanol could decrease the levels of serum FSH and LH which was consistent with the reports by Elsasser et al. [38]. Decreased levels of LH and the damage of Leydig cells account for reduced T production as well as decreased levels of serum T released from testicles. Decreased levels of serum T can stimulate GnRH release through a negative feedback mechanism. However, we did not observe increased levels of serum LH and FSH. This might be correlated to the inhibition effects of Zearanol on GTH cells [39]. Decreased levels of T may also lead to reduced secretion of seminal fluids from seminal vesicles.

In conclusion, these results indicate that Zearanol could damage the reproductive functions of adult male animals. It decreased the sperm count and sperm motility via its direct effects on testicular spermatogenic cells, Leydig cells and Sertoli cells. Zearanol could also interfere with sex hormone levels of male mice through its effects on the hypothalamic-pituitary-testicular axis. The effects of Zearanol on the reproductive functions of male mice deserve further investigation. This study provided valuable information for the application of Zearanol and health protection from exposure to Zearanol.

Acknowledgements

This work was supported by the Shandong Science and Technology Key Project (No. ZR-2012CL12).

Disclosure of conflict of interest

None.

Address correspondence to: Zhenling Zhang, Shandong Academy of Occupational Health and Occupational Medicine, Shandong Academy of Medical Sciences, No. 18877 Jingshi Road, Jinan

250002, Shandong Province, P. R. China. Tel: 86-531-82595632; Fax: 86-531-82919903; E-mail: zhangzljn@126.com

References

- [1] Busk OL, Frizzell C, Verhaegen S, Uhlig S, Connolly L, Ropstad E and Sorlie M. Cytosol protein regulation in H295R steroidogenesis model induced by the zearalenone metabolites, α - and β -zearalenol. *Toxicol* 2012; 59: 17-24.
- [2] Dong Y, Yang N, Liu Y, Li Q and Zuo P. The neuroprotective effects of phytoestrogen α -zearalanol on β -amyloid-induced toxicity in differentiated PC-12 cells. *Eur J Pharmacol* 2011; 670: 392-398.
- [3] Fleck SC, Hildebrand AA, Pfeiffer E and Metzler M. Catechol metabolites of zearanol and 17 β -estradiol: a comparative in vitro study on the induction of oxidative DNA damage and methylation by catechol-O-methyltransferase. *Toxicol Lett* 2012; 210: 9-14.
- [4] Baldwin RS, Williams RD and Terry MK. Zearanol: a review of the metabolism, toxicology, and analytical methods for detection of tissue residues. *Regul Toxicol Pharmacol* 1983; 3: 9-25.
- [5] Bandera EV, Chandran U, Buckley B, Lin Y, Isukapalli S, Marshall I, King M and Zarbl H. Urinary mycoestrogens, body size and breast development in New Jersey girls. *Sci Total Environ* 2011; 409: 5221-5227.
- [6] Massart F and Saggese G. Oestrogenic mycotoxin exposures and precocious pubertal development. *Int J Androl* 2010; 33: 369-376.
- [7] Takemura H, Shim JY, Sayama K, Tsubura A, Zhu BT and Shimoi K. Characterization of the estrogenic activities of zearalenone and zearanol in vivo and in vitro. *J Steroid Biochem Mol Biol* 2007; 103: 170-177.
- [8] Wang Y, Li L, Wang CC and Leung LK. Effect of zearanol on expression of apoptotic and cell cycle proteins in murine placenta. *Toxicology* 2013; 314: 148-154.
- [9] Trout WE, Herr CT, Richert BT, Singleton WL, Haglof SA and Diekmann MA. Effects of Zearanol upon luteal maintenance and fetal development in peripubertal gilts. *Anim Reprod Sci* 2007; 99: 408-412.
- [10] Wang Y, Tan W and Leung LK. Zearanol upregulates corticotropin releasing hormone expression in the placental cell line JEG-3. *Toxicol Lett* 2013; 219: 218-222.
- [11] Guerrero-Bosagna C and Skinner MK. Environmentally induced epigenetic transgenerational inheritance of male infertility. *Curr Opin Genet Dev* 2014; 26: 79-88.
- [12] Cevalco A, Urbatzka R, Bottero S, Massari A, Pedemonte F, Kloas W and Mandich A. Endo-

- crine disrupting chemicals (EDC) with (anti)estrogenic and (anti)androgenic modes of action affecting reproductive biology of *Xenopus laevis*: II. Effects on gonad histomorphology. *Comp Biochem Physiol C Toxicol Pharmacol* 2008; 147: 241-51.
- [13] Ye W, Xu P, Zhong S, Jen R, Threlfall WR, Fra-sure CV, Feng E, Li H, Lin SH, Liu JY and Lin YC. In vitro transformation of MCF-10A cells by sera harvested from heifers two months post-Zeranol implantation. *Int J Oncol* 2011; 38: 985-992.
- [14] Staigmiller RB, Brownson RM, Kartchner RJ and Williams JH. Sexual development in beef bulls following zeranol implants. *J Anim Sci* 1985; 60: 342-351.
- [15] Unruh JA, Gray DG and Dikeman ME. Implanting young bulls with zeranol from birth to four slaughter ages: I. Live measurements, behavior, masculinity and carcass characteristics. *J Anim Sci* 1986; 62: 279-289.
- [16] Ballachey BE, Miller HL, Jost LK and Evenson DP. Flow cytometry evaluation of testicular and sperm cells obtained from bulls implanted with zeranol. *J Anim Sci* 1986; 63: 995-1004.
- [17] Vanderwert W, Berger LL, McKeith FK, Baker AM, Gonyou HW and Bechtel PJ. Influence of zeranol implants on growth, behavior and carcass traits in Angus and Limousin bulls and steers. *J Anim Sci* 1985; 61: 310-319.
- [18] Juniewicz PE, Welsh TH Jr and Johnson BH. Effects of zeranol upon bovine testicular function. *Theriogenology* 1985; 23: 565-582.
- [19] Marois G and Marois M. Comparison of the action of an impeded estrogen, frideron, and of estradiol on the seminal vesicles and on the weight of the testicles and accessory sex glands in the rat. II. *J Gynecol Obstet Biol Reprod (Paris)* 1979; 8: 101-105.
- [20] Perez-Martinez C, Garcia-Iglesias MJ, Ferreras-Estrada MC, Bravo-Moral AM, Espinosa-Alvarez J and Escudero-Diez A. Effects of in-utero exposure to zeranol or diethylstilboestrol on morphological development of the fetal testis in mice. *J Comp Pathol* 1996; 114: 407-418.
- [21] Pylkanen L, Jahnukainen K, Parvinen M and Santti R. Testicular toxicity and mutagenicity of steroidal and non-steroidal estrogens in the male mouse. *Mutat Res* 1991; 261: 181-191.
- [22] Perez-Martinez C, Ferreras-Estrada MC, Garcia-Iglesias MJ, Bravo-Moral AM, Espinosa-Alvarez J and Escudero-Diez A. Effects of in utero exposure to nonsteroidal estrogens on mouse testis. *Can J Vet Res* 1997; 61: 94-98.
- [23] Xuan DF, Yi JH and Hua W. Effect of Low Concentration Manganese on Reproductive Function of Mice. *Industrial Health And Occupational Diseases Beijing* 2002; 28: 17-19.
- [24] Hu Y, Wang L and Jiang S. Effects of N, O-carboxymethyl chitosan on abnormality of spermatozoon in mice. *Chin J Clin Rehabil* 2006; 10: 79-81.
- [25] Claus R, Hoang-Vu C, Ellendorff F, Meyer HD, Schopper D and Weiler U. Seminal oestrogens in the boar: origin and functions in the sow. *J Steroid Biochem* 1987; 27: 331-335.
- [26] Rago V, Siciliano L, Aquila S and Carpino A. Detection of estrogen receptors ER- α and ER- β in human ejaculated immature spermatozoa with excess residual cytoplasm. *Reprod Biol Endocrinol* 2006; 4: 36.
- [27] Stabile V, Russo M and Chieffi P. 17 β -estradiol induces Akt-1 through estrogen receptor- β in the frog (*Rana esculenta*) male germ cells. *Reproduction* 2006; 132: 477-484.
- [28] Katzenellenbogen BS, Katzenellenbogen JA and Mordecai D. Zearalenones: characterization of the estrogenic potencies and receptor interactions of a series of fungal beta-resorcylic acid lactones. *Endocrinology* 1979; 105: 33-40.
- [29] Kiang DT, Kennedy BJ, Pathre SV and Mirocha CJ. Binding characteristics of zearalenone analogs to estrogen receptors. *Cancer Res* 1978; 38: 3611-3615.
- [30] Marques CJ, Francisco T, Sousa S, Carvalho F, Barros A and Sousa M. Methylation defects of imprinted genes in human testicular spermatozoa. *Fertil Steril* 2010; 94: 585-594.
- [31] Jeong SH, Kim BY, Kang HG, Ku HO and Cho JH. Effects of butylated hydroxyanisole on the development and functions of reproductive system in rats. *Toxicology* 2005; 208: 49-62.
- [32] Narayana MV and Chinoy NJ. Reversible effects of sodium fluoride ingestion on spermatozoa of the rat. *Int J Fertil Menopausal Stud* 1994; 39: 337-346.
- [33] Sprando RL, Collins TF, Black TN, Rorie J, Ames MJ and O'Donnell M. Testing the potential of sodium fluoride to affect spermatogenesis in the rat. *Food Chem Toxicol* 1997; 35: 881-890.
- [34] Bartholomew RM and Ryan DS. Lack of mutagenicity of some phytoestrogens in the salmonella/mammalian microsome assay. *Mutation Research/Genetic Toxicology* 1980; 78: 317-321.
- [35] Heneweer M, Houtman R, Poortman J, Groot M, Maliepaard C and Peijnenburg A. Estrogenic effects in the immature rat uterus after dietary exposure to ethinylestradiol and zearalenone using a systems biology approach. *Toxicol Sci* 2007; 99: 303-314.
- [36] Minervini F and Dell'Aquila ME. Zearalenone and reproductive function in farm animals. *Int J Mol Sci* 2008; 9: 2570-2584.
- [37] Richter CA, Birnbaum LS, Farabollini F, Newbold RR, Rubin BS, Talsness CE, Vandenbergh JG, Walser-Kuntz DR and vom Saal FS. In vivo effects of bisphenol A in laboratory rodent studies. *Reprod Toxicol* 2007; 24: 199-224.

Effects of α -zearalanol on male mice

- [38] Elsasser TH, Bolt DJ, Bradley BD and Roper M. Acute and chronic changes in adenohipophyseal hormone secretion in sheep during zearanol administration. *Am J Vet Res* 1983; 44: 1068-1071.
- [39] Hassan AH, Kamel G and El-Hommosi FF. The effect of zearanol implantation on some endocrine glands and gonads in fat-tailed lambs. *Z Mikrosk Anat Forsch* 1981; 95: 634-646.