

Original Article

Extramedullary relapse in lumbar spine of patient with acute promyelocytic leukemia after remission for 16 years: a case report and literature review

Zhengmei He, Shandong Tao, Yuan Deng, Yue Chen, Lixiao Song, Banghe Ding, Kankan Chen, Liang Yu, Chunling Wang

Department of Hematology, Huai'an First People's Hospital, Nanjing Medical University, Huai'an 223300, China

Received July 15, 2015; Accepted December 5, 2015; Epub December 15, 2015; Published December 30, 2015

Abstract: Acute promyelocytic leukemia (APL) is a common myeloid leukemia. At the newly diagnosed stage, it can be fatal because of the serious complication-disseminated intravascular coagulation. With the advent and early application of all-trans retinoic acid, most APL patients can achieve a long-term survival, and only a minority of patients will develop extramedullary relapse after remission. The most common site of extramedullary relapse is central nervous system, while other sites are relatively rare. Here, we report a particularly rare APL patient who experienced extramedullary relapse with lumbar spine as the isolated site after a rather long time of remission for 16 years. At the time of relapse, the main clinical manifestations of the patient are obvious low back pain, weakness in lower limbs and limitation of activity. After treatment of local radiotherapy combined with ATRA and arsenic trioxide, the patient achieved and maintained a second complete remission by now.

Keywords: Acute promyelocytic leukemia, extramedullary relapse, lumbar spine, case report, review

Introduction

Acute promyelocytic leukemia (APL) is a common myeloid leukemia, and it is life-threatening at the early stage due to disseminated intravascular coagulation (DIC). However, since the introduction and early application of all-trans retinoic acid (ATRA), the mortality of APL decreased significantly. Currently, the long-term survival rate of APL raised remarkably based on the recommended treatment of ATRA, arsenic trioxide (ATO) and combination chemotherapy, cure can be expected in the majority of patients. However, approximately 10%-25% of APL patients may still experience relapse after complete remission (CR). And incidence of extramedullary relapse of APL is increasing along with the prolonged disease-free survival. The central nervous system (CNS) is the most frequent site of extramedullary relapse in APL, followed by the skin, and the sites can also be found in the external auditory canal, pleura, testes, lung and so on. The recurrence time of APL after remission generally differs from six months to 12 years. Here, we report a case of

APL patient who suffered extramedullary relapse after 16 years of complete remission, and the patient had an extramedullary disease with lumbar spine as the only relapse site, which is, to our knowledge, has been reported previously.

Case report

A 30-year-old woman was admitted to our hospital due to fatigue, dizziness and fever on July 20, 1996. Physical examination revealed skin ecchymosis, no lymph node enlargement, hepatomegaly or splenomegaly. Complete blood examination showed white blood cell (WBC) $16 \times 10^9/L$; hemoglobin (Hb) 78 g/L; platelet (Plt) $46 \times 10^9/L$ and microscopic examination of a blood smear showed 68% blasts with Auer rods. Bone marrow aspiration revealed hypercellular with a diffuse infiltration by typical promyelocytes (96%) and RT-PCR analysis for PML/RAR α fusion gene was positive. Thereby the diagnosis of APL was confirmed. ATRA was administered orally at 45 mg/m²/day and the patient's WBC count rose to the highest level of

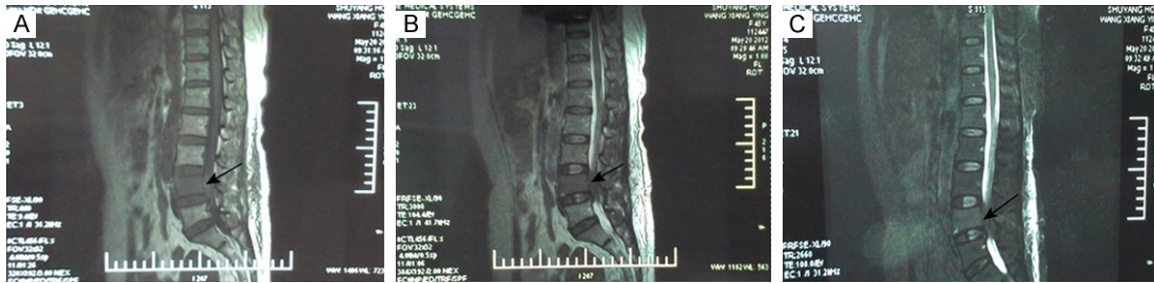

Figure 1. MRI of the lumbar spine revealed impairment in L4, accompanied by hypertrophy of the posterior longitudinal ligament and spinal canal stenosis. The pictures demonstrated low signal intensity of L4 in T1 and T2 phase, and high signal intensity in fat suppression sequence. (A: T1 phase; B: T2 phase; C: Fat suppression sequence; arrow pointed the lesion site in L4).

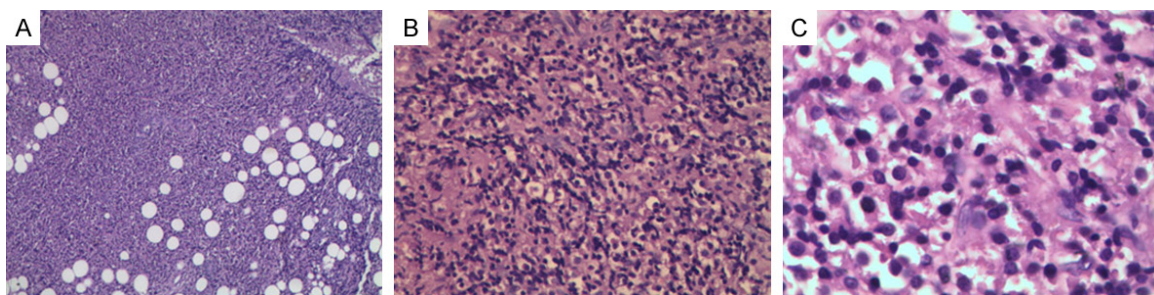


Figure 2. Histopathology examination of the material attached to the lateral vertebral showed diffused distribution of neoplastic cells, mainly granulocytes with infiltrated adipose tissue. (A: Hematoxylin and eosin staining, $\times 4$; B: Hematoxylin and eosin staining, $\times 40$; C: Hematoxylin and eosin staining, $\times 100$).

$44 \times 10^9/L$ during therapy. A month later, bone marrow aspiration was performed again and the evaluation showed a morphologic picture of CR. The patient received sequential consolidation treatment for up to 2 years (from July 20, 1996 to August 3, 1998) before discontinuing the therapy. Periodical follow-up demonstrated persistent CR status and negative PML/RAR α fusion gene.

Five years later (On October 4, 2012), the patient presented to the hospital again with obvious low back pain, weakness in lower limbs and restricted activity. MRI of the lumbar spine revealed impairment in L4, accompanied by hypertrophy of the posterior longitudinal ligament and spinal canal stenosis (**Figure 1**).

The pictures demonstrate low signal intensity of L4 in T1 and T2 phase, high signal intensity in fat suppression sequence. (A: T1 phase; B: T2 phase; C: Fat suppression sequence; arrow pointed the lesion site in L4).

An operation was performed for the patient. Segmental defect of transverse process in L4 and some yellow green material attached to the

lateral vertebral were seen during operation. Histopathology examination of the attachments showed diffused distribution of neoplastic cells, mainly granulocytes, with infiltrated adipose tissue. The immunophenotype characteristics of neoplastic cells were as follows: myeloperoxidase was strongly positive, while CD38, CD79a, CD20, CD3, Syn, and CD117 were negative (**Figure 2**).

The pictures show diffused distribution of neoplastic cells, mainly granulocytes with infiltrated adipose tissue. (A: Hematoxylin and eosin stain, $\times 4$; B: Hematoxylin and eosin stain, $\times 40$; C: Hematoxylin and eosin stain, $\times 100$).

At this time point, complete blood examination was normal, and neither promyelocytes nor blast cells were detected in peripheral blood and bone marrow. Cytogenetic studies showed 46, XX. In addition, PCR analysis for PML/RAR α fusion gene on bone marrow cells confirmed a status of molecular remission. Based on these findings, the diagnosis of extramedullary relapsed APL was made. Since the disease was localized to the lumbar spine, the patient underwent a local radiotherapy with 36Gy. After the

therapy, she was able to walk again and her low back pain improved obviously. Reexamination of local lesion by CT returned to normal. Then she received an alternate therapy of ATRA and ATO for a total of six courses. Currently, she is still in remission and well since the end of treatment.

Discussion

In this paper, we report a rare case of an APL patient who experienced extramedullary relapse with local lesion in lumbar spine after achieving CR for 16 years and one month. Previous studies showed that extramedullary relapse is a relatively rare complication of APL. It is estimated that approximately 3%-5% of APL patients will develop extramedullary relapse [1-3]. However, reports of extramedullary relapse in APL are increasing recently, with the central nervous system as the most frequent site. The likely reasons for this may be as follows [4]: (i) Along with the improving treatment of APL, the patient might suffer extramedullary relapse more likely since they can achieve a prolonged survival; (ii) There's a possibility that the drugs used in the treatment regimens, such as ATRA, ATO and anthracycline, do not penetrate into some special anatomical sites where extramedullary disease eventually occurs. Moreover, the reduced intensity of chemotherapy after ATRA may also increase the incidence of extramedullary relapse; (iii) It is also probable that the biological characteristics of ATRA might contribute to extramedullary relapse of APL. While inducing the differentiation of promyelocytes, ATRA could significantly upregulate the expression of adhesion molecules (LFA-1, VLA-4) which may enhance leukemia cells' ability of adhering to endothelial cells and migrating to extramedullary tissues, resulting in the increasing likelihood of extramedullary relapse [5]. Evans et al. [6] reported that ATRA can upregulate the expression of ICAMs on keratinocytes, so as to promote the proliferation of keratinocytes and increase the possibility of APL recurrence in skin. It is also noted that ATRA may upregulate G-CSF receptors on promyelocytes and make them more sensitive to exogenous or endogenous G-CSF effects, which result in the increased extramedullary lesions of APL patients [7]. These special biological characteristics may be the reason for the increased extramedullary disease after ATRA therapy. Wiernik et al. demonstrated that extramedullary dis-

ease of APL develops more frequently after ATRA than chemotherapy alone [8]. Ko et al. [9] noted that APL patients with ATRA treatment have a 2.1 increased relative risk of extramedullary disease compared with those receiving chemotherapy alone. Ohno et al. [10] suggested that extramedullary relapse was unobserved in all 37 APL patients with chemotherapy only, while it was seen in 8% of 121 APL patients receiving chemotherapy plus ATRA. However, Samanez et al. [11] held that ATRA therapy has no obvious correlation with extramedullary recurrence of APL. Whether the administration of ATRA is the main cause of extramedullary relapse in APL after remission or not remains to be further studied.

Incidence of extramedullary relapse in APL after remission is obviously lower than other types of leukemia. Our case shows an APL patient who suffered extramedullary relapse with an independent site of lumbar spine after remission for 16 years, is particularly rare. The recurrence time of leukemia after CR may be related to the depth of remission, the invasiveness of leukemia cells, the dose of chemotherapy drugs and so on. Extramedullary relapse commonly occurs within 1 year after achieving CR, and can be isolated or can be present precede, concurrently with bone marrow relapse. The most common site of extramedullary relapse in APL patients is CNS. Around 1% of APL patients may suffer CNS relapse in remission [3, 12-14], and approximately 10% of hematologic relapses are accompanied by CNS involvement [6]. In the case described here, the cerebrospinal fluid is normal when extramedullary relapse occurs in lumbar spine and hence we consider the case as a purely isolated extramedullary relapse of lumbar spine.

The prognosis of extramedullary relapse in APL patients is still unclear. Molecular detection of the peripheral blood or bone marrow did not seem to be able to predict whether the patients would suffer extramedullary relapse [2, 3]. But the following risk factors, such as hyperleukocytosis at initial diagnosis ($WBC > 16 \times 10^9/L$), occurrence of differentiation syndrome during treatment, single therapeutic regimen without cytarabine, high expression of CD2 and CD56, PML-RAR α bcr3 isoform expression, may be associated with a higher risk of extramedullary relapse [1, 15-17]. In addition, a previous CNS hemorrhage during induction is also identified

as an independent risk factor for CNS relapse [18]. The case reported here had an initial WBC count of $16 \times 10^9/L$, and it ascended to the highest count of $44 \times 10^9/L$ after ATRA therapy, which might be one of the reasons for extramedullary relapse. At the time when the patient was diagnosed with APL, the detection of CD2 and CD56 expression was not available, so it is not clear whether CD2 and CD56 expression level is relevant to the extramedullary relapse for this case.

The first treatment option for extramedullary granulocyte sarcoma is local radiotherapy. Meanwhile, systemic chemotherapy is also very important. Generally, the recommended drugs are those with strong permeability of passing through the blood brain barrier (BBB), such as high dose cytarabine et al. For these patients, allo-hematopoietic stem cell transplantation (HSCT) or auto-HSCT can also be adopted to cure the disease. The treatment effect of ATO in patients with bone marrow relapse is quite certain, but its efficacy in those with extramedullary recurrence remains unclear at present [19]. Some authors have reported that such drugs can treat diseases by penetrating through BBB which is damaged due to leukemic cells [20-22]. Nevertheless, other studies have considered that ATO cannot kill leukemia cells in cerebrospinal fluid because of its ineffective concentration even if it can pass through BBB [23, 24]. Therefore, the curative effect of ATO in extramedullary relapse of APL patients still needs a further study. The case reported herein underwent extramedullary relapse with independent site of lumbar spine after achieving CR for 16 years. Treatments by removing of the extramedullary lesion, local radiotherapy combined with ATRA and ATO proved to be effective. Currently, the patient remains in CR status for 32 months since her therapy discontinued. The successful diagnosis and treatment of our case may provide a valuable experience for therapy of extramedullary relapsed APL patients.

Extramedullary relapse in APL patients usually occurs at an earlier stage of CR phase, with CNS as the main site. Here, we report a particularly rare APL patient who experienced extramedullary relapse with lumbar spine as the isolated site after a rather long time of remission for 16 years. There are many factors that APL patients develop extramedullary relapse after CR, and the relapse generally has specific clinical

and biological characteristics. It is very important to further explore the early prevention to reduce the occurrence of extramedullary relapse in CR-achieved APL patients.

Acknowledgements

This study was supported by the Natural Science Foundation of Jiangsu Province (No. BK-20141254), "333 projects" Foundation of Jiangsu Province (No. BRA2015152) and "Six talent peaks project" Foundation of Jiangsu Province (No. 2013-WSN-017 and 2015-WSN-099).

Disclosure of conflict of interest

None.

Address correspondence to: Dr. Chunling Wang, Department of Hematology, Huai'an First People's Hospital, Nanjing Medical University, No. 6 Beijing North Road, Huaiyin District, Huai'an 223300, China. E-mail: cnchunlingwang@163.com

References

- [1] De BS, Sanz MA, Chevret S, Dombret H, Martin G, Thomas X, Mediavilla JD, Recher C, Ades L, Quesnel B, Brault P, Fey M, Wandt H, Machover D, Guerci A, Maloisel F, Stoppa AM, Rayon C, Ribera JM, Chomienne C, Degos L, Fenaux P; European APL Group; PETHEMA Group. Extramedullary relapse in acute promyelocytic leukemia treated with all-trans retinoic acid and chemotherapy. *Leukemia* 2006; 20: 35-41.
- [2] Vega-Ruiz A, Faderl S, Estrov Z, Pierce S, Cortes J, Kantarjian H, Ravandi F. Incidence of extramedullary disease in patients with acute promyelocytic leukemia: a single-institution experience. *Int J Hematol* 2009; 89: 489-496.
- [3] Specchia G, Lo Coco F, Vignetti M, Avvisati G, Fazi P, Albano F, Di Raimondo F, Martino B, Ferrara F, Selleri C, Liso V, Mandelli F. Extramedullary involvement at relapse in acute Incidence of extramedullary disease in acute promyelocytic leukemia patients promyelocytic leucemia patients treated or not with all-trans retinoic acid: a report by the Gruppo Italiano Malattie Ematologiche dell'Adulto. *J Clin Oncol* 2001; 19: 4023-4028.
- [4] Ematologia con Trapianto, Università degli Studi di Bari "Aldo Moro". Extramedullary Disease in Acute Promyelocytic Leukemia: Two-in-one disease. *Mediterr J Hematol Infect Dis* 2011; 3: e2011066.
- [5] Di NR, Lo PC, Schiavone EM, Ferrara F, Manzo C, Vacca C, Del VL. All-trans retinoic acid (ATRA)

- and the regulation of adhesion molecules in acute myeloid leukemia. *Leuk Lymphoma* 1996; 21: 201-209.
- [6] Evans GD, Grimwade DJ. Extramedullary disease in acute promyelocytic leukemia. *Leuk Lymphoma* 1999; 33: 219-229.
 - [7] De GA, Toubert ME, Dubois C, Krawice I, Schlageter MH, Balitrand N, Castaigne S, Degos L, Rain JD, Najean Y. Induction of high-affinity GM-CSF receptors during all-trans retinoic acid treatment of acute promyelocytic leukemia. *Leukemia* 1994; 8: 1758-1762.
 - [8] Wiernik PH, De Bellis R, Muxi P, Dutcher JP. Extramedullary acute promyelocytic leukemia. *Cancer* 1996; 78: 25.
 - [9] Ko BS, Tang JL, Chen YC, Yao M, Wang CH, Shen MC, Tien HF. Extramedullary relapse after occurrence of retinoic acid syndrome is a risk factor. *Leukemia* 1999; 13: 1406-1408.
 - [10] Ohno R, Asou N, Ohnishi K. Treatment of acute promyelocytic leukemia: strategy toward further increase of cure rate. *Leukemia* 2003; 17: 1454-1463.
 - [11] Samanez CS, Santillana J, Leon A, Wachtel C. "Pattern of extramedullary relapse in acute promyelocytic leukemia (APL) in Peruvian patients", in Proceedings of the Annual Meeting of American Society of Clinical Oncology (ASCO '02), 2002; 21: abstract no. 1090.
 - [12] Liso V, Specchia G, Pogliani EM, Palumbo G, Mininni D, Rossi V, Teruzzi E, Mestice A, Coppi MR, Biondi A. Extramedullary involvement in patients with acute promyelocytic leukemia: a report of seven cases. *Cancer* 1998; 83: 1522-1528.
 - [13] Burry LD, Seki JT. CNS relapses of acute promyelocytic leukemia after all-trans retinoic acid. *Ann Pharmacother* 2002; 36: 1900-1906.
 - [14] Breccia M, Carmosino I, Diverio D, De Santis S, De Propriis MS, Romano A, Petti MC, Mandelli F, Lo-Coco F. Early detection of meningeal localization in acute promyelocytic leukaemia patients with high presenting leucocyte count. *Br J Haematol* 2003; 120: 266-270.
 - [15] Tallman MS. Treatment of relapsed or refractory acute promyelocytic leukemia. *Best Pract Res Clin Haematol* 2007; 20: 57-65.
 - [16] Ades L, Sanz Miguel A, Chevret S, Montesinos P, Chevallier P, Raffoux E, Vellenga E, Guerci A, Pigneux A, Huguot F, Rayon C, Stoppa AM, de la Serna J, Cahn JY, Meyer-Monard S, Pabst T, Thomas X, de Botton S, Parody R, Bergua J, Lamy T, Vekhoff A, Negri S, Ifrah N, Dombret H, Ferrant A, Bron D, Degos L, Fenaux P. Treatment of newly diagnosed acute promyelocytic leukemia (APL): a comparison of French-Belgian-Swiss and Pethema results. *Blood* 2008; 111: 1078-1084.
 - [17] Montesinos P, Rayón C, Vellenga E, Brunet S, González J, González M, Holowiecka A, Esteve J, Bergua J, González JD, Rivas C, Tormo M, Rubio V, Bueno J, Manso F, Milone G, de la Serna J, Pérez I, Pérez-Encinas M, Krsnik I, Ribera JM, Escoda L, Lowenberg B, Sanz MA; PETHEMA; HOVON Groups. Clinical significance of CD56 expression in patients with acute promyelocytic leukemia treated with all-trans retinoic acid and anthracycline-based regimens. *Blood* 2011; 117: 1799-1805.
 - [18] Montesinos P, Díaz-Mediavilla J, Debèn G, Prates V, Tormo M, Rubio V, Pérez I, Fernández I, Viguria M, Rayón C, González J, de la Serna J, Esteve J, Bergua JM, Rivas C, González M, González JD, Negri S, Brunet S, Lowenberg B, Sanz MA. Central nervous system involvement at first relapse in patients with acute promyelocytic leukemia treated with all-trans retinoic acid and anthracycline monotherapy without intrathecal prophylaxis. *Haematologica* 2009; 94: 1242-1249.
 - [19] Shigeno K, Naito K, Sahara N, Kobayashi M, Nakamura S, Fujisawa S, Shinjo K, Takeshita A, Ohno R, Ohnishi K. Arsenic trioxide therapy in relapsed or refractory Japanese patients with acute promyelocytic leukemia: updated outcomes of the phase II study and postremission therapies. *Int J Hematol* 2005; 82: 224-229.
 - [20] Patriarca F, Fili C, Antonella G, Sperotto A, Prosdocimo S, Fanin R. Activity of all-trans-retinoic acid in a case of central nervous system extramedullary relapse of acute promyelocytic leukemia. *Eur J Haematol* 2002; 68: 310-313.
 - [21] Burry LD, Seki JT. CNS relapses of acute promyelocytic leukemia after all-trans retinoic acid. *Ann Pharmacother* 2002; 36: 1900-1906.
 - [22] Kiguchi T, Yoshino Y, Yuan B, Yoshizawa S, Kitahara T, Akahane D, Gotoh M, Kaise T, Toyoda H, Ohyashiki K. Speciation of arsenic trioxide penetrates into cerebrospinal fluid in patients with acute promyelocytic leukemia. *Leuk Res* 2010; 34: 403-405.
 - [23] Knipp S, Gatterman N, Schapira M, Käferstein H, Gerding U. Arsenic in the cerebrospinal fluid of a patient receiving arsenic trioxide for relapsed acute promyelocytic leukemia with CNS involvement. *Leuk Res* 2007; 31: 1585-1587.
 - [24] Helwig A, Klemm M, Schüttig R, Röllig C, Wassilew N, Ehninger G, Illmer T. Arsenic-induced APL differentiation in cerebrospinal fluid. *Leuk Res* 2007; 31: 703-705.