

Original Article

Laparoscopic repair of iatrogenic vesicovaginal and rectovaginal fistula

Lei Chu*, Jian-Jun Wang*, Li Li, Xiao-Wen Tong, Bo-Zhen Fan, Yi Guo, Huai-Fang Li

*Department of Obstetrics and Gynecology, Tongji Hospital of Tongji University, Shanghai 200065, China. *Equal contributors.*

Received October 19, 2014; Accepted January 17, 2015; Epub February 15, 2015; Published February 28, 2015

Abstract: Objective: To investigate the clinical efficacy of laparoscopic repair of iatrogenic vesicovaginal fistulas (VVF) and rectovaginal fistulas. Methods: Seventeen female patients with iatrogenic fistulas (11 cases of VVF and 6 cases of high rectovaginal fistulas) were included. All patients were hospitalized and underwent laparoscopic fistula repair in our hospital between 2008 and 2012. The mean age of the patients was 44.8 ± 9.1 years. The fistulas and scar tissue were completely excised by laparoscopy, orifices were tension-free closed using absorbable sutures, omental flaps were interposed between the vagina and the bladder or rectum, and drainage was kept after repair. Results: Laparoscopic repair of fistulas was successful in all 17 patients. No complication was found during or after repair. No reoperation was needed after the repair. The operative time was 80.2 ± 30.0 minutes (range 50-140 minutes). The blood loss was 229.4 ± 101.6 ml (range 100-400 ml). The double J catheters were placed in 7 patients and removed 1-2 months after repair. Eight VVF patients underwent cystoscopy 3 months after laparoscopic repair and there were no abnormal findings. The follow-up time was 17.1 ± 6.5 months (range 8-29 months). Conclusion: Laparoscopic repair of VVF and rectovaginal fistulas is a safe and an effective minimally invasive procedure for treatment of iatrogenic fistula.

Keywords: Laparoscopy, extravesical repair, vesicovaginal fistula, rectovaginal fistula

Introduction

Iatrogenic vesicovaginal and rectovaginal fistulas are serious complications of pelvic operations and vaginal delivery and may significantly reduce the quality of life of affected women. The vaginal passage of urine, gas, and stool can cause physical symptoms due to inflammation and depression. Patients may also suffer from significant psychosocial and sexual dysfunction [1].

Most times iatrogenic vesicovaginal and rectovaginal fistulas are due to severe adhesions, excessive sewing, incorrect electric coagulation hemostasis, and neglected injury of the bladder wall or rectum wall during the operation. For patients after a vaginal delivery, vesicovaginal and rectovaginal fistulas are caused by prolonged fetal head compression. The size of fistulas was always large in this situation. Various surgical paths, such as transvaginal, transabdominal, transrectal or a combination

have been used to repair the fistulas. The transabdominal approach is the standard surgical approach for fistula repair, but this method is limited by large injuries and a small field of vision. The laparoscopic repair of fistulas has the advantages of minimal access surgery including minimal wound complications, less blood loss, less postoperative pain and shorter hospital stays. In this study, we investigated the results of laparoscopic repair in patients with vesicovaginal and high rectovaginal fistulas and discuss the safety and effectiveness of this operation.

Material and methods

General data

This study included 17 female patients (11 cases of vesicovaginal fistulas and 6 cases of high rectovaginal fistulas), who were hospitalized and underwent laparoscopic fistula repair in our hospital between 2008 and 2012.

Table 1. Primary diseases of all patients (11 cases of vesicovaginal fistulas and 6 cases of high rectovaginal fistulas)

Primary diseases	Number of cases
Vesicovaginal fistula	11
Endometriosis	5
Myoma of uterus	2
Endometrial cancer	1
Ovarian cancer	1
Pelvic organ prolapsed	2
Rectovaginal fistula	6
Endometriosis	2
Endometrial cancer	1
Pelvic abscess	2
Myoma of uterus	1

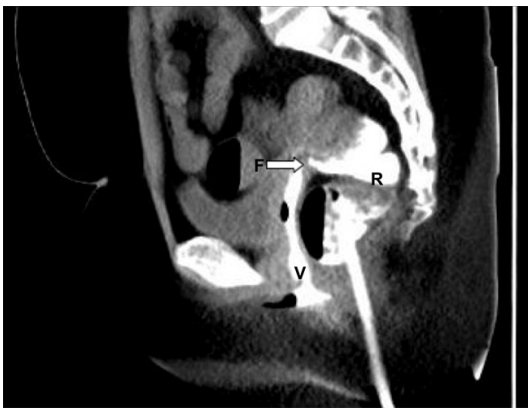

Figure 1. A 58 years old female patient with endometrial cancer received laparoscopic hysterectomy, oophorectomy and pelvic lymphadenectomy. However, vaginal exhaust and defecation occurred 2 weeks after surgery. The patient underwent laparoscopic repair of rectovaginal fistula 2 months after surgery. CT imaging in the coronal plane of rectal perfusion before surgery showed contrast agent flowing into vaginal through the rectovaginal fistula (arrow). V, vaginal; R, rectum; F, fistula.

Patients with vesicovaginal and rectovaginal fistulas due to radiation and recurrent fistulas were excluded from the study. The mean age of the patients was 44.8 ± 9.1 years. The original operations were different in these patients and included 13 patients after laparoscopic or abdominal hysterectomy or simple salpingo-oophorectomy because of endometriosis ($n = 7$), myoma of the uterus ($n = 3$), endometrial cancer ($n = 2$), and ovarian cancer ($n = 1$), 2 after laparoscopic salpingo-oophenrectomy for pelvic abscess, and 2 after pelvic floor reconstruction for pelvic organ prolapse (Table 1).

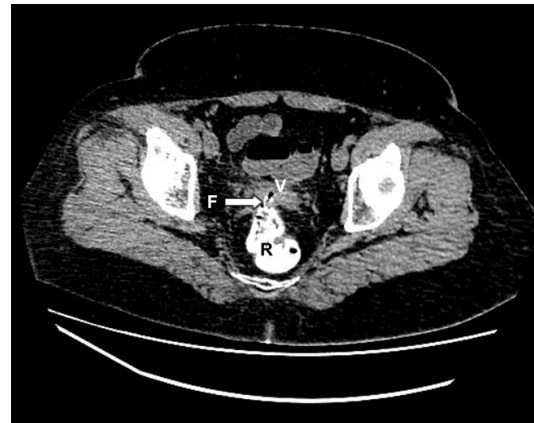

Figure 2. CT imaging of rectal perfusion in horizontal plane indicated contrast agent flowing into vaginal through the fistula at anterior rectal wall (arrow). V, vaginal; R, rectum; F, fistula.

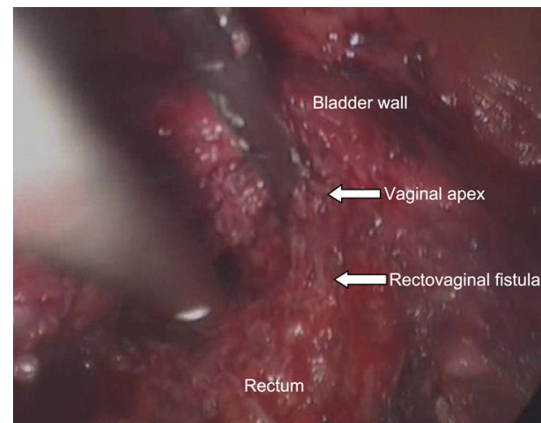


Figure 3. Adhesion between the bladder and rectum was excised under laparoscope until rectovaginal fistulous tract was exposed.

Laparoscopic repair

Laparoscopic repair was performed 2-7 months after the initial surgery. All patients underwent pelvic examination. Fistulas were confirmed by computed tomography, magnetic resonance imaging, voiding cystourethrogram, defecography, and cystoscopy before operation (Figures 1 and 2). Biopsy of the fistula orifice was performed in all patients. Final pathology was negative for malignancy. In all patients, conservative treatment was provided. All cases were performed by the same surgeon.

All patients were given general anesthesia and placed in the lithotomy position. In 7 patients double J catheters were placed in unilateral or

bilateral ureteral occlusions before laparoscopy to protect the ureter. Patients with vesicovaginal fistulas initially underwent cystoscopy, and then Methylene blue was perfused into their bladders until it could be seen in the vagina. A 16 F Foley catheter was inserted into the bladder, and gentle traction was exerted on it. Four trocars (0.5-1 cm) were placed at the umbilicus and hypogastrium. We used the cold light source of xenon lamp (Stryker, USA), laparoscopic instruments (Wolf, Germany) and camera (Olympus, Japan) in all cases.

There were pelvic adhesions in all patients. We released adhesions between the omentum and the anterior abdominal wall to expose the bladder wall and the anterior wall of the rectum first. In three cases of vesicovaginal fistulas with damage near the ureterostoma, we started the operation with dissociation of the ureters. Ultracision harmonic scalpel and microscissors were used carefully to separate the adhesive tissue between the vaginal apex and other organs. In patients with vesicovaginal fistulas, the vagina was separated from the posterior bladder wall until the fistula with methylene blue was exposed. Microscissors were used to completely excise the fistulous tract and scar tissue around it, and electrocautery was prohibited to preserve the viability of the tissue. In two cases with fistulas that had formed during pelvic reconstruction with mesh, the mesh through the fistula was cut off. The vagina was closed in a single layer with continuous 2-0 Vicryl sutures. The urinary bladder was closed in 2 layers using 3-0 Vicryl sutures. We closed the seromuscular layer tension-free as the first layer and serosa only as the second layer. After closure of the bladder, it was filled with 250 ml of Meilan diluent to test its integrity. Omental flaps were routinely used to interpose between the bladder and vaginal apex. In some cases, redundant serosa was attached to the bladder wall. No polypropylene or biological mesh was used. A tube drain was left in all patients at the end of the operation. A 16 F urethral Foley catheter was left in place for 7-16 days. Betadine-soaked roller gauze was inserted into the vagina at the end of the procedure, and this pack was removed on postoperative day 2. Antibiotic treatment was continued for 48-72 hours. After removal of the catheter, patients were asked to urinate every 2 hours and underwent an ultrasound examination for residual urine. All patients were instructed to avoid sexual inter-

course, the use of vaginal tampons, and lifting heavy weights during the first 3 months after the repair (**Figure 3**).

In rectovaginal fistula patients, mechanical bowel preparation was administered 1 day before the surgery. Antibiotics were given pre-operatively. The fistulous tract and scar were cut off with microscissors. The vagina was closed with continuous 2-0 Vicryl sutures. The rectal wall was closed in 2 layers using 3-0 Vicryl sutures. The seams of the rectum and vagina were separated as far as we could to avoid adhesions. After closure of the rectum, 500 ml saline was filled into the pelvis and then 200 ml of air was injected into the rectum to test its integrity. The omental flap was sewn between the rectum and the vagina. A double-cavity cannula was left near the seams of the rectum. A urethral catheter was left in place for 2 days. Antibiotics were used for 3-4 days. Continued double-cavity cannula irrigation and drainage lasted from the second to the seventh day after the operation and the cannula was removed on the ninth day after the operation. Patients were given Nutrison from the second day after the operation and a semi-liquid diet was started on the sixth day. Pinaverium bromide was given in the first week to limit excrement, and lubricant for intestines was given after 1 week. All patients were instructed to take stool softener for 1 month.

Results

Laparoscopic repair of vesicovaginal and rectovaginal fistulas were successful in all 17 patients without conversion to transabdominal repair. No pelvic abscess or associated organ injury was found in any of the patients. No reoperation was needed after repair. The operative time was 80.2 ± 30.0 minutes (range 50-140 minutes). The blood loss was 229.4 ± 101.6 ml (range 100-400 ml), and no one needed blood transfusions. No postoperative stress or urge incontinence occurred in any of the patients. The double J catheters, which were placed during the operations, were removed 1-2 months after the repair, 4/7 of these patients developed urinary tract infections. Eight vesicovaginal fistula patients underwent cystoscopy 3 months after laparoscopic repair and no abnormal findings were detected. The follow-up time was 17.1 ± 6.5 months (range 8-29 months) (**Table 2**).

Table 2. General data of laparoscopic repair of vesicovaginal and rectovaginal fistulas in 17 patients. All procedures were successful without conversion to transabdominal repair or complications

Item	Results
Operative time (min)	80.2 ± 30.0 (range 50-140)
Blood loss (ml)	229.4 ± 101.6 (range 100-400)
Double J catheters placement (n)	7
Cystoscopy (n)	8
Success rate	100%
Complication	0
Bladder drainage of VVF patients (d)	11.1 ± 2.7 (range 7-16)
Follow-up time (month)	17.1 ± 6.5 (range 8-29)

Discussion

Rectovaginal and vesicovaginal fistulas can develop from several conditions, including obstetric trauma, inflammatory bowel disease (rectovaginal fistula), carcinoma, radiation, diverticulitis, and infectious processes. The most common cause of rectovaginal fistulas is obstetric trauma because of prolonged labor. Rectovaginal fistulas can also be found in inflammatory bowel disease, specifically Crohn's disease. Most vesicovaginal fistulas occur after a complex hysterectomy and distocia. There were many reasons for iatrogenic fistulas, including obstetrical factors such as forceps delivery, midline episiotomy, and third degree perineal lacerations [2]. Other factors included electric injury during operation, penetration of the bladder wall or rectal wall when sewing up the vaginal apex, avascular necrosis of tissues due to compression of the fetal head and local infection. The prevalence of vesicovaginal fistulas was 0.1-0.2% [3].

Iatrogenic vesicovaginal and rectovaginal fistula are a surgical challenge, and a burden on society and the patients due to the low success rate of conservative therapy and the difficulty of repair. The quality of life was very low for patients because of the distress and social limitations due to urine leakage. Most patients cannot accept recurrence of fistulas; therefore, it is important to cure the fistula on the first attempt with minimally invasive surgery. The successful management of fistulas depends on the etiology, size, location of the orifice, and expertise of the surgeon. For example, low rectovaginal fistulas are usually repaired through the transvaginal approach, but high rectovagi-

nal fistulas are not suitable for transvaginal repair because of limited vision and difficult separation of different tissues. Imaging examination is very important before developing the surgical plan. Doganov and his partner reported that 10-15% patients with iatrogenic vesicovaginal fistulas had other urinary system trauma [4]. It is our experience that voiding cystourethrogram or defecography by CT or MRI is needed for every patient before the repair to indicate the size and location of the fistula.

Cystoscopy can be chosen before or during vesicovaginal fistula repair. Methylene blue, a guide wire and probe are useful in searching for the fistula during the repair.

Controversy still exists over the optimal timing of the surgical approach and need for adjuvant measures. Conservative therapy could be started immediately when the diagnosis is made, including bladder drainage with a urethral catheter, cannula irrigation and drainage (for rectovaginal patients), and antibiotic use for patients with small fistulas. However, the cure rate of conservative therapy is low (7-12.5% in vesicovaginal fistula) [5, 6]. There is no consensus regarding the reasonable waiting period before surgery. There are many surgical approaches for fistula repair, including transabdominal, transvaginal, and transvesical. The vaginal approach seems to be simpler, safer and quicker for small and simple fistulas, while the abdominal approach may be indicated in complex fistulas. In 1852, James Marion Sims published the first report of a successful transabdominal repair of VVF [7]. Laparoscopic repair of VVF was first reported by Nezhat in 1994 [8], who also first reported successful laparoscopic repair of a rectovaginal fistula in 1998 [9], and since then a lot of reports on laparoscopic repairs of vesicovaginal or rectovaginal fistulas have been published [1, 3, 8, 10-42], including robotic repair [3, 21, 38-40]. The success rate is approximately 93.5% [12], similar to the outcomes of the transabdominal approach (94-100%) [43]. The advantage of laparoscopic repair is clear, it results in less pain, faster recovery, and shorter hospital stay. For the surgeons, laparoscopy can provide a clear view, magnify the fine structures, and expose the fistula quickly in a narrow space. The major rea-

son for iatrogenic fistulas is local adhesions, and laparoscopy is helpful in separating complex pelvic adhesions.

The ideal time for surgical repair of a fistula is still uncertain. Traditionally, there must be at least 3 months before inflammatory reaction has completely subsided. In our study, the time between the initial surgery and laparoscopic repair was 2-7 months. Two patients underwent repair just 2 months after the first surgery. One case was VVF, which occurred after simple a salpingo-oophorectomy for pelvic endometriosis, and another case was a rectovaginal fistula attributed to laparoscopic hysterectomy for endometrial cancer. The orifices of the two cases were smaller than 1 cm, and there was no serious infection in them. In a study by Zhang, 18 patients with supratrigonal VVF underwent laparoscopic repair 10 days to 4 weeks after initial operation and none of the fistulas recurred [13]. He concluded that early laparoscopic repair of supratrigonal vesicovaginal fistulas was safe and effective. However, there is not enough evidence to support early repair.

There are some basic principles of fistula repair. One should locate the orifice accurately before the repair to ensure clear exposure of the fistula and surrounding structures, complete excision of the fistula and scar tissue including mesh, adequate mobilization of the bladder or rectum from the vagina, closure of the bladder, rectum, and vagina in separate layers, tension-free suture of the bladder and rectum, well-vascularized autograft tissue interposition (omentum) between the vagina and bladder or rectum, avoiding electric coagulation hemostasis around the orifice, and continuous drainage postoperatively [8, 12-14, 27, 42]. Successful repair depends on the experience and skill of the surgeon, particularly when dealing with complex urologic cases. Careful separation can reduce the additional injury of the rectum and bladder wall and maintain adequate blood supply. Interposition of well-vascularized flaps also play an important role for successful repair of the fistula as it ensures isolation of the two suture lines and provides a good blood supply [14, 42], and the omentum is the ideal tissue. The double J catheters can protect ureters during the operation especially in cases with serious pelvic adhesions. However, there is a high proportion of urinary tract infection in patients

who underwent placement of double J catheters (4/7 in our study); therefore, this is not a routine step. Double-cavity cannulas were placed near the seam of rectum in all 6 rectovaginal fistula patients in our study, and ongoing irrigation and drainage were used to keep tissue of the repair clean so that potential leakage could close itself. In other reports, the success rate was high without double-cavity cannulas, indicating that this is not a routine step either [42]. The urethral catheter should be kept for 7 to 21 days after VVF repair, based on the size of the orifice. A cystography examination is recommended during follow-up.

In conclusion, laparoscopic repair of VVF and rectovaginal fistula is a safe and effective minimally invasive procedure for treatment of iatrogenic fistulas, and for many patients it is a good alternative to the transabdominal approach. However, advanced laparoscopic skills, particularly with intracorporeal suturing and pelvic surgery are required.

Disclosure of conflict of interest

None.

Address correspondence to: Huai-Fang Li, Department of Obstetrics and Gynecology, Tongji Hospital of Tongji University, 389 Xincun Rd, Shanghai 200065, China. E-mail: lihuaifangdoc@163.com

References

- [1] Sands BE, Blank MA, Patel K and van Deventer SJ. Long-term treatment of rectovaginal fistulas in Crohn's disease: response to infliximab in the ACCENT II Study. *Clin Gastroenterol Hepatol* 2004; 2: 912-920.
- [2] Tebeu PM, de Bernis L, Doh AS, Rochat CH and Delvaux T. Risk factors for obstetric fistula in the Far North Province of Cameroon. *Int J Gynaecol Obstet* 2009; 107: 12-15.
- [3] Melamud O, Eichel L, Turbow B and Shanberg A. Laparoscopic vesicovaginal fistula repair with robotic reconstruction. *Urology* 2005; 65: 163-166.
- [4] Doganov N and Dimitrov R. [Surgical treatment of post hysterectomy vesicovaginal fistulas: our experience of more than a decade]. *Akush Ginekol (Sofia)* 2007; 46: 47-51.
- [5] Hilton P and Ward A. Epidemiological and surgical aspects of urogenital fistulae: a review of 25 years' experience in southeast Nigeria. *Int Urogynecol J Pelvic Floor Dysfunct* 1998; 9: 189-194.

- [6] Hilton P. Vesico-vaginal fistula: new perspectives. *Curr Opin Obstet Gynecol* 2001; 13: 513-520.
- [7] Sims JM. On the treatment of vesico-vaginal fistula. *Am J Med Sci* 1852; 23: 59-82.
- [8] Nezhat CH, Nezhat F, Nezhat C and Rottenberg H. Laparoscopic repair of a vesicovaginal fistula: a case report. *Obstet Gynecol* 1994; 83: 899-901.
- [9] Nezhat CH, Bastidas JA, Pennington E, Nezhat FR, Raga F and Nezhat CR. Laparoscopic treatment of type IV rectovaginal fistula. *J Am Assoc Gynecol Laparosc* 1998; 5: 297-299.
- [10] Puntambekar SP, Desai R, Galagali A, Joshi GA, Joshi S, Kenawadekar R, Pandit A, Aitwade A and Puntambekar SS. Laparoscopic transvesical approach for vesicovaginal fistula repair. *J Minim Invasive Gynecol* 2013; 20: 334.
- [11] Utrera NM, Foneron A and Castillo OA. Laparoscopic vesicovaginal fistula repair. *Arch Esp Urol* 2012; 65: 887-890.
- [12] Simforoosh N, Soltani MH, Lashay A, Ojand A, Nikkar MM, Ahanian A and Sharifi SH. Laparoscopic vesicovaginal fistula repair: report of five cases, literature review, and pooling analysis. *J Laparoendosc Adv Surg Tech A* 2012; 22: 871-875.
- [13] Zhang Q, Ye Z, Liu F, Qi X, Shao C, He X and Zhang D. Laparoscopic transabdominal transvesical repair of supratrigonal vesicovaginal fistula. *Int Urogynecol J* 2013; 24: 337-342.
- [14] Abdel-Karim AM, Mousa A, Hasouna M and El-salmy S. Laparoscopic transperitoneal extravesical repair of vesicovaginal fistula. *Int Urogynecol J* 2011; 22: 693-697.
- [15] Lee JH, Choi JS, Lee KW, Han JS, Choi PC and Hoh JK. Immediate laparoscopic nontransvesical repair without omental interposition for vesicovaginal fistula developing after total abdominal hysterectomy. *JSLs* 2010; 14: 187-191.
- [16] Liu SJ, Ye HY, Li Q, Xu KX, Zhang XP, Yu LP and Wang XF. [Intravesical laparoscopic repair of vesicovaginal fistula]. *Beijing Da Xue Xue Bao* 2010; 42: 458-460.
- [17] Alonso y Gregorio S, Alvarez Maestro M, Cabrera Castillo PM, Hidalgo Togores L and de la Pena Barthel JJ. Laparoscopic repair of the vesicovaginal fistula (laparoscopic O'Connor repair). *Actas Urol Esp* 2009; 33: 1133-1137.
- [18] Shah SJ. Laparoscopic transabdominal transvesical vesicovaginal fistula repair. *J Endourol* 2009; 23: 1135-1137.
- [19] Otsuka RA, Amaro JL, Tanaka MT, Epacagnan E, Mendes JB Jr, Kawano PR and Fugita OE. Laparoscopic repair of vesicovaginal fistula. *J Endourol* 2008; 22: 525-527.
- [20] Erdogru T, Sanli A, Celik O and Baykara M. Laparoscopic transvesical repair of recurrent vesicovaginal fistula using with fleece-bound sealing system. *Arch Gynecol Obstet* 2008; 277: 461-464.
- [21] Schimpf MO, Morgenstern JH, Tulikangas PK and Wagner JR. Vesicovaginal fistula repair without intentional cystotomy using the laparoscopic robotic approach: a case report. *JSLs* 2007; 11: 378-380.
- [22] Tiong HY, Shim T, Lee YM and Tan JK. Laparoscopic repair of vesicovaginal fistula. *Int Urol Nephrol* 2007; 39: 1085-1090.
- [23] Nagraj HK, Kishore TA and Nagalaksmi S. Early laparoscopic repair for supratrigonal vesicovaginal fistula. *Int Urogynecol J Pelvic Floor Dysfunct* 2007; 18: 759-762.
- [24] Modi P, Goel R and Dodia S. Laparoscopic repair of vesicovaginal fistula. *Urol Int* 2006; 76: 374-376.
- [25] Wong C, Lam PN and Lucente VR. Laparoscopic transabdominal transvesical vesicovaginal fistula repair. *J Endourol* 2006; 20: 240-243; discussion 243.
- [26] Sotelo R, Mariano MB, Garcia-Segui A, Dubois R, Spaliviero M, Keklikian W, Novoa J, Yaima H and Finelli A. Laparoscopic repair of vesicovaginal fistula. *J Urol* 2005; 173: 1615-1618.
- [27] Ou CS, Huang UC, Tsuang M and Rowbotham R. Laparoscopic repair of vesicovaginal fistula. *J Laparoendosc Adv Surg Tech A* 2004; 14: 17-21.
- [28] Nabi G and Hemal AK. Laparoscopic repair of vesicovaginal fistula and right nephrectomy for nonfunctioning kidney in a single session. *J Endourol* 2001; 15: 801-803.
- [29] von Theobald P, Hamel P and Febbraro W. Laparoscopic repair of a vesicovaginal fistula using an omental J flap. *Br J Obstet Gynaecol* 1998; 105: 1216-1218.
- [30] Sirithanaphol W, Nethuwakul N and Chotikawanich E. Laparoscopic vesicovaginal fistula repair: a novel approach. *J Med Assoc Thai* 2012; 95 Suppl 11: S11-14.
- [31] Rogers AE, Thiel DD, Brisson TE and Petrou SP. Robotic assisted laparoscopic repair of vesicovaginal fistula: the extravesical approach. *Can J Urol* 2012; 19: 6474-6476.
- [32] Miklos JR and Moore RD. Vesicovaginal fistula failing multiple surgical attempts salvaged laparoscopically without an interposition omental flap. *J Minim Invasive Gynecol* 2012; 19: 794-797.
- [33] Kurz M, Horstmann M and John H. Robot-assisted laparoscopic repair of high vesicovaginal fistulae with peritoneal flap inlay. *Eur Urol* 2012; 61: 229-230.
- [34] Garcia-Segui A. [Laparoscopic repair of vesicovaginal fistula without intentional cystotomy and guided by vaginal transillumination]. *Actas Urol Esp* 2012; 36: 252-258.

- [35] De Ridder D. An update on surgery for vesicovaginal and urethrovaginal fistulae. *Curr Opin Urol* 2011; 21: 297-300.
- [36] Abdel-Karim AM, Moussa A and Elsalmy S. Laparoendoscopic single-site surgery extravesical repair of vesicovaginal fistula: early experience. *Urology* 2011; 78: 567-571.
- [37] Rizvi SJ, Gupta R, Patel S, Trivedi A, Trivedi P and Modi P. Modified laparoscopic abdominal vesico-vaginal fistula repair--"Mini-O'Connor" vesicotomy. *J Laparoendosc Adv Surg Tech A* 2010; 20: 13-15.
- [38] Sears CL, Schenkman N and Lockrow EG. Use of end-to-end anastomotic sizer with occlusion balloon to prevent loss of pneumoperitoneum in robotic vesicovaginal fistula repair. *Urology* 2007; 70: 581-582.
- [39] Sotelo R, Moros V, Clavijo R and Poulakis V. Robotic repair of vesicovaginal fistula (VVF). *BJU Int* 2012; 109: 1416-1434.
- [40] Sundaram BM, Kalidasan G and Hemal AK. Robotic repair of vesicovaginal fistula: case series of five patients. *Urology* 2006; 67: 970-973.
- [41] Bailez MM, Cuenca ES, Di Benedetto V and Solana J. Laparoscopic treatment of rectovaginal fistulas. Feasibility, technical details, and functional results of a rare anorectal malformation. *J Pediatr Surg* 2010; 45: 1837-1842.
- [42] van der Hagen SJ, Soeters PB, Baeten CG and van Gemert WG. Laparoscopic fistula excision and omentoplasty for high rectovaginal fistulas: a prospective study of 40 patients. *Int J Colorectal Dis* 2011; 26: 1463-1467.
- [43] Gozen AS, Teber D, Canda AE and Rassweiler J. Transperitoneal laparoscopic repair of iatrogenic vesicovaginal fistulas: Heilbronn experience and review of the literature. *J Endourol* 2009; 23: 475-479.