

## Case Report

# The diagnosis of gallbladder agenesis: two cases report

Li-Ming Tang, Xin-Fu Wang, Pei-Tu Ren, Guan-Geng Xu, Chen-Sheng Wang

Department of General Surgery, Shaoxing People's Hospital, Shaoxing Hospital of Zhejiang University, Shaoxing, China

Received November 20, 2014; Accepted January 28, 2015; Epub February 15, 2015; Published February 28, 2015

**Abstract:** Congenital absence of the gallbladder is an extremely rare embryological aberration that is frequently mistaken for cholelithiasis; the aim of this study is to investigate the diagnostic methods for agenesis of the gallbladder. Two surgically confirmed gallbladder agenesis cases in our hospital and 75 cases of gallbladder agenesis reported in the literature in China were reviewed. It is extremely difficult to make a correct diagnosis of gallbladder agenesis before operation. When suspected, it may be confirmed by ERCP and MRCP. Interoperate, if no gallbladder can be found during laparoscopy, open surgery should be immediately performed. Clinician's understanding of this disease is of great help in avoiding unnecessary surgical exploration and minimizing the risk of complication. Patients with gallbladder agenesis can be classified into two new types, I: Symptomatic, II: Asymptomatic. Type I can be divided into two subtypes: I a with fatal malformations and I b without fatal malformations.

**Keywords:** Gallbladder agenesis, diagnosis

### Introduction

Gallbladder agenesis without biliary atresia is an extremely rare embryonic aberration. Patients become symptomatic in 23% of cases [1, 2], and gallbladder agenesis will almost always be misinterpreted as cholecystitis with cystic duct obstruction or as a sclero-atrophic gallbladder. Misdiagnosis leads unnecessary operations. We reviewed 77 cases of gallbladder agenesis. The 75 cases reported in the literature of "The China National Knowledge Infrastructure (CNKI)" from Jan 1994 to Jan 2006. Keyword search used was gallbladder agenesis. In 1991 and 2006, 2 cases of gallbladder agenesis were reported in our hospital, and these are briefly described.

### Materials and methods

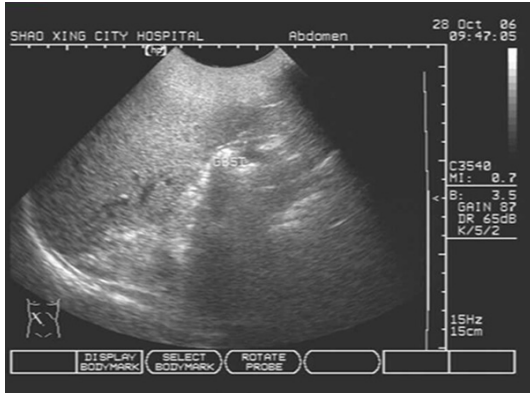
#### Cases in our hospital

**Case 1:** The 44-year-old man was admitted to our hospital because of confirmed gallstone under transabdominal ultrasonography in a routine physical examination. He presented no right upper bellyache, no nausea, no vomiting, no chill, and no fever. Repeated ultrasonography showed a 3.1 cm×1.1 cm gallbladder

(**Figure 1**), with arc-shaped light band inside and acoustic shadow backside, with no choledochectasia. Physical examination: no yellow skin and sclera, belly flat and soft, no tenderness, and negative Murphy's sign. He was diagnosed with cholelithiasis and cholecystic atrophy. The patient was taken to the operating room for laparoscopic cholecystectomy (LC) on Oct 30th, 2006. The initial exploration failed to find the gallbladder. Laparotomy was immediately adopted. The upper part of common bile duct was dilated to 1.5 cm, but still no gallbladder was seen, no stone was palpitated. Ultrasonography during operation showed a negative result consistent with the postoperative ultrasound and CT scan (**Figure 2**).

**Case 2:** This case was a 45-year-old woman presenting upper bellyache, fever and vomiting for 1 day. Physical examination: T39.3°C; Yellow skin and sclera, flat belly, liver palpitated 3 cm below right costal margin, 4 cm below xiphoid process; upper belly tenderness was noted, with no rebound tenderness, and Murphy's sign negative. B ultrasonography: gallbladder wasn't clearly visualized, approximately 4.0 cm×1.5 cm; The common bile duct was dilated to 2.1 cm inside which a 1.9 cm strong echo can be seen with acoustic shadow. She was diagnosed

## Diagnosis of gallbladder agenesis



**Figure 1.** Ultrasound shows an abdominal solitary large stone (GBST) in the gallbladder.

with chronic atrophic cholecystitis, choledocholith and acute suppurative cholangitis. Open exploration was conducted on Dec 3, 1991. The following was seen: the left half of the liver was 2 times as big as the right half, the hepatic porta was rotated toward the back right direction; gallbladder wasn't detected; common bile duct was dilated to 1.6 cm containing purulent bile but no calculus; a 3 cm×3 cm×3 cm hard mass could be palpitated in the ampulla. Ampulla cancers, acute obstructive suppurative cholangitis, congenital liver malformation combining gallbladder agenesis were diagnosed according to the findings made in the operation. Postoperative CT scan prompted diagnosis of ampulla cancer and gallbladder agenesis. T-tube cholangiography showed lower bile duct obstruction, mild dilation in the intrahepatic bile duct; no contrast material filled where was supposed to be the gallbladder. The patient died 9 months later.

### Literature data

We include 75 cases in this group (**Table 1**). 4 of them presented no symptoms at all, 68 had a history of right-upper-quadrant pain, the others exhibited left-upper-quadrant pain (combining situs inversus viscerum); 34 patients had jaundice; 10 patients had nausea and vomiting; 12 patients complained of a lack of appetite; 19 patients had fever. 69 patients took a preoperative ultrasound study, 4 of whom accepted CT or MRI scan simultaneously. 2 patients took PTC (percutaneous transhepatic cholangiography). The assisted examination wasn't described thoroughly in the clinical data of the other 4 patients.

Preoperative diagnosis (**Table 1**): 2 cases were diagnosed with congenital gallbladder agenesis, 3 were congenital gallbladder agenesis with choledocholith, 36 were cholelithiasis, 5 were cholelithiasis with choledocholith, 20 were choledocholith, 2 were atrophic cholecystitis, 1 was atrophic cholecystitis and jaundice without definite cause, 2 were acute cholangitis, 1 was choledochal cyst, 1 was abdominal stabbing injury, 1 was left lateral hepatic tumor, 1 was situs inversus viscerum accompanied by choledocholith.

### Treatment

Laparotomy was applied to 73 cases except 1 that had been diagnosed with congenital gallbladder agenesis and 1 that selected laparoscope exploration.

### Postoperative diagnosis (**Table 2**)

Congenital gallbladder agenesis existed in all patients while 39 of them had other combining diseases. Within the 36 cases given the preoperative diagnosis of cholelithiasis, 31 turned out to be congenital gallbladder agenesis and the other 5 combined choledocholith.

Altogether 34 cases (2 misdiagnosed with atrophic cholecystitis, 32 with cholelithiasis) undertook unnecessary operation. Inevitable visceral injuries occurred in the exploration process: 1 in bile duct, 1 in transverse colon, and 1 in duodenum, all of which were properly and quickly fixed. During the operation, 4 took cholangiography, 1 took ultrasonography. After the operation, 6 received CT scan, 4 received ERCP, and others chose ultrasonography as a rechecking method. A gallbladder wasn't discovered in any of these cases.

### Results

Ectopic gallbladder was found in none of these cases, but with the help of explorative surgery, varying degrees of organ malformation were noticed: 3 had lower common bile duct narrowing, 3 had choledochectasia, 1 was a problem with the lower common bile duct valve, and 1 was situs inversus viscerum.

### Discussion

The pathogenesis of gallbladder agenesis is not fully interpreted yet. Currently we view it as a congenital malformation. Hepatic diverticulum in a 4-week-old embryo is regarded as the bud

## Diagnosis of gallbladder agenesis

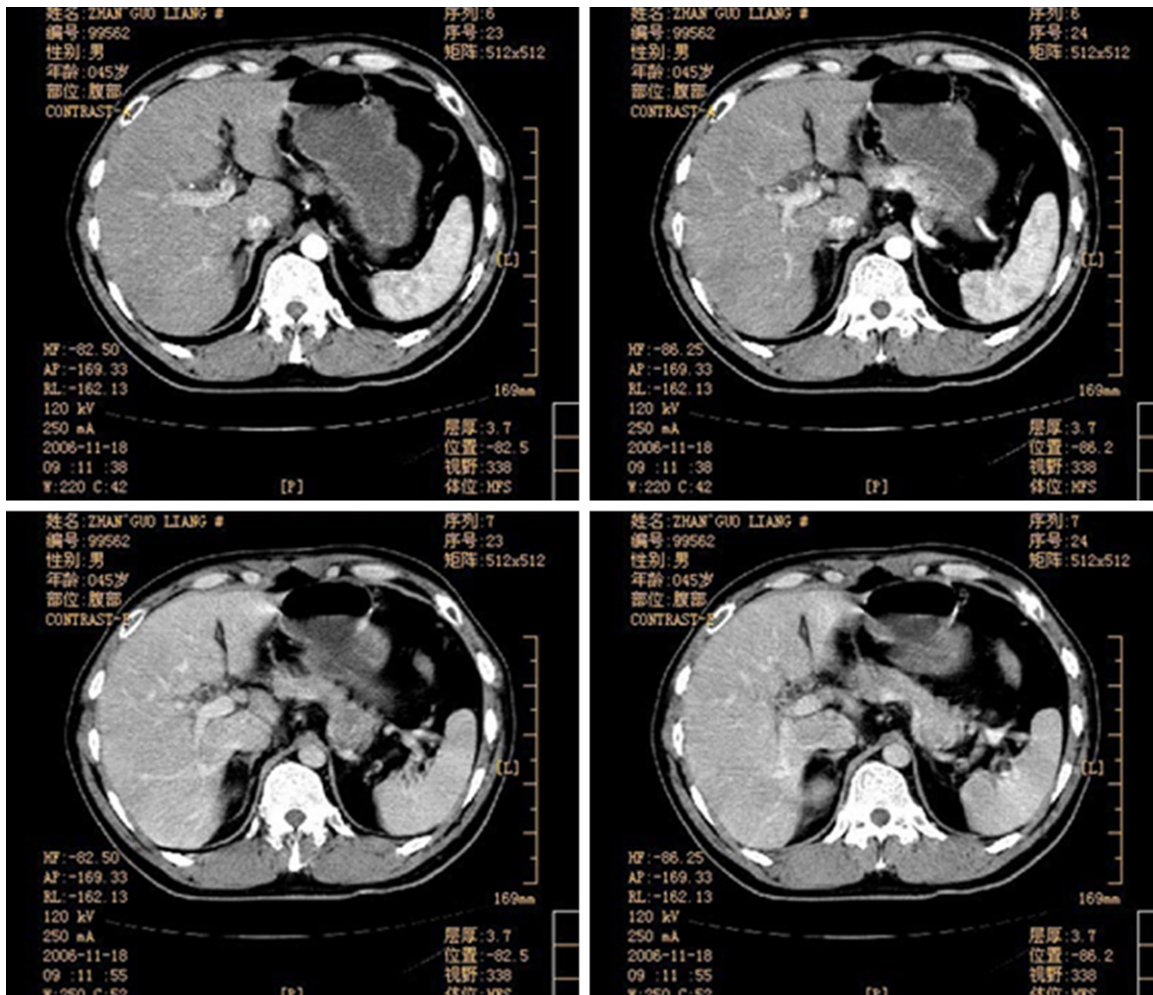


Figure 2. CT scan shows no gallbladder can be found.

of liver, gallbladder and bile duct [3]. The end of hepatic diverticulum expands and separates into caudal and rostral branches. The caudal branch elongates to form a vacuole, which gradually swells. The gallbladder consequently takes its shape (anlage). Meanwhile the proximal narrow segment develops into the cystic duct. The gallbladder is a hollow organ initially, but subsequently transforms to a contemporary solid state because of coating epithelial hyperplasia, which later reopens accompanying epithelial liquefaction. Caudal branch hypoplasia will predispose to gallbladder and cystic duct agenesis. Besides, a solid gallbladder can be detected if the epithelial liquefaction step is missed. Most cases are dispersed, but familial clustering phenomenon also exists [2, 4-9], reminding us that a genetic factor may play a part in the pathogenesis of gallbladder agenesis. However no such case was found in our study.

According to the literature, the incidence of gallbladder agenesis is 0.013%~0.075% [10] overseas and 0.07%~0.38% in China [11-13]. Bennion *et al.* [14] classification methods are most frequently referred to. There are 3 categories: (1) multiple congenital malformations: occupying 12.8%~30% of the total cases, in which 9% are combined with biliary atresia, 12.8%~21% combined other deformities with normal bile ducts. Most of these patients died shortly after their birth. (2) Asymptomatic type: occupies 31.6%. The absence of gallbladder was discovered accidentally in autopsy, other open surgeries, or when the patients' relatives undergo medical screening. (3) Symptomatic type: occupies 55.6%. Symptomatology includes biliary symptoms consistent with an intact gallbladder, such as right-upper-quadrant pain, nausea, vomiting, and intolerance to fatty foods, dyspepsia, jaundice, and choledocholith.

## Diagnosis of gallbladder agenesis

**Table 1.** Preoperative diagnosis

Preoperative diagnosis	Cases in our hospital	Cases In the literature
Congenital gallbladder agenesis		2
Congenital gallbladder agenesis, choledocholith		3
Cholelithiasis	1	36
Cholelithiasis, choledocholith		5
Choledocholith		20
Cholelithiasis, choledocholith, acute suppurative cholangitis	1	
Atrophic cholecystitis		2
Atrophic cholecystitis and jaundice without definite cause		1
Acute cholangitis		2
Choledochal cyst		1
Abdominal stabbing injury		1
Left lateral hepatic tumor		1
Situs inversus viscerum accompanied by choledocholith		1
Total	2	75

**Table 2.** Postoperative diagnosis

Postoperative diagnosis	Cases in our hospital	Cases In the literature
Congenital gallbladder agenesis	1	36
Congenital gallbladder agenesis, choledocholith	1	27
Congenital gallbladder agenesis, ampullae's cancer, choledocholith		1
Congenital gallbladder agenesis, acute cholangitis		3
Congenital gallbladder agenesis, choledochal cyst		1
Congenital gallbladder agenesis, abdominal stabbing injury		1
Congenital gallbladder agenesis, left lateral hepatic tumor		1
Congenital gallbladder agenesis, situs inversus viscerum combining choledocholith		1
Congenital gallbladder agenesis, choledocholith, lower common bile duct narrowing		3
Congenital gallbladder agenesis, choledocholith, lower common bile duct valve		1
Total	2	75

After analyzing the data, we find Bennion's classification is not appropriate enough. His criterion isn't united. Type (1) is actually multiple congenital malformations, while gallbladder agenesis is just one insignificant part, imposing no threat on people's lives. Congenital malformation can be divided into lethal and nonlethal kinds. Under the former circumstance, infants may die in the perinatal period, but babies could survive and manifest the symptoms mentioned above if the situation happened to be the latter one. There is an overlap between Bennion's (1) and (3) types promoting confusion. Take, for example, case 2 in our hospital. Congenital liver malformation and gallbladder agenesis coexist in the same patient. Similar cases can be found in the literature. Dual attribution becomes a tough problem. Here we suggest a classification method as below, I: symp-

tomatic type: can be further divided into I a and I b subtypes. Type I a: Accompanied by lethal deformities such as biliary atresia, ventricular septal defect, imperforate anus, duodenal atresia, etc. The majority of suffers die shortly after birth; I b: Accompanied by nonlethal deformities such as intestinal malrotation, right liver agenesis, cryptorchism, choledochal cyst, choledochectasia, etc. In this study, the major clinical manifestations include: right-upper-quadrant pain 95.8% (69/72), nausea and vomiting 15.3% (11/72), lack of appetite 16.7% (12/72), jaundice 48.6% (35/72), fever 27.8% (20/72). II: Asymptomatic type: it accounts for approximate 6.5% (5/77) of all cases.

Type I b occupies a proportion of 93.5% (72/77) which is significantly higher than the other types, similar to the figure 94% reported by lit-

## Diagnosis of gallbladder agenesis

erature overseas [13]. The attributable reasons maybe: the collaboration of gallbladder, bile duct and the Oddi sphincter in bile reservation and discharge under neural and humoral control is interrupted, resulting in the Oddi sphincter dysfunction and bile duct dyskinesia; in addition, the presence of other deformities within the bile system such as congenital Oddi sphincter dysfunction, bile duct dyskinesia, choledochectasia, etc, ought to be responsible for the figure; or possibly all the reasons mentioned above coexist. All these will promote biliary stasis, infection, choledocholith and corresponding biliary symptoms [15, 16]. The incidence of choledocholith is 44.2% (34/77) in our study object accords with the statistical result overseas that ranged from 20% to 50% [14, 17].

Compared to Bennion's statistics, the proportion of type I a and II seems relatively low. We attribute this to the inadequacy of physical examination and autopsy popularization where the error emerges. Nevertheless, when consulting the statistics of Zhou JZ *et al.* [18], gallbladder agenesis accounts for just 3.4% in paediatric congenital multiple malformations.

Although ultrasonography and other image diagnostic technology provide us with high veracity and classification criteria, gallbladder agenesis is still a difficult thing to diagnose before operation [1, 15, 19-24]. Almost all the symptomatic gallbladder agenesis is confirmed through cystectomy under either transabdominal or laparoscope, but asymptomatic cases are generally detected in autopsy, irrelevant open surgery or screening of patients' family members [25]. 34 (33+1) patients, equal to 44.7% (34/76) of our total objects were misdiagnosed and suffered unnecessary operations.

Misdiagnosis is responsible for unnecessary operations. The common reasons for misdiagnosis are: (1) apparent biliary symptoms such as right-upper-quadrant pain, nausea and vomiting, lack of appetite, jaundice, pyrexia; CA199 may elevate in one or two patients [26], (2) false positive B ultrasound report: intestinal artifacts [27], bile duct dilation and calculus, strip-form fibrous tissue at the normal position of gallbladder [28, 29], (3) Ultrasound doctors and surgeons didn't include this diagnosis into their logical speculation because the chance to come across this malformation in their clinical

experience is so rare. Neglect of this congenital malformation is a dominating reason for misdiagnosis.

Regarding the high frequency of misdiagnosis, we recommend that suspected patients with preoperative B ultrasonographic findings of absent or atrophic gallbladder should undergo further examinations such as CT, ERCP [7, 20, 30-32], and MRC [33, 34] in order to avoid unnecessary operation [36]. Chao *et al.* [37] retrospectively analyzed the preoperative assisted examinations of 9 patients who were later diagnosed with gallbladder agenesis in the operation. He found CT is of great use in elevating preoperative diagnosis rate while cutting down open exploration rate. Orlando *et al.* [38] believe MRCP following B ultrasonograph also helps.

There is another viewpoint proposing laparoscopic exploration [16, 39], but we think if no gallbladder can be found during the exploration, open surgery should be immediately performed. Because ectopic locations for the gallbladder must be excluded before the diagnosis of gallbladder agenesis is made, careful exploration should be carried out. Ectopic gallbladders may be located in the liver, between the leaves of the lesser omentum, in the retroperitoneum and retrohepatic region, within the falciform ligament, or in the retroduodenal and retropancreatic area. Such locations are difficult to reach with a laparoscope [40], ultrasonography [13, 37] or cholangiography [17, 41] can help with the diagnosis. However, excessive exploration may bring on visceral damage [39, 42, 43] because of the presence of anatomic variation in the bile duct system and the difficulty in exposing the Calot triangle [44]. 4 cases [13, 45, 46] in our study suffered iatrogenic injury during the exploration.

Currently, preoperative diagnosis of gallbladder agenesis is still very difficult, but sufficient cognition of this disease can help doctors distinguish suspected cases, make a correct diagnosis, avoid unnecessary operations and lessen exploration complications.

### Acknowledgements

The authors gratefully acknowledge Guo HY, M.D. and Zhou JQ, M.D. from Shaoxing Hospital of Zhejiang University, for critical reading of the

## Diagnosis of gallbladder agenesis

manuscript. Wu X, M.D. and Wendy from Shaoxing University, for collection the foreign data.

### Disclosure of conflict of interest

None.

**Address correspondence to:** Li-Ming Tang, Department of General Surgery, The First Affiliated Hospital of Shaoxing University, Shaoxing People's Hospital, Shaoxing, China. Tel: 0086 13505755800; Fax: 0086 575 88622386; E-mail: limingtangcn@163.com

### References

- [1] Serour F, Klin B, Strauss S and Vinograd I. False-positive ultrasonography in agenesis of gallbladder: a pitfall in the laparoscopic cholecystectomy approach. *Surg Laparosc Endosc* 1993; 3: 144.
- [2] Nadeau LA, Cloutier WA, Konecki JT, Morin G, Taylor RW. Hereditary gallbladder agenesis: twelve cases in the same family. *J Maine Med Assoc* 1972; 63: 1.
- [3] Blechschmidt CM. Agenesis of the gallbladder-borderline case of normality? *Anat Anz* 1982; 151: 281.
- [4] Kabiri H, Domingo OH and Tzarnas CD. Agenesis of the gallbladder. *Curr Surg* 2006; 63: 104.
- [5] Wilson JE and Deitrick JE. Agenesis of the gallbladder: case report and familial investigation. *Surgery* 1986; 99: 106.
- [6] Sterchi RB and Baraitser M. Multiple congenital anomalies. A diagnostic compendium. 1st edition. Cambridge: Chapman and Hall Medical; 1991. pp. 109.
- [7] Venuta A, Laudizi L, Miceli F, Pantusa M and Laudizi Z. Agenesis of the gallbladder. Description of 2 cases in 2 siblings. *Pediatr Med Chir* 1989; 11: 465.
- [8] Becker IW and Mastroni PP. Congenital absence of the gallbladder with a family history. *Am Surg* 1979; 45: 541.
- [9] Kobacker JL. Congenital absence of the gallbladder: a possible hereditary defect. *Ann Int Med* 1950; 25: 1008.
- [10] Singh B, Satyapal KS, Moodley J, Haffjee AA. Congenital absence of the gall bladder. *Surg Radial Anat* 1999; 21: 221.
- [11] Wang CH, Cai ZJ and Wang H. Gall bladder agenesis in abdominal operation: the report of six cases. *Journal of Hepatobiliary Surgery* 2003; 11: 160.
- [12] Zheng MH, Chen JR and Zhou WJ. Congenital gallbladder agenesis combining choledocholith: two cases report. *Chinese Journal of Hepatobiliary Surgery* 2000; 6: 86.
- [13] Li XY, Gao WS and Yang ZY. Congenital gallbladder agenesis: four cases report. *Chinese Journal of Surgery* 2003; 41: 874.
- [14] Bennion RS, Thompson JE JR and Tompkins RK. Agenesis of the gallbladder without extrahepatic biliary atresia. *Arch Surg* 1988; 123: 1257.
- [15] Gotohdan N, Itano S, Horiki S, Endo A, Nakao A, Terada N, Tanaka N. Gallbladder agenesis with no other biliary tract abnormality: report of a case and review of the literature. *Hepatobiliary Pancreat Surg* 2000; 7: 327.
- [16] Akoh JA, George MM, Auld CD, Walls AD. Congenital absence of the gallbladder: ways of avoiding laparotomy. *Br J Clin Pract* 1994; 48: 77.
- [17] Jackson RJ and McClellan D. Agenesis of the gallbladder: a cause of false-positive ultrasonography. *Am Surg* 1989; 55: 36.
- [18] Zhou JZ, Wu S and Chen L. Pathological Analysis of Fatal Malformations From 515 Perinatal Autopsies. *Chinese Journal of Perinatal Medicine* 2003; 6: 96.
- [19] Sabiston CS. *Surgery*. 15th edition. Philadelphia: W. B. Saunders; 1997. pp. 118.
- [20] Cabajo CM, Martin del Olmo JC, Blanco AJ, Atienza Sanchez R. Gallbladder and cystic duct absence. An infrequent malformation in laparoscopic surgery. *Surg Endosc* 1997; 11: 483.
- [21] Amaral JF and Ferland R. Agenesis of the gallbladder: laparoscopic diagnosis. *Surg Laparosc Endosc* 1993; 3: 337.
- [22] Belli G, D'Agostino A, Iannelli A, Rotondano G and Ceccarelli P. Isolated agenesis of the gallbladder. An intraoperative problem. *Minerva Chir* 1997; 52: 1119.
- [23] Kestenholz PB, von FM and Harder F. Agenesis of the gallbladder in adults: a laparoscopic diagnosis. *Chirurg* 1997; 68: 643.
- [24] Azmat N, Francis KR, Mandava N and Pizzi WF. Agenesis of the gallbladder revisited laparoscopically. *Am J Gastroenterol* 1993; 88: 1269.
- [25] Peloponissios N, Gillet M, Cavin R and Halkic N. Agenesis of the gallbladder: A dangerously misdiagnosed malformation. *World J Gastroenterol* 2005; 11: 6228.
- [26] Trompetas V, Panagopoulos E and Ramantanis G. Gallbladder agenesis presenting with obstructive jaundice and elevated CA 19-9. *Acta Chir Belg* 2004; 104: 347.
- [27] Tian BS, Huo XH and Zhang JS. Congenital gallbladder agenesis: two cases report. *Chinese Journal of Surgery of Integrated Traditional and Western Medicine* 2004; 10: 31.
- [28] Lv DC and Yang FN. A case report of congenital gallbladder agenesis with common hepatic (bile) duct valve. *Chinese Journal of Pediatric Surgery* 1998; 19: 225.

## Diagnosis of gallbladder agenesis

- [29] Jiang W, Cao H and Wang YY. A case of misdiagnosis of congenital gallbladder agenesis. *Chinese Journal of Ultrasound in medicine* 2000; 16: 544.
- [30] O'Sullivan J, O'Brien PA, MacFeely L and Whelton MJ. Congenital absence of the gallbladder and cystic duct: nonoperative diagnosis. *Am J Gastroenterol* 1987; 82: 1190.
- [31] Lotz G and Stahlschmidt M. Agnesis of the gallbladder. *Chirurg* 1986; 57: 37.
- [32] Kennard GK. Congenital agnesis of the gallbladder. A diagnostic problem. Report of a case. *Mil Med* 1985; 150: 283.
- [33] Chan FL, Chan JK and Leong LL. Modern imaging in the evaluation of hepatolithiasis. *Hepato-gastroenterology* 1997; 44: 358.
- [34] Vanbeckevoort D, Van HL, Ponette E, Marchal G, Bosmans H and De CB. Imaging of gallbladder and biliary tract before laparoscopic cholecystectomy: comparison of intravenous cholangiography and the combined use of HASTE and singleshot RARE MR imaging. *J Belge Radiol* 1997; 80: 6.
- [35] Schuster DM, Pedrosa MC and Robbins AH. Magnetic resonance cholangiography. *Abdom Imaging* 1995; 20: 353.
- [36] Xiao M, Li JL and Wei XM. Three cases of congenital gallbladder anatomical variation. *Chinese Journal of Hepatobiliary Surgery* 2003; 9: 523.
- [37] Chao CH, Suh KW, Min JS, Kim CK. Congenital absence of gallbladder. *Yonsei Med J* 1992; 33: 364.
- [38] Orlando R, Candiani F and Lirussi F. Agnesis of the gallbladder associated with Gilbert's syndrome. *Surg Endosc* 2001; 15: 757.
- [39] Peloponissios N, Gillet M, Cavin R, Halkic N. Agnesis of the gallbladder: a dangerously misdiagnosed malformation. *World J Gastroenterol* 2005; 11: 6228.
- [40] Raju SG. Agnesis of the gallbladder in two adults: brief review of the literature. *Am J Gastroenterol* 1972; 57: 55.
- [41] Kwon AH, Yanagimoto H, Matsui Y, Imamura A. Agnesis of the gallbladder with hypoplastic cystic duct diagnosed at laparoscopy. *Surg Laparosc Endosc Percutan Tech* 2006; 16: 251.
- [42] Pan WQ, Yin YM and Ai H. Gallbladder agnesis: two cases report. *Chinese Journal of General Surgery* 2002; 10: 101.
- [43] Peng XQ, Wei QZ and Nie H. The misdiagnosis of congenital gallbladder agnesis with cholelithiasis. *Beijing Medical Journal* 2006; 28: 346.
- [44] Dalla Torre A, D'Amata G, Perri SG, Pietrasanta D, Palmieri I, Moraldi A. Isolated agnesis of the gallbladder: case report. *G Chir* 2004; 25: 294.
- [45] Liu C, Lv Y and Wang ZF. The lessons in the diagnosis and treatment of congenital gallbladder agnesis. *Chinese Journal of Hepatobiliary Surgery* 2002; 8: 375.
- [46] Zhou YG, Li ZH and Shi GJ. Congenital gallbladder agnesis with operational combination: a case report. *Journal of Hepatopancreatobiliary Surgery* 2002; 14: 131.